

Guidelines on Urological Trauma

D.J. Summerton (Chair), N. Djakovic, N.D. Kitrey,
F.E. Kuehhas, N. Lumen, E. Serafetinidis, D.M. Sharma

TABLE OF CONTENTS

PAGE

1.	INTRODUCTION	6
1.1	Aims and objectives	6
1.2	Panel composition	6
1.2.1	Potential conflict of interest	6
1.3	Available publications	6
1.4	Publication history and summary of changes	6
1.4.1	Publication history	6
1.4.2	Summary of changes	6
2.	METHODS	6
2.1	Evidence sources	6
2.2	Peer review	6
3.	EPIDEMIOLOGY & CLASSIFICATION	6
3.1	Definition and Epidemiology	6
3.1.1	Genito-Urinary Trauma	7
3.2	Classification of trauma	7
3.3	Initial evaluation and treatment	7
4.	UROGENITAL TRAUMA GUIDELINES	8
4.1	Renal Trauma	8
4.1.1	Epidemiology, aetiology and pathophysiology	8
4.1.1.1	Definition and impact of the disease	8
4.1.1.2	Mode of injury	8
4.1.1.2.1	Blunt renal injuries	8
4.1.1.2.2	Penetrating renal injuries	8
4.1.1.3	Classification systems	8
4.1.2	Diagnostic evaluation	9
4.1.2.1	Patient history and physical examination	9
4.1.2.1.1	Recommendations for patient history and physical examination	9
4.1.2.2	Laboratory evaluation	9
4.1.2.2.1	Recommendations for laboratory evaluation	10
4.1.2.3	Imaging: criteria for radiographic assessment	10
4.1.2.3.1	Ultrasonography	10
4.1.2.3.2	Intravenous pyelography	10
4.1.2.3.3	One-shot intraoperative IVP	10
4.1.2.3.4	Computed tomography (CT)	10
4.1.2.3.5	Magnetic resonance imaging (MRI)	11
4.1.2.3.6	Radionuclide scans	11
4.1.2.3.7	Recommendations for radiographic assessment	11
4.1.3	Disease management	11
4.1.3.1	Conservative management	11
4.1.3.1.1	Blunt renal injuries	11
4.1.3.1.2	Penetrating renal injuries	11
4.1.3.1.3	Interventional radiology	12
4.1.3.2	Surgical management	12
4.1.3.2.1	Indications for renal exploration	12
4.1.3.2.2	Operative findings and reconstruction	12
4.1.3.2.3	Recommendations for conservative management	13
4.1.4	Follow-up	13
4.1.4.1	Complications	13
4.1.4.2	Recommendations for follow-up	14
4.1.5	Renal injury in the multitrauma patient	14
4.1.5.1	Recommendations for multitrauma patient management	14
4.1.6	Iatrogenic renal injuries	14
4.1.6.1	Introduction	14
4.1.6.2	Incidence and aetiology	15
4.1.6.3	Diagnosis	15

	4.1.6.4	Management	16
	4.1.6.5	Statements and recommendations for iatrogenic renal injuries	17
	4.1.7	Algorithms	17
4.2		Ureteral Trauma	19
	4.2.1	Incidence	19
	4.2.2	Epidemiology, aetiology, and pathophysiology	20
	4.2.3	Diagnosis	20
	4.2.3.1	Clinical diagnosis	20
	4.2.3.2	Radiological diagnosis	21
	4.2.4	Prevention of iatrogenic trauma	21
	4.2.5	Management	21
	4.2.5.1	Proximal and mid-ureteral injury	21
	4.2.5.2	Distal ureteral injury	21
	4.2.5.3	Complete ureteral injury	21
	4.2.6	Statements and recommendations for ureteral trauma	22
4.3		Bladder Trauma	22
	4.3.1	Classification	22
	4.3.2	Epidemiology, aetiology and pathophysiology	23
	4.3.2.1	Non-iatrogenic trauma	23
	4.3.2.2	Iatrogenic bladder trauma (IBT)	23
	4.3.3	Diagnostic evaluation	24
	4.3.3.1	General evaluation	24
	4.3.3.2	Supplemental evaluation	25
	4.3.3.2.1	Cystography	25
	4.3.3.2.2	Cystoscopy	25
	4.3.3.2.3	Excretory phase of CT or IVP	25
	4.3.3.2.4	Ultrasound	25
	4.3.4	Disease management	25
	4.3.4.1	Conservative management	25
	4.3.4.2	Surgical management	25
	4.3.4.2.1	Blunt non-iatrogenic trauma	25
	4.3.4.2.2	Penetrating non-iatrogenic trauma	26
	4.3.4.2.3	Non-iatrogenic bladder trauma with avulsion of lower abdominal wall or perineum and/or bladder tissue loss	26
	4.3.4.2.4	Iatrogenic bladder trauma	26
	4.3.4.2.5	Intravesical foreign body	26
	4.3.5	Follow-up	26
	4.3.6	Statements and recommendations for bladder injury	26
4.4		Urethral Trauma	27
	4.4.1	Epidemiology, aetiology and pathophysiology	27
	4.4.1.1	Iatrogenic urethral trauma	27
	4.4.1.1.1	Transurethral catheterisation	27
	4.4.1.1.2	Transurethral surgery	27
	4.4.1.1.3	Surgical treatment for prostate cancer	27
	4.4.1.1.4	Radiotherapy for prostate cancer	28
	4.4.1.1.5	Major pelvic surgery and cystectomy	28
	4.4.1.2	Non-iatrogenic urethral injuries	28
	4.4.1.2.1	Anterior urethral injuries (in males)	28
	4.4.1.2.2	Posterior urethral injuries (in males)	29
	4.4.1.3	Urethral injuries in females	29
	4.4.2	Diagnosis in males and females	29
	4.4.2.1	Clinical signs	29
	4.4.2.2	Further diagnostic evaluation	30
	4.4.2.2.1	Retrograde urethrography	30
	4.4.2.2.2	Ultrasound, CT and MR imaging	30
	4.4.2.2.3	Cystoscopy	30
	4.4.2.3	Summary	30
	4.4.3	Disease Management	31
	4.4.3.1	Anterior urethral injuries	31
	4.4.3.1.1	Blunt anterior urethral injuries	31

4.4.3.1.2	Penile fracture-related anterior urethral injuries	31
4.4.3.1.3	Penetrating anterior urethral injuries	31
4.4.3.2	Posterior urethral injuries	31
4.4.3.2.1	Blunt posterior urethral injuries	31
4.4.3.2.1.1	Immediate management	31
4.4.3.2.1.1.1	Partial posterior urethral rupture	32
4.4.3.2.1.1.2	Complete posterior urethral rupture	32
4.4.3.2.1.1.2.1	Immediate realignment	32
4.4.3.2.1.1.2.2	Immediate urethroplasty	32
4.4.3.2.1.1.3	Delayed primary treatment	32
4.4.3.2.1.1.3.1	Delayed primary realignment	33
4.4.3.2.1.1.3.2	Delayed primary urethroplasty	33
4.4.3.2.1.1.4	Deferred treatment	33
4.4.3.2.1.1.4.1	Deferred urethroplasty	33
4.4.3.2.1.1.4.2	Deferred endoscopic treatment	34
4.4.3.2.2	Penetrating posterior urethral injuries	34
4.4.3.2.2.1	Female urethral injuries	34
4.4.3.2.2.1.1	Iatrogenic urethral injuries	34
4.4.3.3	Treatment algorithms	35
4.4.4	Statements and recommendation for urethral trauma	37
4.4.4.1	Statements and recommendations for iatrogenic urethral trauma	38
4.5.	Genital Trauma	38
4.5.1	Introduction and background	38
4.5.2	General principles and pathophysiology	38
4.5.2.1	Gunshot wounds	39
4.5.2.2	Bites	39
4.5.2.2.1	Animal bites	39
4.5.2.2.2	Human bites	39
4.5.2.3	Sexual assault	39
4.5.3	Organ-specific genital trauma	39
4.5.3.1	Penile trauma	39
4.5.3.1.1	Blunt penile trauma	39
4.5.3.1.1.1	Penile fracture	39
4.5.3.2	Penetrating penile trauma	40
4.5.3.3	Penile avulsion injuries and amputation	41
4.5.4	Scrotal trauma	41
4.5.4.1	Blunt scrotal trauma	41
4.5.4.1.1	Testicular dislocation	41
4.5.4.1.2	Haematocoele	41
4.5.4.1.3	Testicular rupture	41
4.5.4.2	Penetrating scrotal trauma	42
4.5.5	Genital trauma in females	42
4.5.5.1	Blunt vulvar injuries	42
4.5.6	Conclusion and recommendations for genital trauma	42
5.	POLYTRAUMA, DAMAGE CONTROL AND MASS CASUALTY EVENTS	43
5.1	Introduction	43
5.1.1	The development of major trauma centres	43
5.1.1.1	Recommendations for polytrauma management	43
5.2	Damage control	43
5.3	Management principles: polytrauma and associated urological injury	43
5.3.1	Statement and recommendation on management principles	44
5.4	Urological injury management in polytrauma	44
5.4.1	Renal injury	44
5.4.1.1	Renal preservation	44
5.4.1.2	Recommendations for the management of renal injury	45
5.4.2	Ureteral injury	45
5.4.2.1	Recommendations for the management of ureteral injury	45
5.4.3	Bladder trauma	45
5.4.3.1	Recommendations for the management of bladder trauma	46

5.4.4	Urethral injury	46
5.4.4.1	Recommendation for the management of urethral injury	46
5.4.5	External genital injury	46
5.5	Mass casualty events	46
5.5.1	Triage	46
5.5.2	Urological role in the mass casualty setting	47
5.5.3	Statements and recommendations for mass casualty events	47
6.	REFERENCES	47
7.	CONFLICT OF INTEREST	67

1. INTRODUCTION

1.1 Aims and objectives

The European Association of Urology (EAU) Guidelines Group for Urological Trauma prepared these guidelines in order to assist medical professionals in the management of urological trauma in adults. Paediatric trauma is addressed in the EAU Paediatric Urology Guidelines.

1.2 Panel composition

The EAU Urological Trauma Guidelines Panel consists of an international group of clinicians with particular expertise in this area.

1.2.1 Potential conflict of interest

The expert panel have submitted potential conflict of interest statements which can be viewed on the EAU website.

1.3 Available publications

A quick reference document (Pocket guidelines) is available, in print and in a number of versions for mobile devices. These are abridged versions which may require consultation together with the full text versions. Also a number of translated versions, alongside several scientific publications in European Urology, the Associations scientific journal are available [1-4]. All documents can be viewed free access through the EAU website: <http://www.uroweb.org/guidelines/online-guidelines/>.

1.4 Publication history and summary of changes

1.4.1 Publication history

The Urological Trauma Guidelines were first published in 2003. This 2015 document presents a limited update of the 2014 publication.

1.4.2 Summary of changes

The literature in the complete document has been assessed and updated, whenever relevant.

Key changes for the 2015 publication:

Figure 4.4.1 – Management of anterior urethral injuries in men, has been revised.

Conclusions and recommendations have been rephrased throughout the document.

2. METHODS

2.1 Evidence sources

The Urological Trauma guidelines are based on a review of the relevant literature, using on-line searches of the following databases: Medline, Embase, Cochrane, and other source documents published between 2002 and 2014. A critical assessment of the findings was made. The majority of publications on the subject are comprised of case reports and retrospective case series. The paucity of high-powered randomised controlled trials makes it difficult to draw meaningful conclusions. The panel recognises this critical limitation.

In this 2015 EAU Guidelines compilation, all standard information on levels of evidence (LE) and grading of recommendations (GR) has been taken out of the individual guidelines topics for the sake of brevity. This information is included in the introductory section of this print.

2.2 Peer review

This document was subjected to double-blind peer review prior to publication.

3. EPIDEMIOLOGY & CLASSIFICATION

3.1 Definition and Epidemiology

Trauma is defined as a physical injury or a wound to living tissue caused by an extrinsic agent. Trauma is the

sixth leading cause of death worldwide, accounting for 10% of all mortalities. It accounts for approximately 5 million deaths each year worldwide and causes disability to millions more [5, 6].

About half of all deaths due to trauma are in people aged 15-45 years and in this age group it is the leading cause of death [7]. Death from injury is twice as common in males than in females, especially from motor vehicle accidents (MVAs) and interpersonal violence. Trauma is therefore a serious public health problem with significant social and economic costs.

Significant variation exists in the causes and the effects of traumatic injuries between geographical areas, and between low, middle, and high-income countries. It should be noted that alcohol and drug abuse increase the rate of traumatic injuries by precipitating interpersonal violence, child and sexual abuse, and MVAs [8].

3.1.1 **Genito-Urinary Trauma**

Genito-urinary trauma is seen in both sexes and in all age groups, but is more common in males.

The kidney is the most commonly injured organ in the genito-urinary system and renal trauma is seen in up to 5% of all trauma cases [9, 10], and in 10% of all abdominal trauma cases [11]. In MVAs, renal trauma is seen after direct impact into the seatbelt or steering wheel (frontal crashes) or from body panel intrusion in side-impact crashes [12].

Ureteral trauma is relatively rare and mainly due to iatrogenic injuries or penetrating gunshot wounds – both in military and civilian settings [13].

Traumatic bladder injuries are usually due to blunt causes (MVA) and associated with pelvic fracture [14], although may also be a result of iatrogenic trauma.

The anterior urethra is most commonly injured by blunt or “fall-astride” trauma, whereas the posterior urethra is usually injured in pelvic fracture cases - the majority of which are seen in MVAs [15].

Genital trauma is much more common in males due to anatomical considerations and more frequent participation in physical sports, violence and war-fighting. Of all genito-urinary injuries, 1/3-2/3 involve the external genitalia [16].

3.2 **Classification of trauma**

Traumatic injuries are classified by the World Health Organization (WHO) into intentional (either interpersonal violence related, war-related or self-inflicted injuries), and unintentional injuries - mainly motor vehicle collisions, falls, and other domestic accidents. Intentional trauma accounts for approximately half of the trauma-related deaths worldwide [6]. A specific type of unintentional injury consists of iatrogenic injury which is created during therapeutic- or diagnostic procedures by healthcare personnel.

Traumatic insults are classified according to the basic mechanism of the injury into penetrating when an object pierces the skin, and blunt injuries.

Penetrating trauma is further classified according to the velocity of the projectile into:

1. High-velocity projectiles (e.g. rifle bullets - 800-1000 m/sec);
2. Medium-velocity projectiles (e.g. handgun bullets - 200-300 m/sec);
3. Low-velocity items (e.g. knife stab).

High-velocity weapons inflict greater damage because the bullets transmit large amounts of energy to the tissues. They form a temporary expansive cavitation that immediately collapses and creates shear forces and destruction in a much larger area than the projectile tract itself. Cavity formation disrupts tissue, ruptures blood vessels and nerves, and may fracture bones away from the path of the missile. In lower velocity injuries, the damage is usually confined to the track of the projectile.

Blast injury is a complex cause of trauma because it commonly includes both blunt and penetrating trauma, and may also be accompanied by a burn injury.

Several classifications are used to describe the severity and the features of a traumatic injury. The most common is the AAST (American Association for the Surgery of Trauma) injury scoring scale, which is widely used in renal trauma (see the relevant section) <http://www.aast.org/library/traumatools/injuryscoringscales.aspx> [17]. For the other urological organs, general practice is that injuries are described by their anatomical site and severity (partial/complete) and the elaborated AAST tables were therefore omitted from these guidelines.

3.3 **Initial evaluation and treatment**

The initial emergency assessment of the trauma patient is beyond the focus of these guidelines, and is usually carried out by emergency medicine and trauma specialised personnel. The first priority is stabilisation of the patient and treatment of associated life-threatening injuries. The initial treatment should include securing the

airway, controlling external bleeding and resuscitation of shock. In many cases, physical examination is carried out during stabilisation of the patient.

A direct history is obtained from conscious patients, while witnesses and emergency personnel can provide valuable information about unconscious or seriously injured patients. In penetrating injuries, important information includes the size of the weapon in stabbings, and the type and calibre of the weapon used in gunshot wounds. The medical history should be as detailed as possible, as pre-existing organ dysfunction can have a negative effect on trauma patient outcome [18, 19].

It is essential that all persons treating trauma patients are aware of the risk of hepatitis B and C infection. An infection rate of 38% was reported among males with penetrating wounds to the external genitalia [20]. In any penetrating trauma, tetanus vaccination should be considered according to the patient's vaccination history and the features of the wound itself (CDC tetanus wound management) [21].

4. UROGENITAL TRAUMA GUIDELINES

4.1 Renal Trauma

4.1.1 *Epidemiology, aetiology and pathophysiology*

4.1.1.1 *Definition and impact of the disease*

Renal trauma occurs in approximately 1-5% of all trauma cases [10, 22]. The kidney is the most commonly injured genitourinary organ, with a male to female ratio of 3:1 [23, 24]. Most injuries can be managed conservatively as advances in imaging and treatment strategies have decreased the need for surgical intervention and increased organ preservation [11, 25, 26].

4.1.1.2 *Mode of injury*

4.1.1.2.1 Blunt renal injuries

Blunt mechanisms include motor vehicle collision, falls, vehicle-associated pedestrian accidents, sports and assault. Traffic accidents are the major cause, accounting for almost half of blunt injuries [27]. A direct blow to the flank or abdomen during sports activities is another cause. Sudden deceleration or a crush injury may result in contusion or laceration of the parenchyma.

In general, renal vascular injuries occur in less than 5% of blunt abdominal trauma, while isolated renal artery injury is very rare (0.05-0.08%) [11] and renal artery occlusion is associated with rapid deceleration injuries.

4.1.1.2.2 Penetrating renal injuries

Gunshot and stab wounds represent the most common causes of penetrating injuries and tend to be more severe and less predictable than blunt trauma. In urban settings, the percentage of penetrating injuries can be as high as 20% or higher [28, 29]. Bullets have the potential for greater parenchymal destruction and are most often associated with multiple-organ injuries [30]. Penetrating injury produces direct tissue disruption of the parenchyma, vascular pedicles, or collecting system.

4.1.1.3 *Classification systems*

The most commonly used classification system is that of the American Association for the Surgery of Trauma (AAST) [17] (Table 4.1.1). This validated system has clinical and prognostic relevance and helps to predict the need for intervention [31-33]. It also predicts morbidity after blunt or penetrating injury and mortality after blunt injury [33].

Table 4.1.1: AAST renal injury grading scale

Grade*	Description of injury
1	Contusion or non-expanding subcapsular haematoma
	No laceration
2	Non-expanding peri-renal haematoma
	Cortical laceration < 1 cm deep without extravasation
3	Cortical laceration > 1 cm without urinary extravasation

4	Laceration: through corticomedullary junction into collecting system <i>or</i> Vascular: segmental renal artery or vein injury with contained haematoma, or partial vessel laceration, or vessel thrombosis
5	Laceration: shattered kidney <i>or</i> Vascular: renal pedicle or avulsion

**Advance one grade for bilateral injuries up to grade III.*

Proposals for changes include a substratification of the intermediate grade injury into grade 4a (low-risk-cases likely to be managed non-operatively) and grade 4b (high risk-cases likely to benefit from angiographic embolisation, repair or nephrectomy), based on the presence of important radiographic risk factors, including peri-renal haematoma, intravascular contrast extravasation and laceration complexity [34], as well as a suggestion that grade 4 injuries comprise all collecting system injuries, including ureteropelvic junction (UPJ) injury of any severity and segmental arterial and venous injuries, while grade 5 injuries should include only hilar injuries, including thrombotic events [35].

4.1.2 **Diagnostic evaluation**

4.1.2.1 *Patient history and physical examination*

Vital signs should be recorded throughout the diagnostic evaluation. Possible indicators of major injury include a history of a rapid deceleration event (fall, high-speed motor vehicle accidents) or a direct blow to the flank. In the early resuscitation phase, special consideration should be given to pre-existing renal disease [36]. In patients with a solitary kidney, the whole functioning renal mass may be endangered [37, 38]. Pre-existing abnormality makes injury more likely following trauma. Hydronephrosis due to UPJ abnormality, calculi, cysts and tumours are the most commonly reported entities that may complicate a minor injury [38].

Physical examination may reveal an obvious penetrating trauma from a stab wound to the lower thoracic back, flanks and upper abdomen, or bullet entry or exit wounds. In stab wounds, the extent of the entrance wound may not accurately reflect the depth of penetration.

Blunt trauma to the back, flank, lower thorax or upper abdomen may result in renal injury. Haematuria, flank pain, ecchymoses, abrasions, fractured ribs, abdominal distension and/or a mass and tenderness raise the suspicion of renal involvement.

4.1.2.1.1 Recommendations for patient history and physical examination

	GR
Haemodynamic stability should be assessed upon admission.	A*
History should be taken from conscious patients, witnesses and rescue team personnel with regard to the time and setting of the incident.	A*
Past renal surgery, and known pre-existing renal abnormalities (UPJ obstruction, large cysts, lithiasis) should be recorded.	A*
A thorough physical examination should be made to rule out penetrating injury. Haematuria, flank pain, flank abrasions and bruising ecchymoses, fractured ribs, abdominal tenderness, distension or mass, could indicate possible renal involvement.	A*

**Upgraded following panel consensus.*

GR = grade of recommendation.

4.1.2.2 *Laboratory evaluation*

Urinalysis, haematocrit and baseline creatinine are the most important tests. Haematuria, either non-visible or visible is often seen, but is neither sensitive nor specific enough to differentiate between minor and major injuries [39].

Major injury, such as disruption of the UPJ, pedicle injuries, segmental arterial thrombosis and approximately 9% of patients with stab wounds and renal injury may occur without haematuria [40, 41]. Haematuria that is out of proportion to the history of trauma may suggest pre-existing pathology [42]. A urine dipstick is an acceptable reliable and rapid test to evaluate haematuria, however, the rate of false-negative results range from 3-10% [43].

Serial haematocrit determinations in combination with vital signs are used for continuous evaluation of the patient. A decrease in haematocrit and the requirement for blood transfusions are indirect signs of the rate of blood loss, and along with the patient's response to resuscitation, are valuable in the decision-making process. However, until evaluation is complete, it will not be clear whether this is due to renal trauma and/or associated injuries.

As most trauma patients are evaluated within 1 hour of injury, creatinine measurement reflects renal function prior to the injury. An increased creatinine level usually reflects pre-existing renal pathology.

4.1.2.2.1 Recommendations for laboratory evaluation

	GR
Urine from a patient with suspected renal injury should be inspected for haematuria (visually and by dipstick analysis).	A*
Creatinine levels should be measured to identify patients with impaired renal function prior to injury.	C

*Upgraded following panel consensus.

GR = grade of recommendation.

4.1.2.3 Imaging: criteria for radiographic assessment

Decisions on radiographic imaging in cases of suspected renal trauma are based on the clinical findings and the mechanism of injury. Indications for radiographic evaluation are visible haematuria, non-visible haematuria with hypotension, or the presence of major associated injuries. However, patients with a history of rapid deceleration injury or clinical indicators of renal trauma also need immediate imaging to rule out ureteral avulsion or pedicle injury [44]. Patients with non-visible haematuria and no shock after blunt trauma have a low likelihood of concealing significant injury.

Patients with penetrating trauma to the torso have a high incidence of significant renal injuries. If there is such a suspicion on the basis of an entry or exit wound, imaging should be performed, regardless of the degree of haematuria [45].

4.1.2.3.1 Ultrasonography

Ultrasound (US) scans can detect lacerations, but cannot accurately assess their depth and extent. They do not provide functional information about excretion or urine leakage. Ultrasound is useful for the routine follow-up of parenchymal lesions or haematomas and for serial evaluation of stable injuries, as well as for assessment of the resolution of urinomas [39]. Ultrasound can also identify which patients require an aggressive radiological exploration to obtain a diagnosis [46]. Contrast-enhanced sonography is described as more sensitive, but it is not commonly used [47].

4.1.2.3.2 Intravenous pyelography

The use of intravenous pyelography (IVP) is recommended only when it is the only modality available [48]. IVP can be used to establish the presence or absence of one or both kidneys, clearly define the parenchyma and outline the collecting system. The most significant findings are non-function and extravasation. Non-function is a sign of extensive trauma to the kidney, pedicle injury, or a severely shattered kidney. Extravasation of the contrast medium implies a severe degree of trauma, involving the capsule, parenchyma and collecting system. Non-visualisation, contour deformity or contrast extravasation should prompt further radiological evaluation. The sensitivity of IVP is high (> 92%) for all grades of renal injury trauma [49].

4.1.2.3.3 One-shot intraoperative IVP

In unstable patients undergoing emergency laparotomy, IVP may provide information on the presence of a normal functioning contralateral kidney [50]. The technique consists of a bolus intravenous injection of 2 mL/kg of radiographic contrast followed by a single plain film taken after 10 minutes.

4.1.2.3.4 Computed tomography (CT)

CT is the best method for assessment of stable patients. CT is more sensitive and specific than IVP, ultrasonography or angiography, since it accurately defines the location of injuries, easily detects contusions and devitalised segments, visualises the entire retroperitoneum and any associated haematomas, and simultaneously provides a view of both the abdomen and pelvis. It demonstrates superior anatomical details, including the depth and location of lacerations and the presence of associated abdominal injuries, and establishes the presence and location of the contralateral kidney [49, 51].

Intravenous contrast should be administered for renal evaluation. A lack of contrast enhancement is a hallmark of pedicle injury. In cases where this typical finding is not demonstrated, central parahilar haematoma may also raise the possibility of pedicle injury. This sign should be considered even if the parenchyma is well enhanced [52]. Renal vein injury is difficult to diagnose, but the presence on CT of a large haematoma, medial to the kidney and displacing the vasculature, should raise the suspicion. Spiral CT provides fewer artefacts in the examination of patients who cannot co-operate adequately [53]. Three-dimensional post-processing modalities allow assessment of the vascular pedicle by CT angiography and improve the demonstration of complex lacerations of the parenchyma [54]. As injury to the collecting system may be missed

during routine spiral CT, in all cases of suspected trauma, repeat scans of the kidneys should be performed 10-15 minutes after contrast injection [55]. Most blunt ureteral and UPJ injuries can be identified with delayed excretory CT scans [56]. CT scanning is an essential diagnostic modality in patients with gunshot wounds who are being considered for non-operative management [57]. Missed injuries are common, but are mostly minor, and do not alter the patients' clinical course [58].

4.1.2.3.5 Magnetic resonance imaging (MRI)

MRI is not commonly used in this setup, although it is sensitive for the evaluation of blunt renal trauma [59]. MRI requires a longer imaging time and limits access to patients during the examination, and is therefore useful only if CT is not available, in patients with iodine allergy, or in cases where CT findings are equivocal [60].

4.1.2.3.6 Radionuclide scans

Radionuclide scans are generally used or required only in trauma patients with allergy to iodinated contrast material [49].

4.1.2.3.7 Recommendations for radiographic assessment

	GR
Blunt trauma patients with visible haematuria or non-visible haematuria and haemodynamic instability should undergo radiographic evaluation.	A*
Radiographic evaluation is recommended for all patients with a history of rapid deceleration injury and/or significant associated injuries.	B
All patients with or without haematuria after penetrating abdominal or lower thoracic injury require urgent renal imaging.	A*
Ultrasonography alone should not be used to set the diagnosis of renal injury as it cannot provide sufficient information. However, it can be informative during the primary evaluation of multitrauma patients and for the follow-up of recuperating patients.	C
A CT scan with enhancement of intravenous contrast material and delayed images is the gold standard for the diagnosis and staging of renal injuries in haemodynamically stable patients.	A

**Upgraded following panel consensus.*

GR = grade of recommendation.

4.1.3 Disease management

4.1.3.1 Conservative management

4.1.3.1.1 Blunt renal injuries

Haemodynamic stability is the primary criterion for the management of all renal injuries. Non-operative management has become the treatment of choice for most renal injuries. In stable patients, this means supportive care with bed-rest and observation. Primary conservative management is associated with a lower rate of nephrectomies, without any increase in the immediate or long-term morbidity [61]. Hospitalisation or prolonged observation for evaluation of possible injury after a normal abdominal CT scan, when combined with clinical judgment, is unnecessary in most cases [62]. All grade 1 and 2 injuries, either due to blunt or penetrating trauma, can be managed non-operatively, whether due to blunt or penetrating trauma. For the treatment of grade 3 injuries, most studies support expectant treatment [63-65].

Most patients with grade 4 and 5 injuries present with major associated injuries, and consequently often undergo exploration and nephrectomy rates [66], although emerging data indicate that many of these patients can be managed safely with an expectant approach [67]. An initially conservative approach is feasible in stable patients with devitalised fragments [68], although these injuries are associated with an increased rate of complications and late surgery [69]. Patients diagnosed with urinary extravasation from solitary injuries can be managed without major intervention with a resolution rate of > 90% [67, 70]. Similarly, unilateral main arterial injuries are normally managed non-operatively in a haemodynamically stable patient with surgical repair reserved for bilateral artery injuries or injuries involving a solitary functional kidney. Conservative management is also advised in the treatment of unilateral complete blunt arterial thrombosis. However, a blunt arterial thrombosis in multiple trauma patients is usually associated with severe injuries and attempts of repair are usually unsuccessful [71].

4.1.3.1.2 Penetrating renal injuries

Penetrating wounds have traditionally been approached surgically. A systematic approach based on clinical, laboratory and radiological evaluation minimises the incidence of negative exploration without increasing

morbidity from a missed injury [72]. Selective non-operative management of abdominal stab wounds is generally accepted following complete staging in stable patients [65, 73]. If the site of penetration by the stab wound is posterior to the anterior axillary line, 88% of such injuries can be managed non-operatively [74]. Stab wounds producing major renal injuries (grade 3 or higher) are more unpredictable and are associated with a higher rate of delayed complications if treated expectantly [75].

Isolated grade 4 injuries represent a unique situation where treatment of the patient is based solely on the extent of the renal injury. Gunshot injuries should be explored only if they involve the hilum or are accompanied by signs of ongoing bleeding, ureteral injuries, or renal pelvis lacerations [76]. Minor low-velocity gunshot and stab wounds may be managed conservatively with an acceptably good outcome [77]. In contrast, tissue damage due to high-velocity gunshot injuries can be more extensive and nephrectomy may be required. Non-operative management of penetrating injuries in selected stable patients is associated with a successful outcome in approximately 50% of stab wounds and up to 40% of gunshot wounds [78-80].

4.1.3.1.3 Interventional radiology

Angiography with selective embolisation is the first-line option in the absence of other indications for immediate open surgery. The main indications for angiography are: embolisation for active haemorrhage, pseudo-aneurysm, and vascular fistulae [81]. Higher grade of renal injury is associated with an increased risk of failure for the first attempt and a need for repeat intervention [82]. However, initial and/or repeat embolisation for high grade injuries prevents nephrectomy in > 75% of these patients. Secondary open surgery after failed embolisation usually results in nephrectomy [83]. Embolisation is 3 times more likely to fail in penetrating trauma. However, with reports that conservative management of penetrating trauma is possible in selected cases, renal embolisation in the setting of failed conservative therapy for penetrating trauma must be critically considered [72]. In cases of severe multitrauma or high operative risk, the main artery may be embolised, either as a definitive treatment or to be followed by interval nephrectomy.

4.1.3.2 Surgical management

4.1.3.2.1 Indications for renal exploration

The need for renal exploration can be predicted by considering the type of injury, transfusion requirements, blood urea nitrogen (BUN), creatinine and injury grade [84]. However, the management of renal injury may also be influenced by the decision to explore or observe associated abdominal injuries [85].

Continuing haemodynamic instability unresponsive to aggressive resuscitation due to renal haemorrhage is an indication for exploration, irrespective of the mode of injury [72, 86]. Other indications include an expanding or pulsatile peri-renal haematoma identified at exploratory laparotomy performed for associated injuries. Persistent extravasation or urinoma are usually managed successfully with endourological techniques. Inconclusive imaging and a pre-existing abnormality or an incidentally diagnosed tumour may require surgery even after minor renal injury [42].

Grade 5 vascular injuries are regarded as an absolute indication for exploration, but parenchymal grade 5 patients who are stable at presentation may be safely treated conservatively [87-90]. In these patients, intervention is predicted by the need for continued fluid and blood resuscitation, peri-renal haematoma size > 3.5 cm and the presence of intravascular contrast extravasation [34].

4.1.3.2.2 Operative findings and reconstruction

The overall exploration rate for blunt trauma is less than 10% [86], and may be even lower as the conservative approach is increasingly adopted [91]. The goal of exploration following renal trauma are control of haemorrhage and renal salvage.

Most series suggest the transperitoneal approach for surgery [92, 93]. Access to the pedicle is obtained either through the posterior parietal peritoneum, which is incised over the aorta, just medial to the inferior mesenteric vein or by bluntly dissecting along the plane of the psoas muscle fascia, adjacent to the great vessels, and directly placing a vascular clamp on the hilum [94]. Stable haematomas detected during exploration for associated injuries should not be opened. Central or expanding haematomas indicate injuries of the renal pedicle, aorta, or vena cava and are potentially life-threatening [95].

In cases with unilateral arterial intimal disruption, repair can be delayed, especially in the presence of a normal contralateral kidney. However, prolonged warm ischaemia usually results in irreparable damage and renal loss. Entering the retroperitoneum and leaving the confined haematoma undisturbed within the perinephric fascia is recommended unless it is violated and cortical bleeding is noted; packing the fossa tightly with laparotomy pads temporarily can salvage the kidney [96]. Haemorrhage can occur while the patient is resuscitated, warmed, and awaits re-exploration, however, careful monitoring is sufficient. A brief period of controlled local urinary extravasation is unlikely to result in a significant adverse event or impact overall recovery. During the next 48 to 72 hours, CT scans can identify injuries and select patients for reconstruction or continued expectant management [97]. Ureteral stenting or nephrostomy diversion should be considered after

delayed reconstruction due to the increased risk of postoperative urinary extravasation.

Renal reconstruction is feasible in most cases. The overall rate of patients who undergo a nephrectomy during exploration is around 13%, usually in patients with penetrating injuries and higher rates of transfusion requirements, haemodynamic instability, and higher injury severity scores [98]. Other intra-abdominal injuries also slightly increase the need for nephrectomy [99]. Mortality is associated with overall severity of the injury and not often a consequence of the renal injury itself [100]. In gunshot injuries caused by a high-velocity bullet, reconstruction can be difficult and nephrectomy is often required [101]. Renorrhaphy is the most common reconstructive technique. Partial nephrectomy is required when non-viable tissue is detected. Watertight closure of the collecting system, if open, is desirable, although closing the parenchyma over the injured collecting system also has good results. If the capsule is not preserved, an omental pedicle flap or peri-renal fat bolster may be used for coverage [102]. The use of haemostatic agents and sealants in reconstruction can be helpful [103]. In all cases, drainage of the ipsilateral retroperitoneum is recommended.

Following blunt trauma, repair of vascular injuries (grade 5) is seldom, if ever, effective [104]. Repair should be attempted in patients with a solitary kidney or bilateral injuries [105], but is not used in the presence of a functioning contralateral kidney [26]. Nephrectomy for main artery injury has outcomes similar to those of vascular repair and does not worsen post-treatment renal function in the short-term.

4.1.3.2.3 Recommendations for conservative management

	GR
Following blunt renal trauma, stable patients should be managed conservatively with close monitoring of vital signs.	B
Isolated grade 1-3 stab and low-velocity gunshot wounds in stable patients, after complete staging, should be managed expectantly.	B
Indications for renal exploration include: <ul style="list-style-type: none"> • haemodynamic instability; • exploration for associated injuries; • expanding or pulsatile peri-renal haematoma identified during laparotomy; • grade 5 vascular injury. 	B
Radiological embolisation is indicated in patients with active bleeding from renal injury, but without other indications for immediate abdominal operation.	B
Intraoperatively, renal reconstruction should be attempted once haemorrhage is controlled and there is sufficient viable renal parenchyma.	B

GR = grade of recommendation.

4.1.4 Follow-up

The risk of complications in patients who have been treated conservatively increases with injury grade. Repeat imaging 2-4 days after trauma minimises the risk of missed complications, especially in grade 3-5 blunt injuries [106]. The usefulness of frequent CT scanning after injury has never been satisfactorily proved. CT scans should always be performed on patients with fever, unexplained decreased haematocrit or significant flank pain. Repeat imaging can be safely omitted for patients with grade 1-4 injuries as long as they remain clinically well [107].

Nuclear scans are useful for documenting and tracking functional recovery following renal reconstruction [108]. Follow-up should involve physical examination, urinalysis, individualised radiological investigation, serial blood pressure measurement and serum determination of renal function [68]. A decline in renal function correlates directly with injury grade; this is independent of the mechanism of injury and the method of management [109, 110]. Follow-up examinations should continue until healing is documented and laboratory findings have stabilised, although checking for latent renovascular hypertension may need to continue for years [111]. In general, the literature is inadequate on the subject of the long-term consequences of renal tissue trauma.

4.1.4.1 Complications

Early complications, occurring less than 1 month after injury, include bleeding, infection, perinephric abscess, sepsis, urinary fistula, hypertension, urinary extravasation and urinoma. Delayed complications include bleeding, hydronephrosis, calculus formation, chronic pyelonephritis, hypertension, arteriovenous fistula, hydronephrosis and pseudo-aneurysms. Delayed retroperitoneal bleeding may be life-threatening and selective angiographic embolisation is the preferred treatment [112]. Perinephric abscess formation is best managed by percutaneous drainage, although open drainage may sometimes be required. Percutaneous management of complications may pose less risk of renal loss than re-operation, when infected tissues make reconstruction difficult [86].

Renal trauma is a rare cause of hypertension, and is mostly observed in young men. The frequency of posttraumatic hypertension is estimated to be less than 5% [113, 114]. Hypertension may occur acutely as a result of external compression from peri-renal haematoma (Page kidney), or chronically due to compressive scar formation. Renin-mediated hypertension may occur as a long-term complication; aetiologies include renal artery thrombosis, segmental arterial thrombosis, renal artery stenosis (Goldblatt kidney), devitalised fragments and arteriovenous fistulae (AVF). Arteriography is informative in cases of post-traumatic hypertension. Treatment is required if the hypertension persists and could include medical management, excision of the ischaemic parenchymal segment, vascular reconstruction, or total nephrectomy [115].

Urinary extravasation after reconstruction often subsides without intervention as long as ureteral obstruction and infection are not present. Ureteral retrograde stenting may improve drainage and allow healing [116]. Persistent urinary extravasation from an otherwise viable kidney after blunt trauma often responds to stent placement and/or percutaneous drainage as necessary [117].

Arteriovenous fistulae usually present with delayed onset of significant haematuria, most often after penetrating trauma. Percutaneous embolisation is often effective for symptomatic AVF, but larger ones may require surgery [118]. Post-procedural complications include infection, sepsis, urinary fistula, and renal infarction [119]. The development of pseudo-aneurysm is a rare complication following blunt trauma. In numerous case reports, transcatheter embolisation appears to be a reliable minimally invasive solution [120]. Acute renal colic from a retained missile has been reported, and can be managed endoscopically if possible [121].

4.1.4.2 Recommendations for follow-up

	GR
Repeat imaging is recommended in cases of fever, flank pain, or falling haematocrit.	B
Nuclear scintigraphy is useful for documenting functional recovery.	C
First follow-up should be approximately 3 months after major renal injury with hospitalisation. Each follow-up should include: physical examination, urinalysis, individualised radiological investigation, serial blood pressure measurement and renal function tests.	C
Medical management and minimally invasive techniques should be the first choice for the management of complications.	C
Long-term follow-up should be decided on a case-by-case basis.	C

GR = grade of recommendation.

4.1.5 Renal injury in the multitrauma patient

Approximately 8-10% of blunt and penetrating abdominal injuries involve the kidneys. The incidence of associated injury in penetrating renal trauma ranges from 77% to 100%. Gunshot wounds are associated with adjacent organ injury more often than stab wounds. Most patients with penetrating renal trauma have associated adjacent organ injuries that may complicate treatment. In the absence of an expanding haematoma with haemodynamic instability, associated multiorgan injuries do not increase the risk of nephrectomy [29]. Blunt and penetrating injuries contribute equally to combined renal and pancreatic injury. Renal preservation is achieved in most patients, and the complication rate is 15% [122]. A similar rate of complications (16%) is reported in patients with simultaneous colon and renal injury [123]. Renal injuries seem to be rare in patients with blunt chest trauma [89].

4.1.5.1 Recommendations for multitrauma patient management

	GR
Multitrauma patients with associated renal injuries should be evaluated on the basis of the most significant injury.	C
In cases where surgical intervention is chosen, all associated abdominal injuries should be managed where appropriate simultaneously.	C
When deciding on conservative management all injuries should be considered independently.	C

GR = grade of recommendation.

4.1.6 Iatrogenic renal injuries

4.1.6.1 Introduction

Iatrogenic renal trauma (IRT) is rare, but can lead to significant morbidity.

4.1.6.2 Incidence and aetiology

The commonest causes of IRT are listed in Table 4.1.2 [124].

Table 4.1.2: Incidence and aetiology of commonest iatrogenic renal trauma during various procedures

Procedure	Haemorrhage	AVF	Pseudoaneurysm	Renal pelvis injury	Aortocaliceal fistula	Foreign body
Nephrostomy	+		+	+		
Biopsy	+ (0.5-1.5%)	+	+ (0.9%)			
PCNL	+	+		+		
Laparoscopic surgery (oncology)	+					
Open surgery (oncology)	+		+ (0.43%)			+
Transplantation	+	+	+		+	
Endopyelotomy	+			+		+
Endovascular procedure	+ (1.6%)					

AVF = arteriovenous fistulae; PCNL = percutaneous nephrolithotomy.

Large haematomas after biopsy (0.5-1.5%) are caused by laceration or arterial damage [125]. Renal artery and intraparenchymal pseudo-aneurysms (0.9%) may be caused by percutaneous biopsy, nephrostomy, and partial nephrectomy (0.43%) [126]. In PCNL, haemorrhage is the most dangerous IRT, especially when punctures are too medial or directly entering the renal pelvis. Other injuries include AVF or a tear in the pelvicaliceal system.

Iatrogenic renal injuries associated with renal transplantation include AVF, intrarenal pseudo-aneurysms, arterial dissection and arterio-caliceal fistulas. Pseudo-aneurysm is a rare complication of allograft biopsy. Although the overall complication rate following biopsy in transplanted kidneys is 9% (including haematoma, AVF, visible haematuria and infection), vascular complications requiring intervention account for 0.2-2.0% [127]. Predisposing factors include hypertension, renal medullary disease, central biopsies, and numerous needle passes [128]. Arteriovenous fistulae and pseudo-aneurysms can occur in 1-18% of allograft biopsies [125].

Extrarenal pseudo-aneurysms after transplantation procedures generally occur at the anastomosis, in association with local or haematogenous infection. Arterial dissection related to transplantation is rare and presents in the early postoperative period [129].

Iatrogenic renal trauma associated with endopyelotomy is classified as major (vascular injury), and minor (urinoma) [130]. Patients undergoing cryoablation for small masses via the percutaneous or the laparoscopic approach may have asymptomatic perinephric haematoma and self-limited urine leakage.

Vascular injury is a rare complication (1.6%) of endovascular interventions in contrast to patients with surgical injuries. The renal vessels are vulnerable mainly during oncological procedures [131]. Renal foreign bodies, with retained sponges or wires during open or endourological procedures, are uncommon.

4.1.6.3 Diagnosis

Haematuria is common after insertion of nephrostomies, but massive retroperitoneal haemorrhage is rare. Following percutaneous biopsy, AVF may occur with severe hypertension. A pseudo-aneurysm should be suspected if the patient presents with flank pain and decreasing haematocrit, even in the absence of haematuria.

During PCNL, acute bleeding may be caused by injury to the anterior or posterior segmental arteries, or late postoperative bleeding may be caused by interlobar and lower-pole arterial lesions, AVF and post-traumatic aneurysms [132]. Duplex ultrasound and CT angiography can be used to diagnose vascular injuries. A close watch on irrigation fluid input and output is required to ensure early recognition of fluid extravasation. Intra-operative evaluation of serum electrolytes, acid-base status, oxygenation, and monitoring of airway pressure are good indicators of this complication.

In arterial dissection related to transplantation, symptoms include anuria and a prolonged dependence on dialysis. Doppler ultrasound can demonstrate compromised arterial flow. Dissection can lead to thrombosis of the renal artery and/or vein.

After angioplasty and stent-graft placement in the renal artery, during which wire or catheters may enter the parenchyma and penetrate through the capsule, possible radiological findings include AVF, pseudo-aneurysm, arterial dissection and contrast extravasation. Common symptoms of pseudo-aneurysms are flank

pain and visible haematuria within 2 or 3 weeks after surgery [133]. Transplant AVF and pseudo-aneurysms may be asymptomatic or may cause visible haematuria or hypovolemia due to shunting and the 'steal' phenomenon, renal insufficiency, hypertension, and high output cardiac failure.

Patients with extrarenal pseudo-aneurysms (post-transplantation) may present with infection/bleeding, swelling, pain and intermittent claudication. Doppler ultrasound findings for AVFs include high-velocity, low-resistance, spectral waveforms, with focal areas of disorganised colour flow outside the normal vascular borders, and possibly a dilated vein [134]. Pseudo-aneurysms appear on ultrasound as anechoic cysts, with intracystic flow on colour Doppler.

Potential complications of retained sponges include abscess formation, fistula formation to the skin or intestinal tract, and sepsis. Retained sponges may look like pseudo-tumours or appear as solid masses. MRI clearly shows the characteristic features [135]. Absorbable haemostatic agents may also produce a foreign-body giant cell reaction, but the imaging characteristics are not specific. Retained stents, wires, or fractured Acucise cutting wires may also present as foreign bodies and can serve as a nidus for stone formation [136].

4.1.6.4 Management

If a nephrostomy catheter appears to transfix the renal pelvis, significant arterial injury is possible. The misplaced catheter should be withdrawn and embolisation may rapidly arrest the haemorrhage. CT can also successfully guide repositioning of the catheter into the collecting system [137]. Small subcapsular haematomas after insertion of nephrostomies resolve spontaneously, while AVF are best managed by embolisation. AVF and pseudo-aneurysms after biopsy are also managed by embolisation [138].

During PCNL, bleeding can be venous or arterial. In major venous trauma with haemorrhage, patients with concomitant renal insufficiency can be treated without open exploration or angiographic embolisation using a Council-tip balloon catheter [139]. In the case of profuse bleeding at the end of a PCNL, conservative management is usually effective. The patient should be placed in the supine position, clamping the nephrostomy catheter and forcing diuresis. Superselective embolisation is required in less than 1% of cases and has proved effective in more than 90% [140]. Short-term deleterious effects are more pronounced in patients with a solitary kidney, but long-term follow-up shows functional and morphological improvements [141]. Termination of PCNL if the renal pelvis is torn or ruptured is a safe choice. Management requires close monitoring, placement of an abdominal or retroperitoneal drain and supportive measures [142]. Most surgical venous injuries include partial lacerations that can be managed with various techniques, such as venorrhaphy, patch angioplasty with autologous vein, or an expanded polytetrafluoroethylene (ePTFE) graft [143]. If conservative measures fail in cases of pseudo-aneurysm and clinical symptoms or a relevant decrease in haemoglobin occurs, transarterial embolisation should be considered [144]. As the success rate is similar for initial and repeat interventions, a repeat intervention is justified when the clinical course allows this [82].

Traditionally, patients with postoperative haemorrhage following intra-abdominal laparoscopic surgery of the kidney require laparotomy. Pseudo-aneurysms and AVF are uncommon after minimally invasive partial nephrectomy, but can lead to significant morbidity. Temporary haemostasis occurs with coagulation and/or tamponade, but later degradation of the clot, connection with the extravascular space, and possible fistula formation within the collecting system may develop. Patients typically present with visible haematuria, even though they may also experience flank pain, dizziness and fever. Embolisation is the reference standard for both diagnosis and treatment in the acute setting, although CT can be used if the symptoms are not severe and/or the diagnosis is ambiguous. Reports have described good preservation of renal function after embolisation [145].

Endoluminal management after renal transplantation consists of stabilising the intimal flap with stent placement. Embolisation is the treatment of choice for a symptomatic transplant AVF or enlarging pseudo-aneurysm [146]. Superselective embolisation with a coaxial catheter and metallic coils helps to limit the loss of normal functioning graft tissue [147]. Failure of embolisation is associated with a high nephrectomy rate. The long-term outcome depends on the course of the transplant and the amount of contrast medium used during the procedure.

Surgical treatment for AVF consists of partial or total nephrectomy or arterial ligation, which results in loss of part of the transplant or the entire transplant. To date, surgery has been the main approach in the treatment of renal vascular injuries. In patients with retroperitoneal haematoma, AVF, and haemorrhagic shock, interventional therapy is associated with a lower level of risk compared to surgery [148]. Renal arteriography followed by selective embolisation can confirm the injury. In injuries during angioplasty and stent-graft placement, transcatheter embolisation is the first choice of treatment [149]. The treatment for acute iatrogenic rupture of the main renal artery is balloon tamponade. If this fails, immediate availability of a stent graft is vital [150]. The true nature of lesions caused by foreign bodies is revealed after exploration.

4.1.6.5 Statements and recommendations for iatrogenic renal injuries

Statements	LE
Iatrogenic renal injuries are procedure-dependent (1.8-15%).	3
Significant injury requiring intervention is rare.	3
The most common injuries are vascular.	3
Renal allografts are more susceptible.	3
Injuries occurring during surgery are rectified immediately.	3
Symptoms suggestive of a significant injury require investigation.	3

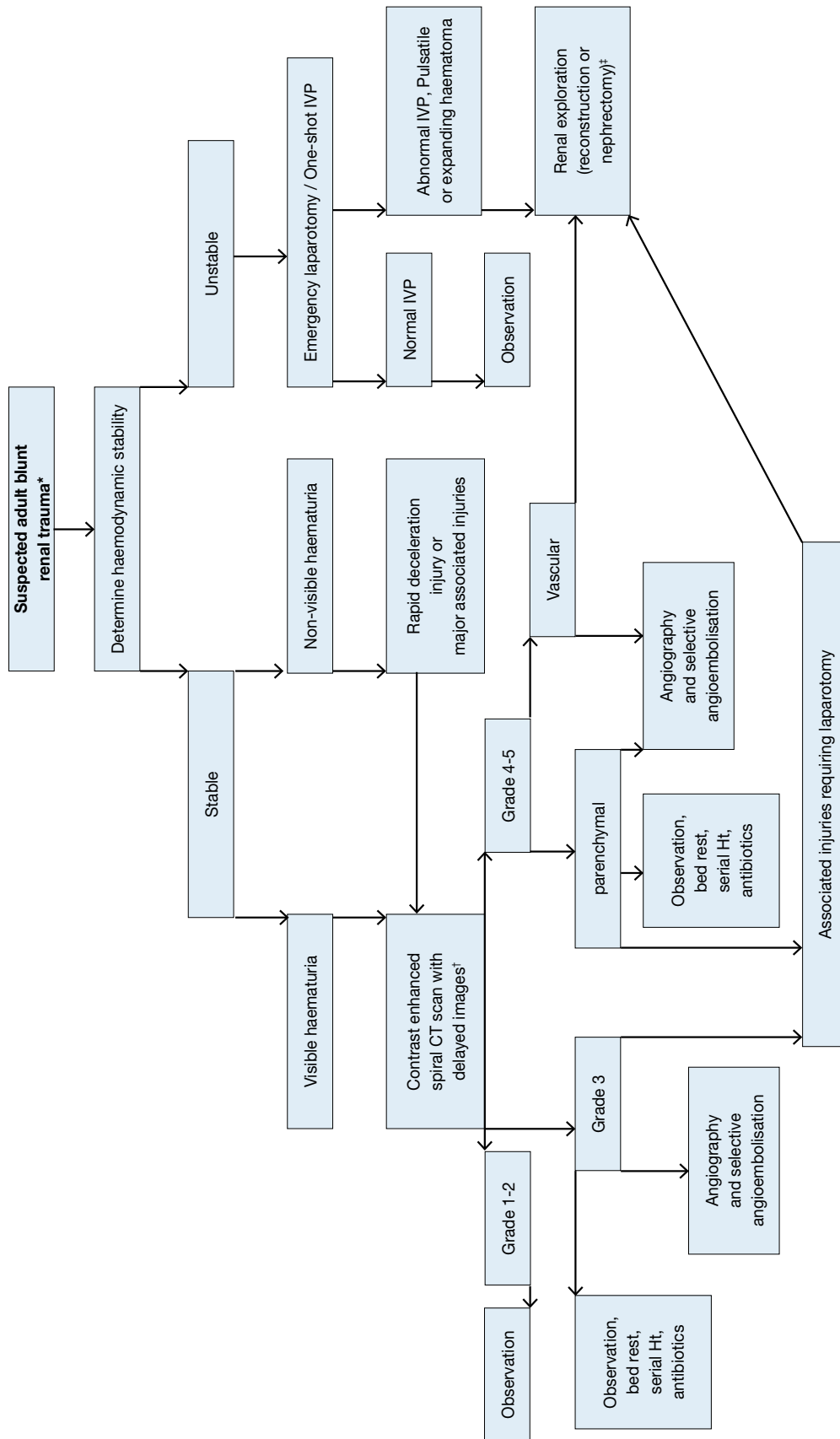
Recommendations	GR
Patients with minor injuries should be treated conservatively.	B
Severe or persistent injuries require intervention with embolisation.	B
In stable patients, a second embolisation should be considered in case of failure.	C

GR = grade; LE = level of evidence.

4.1.7 Algorithms

Figures 4.1.1 and 4.1.2 show the suggested treatment of blunt and penetrating renal injuries in adults.

Figure 4.1.1: Evaluation of blunt renal trauma in adults

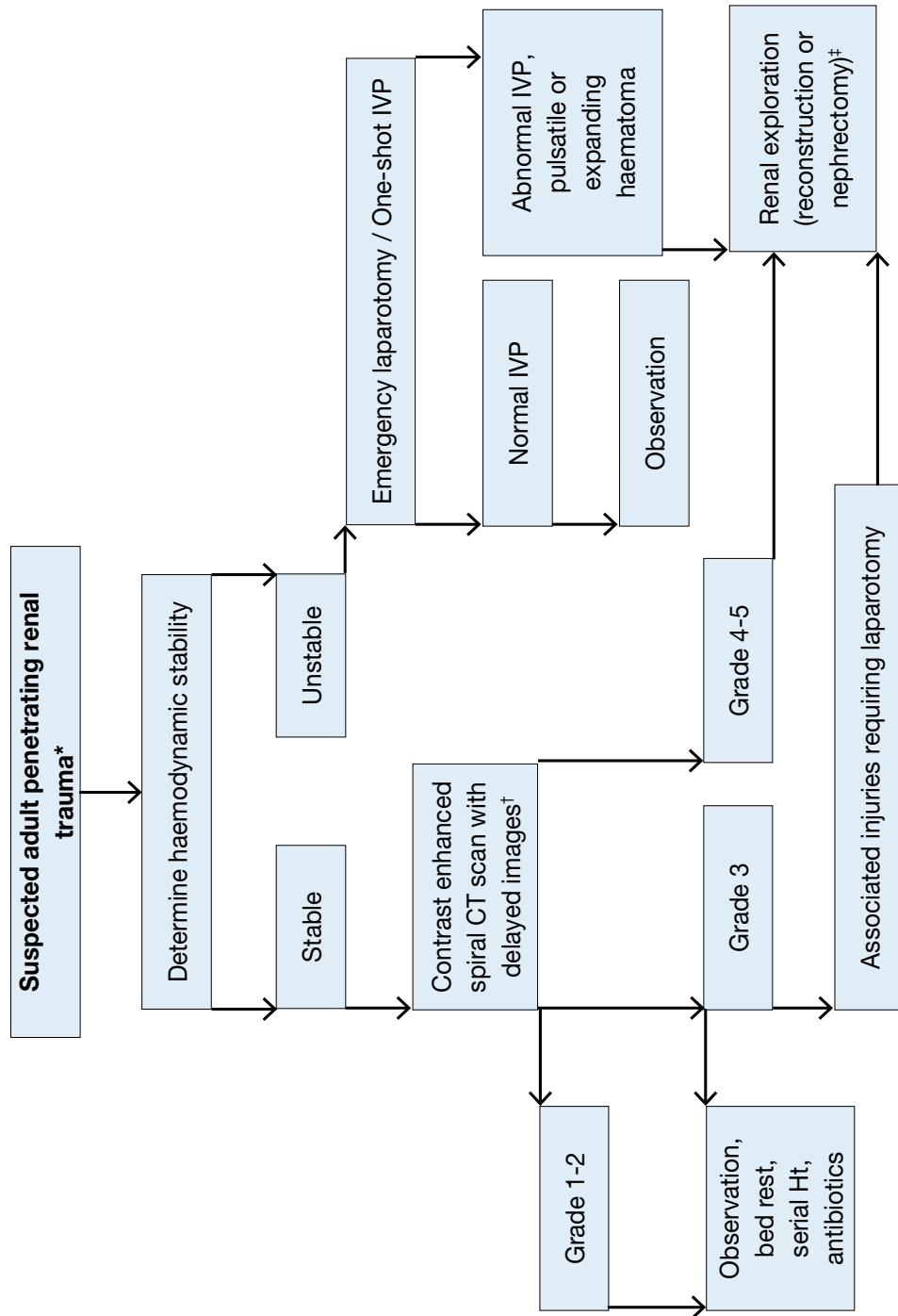


* Suspected renal trauma results from reported mechanism of injury and physical examination.

† Renal imaging: CT scans are the gold standard for evaluating blunt and penetrating renal injuries in stable patients. In settings where CT is not available, the urologist should rely on other imaging modalities (IVP, angiography, radiographic scintigraphy, MRI).

‡ Renal exploration: Although renal salvage is a primary goal for the urologist, decisions concerning the viability of the organ and the type of reconstruction are made during the operation.

Figure 4.1.2: Evaluation of penetrating renal trauma in adults



* Suspected renal trauma results from reported mechanism of injury and physical examination.

† Renal imaging: CT scans are the gold standard for evaluating blunt and penetrating renal injuries in stable patients. In settings where CT is not available, the urologist should rely on other imaging modalities (IVP, angiography, radiographic scintigraphy, MRI).

‡ Renal exploration: Although renal salvage is a primary goal for the urologist, decisions concerning the viability of the organ and the type of reconstruction are made during the operation.

4.2 Ureteral Trauma

4.2.1 Incidence

Trauma to the ureters is relatively rare because they are protected from injury by their small size, mobility, and the adjacent vertebrae, bony pelvis, and muscles. Iatrogenic trauma is the commonest cause of ureteral injury. It is seen in open, laparoscopic or endoscopic surgery and is often missed intraoperatively. Any trauma to the ureter may result in severe sequelae.

4.2.2 **Epidemiology, aetiology, and pathophysiology**

Overall, ureteral trauma accounts for 1-2.5% of urinary tract trauma [13, 151-153], and even higher rates in modern combat injuries [154]. Penetrating external ureteral trauma, mainly caused by gunshot wounds, dominates most of the modern series, both civilian and military [13, 151, 155]. About one-third of cases of external trauma to the ureters are caused by blunt trauma, mostly road traffic injuries [152, 153].

Ureteral injury should be suspected in all cases of penetrating abdominal injury, especially gunshot wounds, because it occurs in 2-3% of cases [151]. It should also be suspected in blunt trauma with deceleration mechanism, when the renal pelvis can be torn away from the ureter [151]. In external ureteral injuries, their distribution along the ureter varies between series, but it is more common in the upper ureter [13, 152, 153].

Iatrogenic ureteral trauma can result from various mechanisms: ligation or kinking with a suture, crushing from a clamp, partial or complete transection, thermal injury, or ischaemia from devascularisation [155-157]. It usually involves damage to the lower ureter [151, 155, 156, 158]. Gynaecological operations are the commonest cause of iatrogenic trauma to the ureters (Table 4.2.1), but it may also occur in colorectal operations, especially abdominoperineal resection and low anterior resection [159]. The incidence of urological iatrogenic trauma has decreased in the last 20 years [155, 160] due to improvements in technique, instruments and surgical experience.

Risk factors for iatrogenic trauma include conditions that alter the normal anatomy, e.g. advanced malignancy, prior surgery or irradiation, diverticulitis, endometriosis, anatomical abnormalities, and major haemorrhage [155, 159, 161]. Occult ureteral injury occurs more often than reported and not all injuries are diagnosed intraoperatively. In gynaecological surgery, if routine intraoperative cystoscopy is used, the detection rate of ureteral trauma is five times higher than usually reported [161, 162].

Table 4.2.1: Incidence of ureteral injury in various procedures

Procedure	Percentage %
Gynaecological [158, 162-164]	
Vaginal hysterectomy	0.02 – 0.5
Abdominal hysterectomy	0.03 – 2.0
Laparoscopic hysterectomy	0.2 – 6.0
Urogynaecological (anti-incontinence/prolapse)	1.7 – 3.0
Colorectal [157, 162, 165]	
Ureteroscopy [160]	
Mucosal abrasion	0.3 – 4.1
Ureteral perforation	0.2 – 2.0
Intussusception/avulsion	0 – 0.3
Radical Prostatectomy [166]	
Open Retropubic	0.05 – 1.6
Robot-Assisted	0.05 – 0.4

4.2.3 **Diagnosis**

The diagnosis of ureteral trauma is challenging, therefore, a high index of suspicion should be maintained. In penetrating external trauma, it is usually made intraoperatively during laparotomy [167], while it is delayed in most blunt trauma and iatrogenic cases [155, 158, 168].

4.2.3.1 **Clinical diagnosis**

External ureteral trauma usually accompanies severe abdominal and pelvic injuries. Penetrating trauma is usually associated with vascular and intestinal injuries, while blunt trauma is associated with damage to the pelvic bones and lumbosacral spine injuries [152, 153]. Haematuria is an unreliable poor indicator of ureteral injury, as it is present in only 50-75% of patients [151, 155, 169].

Iatrogenic injury may be better noticed during the primary procedure, when intravenous dye (e.g. indigo carmine) is injected to exclude ureteral injury. It is usually noticed later, when it is discovered by subsequent evidence of upper tract obstruction, urinary fistulae formation or sepsis. The following clinical signs are characteristic of delayed diagnosis: flank pain, urinary incontinence, vaginal or drain urinary leakage, haematuria, fever, uraemia or urinoma. When the diagnosis is missed, the complication rate increases [151, 154, 168]. Early recognition facilitates immediate repair and provides better outcome [164, 170].

4.2.3.2 *Radiological diagnosis*

Extravasation of contrast medium in computerised tomography (CT) is the hallmark sign of ureteral trauma. However, hydronephrosis, ascites, urinoma or mild ureteral dilation are often the only signs. In unclear cases, a retrograde or antegrade urography is the gold standard for confirmation [155]. Intravenous pyelography, especially one-shot IVP, is unreliable in diagnosis, as it is negative in up to 60% of patients [151, 155].

4.2.4 **Prevention of iatrogenic trauma**

The prevention of iatrogenic trauma to the ureters depends upon the visual identification of the ureters and careful intraoperative dissection in their proximity [155-157]. The use of prophylactic preoperative ureteral stent insertion assists in visualisation and palpation and is often used in complicated cases (about 4% in a large cohort [171]). It is probably also advantageous in making it easier to detect ureteral injury [156]; however, it does not decrease the rate of injury [155]. Apart from its evident disadvantages (potential complications and cost), a stent may alter the location of the ureter and diminish its flexibility [156, 165]. Routine prophylactic stenting is generally not cost-effective [156]. Another form of secondary prevention is intraoperative cystoscopy after intravenous dye injection, which can provide confirmation of ureteral patency [158]. Routine cystoscopy has minimal risks and can markedly increase the rate of ureteral injury detection [162].

4.2.5 **Management**

Management of a ureteral trauma depends on many factors concerning the nature, severity and location of the injury. Immediate diagnosis of a ligation injury during an operation can be managed by de-ligation and stent placement. Partial injuries can be repaired immediately with a stent or urine diversion by a nephrostomy tube. Stenting is helpful because it provides canalisation and may decrease the risk of stricture [155]. On the other hand, its insertion has to be weighed against potentially aggravating the severity of the ureteral injury. Immediate repair of ureteral injury is usually advisable. However, in cases of unstable trauma patients, a 'damage control' approach is preferred with ligation of the ureter, diversion of the urine (e.g. by a nephrostomy), and a delayed definitive repair [172]. Injuries that are diagnosed late are usually treated first by a nephrostomy tube with or without a stent [155]. Retrograde stenting is often unsuccessful in this setting.

The endourological treatment of small ureteral fistulae and strictures is safe and effective in selected cases [173], but an open surgical repair is often necessary. The basic principles for any surgical repair of a ureteral injury are outlined in Table 4.2.2. Wide debridement is highly recommended for gunshot wound injuries due to the 'blast effect' of the injury.

4.2.5.1 *Proximal and mid-ureteral injury*

Injuries shorter than 2-3 cm can usually be managed by a primary uretero-ureterostomy [151]. When this approach is not feasible, a uretero-calycostomy should be considered. In extensive ureteral loss, a transuretero-ureterostomy is a valid option, where the proximal stump of the ureter is transposed across the midline and anastomosed to the contralateral ureter. The reported stenosis rate is 4% and intervention or revision occur in 10% of cases [174].

4.2.5.2 *Distal ureteral injury*

Distal injuries are best managed by ureteral reimplantation (ureteroneocystostomy) because the primary trauma usually jeopardises the blood supply to the distal ureter. The question of refluxing vs. non-refluxing ureteral reimplantation remains unresolved in the literature. The risk for clinically significant reflux should be weighed against the risk for ureteral obstruction.

A psoas hitch between the bladder and the ipsilateral psoas tendon is usually needed to bridge the gap and to protect the anastomosis from tension. The contralateral superior vesical pedicle may be divided to improve bladder mobility. The reported success rate is very high (97%) [174]. In extensive mid-lower ureteral injury, the large gap can be bridged with a tubularised L-shaped bladder flap (Boari flap). It is a time-consuming operation and not usually suitable in the acute setting. The success rate is reported to be 81-88% [175].

4.2.5.3 *Complete ureteral injury*

A longer ureteral injury can be replaced using a segment of the intestines, usually the ileum (ileal interposition graft). This should be avoided in patients with impaired renal function or known intestinal disease. Follow-up should include serum chemistry to diagnose hyperchloremic metabolic acidosis [176]. The long-term complications include anastomotic stricture (3%) and fistulae (6%) [177]. In cases of extensive ureteral loss or after multiple attempts of ureteral repair, the kidney can be relocated to the pelvis (autotransplantation). The renal vessels are anastomosed to the iliac vessels and a ureteral reimplantation is performed [178].

Table 4.2.2: Principles of surgical repair of ureteral injury

<ul style="list-style-type: none"> • Principles of surgical repair of ureteral injury • Debridement of necrotic tissue • Spatulation of ureteral ends • Watertight mucosa-to-mucosa anastomosis with absorbable sutures • Internal stenting • External drain • Isolation of injury with peritoneum or omentum
--

Table 4.2.3: Reconstruction option by site of injury

Site of injury	Reconstruction options
Upper ureter	Uretero-ureterostomy
	Transuretero-ureterostomy
	Uretero-calycostomy
Mid ureter	Uretero-ureterostomy
	Transuretero-ureterostomy
	Ureteral reimplantation and a Boari flap
Lower ureter	Ureteral reimplantation
	Ureteral reimplantation with a psoas hitch
Complete	Ileal interposition graft
	Autotransplantation

4.2.6 Statements and recommendations for ureteral trauma

Statements	LE
Iatrogenic ureteral trauma gives rise to the commonest cause of ureteral injury.	3
Gunshot wounds account for the majority of penetrating ureteral injuries, while motor vehicle accidents account for most of blunt injuries.	3
Ureteral trauma usually accompanies severe abdominal and pelvic injuries.	3
Haematuria is an unreliable poor indicator of ureteral injury.	3
The diagnosis of ureteral trauma is often delayed.	2
Preoperative prophylactic stents do not prevent ureteral injury, but may assist in its detection.	2
Endourological treatment of small ureteral fistulae and strictures is safe and effective.	3
Major ureteral injury requires ureteral reconstruction following temporary urinary diversion.	3

Recommendations	GR
Visual identification of the ureters and meticulous dissection in their vicinity are mandatory to prevent ureteral trauma during abdominal and pelvic surgery.	A*
High level of suspicion for ureteral injury should be maintained in all abdominal penetrating trauma, and in deceleration-type blunt trauma.	A*
Preoperative prophylactic stents do not prevent ureteral injury and therefore it is recommended to be used in selected cases (based on risk factors and surgeon's experience).	B

*Upgraded following panel consensus.

GR= grade of recommendation; LE = level of evidence.

4.3 Bladder Trauma

4.3.1 Classification

A classification of bladder trauma can be made based on mode of action (Table 4.3.1).

Location of the bladder injury is important as it will guide further management:

- Intraperitoneal
- Extraperitoneal
- Combined intra-extraperitoneal

Table 4.3.1: Classification of bladder trauma based on mode of action

Non-iatrogenic trauma
• blunt
• penetrating
Iatrogenic trauma
• external
• internal
• foreign body

4.3.2 Epidemiology, aetiology and pathophysiology**4.3.2.1 Non-iatrogenic trauma**

Motor vehicle traffic collisions are the most common cause of blunt bladder injury, followed by falls, industrial trauma/pelvic crush injuries and blows to the lower abdomen [14, 179, 180]. Between 60-90% of patients with bladder injuries caused by blunt trauma have associated pelvic fractures, and 44% of patients with bladder injuries have at least one other intra-abdominal injury [181]. Pelvic fractures are associated with bladder injuries in only 3.6% of cases [14]. The majority of ruptures are extraperitoneal, followed by intraperitoneal ruptures and combined intra- and extra-peritoneal ruptures [179, 181]. A combination of bladder and urethral injury is present in 4.1-15% of cases [14, 179].

Extraperitoneal ruptures are almost always associated with pelvic fractures [180]. The injury is usually caused by distortion of the pelvic ring, with shearing of the anterolateral bladder wall near the bladder base (at its fascial attachments), or by a 'counter-coup' that bursts opposite the fracture site. Occasionally, the bladder is directly perforated by a sharp bony fragment [179, 182]. The highest risk of bladder injury was found in disruptions of the pelvic circle with displacement > 1 cm, diastasis of the pubic symphysis > 1 cm and fractures of the rami pubis [14, 183]. An isolated acetabular fracture is not likely to be associated with bladder injury [183].

Intraperitoneal ruptures are caused by a sudden rise in intravesical pressure, secondary to a blow to the pelvis or lower abdomen. The bladder dome is the weakest point of the bladder and ruptures will usually occur there [179]. A full bladder is a risk factor for intraperitoneal ruptures [179].

Penetrating injuries, mainly gunshot wounds, are rare in the civilian setting [184].

4.3.2.2 Iatrogenic bladder trauma (IBT)

The bladder is the urological organ that most often suffers iatrogenic injury [185]. Table 4.3.2 shows the incidence of IBT during various procedures.

Table 4.3.2: Incidence of IBT during various procedures

Procedure	Percentage (%)
External	
<i>Obstetrics</i>	
Caesarean delivery [186, 187]	0.0016-0.94
<i>Gynaecology</i>	
Laparoscopic sterilisation [179]	0.02
Diagnostic laparoscopy [179]	0.01
Laparoscopic hysterectomy [188, 189] (benign)	0.5-2.0
Vaginal hysterectomy [188, 189] (benign)	0.44-6.3
Abdominal hysterectomy [188, 189] (benign)	0.73-2.5
<i>General surgery</i>	
Inguinal canal surgery [179, 190]	0.08-0.3
Abdominal cytoreductive surgery [191]	4.5
<i>Urology</i>	
Retropubic male sling [192]	8.0-50
Laparoscopic sacrocolpopexy [193]	1.9
Burch colposuspension [194, 195]	1.0-1.2
Midurethral sling (Transobturator route) [194, 196]	0-2.4
Midurethral sling (Retropubic route) [194, 196]	3.2-8.5
Pubovaginal sling [194]	2.8
Transvaginal mesh surgery [197, 198]	1.5-3.5

Anterior colporrhaphy [198]	0.5
TURB [199, 200]	3.5-58
TURP [179]	0.01

TURB = transurethral resection of the bladder; TURP = transurethral resection of the prostate.

External IBT occurs most often during obstetric and gynaecological procedures, followed by general surgical and urological interventions [185]. Main risk factors are previous surgery, inflammation and malignancy [185].

Internal IBT mainly occurs during transurethral resection of bladder tumour (TURB). Reported risk factors are larger tumours, older age, pretreated bladders (previous TURB, intravesical instillations) and location at the bladder dome [201, 202]. Monopolar TURB at the lateral wall with inadequate muscle relaxation and subsequent risk of stimulation of the obturator nerve, also increases the risk of perforation. Perforations requiring intervention are rare (0.16-0.57%) [201]. Extraperitoneal perforations are more frequent than intraperitoneal perforations [202, 203].

Intravesical foreign bodies include:

- Retained parts of endourologic equipment such as resectoscopes, ureteric stents or bladder catheters;
- Forgotten pieces of surgical gauze, sutures or staples used in pelvic procedures [204, 205];
- An unrecognised perforation or erosion of mesh used for correction of urinary incontinence or pelvic organ prolapse [204].

4.3.3 Diagnostic evaluation

4.3.3.1 General evaluation

The cardinal sign of bladder injury is visible haematuria [179, 180].

Non-iatrogenic bladder injury is strongly correlated with a combination of pelvic fracture and visible haematuria [206], and this combination is an absolute indication for further imaging [179, 206] (LE: 3). However, approximately 5-15% of patients with bladder rupture only have non-visible haematuria [183]. Existing data do not support lower urinary tract imaging in all patients with pelvic fracture or non-visible haematuria alone. In visible haematuria without pelvic fracture, non-visible haematuria with pelvic fracture and isolated non-visible haematuria, the decision for further imaging should be based on the presence of other clinical signs and symptoms and the site of maximal trauma [179]. Clinical signs and symptoms are summarised in Table 4.3.3.

Table 4.3.3: Clinical signs and symptoms of bladder injury

Signs and symptoms	Remarks
Haematuria [179, 180]	Visible = cardinal sign
Inability to void [179, 207]	
Abdominal tenderness [180]	
Suprapubic bruising [179, 207]	
Abdominal distension [179, 207]	In the case of urinary ascites
Swelling of scrotum, perineum, abdominal wall and/or thighs [179]	
Uraemia and elevated creatinine level [179]	Intraperitoneal rupture => reabsorption of urea nitrogen and creatinine
Entrance/exit wounds at lower abdomen, perineum or buttocks [184, 207]	In penetrating injuries

Signs of external IBT are extravasation of urine, visible laceration, clear fluid in the surgical field, appearance of the bladder catheter, and blood and/or gas in the urine bag during laparoscopy [179, 186]. Direct inspection is the most reliable method of assessing bladder integrity [185]. Intravesical instillation of methylene blue may be helpful [186]. If bladder perforation is close to the trigone, the ureteric orifices should be inspected [179, 185].

Internal IBT is suggested by cystoscopic identification of fatty tissue, a dark space between detrusor muscle fibres, or the visualisation of bowel [199]. Signs of major perforation are the inability to distend the bladder, a low return of irrigation fluid, and abdominal distension [208].

An IBT not recognised during surgery is more likely with laparoscopic procedures [185]. Clinical signs and symptoms include haematuria, abdominal pain, abdominal distension, ileus, peritonitis, sepsis, urine leakage from the wound, decreased urinary output, and increased serum creatinine [179, 185].

Symptoms of an intravesical foreign body include dysuria, recurrent urinary tract infection, frequency, urgency, haematuria, and perineal/pelvic pain [204]. Bladder calculi usually develop once the foreign body has been present > 3 months [204, 209].

4.3.3.2 *Supplemental evaluation*

4.3.3.2.1 *Cystography*

Cystography is the preferred diagnostic modality for non-iatrogenic bladder injury and for a suspected IBT in the post-operative setting [182, 185]. Both plain and CT cystography have a comparable sensitivity (90-95%) and specificity (100%) [180, 210]. In addition, CT cystography can diagnose other injuries or causes of abdominal pain [179].

Cystography must be performed using retrograde filling of the bladder with a minimum volume of 350 mL of dilute contrast material [182].

With intraperitoneal extravasation, free contrast medium is visualised in the abdomen, highlighting bowel loops and/or outlining abdominal viscera such as the liver [179, 211]. Extraperitoneal bladder injury is associated with flame-shaped areas of contrast extravasation in the perivesical soft tissues [179].

4.3.3.2.2 *Cystoscopy*

Cystoscopy is the preferred method for detection of intra-operative bladder injuries, as it may directly visualise the laceration. Cystoscopy can localise the lesion in relation to the position of the trigone and ureteral orifices [211]. A lack of bladder distension during cystoscopy suggests a large perforation.

Routine cystoscopy is advised at the end of a hysterectomy and every major gynaecological procedure [189]. Cystoscopy is recommended to detect perforation of the bladder (or urethra) following suburethral sling operations by the retropubic route [195, 212]. Routine cystoscopy after sling insertion through the obturator route is controversial because bladder injuries are rare but not impossible [195, 212]. Cystoscopy after transvaginal mesh procedures is preferable, but not mandatory [213].

Cystoscopy is preferred to diagnose a foreign body [205, 209].

4.3.3.2.3 *Excretory phase of CT or IVP*

Passive bladder filling by clamping the urinary catheter during the excretory phase of CT or IVP is not sufficient to exclude bladder injury [179, 182].

4.3.3.2.4 *Ultrasound*

Demonstration of intraperitoneal fluid or an extraperitoneal collection suggests intraperitoneal or extraperitoneal perforation, respectively. However, ultrasound alone is insufficient in the diagnosis of bladder trauma [179].

4.3.4 ***Disease management***

4.3.4.1 *Conservative management*

Conservative treatment comprises clinical observation, continuous bladder drainage and antibiotics prophylaxis [179, 202]. This is the standard treatment for an uncomplicated extraperitoneal injury due to blunt trauma, after TURB or after other operations in which the injury was not recognised during surgery [179, 202, 207].

It is an option for an uncomplicated intraperitoneal injury after TURB or not recognised during surgery, but only in the absence of peritonitis and ileus [200, 211]. In addition to conservative treatment, placement of an intraperitoneal drain has been advocated, especially when the lesion is larger [208, 214].

4.3.4.2 *Surgical management*

The preferred method is two-layer vesicorrhaphy (mucosa-detrusor) with absorbable sutures [179, 185].

4.3.4.2.1 *Blunt non-iatrogenic trauma*

Although most extraperitoneal ruptures can be treated conservatively, bladder neck involvement, bone fragments in the bladder wall, concomitant rectal injury or entrapment of the bladder wall will necessitate surgical intervention [179, 207] (LE: 3). There is an increasing trend to treat pelvic ring fractures with open stabilisation and internal fixation with osteosynthetic material. During this procedure, an extraperitoneal rupture should be sutured concomitantly in order to reduce the risk of infection [179, 180]. Similarly, during surgical exploration for other injuries, an extraperitoneal rupture should be sutured concomitantly in order to reduce infective complications [180, 181].

Intraperitoneal ruptures should always be managed by formal surgical repair [179, 207] because intraperitoneal urine extravasation can lead to peritonitis, intra-abdominal sepsis and death [181] (LE: 3). Abdominal organs should be inspected for possible associated injuries and urinomas must be drained if detected. In the absence of other intra-abdominal injuries, laparoscopic suturing of the intraperitoneal rupture is possible [180].

4.3.4.2.2 Penetrating non-iatrogenic trauma

This requires emergency exploration, debridement of devitalised bladder muscle and primary bladder repair [184, 207] (LE: 3). A midline exploratory cystotomy is advised to inspect the bladder wall and the distal ureters [179, 184]. In gunshot wounds, there is a strong association with intestinal and rectal injuries, requiring faecal diversion [184]. Most gunshot wounds are associated with two transmural injuries (entry and exit wounds) and the bladder should be carefully checked for those two lesions [184].

4.3.4.2.3 Non-iatrogenic bladder trauma with avulsion of lower abdominal wall or perineum and/or bladder tissue loss

In these cases, direct closure of the traumatised bladder will lead to excessive tension, resulting in ischaemia and eventually breakdown of the repair. A bladder wall substitute is needed to repair the bladder defects and to restore the lower abdominal wall or perineum. A pedicled vastus lateralis myocutaneous flap has been proposed for this [200, 215].

4.3.4.2.4 Iatrogenic bladder trauma

Perforations recognised intra-operatively are primarily closed.

For bladder injuries not recognised during surgery or for internal injuries, a distinction must be made between intraperitoneal and extraperitoneal injuries. For intraperitoneal injuries, the standard of care is surgical exploration with repair [179, 211]. If surgical exploration is performed after TURB, the bowel must be inspected to rule out concomitant injury [201]. For extraperitoneal injuries, exploration is only needed for large perforations complicated by symptomatic extravescical collections. It requires drainage of the collection, with or without closure of the perforation [216].

If bladder perforation is encountered during midurethral sling or transvaginal mesh procedures, sling re-insertion and urethral catheterisation (1-2 days) should be performed [217].

4.3.4.2.5 Intravesical foreign body

For perforated or eroded meshes, the intravesical portion must be removed by open cystotomy or endoscopically [209, 218]. The choice depends on the surgeon's level of experience and the location of the mesh [209, 218]. For other types of foreign bodies, cystoscopic removal is performed and if this fails cystotomy is needed [205].

4.3.5 **Follow-up**

Continuous bladder drainage is required to prevent elevated intravesical pressure and to allow the bladder to heal [185, 219]. Conservatively treated bladder injuries (traumatic or external IBT) are followed by planned cystography scheduled to evaluate bladder healing, with catheter removal in case of absence of contrast extravasation [220]. The first cystography is planned 7-14 days after injury, depending on the extent of the laceration, and should be repeated thereafter in the case of an on-going leakage [220].

After operative repair of a simple injury in a healthy patient, the catheter can be removed after 7-10 days without need for a control cystography [204, 219] (LE: 2a). After repair of a complex injury (trigone involvement, ureteric reimplantation) or in the case of risk factors of wound healing (e.g. use of steroids, malnutrition), control cystography is advised [204, 219].

For conservatively treated internal IBT, a catheter duration of 5 and 7 days for extraperitoneal and intraperitoneal perforations, respectively, has been proposed [187, 188, 202, 203] (LE: 3).

4.3.6 **Statements and recommendations for bladder injury**

Statements	LE
Extraperitoneal bladder perforations are more common than intraperitoneal perforations.	3
The risk of bladder perforation during midurethral sling operations for stress urinary incontinence is lower for the obturator route compared to the retropubic route.	1a
The combination of pelvic fracture and visible haematuria is highly suggestive of bladder injury.	3

Recommendations	GR
Cystography is the preferred diagnostic modality for non-iatrogenic bladder injuries, and in suspected, iatrogenic, post-operative, bladder injuries.	B
Cystography (conventional or CT imaging) is required in the presence of visible haematuria and pelvic fracture.	B
Cystography should be performed with filling of the bladder with at least 350 mL of dilute contrast. Passive bladder filling by clamping the catheter during the excretory phase of CT or IVP is insufficient for diagnosis.	B
Cystoscopy is recommended after suburethral sling operations via the retropubic route and after major gynaecological operations. It is optional after any other type of sling procedure or transvaginal mesh procedure.	B
In the absence of bladder neck involvement and/or associated injuries that require surgical intervention, extraperitoneal bladder ruptures caused by blunt trauma are managed conservatively.	B
Intraperitoneal bladder ruptures by blunt trauma, and any type of bladder injury by penetrating trauma, must be managed by emergency surgical exploration and repair.	B
Conservative management is an option for small, uncomplicated, iatrogenic intraperitoneal bladder perforations.	C

GR= grade of recommendation; LE = level of evidence.

4.4 Urethral Trauma

4.4.1 Epidemiology, aetiology and pathophysiology

4.4.1.1 Iatrogenic urethral trauma

The most common type of urethral trauma seen in urological practice is iatrogenic, due to catheterisation, instrumentation, or surgery [221, 222]. New treatment methods and applied energy sources can also injure the urethra [223].

4.4.1.1.1 Transurethral catheterisation

Iatrogenic urethral trauma usually results from improper or prolonged catheterisation and accounts for 32% of strictures. Most of these strictures affect the bulbar urethra [223, 224], while the bladder neck is rarely affected in such cases [225].

The size and type of catheter used have an important impact on urethral stricture formation. Current data indicate that silicone catheters and small-calibre Foley catheters are associated with less urethral morbidity [226] (see Figure 4.4.3). Implementing training programmes may significantly decrease the incidence of such injuries, increase patients' safety and reduce the negative long-term effects [222, 227].

4.4.1.1.2 Transurethral surgery

Transurethral procedures are a common cause of iatrogenic urethral trauma. Factors that may influence the development of iatrogenic endoscopic urethral strictures include electrical dispersion generated by unipolar current and the diameter of the instruments used [228].

Predisposing factors most strongly associated with stricture formation in patients undergoing TURP are increased prostate volume, prostate cancer and the surgeon's experience [229].

Meatal strictures occur as a result of a mismatch between the size of the instrument and the diameter of the urethral meatus. Bulbar strictures occur due to insufficient insulation by the lubricant, causing the monopolar current to leak. To prevent strictures, lubricant gel should be applied carefully in the urethra.

The lubricant must be reapplied when the resection time is prolonged [230]. Internal urethrotomy must be performed before TURP if there are pre-existing meatal or urethral strictures [230].

There appears to be no relationship with the duration of the procedure or the method used (holmium laser or traditional TURP) on the rate of stricture formation [231].

4.4.1.1.3 Surgical treatment for prostate cancer

Urethral stricture following prostate cancer treatment can occur anywhere from the bladder neck to the urethral meatus. The rate of bladder neck constriction after radical prostatectomy varies with the definition of the stricture used and individual practice [232, 233]. The Cancer of the Prostate Strategic Urologic Research Endeavour (CaPSURE) database shows an incidence of urethral stricture after various forms of prostate cancer therapy of 1.1-8.4%. The risk is greatest after radical prostatectomy if combined with external-beam radiation therapy. In a multivariate analysis, primary treatment type, age, and obesity were found to be significant predictors for stricture development [232].

Robot-assisted prostatectomy also affects urinary function and the risk of iatrogenic trauma. Iatrogenic complications involving the bladder neck account for 2.2%, similar to the stricture rate found with conventional treatment for localised prostate cancer [234].

Anastomotic stricture is a complication in conventional laparoscopic prostatectomy. If prospective studies only are taken into account, there is no significant difference in the anastomotic stricture rates comparing laparoscopic and robot-assisted radical prostatectomy [235].

4.4.1.1.4 Radiotherapy for prostate cancer

The development of urinary fistulae has been reported after brachytherapy and radical prostatectomy, with incidences of 0.3-3.0% and 0-0.6%, respectively, with most fistulae involving the rectum [236, 237]. Brachytherapy is a recognised cause of strictures in patients with localised prostate cancer, as the CaPSURE study has shown [238]. Previous TURP increases the risk of stricture formation [239, 240].

4.4.1.1.5 Major pelvic surgery and cystectomy

Iatrogenic injuries to the urethra can be a complication of major pelvic procedures. Bladder and urethral catheterisation must therefore be carried out preoperatively to prevent these complications [241]. Radical cystectomy and subsequent urinary diversion may also cause urethral trauma [242]. Table 4.4.1 lists the most common causes of urethral trauma.

Table 4.4.1: Most common causes of iatrogenic urethral trauma

Procedure	Percentage
Catheterisation	32% of iatrogenic urethral strictures (52% bulbar urethra)
Urethral instrumentation for therapy and/or diagnosis	
Treatment for prostatic disease	1.1-8.4% urethral stricture rate
Transurethral surgery (e.g. TURB/TURP)	2.2-9.8% urethral stricture rate
Radical prostatectomy	0.5-32% bladder neck constriction; no difference between LRP and RALP (relative risk: 1.42; 95% confidence interval for relative risk, 0.40-5.06; p = 0.59)
Radiotherapy (percutaneous or brachytherapy)	6% urethral stricture rate, 0.3-3.0% urinary fistula rate
The greatest risk for urethral stricture is found in the combination of radical prostatectomy and EBRT	
Cryotherapy	
HIFU	
Treatment for bladder disease	
TURB	
Cystectomy	3.1% subneovesical obstruction, 1.2% neovesicourethral anastomotic strictures, 0.9% urethral strictures
Injury during major abdominal and pelvic operations	

TURB = transurethral resection of the bladder; TURP = transurethral resection of the prostate; LRP = laparoscopic radical prostatectomy; RALP = robot-assisted laparoscopic radical prostatectomy; EBRT = external-beam radiation therapy; HIFU = high-intensity focused ultrasound.

4.4.1.2 Non-iatrogenic urethral injuries

4.4.1.2.1 Anterior urethral injuries (in males)

Different causes of anterior injuries [243] are depicted in Table 4.4.2. Anterior urethral injuries are mainly caused by blunt trauma [243-245], with the bulbar urethra being the most common site injured [245, 246]. In these bulbar injuries, which are mostly 'straddle injuries' or kicks in the perineum, the bulb is compressed against the pubic symphysis, resulting in rupture of the urethra at this site [247].

Penetrating injuries of the penile or bulbar urethra are rare and usually caused by gunshot wounds [247-252]. Depending on the affected segment, penetrating injuries are usually associated with penile, testicular and/or pelvic injuries [249, 252].

Insertion of foreign bodies is another rare cause of anterior injury. It is usually a result of autoerotic stimulation or may be associated with psychiatric disorders [248]. Penile fractures account for 10-20% of anterior injuries [248]. In up to one-third of cases, the tear extends into the corpus spongiosum and urethra [253]. Urethral instrumentation is by far the most common cause of urethral trauma in the Western world and

can affect all segments of the anterior urethra [254, 255].

Table 4.4.2: Aetiology of urethral injury

Cause	Example
Blunt trauma	Vehicular accidents
	Fall astride ('straddle') e.g. on bicycle, fences, inspection covers
	Kicks in the perineum
Sexual intercourse	Penile fractures
	Urethral intraluminal stimulation
Penetrating trauma	Gunshot wounds
	Stab wounds
	Dog bites
	External impalement
	Penile amputations
Constriction bands	Paraplegia
Iatrogenic injuries	Endoscopic instruments
	Urethral catheters/dilators

4.4.1.2.2 Posterior urethral injuries (in males)

Injuries to the posterior urethra are most often related to pelvic fractures (about 72%) [254, 255], which themselves are usually caused by motor vehicle accidents [14, 221, 256]. Iatrogenic posterior injuries, due to irradiation or surgery to the prostate, are an increasing problem [254, 255], but appear to be less common than previously believed (3-25%) [243].

Surgically, these injuries are divided into either partial or complete ruptures. In complete ruptures, there is a gap between the disrupted ends of the urethra. The dismembered ends of the urethra retract and fibrous tissue fills the space between them [221]. There is no urethral wall in the scarred space and any lumen represents merely a fistulous tract between the urethral stumps [221]. Injury to the posterior urethra exclusively occurs in pelvic fractures with disruption of the pelvic ring [14]. The highest risk of urethral injury is in straddle fractures with a concomitant diastasis of the sacroiliac joint, followed by straddle fractures alone, and Malgaigne fractures [257]. Displaced fractures of the inferomedial pubic bone and pubic symphysis diastasis, together with their degree of displacement, are independent predictors of urethral injury [256]. Injuries of the bladder neck and prostate are rare [258] and they mostly occur at the anterior midline of both the bladder neck and prostatic urethra. It is more rare to find a complete transection of the bladder neck or an avulsion of the anterior part of the prostate [258].

Penetrating injuries of the pelvis, perineum or buttocks (mainly gunshot wounds) can also cause damage to the posterior urethra, but are extremely rare [259]. There is a high probability of associated injuries (80-90%), mainly intra-abdominal [184, 259].

Although urethral injuries themselves are not directly life-threatening [14, 243], the association with pelvic fractures and concomitant injuries of the thorax, abdomen and spine, may be life-threatening [14, 256].

Delayed morbidity of posterior urethral injuries includes strictures, incontinence and erectile dysfunction (ED), which may all have a detrimental effect on the quality of life [260]. Erectile dysfunction occurs in approximately 45% of patients after traumatic posterior urethral rupture [260, 261]. Strong predictors for ED are diastasis of the pubic symphysis [260-262], lateral displacement of the prostate [260, 263], a long urethral gap (> 2 cm) [260], a bilateral pubic rami fracture and a Malgaigne's fracture [260]. The assessment of sexual function and the definitive treatment (e.g. penile prosthesis) should be performed 2 years after the trauma because of the potential return of potency within that time [260].

4.4.1.3 Urethral injuries in females

Urethral injuries are very rare in females [244, 247]. Pelvic fractures are the main aetiology [244]. The injury is usually a partial longitudinal tear of the anterior wall associated with vaginal laceration [244, 248]. Urethral injuries in females which extend into the bladder neck may disrupt the normal continence mechanism [264].

4.4.2 **Diagnosis in males and females**

4.4.2.1 *Clinical signs*

Blood at the meatus is the cardinal sign of urethral injury [221]. The absence of it, however, does not rule out a urethral injury.

An inability to void (with a palpable distended bladder) is another classic sign and is often

associated with a complete rupture [221]. In addition, haematuria and pain on urination may be present. Urinary extravasation and bleeding may result in scrotal, penile and/or perineal swelling and ecchymosis, depending on the location and extent of the trauma [243, 248]. The presentation of these clinical symptoms may be delayed (> 1 hour) [221].

Rectal examination should always be done to exclude an associated rectal injury (up to 5% of cases) [265, 266] and may reveal a 'high-riding' prostate, which is an unreliable finding [221, 265]. Failure to detect a rectal injury will cause significant morbidity and even mortality [265]. A rectal injury is suggested by blood on the examining finger and/or a palpable laceration [265]. Another sign of urethral injury is difficulty or an inability to pass a urethral catheter [265].

A female urethral injury should be suspected from the combination of a pelvic fracture with blood at the vaginal introitus, vaginal laceration, haematuria, urethrorrhagia, labial swelling and/or urinary retention [244, 247, 248]. Vaginal examination is indicated to assess vaginal lacerations [265].

Symptoms of urethral lesions caused by improper catheterisation or instrumentation are penile and/or perineal pain (100%) and urethral bleeding (86%) [225]. Failure to diagnose accurately and treat urethral injuries may lead to significant long-term sequelae, mostly presenting as strictures [267, 268].

4.4.2.2 Further diagnostic evaluation

4.4.2.2.1 Retrograde urethrography

Retrograde urethrography is the standard diagnostic investigation for the acute evaluation of a male urethral injury [243]. A retrograde urethrography is conducted by injecting 20-30 mL of contrast material while occluding the meatus, with a balloon of a Foley catheter inflated in the fossa navicularis. Films should be taken in a 30°-oblique position, unless this is not possible because of the severity of the pelvic fractures and associated patient discomfort [243, 248]. In an unstable patient, retrograde urethrography should be postponed until the patient has been stabilised [184, 244].

A urethrogram allows for identification of the site of injury and assessment of the extent of any injury [244, 265]. Any extravasation outside the urethra is pathognomonic for urethral injury. However, the distinction between a complete and partial rupture is not always clear [221]. A typical image for incomplete rupture shows extravasation from the urethra which occurs while the bladder is still filling. A complete rupture is suggested by massive extravasation without bladder filling [221].

The following classification of urethral injuries is based on retrograde urethrography (Table 4.4.3) [243]:

Table 4.4.3: Staging of urethral injuries*

Anterior urethra
• Partial disruption
• Complete disruption
Posterior urethra
• Stretched but intact
• Partial disruption
• Complete disruption
• Complex (involves bladder neck/rectum)

*According to the 2004 Consensus Panel on Urethral Trauma [243].

4.4.2.2.2 Ultrasound, CT and MR imaging

In the acute phase, ultrasound (US) scanning is used for guiding the placement of a suprapubic catheter [243]. CT and rarely MRI are useful to evaluate concomitant injuries [243, 248].

4.4.2.2.3 Cystoscopy

Flexible cystoscopy is an option to diagnose (and manage) an acute urethral injury and may distinguish between complete- and incomplete rupture [243]. In addition, it may allow a guidewire to be passed into the bladder for early catheterisation [244, 269]. Flexible cystoscopy is also recommended above retrograde urethrography in suspected penile fracture-associated urethral injury [264, 270, 271]. In females, where the short urethra precludes adequate, radiological visualisation, urethroscopy and vaginoscopy are the diagnostic modalities of choice [243, 244].

4.4.2.3 Summary

Prior to deferred management, the combination of retrograde urethrography and antegrade cystourethrography

is standard [243]. The location and extent of the obliteration is diagnosed [243]. An MRI of the pelvis provides valuable additional information, which can help to determine the most appropriate surgical strategy [243, 263]. If the competence of the bladder neck is not clear upon antegrade cystourethrography, suprapubic cystoscopy is then advised [243].

4.4.3 **Disease Management**

4.4.3.1 *Anterior urethral injuries*

Anterior urethral injuries are usually not associated with other life-threatening injuries [244, 248]. Treatment decisions are based mainly on the type of injury (blunt, penile fracture associated or penetrating).

4.4.3.1.1 Blunt anterior urethral injuries

Blunt anterior urethral injuries are associated with spongiosal contusion, which makes it more difficult to evaluate the limits of urethral debridement in the acute phase. Acute or early urethroplasty is therefore not indicated [243]. The therapeutic options are suprapubic diversion or (a trial of) early endoscopic realignment with transurethral catheterisation [244]. Urinary diversion is maintained for 2 and 3 weeks for partial and complete ruptures, respectively [246].

Satisfactory urethral luminal recanalisation may occur in up to 68% after partial ruptures, but is rare after complete ruptures [246, 272].

4.4.3.1.2 Penile fracture-related anterior urethral injuries

In order to preserve erectile function, penile fractures require early exploration [247, 264, 273, 274]. The strategy consists of closing the tear in the cavernosal tunica albuginea, while the concomitant tear in the urethra is repaired at the same time [273]. In these circumstances, there is no substantial urethral tissue loss [275]. A small laceration can be repaired by simple closure, while a complete rupture requires an anastomotic repair [273, 274].

4.4.3.1.3 Penetrating anterior urethral injuries

Immediate exploration is advised, except when this is precluded by other life-threatening injuries [243]. Devitalised tissues should be debrided, although urethral and spongiosal debridement should be kept to a minimum due to the excellent vascularisation [252, 264]. For small lacerations and stab wounds, simple urethral closure might be sufficient [243]. Defects of up to 2-3 cm in length in the bulbar urethra, and up to 1.5 cm in the penile urethra, can be treated by spatulation of the urethral ends and primary anastomosis [244, 250, 252]. In the case of longer defects or apparent infection (particularly bite wounds), a staged repair with urethral marsupialisation and a suprapubic catheter is needed [250, 252]. Peri- and post-operative antibiotic treatment is also necessary [251].

4.4.3.2 *Posterior urethral injuries*

4.4.3.2.1 Blunt posterior urethral injuries

In posterior injuries, it is important to distinguish between complete and partial ruptures prior to treatment. The timing of the surgical intervention is classified as [243, 244]:

- Immediate: < 48 hours after injury (4.4.3.2.1.1);
- Delayed primary: 2 days to 2 weeks after injury (4.4.3.2.1.2);
- Deferred: > 3 months after injury (4.4.3.2.1.3).

4.4.3.2.1.1 Immediate management

Although urinary diversion is not essential during the first hours after trauma, many prefer to perform an early urinary diversion for three main reasons [221, 244]:

- To monitor urinary output, since this is a valuable sign of the haemodynamic condition and the renal function of the patient;
- To treat symptomatic retention if the patient is still conscious;
- To minimise urinary extravasation and its secondary effects, such as infection and fibrosis.

Insertion of a suprapubic catheter is always a good solution in urgent situations [243, 264]. However, insertion of a suprapubic catheter is not without risk, especially in the unstable trauma patient where the bladder is often displaced by the pelvic haematoma or because of poor bladder filling due to haemodynamic shock or concomitant bladder injury. In these circumstances, an attempt of urethral catheterisation can be carried out by experienced hands. It is extremely unlikely that the gentle passage of a urethral catheter will do any additional damage [221, 244, 248, 254, 255, 275]. If there is any difficulty, a suprapubic catheter should be placed under US guidance and direct vision [221].

4.4.3.2.1.1.1 Partial posterior urethral rupture

Partial tears of the posterior urethra can be managed with a suprapubic or urethral catheter [264]. Urethrography should be performed at 2-weekly intervals until healing has occurred [266, 276]. Injuries may heal without significant scarring or obstruction if managed by diversion alone [264]. A residual or subsequent stricture should be managed with:

- Internal urethrotomy if it is short and non-obliterative;
- Anastomotic urethroplasty, if it is long and dense, as is found with complete obliteration or after failed internal urethrotomy [272, 277].

4.4.3.2.1.1.2 Complete posterior urethral rupture

Acute definitive treatment options include:

- Immediate realignment: apposition of the urethral ends over a catheter (4.4.3.2.1.1.2.1);
- Immediate urethroplasty: suturing of urethral ends (4.4.3.2.1.1.2.2).

4.4.3.2.1.1.2.1 Immediate realignment

The aim of realignment is to correct severe distraction injuries rather than to prevent a stricture [264].

The reported benefits of realignment are:

- A lower stricture rate than with suprapubic catheter placement alone (where stricture formation is almost certain) [272, 277, 278];
- If scarring and subsequent stricture formation occurs, the restoration of urethral continuity is simplified. For short (< 2 cm), non-obliterative strictures, internal urethrotomy can be attempted, with a 50-90% success rate [272, 277, 279]. For longer strictures, or in the case of failure of an internal urethrotomy, urethroplasty is required [277].
- If urethroplasty is required later, it is technically easier when the prostate and urethra are well aligned [280].

Endoscopic realignment is the preferred technique 87-95 [244, 264]. Using a flexible/rigid cystoscope and biplanar fluoroscopy, a guidewire is placed inside the bladder. Over this, a catheter is placed into the bladder. If necessary, two cystoscopes can be used: one retrograde (per urethra) and one antegradely (suprapubic route through the bladder neck) [272, 277, 278]. The duration of catheter stay varies between 4 and 8 weeks among series [265, 272, 277, 278].

It is important to avoid traction on the Foley balloon catheter since it can damage the remaining sphincter mechanism at the bladder neck. Concomitant bladder neck or rectal injuries or presence of bony fragments inside the bladder must be repaired immediately.

The reasons for immediate repair of bladder neck and rectal injury are:

- Unrepaired bladder neck injury risks incontinence and infection of the pelvic fractures;
- Unrepaired rectal injury carries the obvious risk of sepsis and fistula. Early exploration is indicated to evacuate contaminated haematomas and to perform colostomy if necessary.

Immediate endoscopic realignment can also be performed when the patient is on the operating table for other surgery. Early endoscopic realignment (immediate or delayed primary, see below) is also possible in a stable patient without significant concomitant injuries [277, 278].

With modern endoscopic realignment procedures, acceptable complication rates have been reported for stricture formation (14-79%), incontinence (< 5%) and impotence (10-55%) [277, 278].

Differences between series in the rates of incontinence, impotence and re-stricture can be explained by differences in patient selection (severe vs. less severe trauma), a mix of partial and complete ruptures, and differences in follow-up duration. Furthermore, these differences make the comparison with other techniques difficult, especially with urethroplasty [265, 272, 277, 278].

4.4.3.2.1.1.2.2 Immediate urethroplasty

Immediate urethroplasty with suturing of the urethral ends is difficult because of poor visualisation and the inability to assess accurately the degree of urethral disruption, because of extensive swelling and ecchymosis. This might lead to extensive unjustified urethral debridement [244]. Another problem is the risk of uncontrolled bleeding following entry into the pelvic haematoma, which may result in uncontrolled re-bleeding [244]. Because of disturbingly high rates of impotence (56%), incontinence (21%) and strictures (69%) [276], immediate urethroplasty cannot be recommended and should only be done in experienced centres [281, 282].

4.4.3.2.1.1.3 Delayed primary treatment

Delayed treatment options include delayed primary realignment (4.4.3.2.1.2.1) and delayed primary urethroplasty (4.4.3.2.1.2.2).

4.4.3.2.1.1.3.1 Delayed primary realignment

In the absence of indications for immediate exploration, posterior urethral disruption can be managed in a delayed primary fashion. Delayed primary realignment requires the placement of a suprapubic tube at the time of initial injury, with endoscopic realignment performed within 14 days (i.e. before fibrosis begins). At that time, patients are stable and most of the pelvic bleeding has resolved [276, 278]. The aim and proposed benefits of delayed primary realignment are the same as mentioned for immediate realignment. Endoscopic realignment is also the preferred modality.

4.4.3.2.1.1.3.2 Delayed primary urethroplasty

Delayed primary urethroplasty is performed no later than 14 days after the initial injury i.e. before the start of the fibrotic process [283, 284]. If successful, it avoids a long period of suprapubic diversion [283]. It is restricted to stable patients with a short distraction defect, who are able to lie down in the lithotomy position [283]. Considering the limited accumulated experience with this approach, it cannot be generally recommended [283, 285, 286].

Supporters of early versus delayed intervention state that it does not affect the outcome of an eventual subsequent urethroplasty [281, 287]. However, some authors have reported worse outcomes of subsequent urethroplasty after failed initial urethral manipulation (realignment or urethroplasty) [282, 283, 288]. Due to this concern and the excellent results obtained with deferred urethroplasty, early realignment or urethroplasty should only be selectively performed in highly experienced centres [281, 282].

4.4.3.2.1.1.4 Deferred treatment

In the case of a complete rupture, treated with an initial period of 3 months' suprapubic diversion, obliteration of the posterior urethra is almost inevitable [221, 276]. Treatment options for these posterior urethral strictures are deferred urethroplasty (4.4.3.2.1.3.1) and deferred endoscopic optical incision (4.4.3.2.1.3.2).

4.4.3.2.1.1.4.1 Deferred urethroplasty

Deferred urethroplasty is the procedure of choice for the treatment of posterior urethral distraction defects [264]. After 3 months of suprapubic diversion, the pelvic haematoma is nearly always already resolved, the prostate has descended into a more normal position and the scar tissue has stabilised [283] and the patient is clinically stable and able to lie down in the lithotomy position [243, 244].

Most posterior urethral distraction defects are short and can be treated using a perineal anastomotic repair [243, 283]. The key objective of the operation is to achieve a tension-free anastomosis between two healthy urethral ends (i.e. after complete excision of any scar tissue) [264, 283].

After resection of fibrosis and spatulation of both healthy urethral ends, the gap between both ends is bridged by the so-called 'elaborated perineal approach', which is a series of consecutive manoeuvres, first described by Webster and Ramon [289] with reported success rates of 80-98% [290-292].

Most urethral stenoses are short and can be treated by mobilisation of the bulbar urethra, with or without separation of the corpora cavernosa [283]. This is in contrast to the situation in developing countries, where stenoses are more complex, and where additional manoeuvres, such as inferior pubectomy and supracrural rerouting or a combined abdominoperineal approach are needed more often [279, 291].

A number of situations may prevent the use of perineal anastomotic repair, either as an initial or as a salvage therapy. These situations probably represent < 5% of cases (Table 4.4.4) [293, 294].

Table 4.4.4: Circumstances that might preclude successful perineal anastomotic repair, either as an initial or as a salvage therapy [293, 294]

Circumstance	Alternative procedure
Distraction defects longer than 7-8 cm	A tubed interposition flap of penile or perineal skin can be used for reconstruction [295]. This is seldom required and most patients that require flap urethroplasties have previous failed repairs of posterior urethral rupture [264].
Fistulae	These might require a combined abdominoperineal approach to secure adequate closure [291].
Synchronous anterior urethral stricture	The presence of anterior urethral stricture may compromise the blood supply to the bulbar urethra following division of the bulbar arteries. These patients should be treated cautiously.
Urinary incontinence	The distal urethral sphincter mechanism can be defunctionalised by urethral distraction, so that urinary continence is maintained primarily by the proximal bladder neck sphincter. Concomitant bladder neck injury might increase incontinence and should require an abdominoperineal procedure to allow simultaneous bladder neck and urethral reconstruction [243, 264, 291].

Outcome after deferred urethroplasty is excellent with a stricture rate of around 10% [289, 296]. Deferred urethroplasty is unlikely to result in additional ED [283, 296]. Decompression of the erectile nerves after excision of the scar tissue might explain the amelioration of erectile function after urethroplasty [297]. Incontinence is rare with deferred urethroplasty (< 4%) [283] and is usually due to incompetence of the bladder neck [264, 291]. Standard therapy is a deferred urethroplasty at a minimum of 3 months after trauma, using a one-stage perineal approach whenever possible.

4.4.3.2.1.4.2 Deferred endoscopic treatment

Cold knife or laser core-through or cut-to-the light urethrotomy for complete urethral obliteration has been described. The results of this technique are poor [298, 299] and the procedure is therefore not recommended. For short, non-obliterative strictures following realignment or urethroplasty, direct vision urethrotomy can be performed [292] while in other cases, urethroplasty is warranted.

4.4.3.2.2 Penetrating posterior urethral injuries

The management of penetrating posterior urethral injuries is mainly dependent on associated injuries and the clinical condition of the patient [184, 259]. If possible, immediate exploration by the retropubic route and primary repair or realignment can be performed [184, 259, 264]. In the case of rectal injury, a diverting colostomy is necessary [184, 259]. Life-threatening associated injuries often preclude direct urethral repair. In those cases, suprapubic diversion with delayed abdominoperineal urethroplasty is advised [184, 252, 259].

4.4.3.2.2.1 Female urethral injuries

Proximal and mid-urethral disruptions require immediate exploration and primary repair using the retropubic and transvaginal routes, respectively, with primary suturing of the urethral ends. Concomitant vaginal lacerations are repaired transvaginally at the same time [244, 247, 265, 266]. Distal urethral injuries can be managed vaginally by primary suturing and closure of the vaginal laceration [244, 266]. In all of these operations, it is advisable to use a flap (e.g. Martius) to prevent urethrovaginal fistulas [300]. Nevertheless, distal urethral injuries can be left unrepaired and hypospadiac since they do not disrupt the sphincteric mechanism [244, 247, 265, 266].

4.4.3.2.2.1.1 Iatrogenic urethral injuries

Temporary stenting with an indwelling catheter is the conventional treatment option for an acute false passage [301], although its value in minor urethral injuries is unproven. In difficult cases, catheter insertion may be assisted by cystoscopy and guidewire placement [302], and suprapubic catheterisation is an alternative.

Endoscopic management, either with incision or resection, can successfully treat iatrogenic prostatic urethral strictures. Indwelling catheter placement or an open procedure (which is associated with increased morbidity) are alternatives [303].

Urethral lesions following radiotherapy are often more difficult to treat and may require complex reconstructive surgery [236, 237]. Section 4.4.4.1 lists the statements and recommendations regarding the iatrogenic causes of urethral trauma.

4.4.3.3 Treatment algorithms

The following algorithms are suggested for the treatment of anterior and posterior urethral injuries in men (Figures 4.4.1 and 4.4.2).

Figure 4.4.1: Management of anterior urethral injuries in men

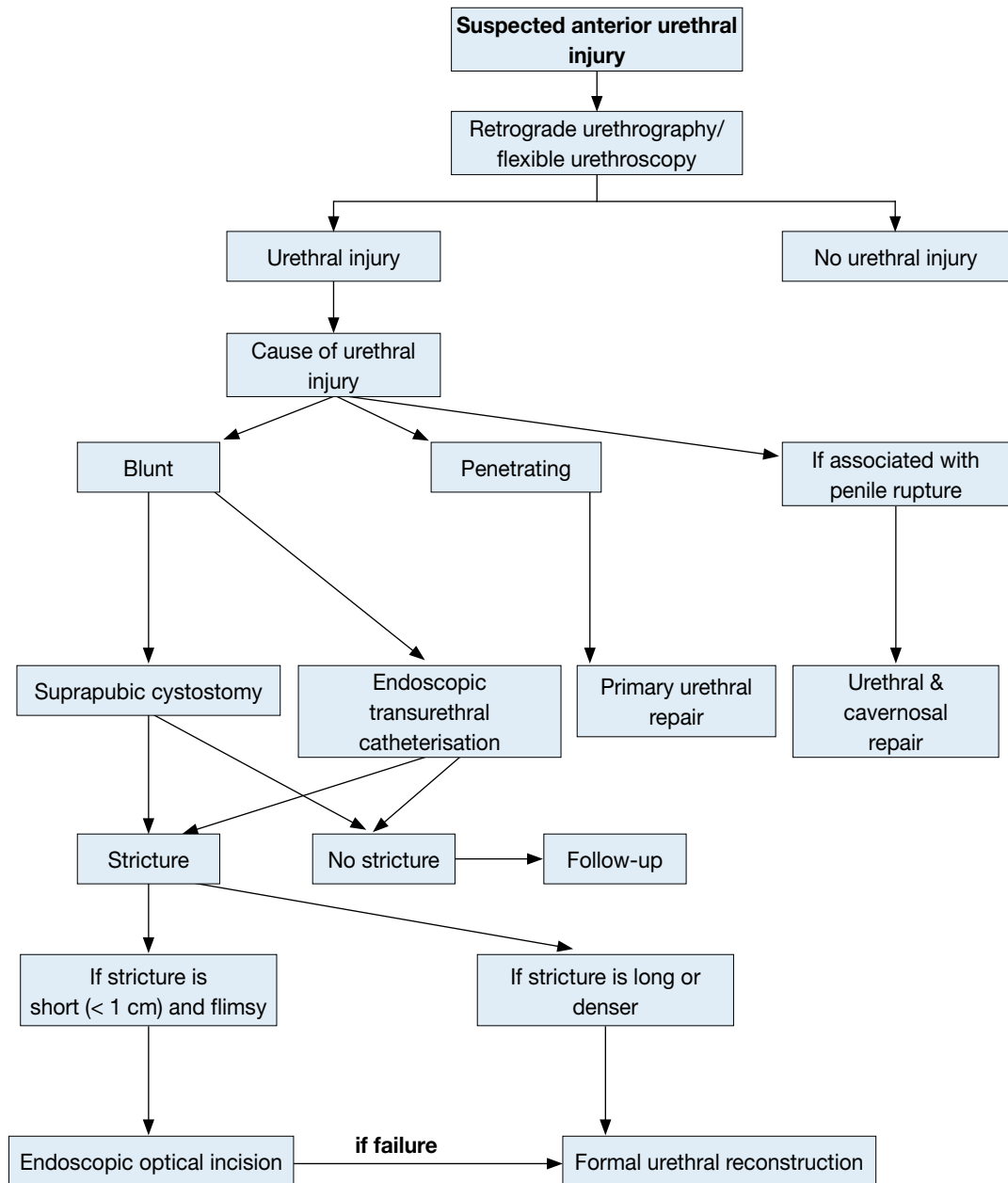


Figure 4.4.2: Management of posterior urethral injuries in men

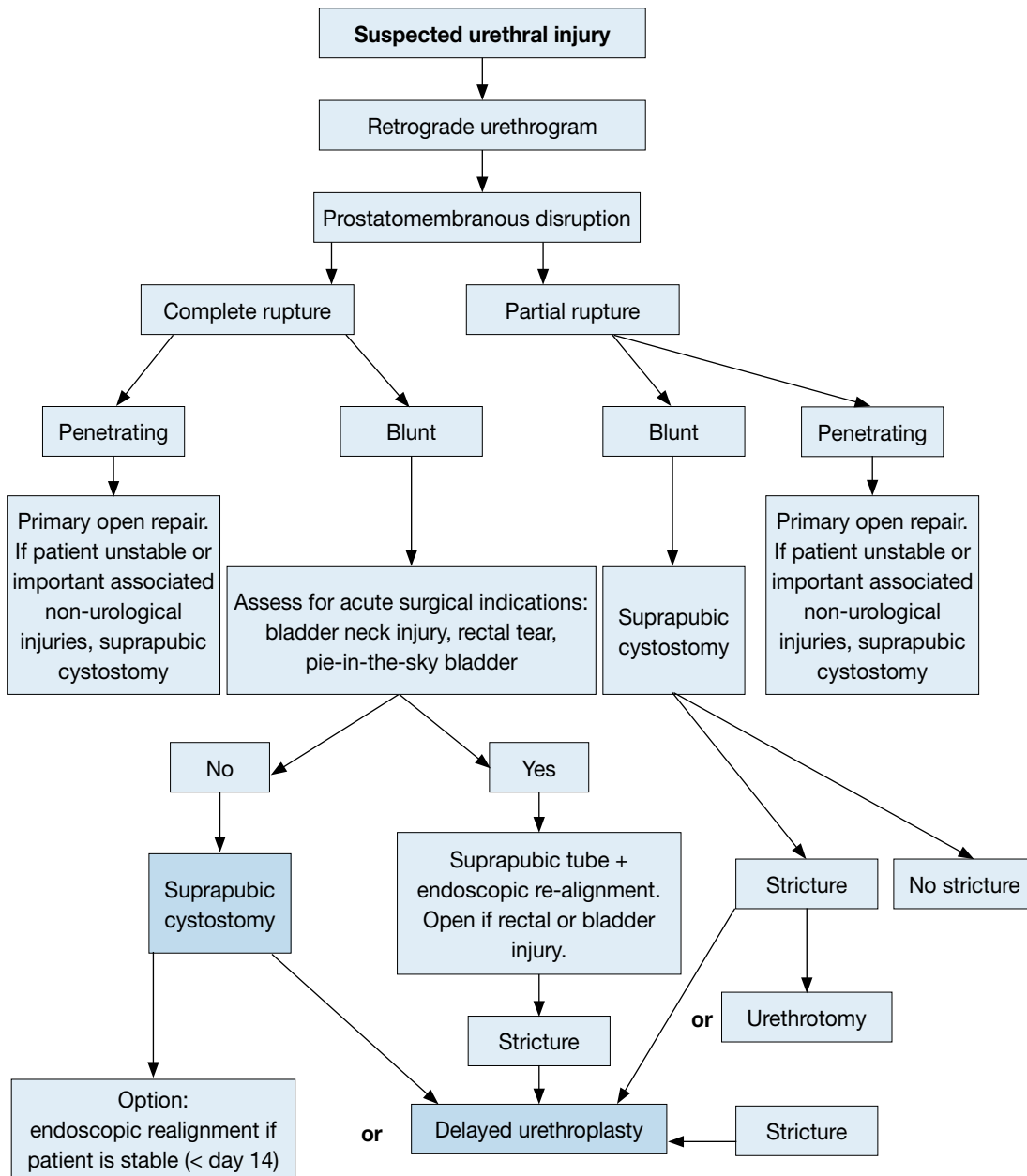


Figure 4.4.3: Treatment of iatrogenic urethral injury caused by improper insertion of a catheter

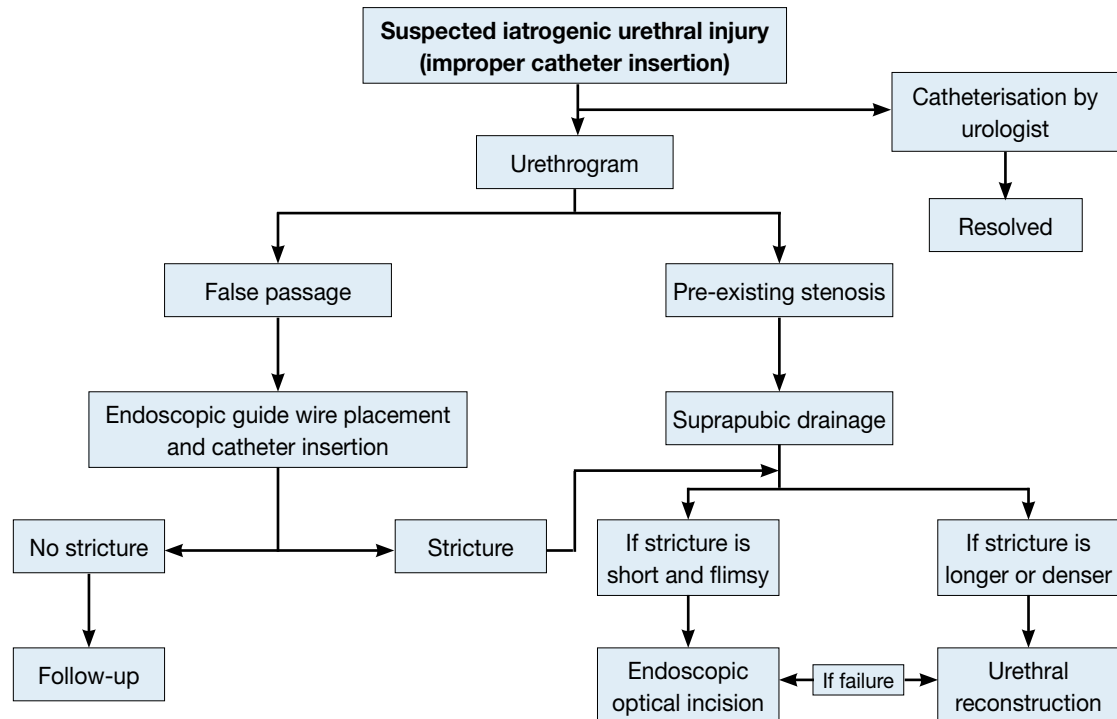
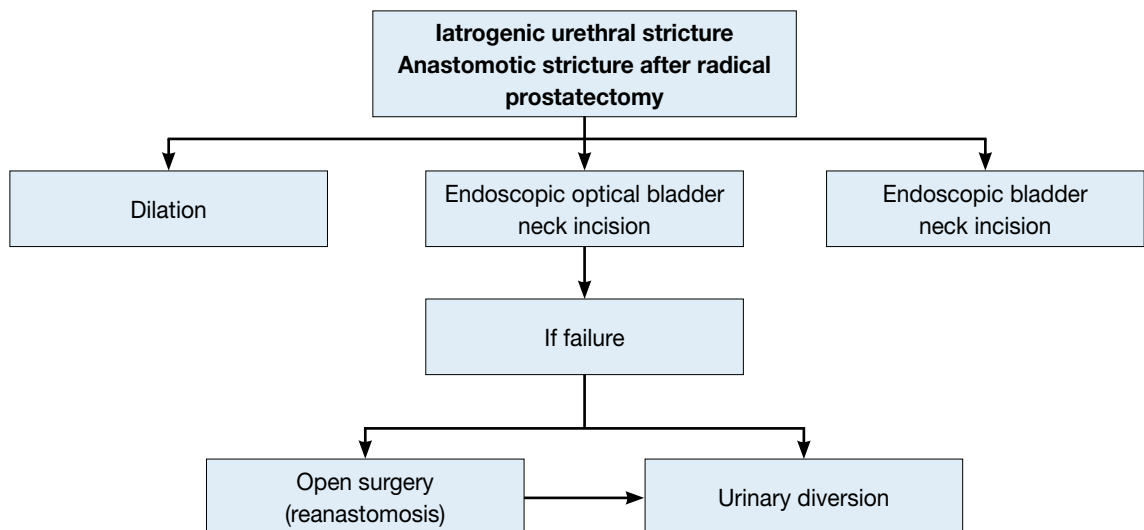


Figure 4.4.4: Treatment for stricture after radical prostatectomy



4.4.4 Statements and recommendation for urethral trauma

Statements	LE
Blunt trauma accounts for more than 90% of urethral injuries.	3
In penile fracture, the urethra is involved in 20% of cases.	4
The male posterior urethra is injured in 4-19% of pelvic fracture cases. In industrialised societies pelvic fracture-related injuries of the posterior urethra are the most common non-iatrogenic injuries.	3
Erectile dysfunction occurs in 20-60% of patients after traumatic urethral rupture.	3

Recommendations	GR
Retrograde urethrography is the gold standard for evaluating urethral injuries.	B
Delayed formal urethroplasty is the procedure of choice for the treatment of posterior urethral distraction defects.	B
Partial posterior urethral ruptures should be treated by urethral or suprapubic catheterisation.	C
Blunt anterior urethral injuries should be treated by suprapubic diversion.	C

GR= grade of recommendation; LE = level of evidence.

4.4.4.1 Statements and recommendations for iatrogenic urethral trauma

Statements	LE
Iatrogenic causes are the most common type of urethral injury in Europe, and therefore the most common cause of urethral stricture formation.	2a
Implementing training programmes on urinary catheter insertion significantly improves the rate of catheter-related complications.	2b
New technologies represent an additional source of urethral injury.	3

Recommendations	GR
Proper training should be provided to reduce the risk of traumatic catheterisation.	A
Urethral instrumentation should only be carried out when there are valid clinical indications.	A
When catheterisation is necessary, its duration should be kept to a minimum.	B

LE= level of evidence; GR = grade of recommendation.

4.5. Genital Trauma

4.5.1 Introduction and background

Genitourinary trauma is seen in both sexes and in all age groups. Of all urological injuries, 33-66% involve the external genitalia [16]. Genital trauma is much more common in males than in females, especially between the ages of 15 and 40 years. This is due to anatomical differences, increased frequency of road traffic accidents and increased participation in physical sports, war and violent crime.

Genital trauma is commonly caused by blunt injuries (80%). The risk of associated injuries to neighbouring organs (bladder, urethra, vagina, rectum and bowel) after blunt trauma is higher in females than in males. In males, blunt genital trauma frequently occurs unilaterally and only approximately 1% present as bilateral scrotal or testicular injuries [304].

Any kind of contact sport, without the use of necessary protective aids, may be associated with genital trauma. Off-road bicycling and motorbike riding (especially on motorbikes with a dominant petrol tank), rugby, football and hockey are all activities which are associated with blunt testicular trauma [305-308].

Penetrating injuries account for 20% of genitourinary trauma, with 40-60% of all penetrating genitourinary lesions involving the external genitalia [249, 309]. Thirty-five per cent of all genitourinary gunshot wounds involve the genitalia [304]. In a recent series of wartime genitourinary injuries, 71.5% of 361 operations involved the external genitalia - the majority caused by improvised explosive devices (IEDs) and other explosive ordinance, while smaller numbers of injuries were due to gunshot injuries [310]. In both males and females, penetrating genital injuries occur with other associated injuries in 70% of patients. In males, penetrating scrotal injuries affect both testes in 30% of cases compared with 1% in blunt scrotal injuries [304, 311].

Self-mutilation of the external genitalia has also been reported in psychotic patients and transsexuals [312]. Genital burns are rare in isolation, usually due to industrial flame or chemicals in adults, and all but the full thickness type are treated conservatively [313]. Both male and female genital piercings increase the risk for unexpected genital trauma [314]. Although there is an increased risk of Hepatitis B and C in genitally injured patients, there is no higher incidence of STDs in patients with genital piercing [314].

4.5.2 General principles and pathophysiology

In genital trauma, a urinalysis should be performed. The presence of visible- and/or non-visible requires a retrograde urethrogram in males. In females, flexible or rigid cystoscopy has been recommended to exclude urethral and bladder injury [315, 316]. In women with genital injuries and blood at the vaginal introitus, further gynaecological investigation is needed to exclude vaginal injuries [316]. The potential for significant injury

should never be discounted in those patients who may also have blood in the vaginal vault from menstruation. Complete vaginal inspection with specula is mandatory.

4.5.2.1 *Gunshot wounds*

In patients with genitalia injured by gunshot wounds, it is very useful to have information about the causative weapon, particularly the range, calibre and type of weapon. High-velocity missiles transmit large amounts of energy to the tissues and can produce trauma to structures outside the wound track. The passage of a missile creates an expansive cavity of sub-atmospheric pressure, which then collapses and creates shear forces and induction of other foreign bodies and (usually) infected material [16].

4.5.2.2 *Bites*

4.5.2.2.1 *Animal bites*

Although animal bites are common, bites injuring the external genital are rare. Wounds are usually minor, but have a risk of wound infection. The most common bacterial infection caused by a dog bite is *Pasturella multocida*, which accounts for up to 50% of infections [317]. Other commonly involved organisms are *Escherichia coli*, *Streptococcus viridans*, *Staphylococcus aureus*, *Eikenella corrodens*, *Capnocytophaga canimorsus*, *Veillonella parvula*, *Bacteroides* and *Fusobacterium spp.* [312, 317, 318].

The first choice of antibiotics is penicillin-amoxiclavulanic acid, followed by doxycycline, cephalosporin or erythromycin for 10-14 days [319-321]. The possibility of rabies infection must be considered. If rabies infection is suspected, vaccination should be considered taking into account the geographical location, animal involved, specific nature of the wound and the type of attack (provoked/unprovoked). Besides vaccination, local wound management is an essential part of post-exposure prophylaxis. High-risk patients should be vaccinated with human rabies immunoglobulin and human diploid cell vaccine [322, 323].

4.5.2.2.2 *Human bites*

Human bites are much less common, but infection should be considered, especially in risk groups. Since transmission of viral diseases may occur, risk assessment should be made. If appropriate, hepatitis B vaccine/immunoglobulin and/or HIV post-exposure prophylaxis should be offered. For further details, see Guidelines for the Management of Human Bite Injuries [324].

4.5.2.3 *Sexual assault*

Genital injury is often seen (42%) after sexual abuse, which must be considered when genital injuries present at any age [325]. In these cases, the examiner should be aware of the extraordinary emotional situation of the patient and the privacy of the patient respected. In suspicious cases, gynaecological and forensic support and advice is necessary. Swabs or vaginal smears should be taken for detection of spermatozoa [326] and local legal protocols followed closely. A thorough history and examination (in some cases under anaesthesia), photo documentation, and identification of forensic material may be important. In a recent report, only 38% of the forensic samples tested positive for an ejaculate and/or sperm. This may be due to delayed presentation or lack of vaginal/anal ejaculation [327, 328].

4.5.3 **Organ-specific genital trauma**

4.5.3.1 *Penile trauma*

4.5.3.1.1 *Blunt penile trauma*

Blunt trauma to the flaccid penis does not usually cause tearing of the tunica. In these cases, only subcutaneous haematoma with intact tunica albuginea may be seen.

4.5.3.1.1.1 *Penile fracture*

The most important and common presentation of blunt penile trauma is penile fracture. This results from trauma to the erect penis during sexual intercourse, masturbation, rolling over in bed (rarely) and as a result of self-inflicted bending to produce detumescence in some Middle Eastern Cultures—a practice known as ‘taqaandan’ (which, when translated, means ‘to click’) [329]. The most common mechanism of injury is when the penis slips out of the vagina and strikes against the symphysis pubis or perineum. Sixty per cent of cases occur during consensual intercourse [330], and is more likely when the partner is on top. Penile fracture is caused by rupture of the cavernosal tunica albuginea, and may be associated with subcutaneous haematoma and lesions of the corpus spongiosum or urethra in 10-22% [331, 332].

The thickness of the tunica albuginea in the flaccid state (approximately 2 mm) decreases in erection to 0.25-0.5 mm, and is therefore more vulnerable to traumatic injury [333, 334]. Penile fracture is associated with a sudden cracking or popping sound, pain and immediate detumescence. Local swelling of the penile shaft

develops quickly, due to enlarging haematoma. Bleeding may spread along the fascial layers of the penile shaft and extend to the lower abdominal wall if Buck's fascia is also ruptured. Sometimes, the rupture of the tunica may be palpable. Less severe penile injuries can be distinguished from penile fracture, as they are not usually associated with detumescence.

A thorough history and examination usually confirm the diagnosis, but in some cases imaging may be useful. Cavernosography, US or MRI [335-337] can identify lacerations of the tunica albuginea in unclear cases [338], or provide reassurance that the tunica is intact. If a concomitant urethral injury is suspected, a retrograde urethrogram (RUG) may be performed, even though flexible cystoscopy under anaesthesia during exploration/repair is more usually employed.

Subcutaneous haematoma, without associated rupture of the cavernosal tunica albuginea, does not require surgical intervention. In these cases, non-steroidal analgesics and ice-packs are recommended [339].

When a penile fracture is diagnosed, surgical intervention with closure of the tunica albuginea is recommended. The approach is usually through a circumferential incision proximal to the coronal sulcus which enables degloving the penis entirely. Increasingly, local longitudinal incisions centred on the area of fracture are currently used and further localisation may be gained with a flexible cystoscopy performed prior to incision, if urethral trauma is suspected and eventually proven.

Closure can be obtained by using absorbable sutures, with good long-term outcome, and protection of potency. Post-operative complications were reported in 9%, including superficial wound infection and impotence in 1.3% [330, 340]. The conservative management of penile fracture is not recommended. It increases complications, such as penile abscess, missed urethral disruption, penile curvature, and persistent haematoma requiring delayed surgical intervention [340]. Late complications after conservative management were fibrosis and angulations in 35%, and impotence in up to 62% [330, 340].

4.5.3.2 Penetrating penile trauma

Penetrating penile trauma is rarely seen in isolation. Most cases are associated with multiple injuries. Non-operative management is recommended in small superficial injuries with intact Buck's fascia [249]. In more significant penetrating penile injuries, surgical exploration and debridement of necrotic tissue is recommended. Even in extended injuries of the penis, primary alignment of the disrupted tissues may allow for acceptable healing because of the robust penile blood supply [312].

The principles of care are debridement of devitalised tissue, with the preservation of as much viable tissues as possible, haemostasis, diversion of urine in selected cases and the removal of foreign bodies. Tissues of questionable viability may be left for subsequent definitive surgery. If a subsequent immediate or delayed repair is needed, depending on the type of injury and the extent of tissue damage, it usually takes place 4-6 weeks after the trauma has occurred.

The surgical approach depends upon the site and extent of the injury, but a subcoronal incision with penile degloving usually gives good exposure. Initially, a defect in the tunica albuginea should be closed after copious irrigation. If there has been too much tissue loss, the defect can be repaired either immediately or after delay with a patch (either from an autologous saphenous vein or xenograft). If a concomitant urethral injury is suspected, a pre- or peri-operative urethrogram or cystoscopy is useful to diagnose any urethral involvement, to define its position, and to decide upon the incision used.

The elasticity of genital skin means it is usually possible to manage the loss of a moderate amount of penile skin. However, management is more difficult in extensive injuries with significant skin loss. The tissue chosen for reconstruction following trauma needs to provide good coverage and must be suitable for reconstruction. Split-thickness skin grafting provides good coverage and a dependable take that is reproducible and durable. However, split-thickness grafts contract more than full-thickness grafts and their use on the penile shaft should be kept to a minimum. In accordance, McAninch et al. recommended the use of skin grafts with thickness of at least 0.015 inch (0.4 mm) in order to reduce the risk of contraction [312]. Full-thickness skin grafting onto the penile shaft gives less contracture, a better cosmetic appearance and more resistance to trauma during intercourse, when eventually re-established [339]. The donor site may be taken from the abdomen, buttock, thigh or axilla and is chosen according to surgeon's preference and the pattern of injury.

In cases of extensive destruction of deeper tissues, or if later prosthetic placement is being considered, skin flaps, with their secure vascular supply can be used.

4.5.3.3 *Penile avulsion injuries and amputation*

Most injuries are self-inflicted, but some are a result of industrial accidents or assault. Acute management involves resuscitation of the patient, who may be compromised from massive blood loss, and preparation for surgical re-implantation of the penis if it has been recovered and is not too badly damaged. Surgical re-implantation should be considered for all patients and should be performed within 24 hours of amputation. If the injury occurred during a psychotic episode, early psychiatric advice and support should be sought.

The severed penis should be washed with sterile saline, wrapped in saline-soaked gauze, placed in a sterile bag and immersed in iced water. The penis must not come into direct contact with the ice. A pressure dressing or a tourniquet should be placed around the penile stump to prevent excessive blood loss. Re-attachment can be achieved in a non-microsurgical way, a technique which probably gives higher rates of post-operative urethral stricture and more problems with loss of sensation [341]. When operating microscopically, the corpora cavernosa and urethra are firstly aligned and repaired. Subsequently, the dorsal penile arteries, the dorsal vein and the dorsal nerves are anastomosed. The cavernosal arteries are generally too small to anastomose. The fascia and skin are closed in layers and both a urethral and a supra-pubic catheter are placed.

If the severed penis cannot be found, or is unsuitable for re-attachment, then the end should be closed as it is done in partial penectomy. Later reconstruction may be employed to lengthen the penis (e.g. suspensory ligament division and V-Y plasty, pseudo-glans formation with split-thickness skin grafting, etc). A delayed major reconstructive procedure, i.e. phalloplasty (either radial artery or pubic), is sometimes required for injuries which leave a very little or non-functioning penile stump.

4.5.4 **Scrotal trauma**

4.5.4.1 *Blunt scrotal trauma*

Blunt trauma to the scrotum can cause testicular dislocation, testicular haematocoele, testicular rupture and/or scrotal haematoma.

4.5.4.1.1 Testicular dislocation

Traumatic dislocation of the testicle occurs rarely. It is most common in victims of MVAs [342-345]. Bilateral dislocation of the testes has been reported in up to 25% of cases [343]. It can be either a subcutaneous dislocation with epifascial displacement of the testis or an internal dislocation. In the latter, the testis is positioned in the superficial external inguinal ring, inguinal canal or abdominal cavity. Traumatic dislocation of the testis is treated by manual replacement and secondary orchidopexy. If primary manual reposition cannot be performed, immediate orchidopexy is indicated.

4.5.4.1.2 Haematocoele

Conservative management is recommended in haematocoeles smaller than three times the size of the contralateral testis [346]. In large haematocoeles, non-operative management often fails, and delayed surgery (> 3 days) is often required. Patients with large haematocoeles have a higher rate of orchiectomy than patients who undergo early surgery, even in non-ruptured testes [304, 312, 347-349]. Early surgical intervention results in preservation of the testis in more than 90% of cases compared to delayed surgeries which result in orchiectomy in 45-55% of patients [349]. In addition, non-operative management is also associated with prolonged hospital stays. Therefore, large haematocoeles should be treated surgically, irrespective of the presence of testicular contusion or rupture. At the very least, the blood clot should be evacuated from the tunica vaginalis sac to relieve disability and hasten recovery. Patients initially treated non-operatively may eventually need delayed surgery if they develop infection or undue pain.

4.5.4.1.3 Testicular rupture

Testicular rupture is found in approximately 50% of cases of direct blunt scrotal trauma [349]. It may occur under intense, traumatic compression of the testis against the inferior pubic ramus or symphysis, resulting in a rupture of the tunica albuginea of the testis. A force of approximately 50 kg is necessary to cause testicular rupture [350]. Testicular rupture is associated with immediate pain, nausea, vomiting, and sometimes fainting.

The hemiscrotum is tender, swollen, and ecchymotic. The testis itself may be difficult to palpate.

High-resolution, real-time US with a high-resolution probe (minimum 7.5 MHz or higher) should be performed to determine intra- and/or extra-testicular haematoma, testicular contusion, or rupture [351-357, 358]. The literature is contradictory as to the usefulness of US compared to clinical examination alone. Some studies have reported convincing findings with a specificity of up to 98.6% [334]. Others reported poor specificity (78%) and sensitivity (28%) for the differentiation between testicular rupture and haematocoele, while accuracy is as low as 56% [352]. Colour Doppler-duplex US may provide useful information when used to evaluate

testicular perfusion. If scrotal US is inconclusive, testicular CT or MRI may be helpful [359]. However, these techniques did not specifically increase the detection rates of testicular rupture. It is therefore essential to surgically explore equivocal patients whenever imaging studies cannot definitively exclude testicular rupture. This involves exploration with evacuation of blood clots and haematoma, excision of any necrotic testicular tubules and closure of the tunica albuginea, usually with running absorbable sutures (e.g. 3/0 Vicryl).

4.5.4.2 Penetrating scrotal trauma

Penetrating injuries to the scrotum require surgical exploration with conservative debridement of non-viable tissue. Depending on the extent of the injury, primary reconstruction of the testis and scrotum can usually be performed. In complete disruption of the spermatic cord, realignment without vaso-vasostomy may be considered if surgically feasible [360]. Staged secondary microsurgical vaso-vasostomy can be performed after rehabilitation, although only a few cases have been reported [360]. If there is extensive destruction of the tunica albuginea, mobilisation of a free tunica vaginalis flap can be performed for testicular closure. If the patient is unstable or reconstruction cannot be achieved, orchiectomy is then indicated.

Prophylactic antibiotics are recommended after scrotal penetrating trauma, although data to support this approach is lacking. Tetanus prophylaxis is mandatory. Post-operative complications were reported in 8% of patients who underwent testicular repair after penetrating trauma [249].

Extended laceration of scrotal skin requires surgical intervention for skin closure. Due to the elasticity of the scrotum, most defects can be primarily closed, even if the lacerated skin is only minimally attached to the scrotum [312]. Local wound management with extensive initial wound debridement and washout is important for scrotal convalescence. In the case of extensive loss of genital tissue, e.g. IED blast injury, complex and staged reconstructive surgical procedures are often required [310].

4.5.5 Genital trauma in females

In females with blunt trauma to the external genitalia, imaging of the pelvis with US, CT, or MRI should be performed since additional injuries and extensive intra-pelvic haematomas are frequently expected [316, 326].

4.5.5.1 Blunt vulvar injuries

Blunt trauma to the vulva is rarely reported and usually presents as a large haematoma. The incidence of traumatic vulvar haematomas after vaginal deliveries has been reported as 1 in 310 deliveries [361]. Although blunt trauma to the female external genitalia is rarely reported, the presence of a vulvar haematoma is closely related to an increased risk of associated vaginal, pelvic or abdominal injuries. Goldman et al. reported that blunt injuries of the vulva and vagina were associated with pelvic trauma in 30%, after consensual intercourse in 25%, sexual assault in 20%, and other blunt trauma in 15% [315].

Blunt vulvar or perineal trauma may be associated with voiding problems and bladder catheterisation is usually required. Vulvar haematomas usually do not require surgical intervention, although they can cause a significant blood loss, which sometimes even requires blood transfusion. Data are scarce [362], but in haemodynamically stable women, non-steroidal anti-inflammatory medication and cold packs are generally successfully used. Yet, in cases of massive vulvar haematoma and haemodynamically unstable patients, surgical intervention with lavage and drainage is sometimes indicated [363].

Although antibiotics are often recommended after major vulvar trauma, there is no data to support this approach. It is important to emphasise that vulvar haematoma and/or blood at the vaginal introitus are indications for vaginal exploration under sedation or general anaesthesia. The aim is to identify possible associated vaginal and/or rectal injuries [316]. Flexible or rigid cystoscopy has been recommended to exclude urethral and bladder injury [315, 316]. In the case of vulvar laceration, suturing after conservative debridement is indicated. If there are associated injuries to the vagina, these can be repaired immediately by primary suturing.

4.5.6 Conclusion and recommendations for genital trauma

Conclusion	LE
Most genital injuries, in males and females, are caused by blunt trauma.	3

Recommendations	GR
In penile fracture, early surgical management, with closure of tunica albuginea, is recommended to enable good long-term outcome and preservation of potency.	B
In testicular trauma, surgical exploration is recommended in all cases of testicular rupture and in those with equivocal imaging.	B

GR= grade of recommendation; LE = level of evidence.

5. POLYTRAUMA, DAMAGE CONTROL AND MASS CASUALTY EVENTS

5.1 Introduction

Urological trauma is often associated with significant and higher priority injuries in the polytraumatised patient [364]. Lessons from civilian trauma networks, the battlefield, and mass casualty events have led to many advances in general trauma care [365, 366]. These include the widespread acceptance of damage control principles, trauma centralisation and recognition of the value of dedicated trauma teams. Urologists need to understand their role in the context of polytrauma with the ultimate aims of improving survivability and decreasing morbidity in these patients.

5.1.1 The development of major trauma centres

Multidisciplinary management of trauma patients has been shown to improve outcomes [367]. Major trauma patients initially managed in local hospitals are 1.5 to 5 times more likely to die than patients transported directly to specialist trauma centres. The reorganisation of care to these centres has been shown to reduce mortality by 25% and length of stay by four days [365]. Major trauma centres, which are expected to provide senior-led resuscitative trauma teams, dedicated trauma theatres, input from all major surgical specialties and interventional radiologists, have therefore been established worldwide. Urologists have an important role to play in this process [368].

5.1.1.1 Recommendations for polytrauma management

	LE	GR
Polytrauma patients are ideally managed in designated major trauma centres.	3	A
Urologists are to be involved in cases of associated urological injury.	4	A

GR= grade of recommendation; LE = level of evidence.

5.2 Damage control

Damage control is a life-saving strategy for severely injured patients that recognises the consequences of the lethal triad of trauma, i.e. hypothermia, coagulopathy and acidosis [369-371].

It is a prioritised three-phase approach:

- The first phase consists of rapid control of haemorrhage and wound contamination.
- The second phase involves resuscitation in the intensive care unit (ICU), with the goal of restoring normal temperature, coagulation, and tissue oxygenation.
- The third stage involves definitive surgery when more time-consuming reconstructive procedures are performed in the stabilised patient [372].

Identifying which patients benefit from the damage control mode requires critical decision-making by the trauma team leader. Prior preparedness and regular communication between the surgical, critical care and anaesthetic teams are vital [373]. Damage control principles have been successfully adopted in the context of civilian mass casualty events, military field surgery, and initial treatment in rural areas with long-range transfers [370, 374].

5.3 Management principles: polytrauma and associated urological injury

Urologists are often asked for advice in polytrauma patients, some of whom might be in a damage control phase of management. Fortunately, the management of urological trauma often involves the use of temporary measures, followed by later definitive surgery, which fits in well with these principles.

In the polytrauma setting, the urologist will usually work alongside the general/trauma surgeon. Procedures

should be directed at the rapid control of bleeding, debridement of dead and devitalised tissue, and minimizing urinary extravasation by simple diversionary measures. Complex reconstructive procedures, including organ preservation, are preferably delayed.

Examples where urological input is required in the polytraumatised patient include:

- Haemodynamically unstable patients with suspected intra-abdominal bleeding, who are transferred urgently to the operating theatre without any pre-operative imaging;
- Stable patients with suspected renal injuries-penetrating trauma to the upper abdomen/flanks/lower chest, or blunt abdominal trauma and visible haematuria;
- Patients with suspected urethral or bladder injury associated with pelvic fractures-blood at the urethral meatus and/or the inability to void;
- External genitalia injury associated with penetrating trauma (intra-abdominal injury).

5.3.1 **Statement and recommendation on management principles**

Statement	LE	GR
Damage control principles govern the management of the severely injured polytrauma patient.	4	
Recommendation		
Urologists are to understand their role in the damage control setting.	4	A

GR= grade of recommendation; LE = level of evidence.

5.4 **Urological injury management in polytrauma**

5.4.1 **Renal injury**

The incidence of multiorgan injury is high in penetrating trauma [29]. Most of these injuries can be managed without surgical exploration [26]. Renal exploration is required to control life-threatening bleeding [375]. The preservation of viable renal parenchyma is a secondary goal, with time-consuming renal reconstruction delayed until the patient is optimised [101].

At laparotomy, it is considered best practice not to explore the injured kidney if there is no active haemorrhage, even if delayed exploration is then necessary [75]. In unstable patients, packing the renal fossa and transferring the patient to the surgical ICU is the option of choice for damage control. A planned second-look laparotomy is then performed [172]. However, in patients with significant ongoing haemorrhage, speedy nephrectomy is required. It is recommended that the contralateral kidney should at least be palpated prior to nephrectomy [376].

In patients who are packed temporarily and who become sufficiently stable in the intensive setting, radiological assessment allows definitive management to begin. Computed tomography allows the kidney injury to be graded, documents the presence of a contralateral kidney, and helps to determine whether or not intervention (radiological or surgical) is necessary.

In patients who are haemodynamically unstable after the initial, acute-damage-control, laparotomy, or in patients with deteriorating haemodynamic parameters (indicating ongoing or delayed bleeding), the management options are angiographic embolisation of the bleeding kidney or re-operation. This decision should be made according to:

- The status of the patient;
- The presence of associated injuries (stapled bowel, packed liver or spleen), which may need re-operation irrespective of the renal injury;
- The availability of angioembolisation.

5.4.1.1 **Renal preservation**

Haemostatic techniques, many of which were developed for hepatic surgery and splenic trauma, can be used to control renal parenchymal bleeding. These techniques are not consistent with damage control principles and should only be considered in the rare casualty situation of a solitary kidney or bilateral renal injury.

These techniques are outlined below:

- Mattress sutures through the parenchyma, i.e. Renorrhaphy [172].
- Haemostatic agents, i.e. combined acellular matrix and fibrin sealants [103].
- Absorbable mesh kidney bags to maintain contact between renal parenchymal fragments [96].
- An intra-operative drain is left *in situ* to collect any urine that leaks following organ salvage.

5.4.1.2 Recommendations for the management of renal injury

	LE	GR
Life-threatening bleeding from renal injury is best managed by urgent nephrectomy.	4	B
Renal packing is an acceptable damage control option for haemorrhage.	4	B
Angioembolisation can be used immediately or can be delayed as a very effective haemostatic option.	4	B
Renal preservation is reserved primarily for patients with a solitary kidney.	4	B

GR= grade of recommendation; LE = level of evidence.

5.4.2 Ureteral injury

Ureteral injuries are primarily associated with penetrating intra-abdominal injury; although rapid deceleration injuries can also result in ureteropelvic disruption [155]. A high index of suspicion is required as these injuries are quite commonly missed [377]. The results of immediate ureteral reconstruction are generally satisfactory, but this is time-consuming and may not be appropriate in the polytraumatised patient. Diagnostic procedures, such as on-table IVP or retrograde ureteropyelography, to evaluate ureteral injuries are also not recommended in this setting.

If a ureteral injury is suspected but not clearly identified, a drain should be sited. If urine leaks post-operatively, a nephrostomy should be arranged. If a partial ureteral tear is identified (less than half a circumference) and the ureter is otherwise healthy, a double J-stent may be inserted over a guide wire through the tear, and the tear quickly closed with fine interrupted absorbable stitches.

When complete ureteral injuries are identified, definitive repair should not be performed. Dissection of the ureteral stumps should be avoided as it interferes with the blood supply. Temporary measures to control urine spillage should be performed:

- A single J or 8 French feeding tube is inserted into the ureter;
- The end of the disrupted proximal ureter is secured over the tube, which is exteriorised and secured to the skin.

The distal ureteral stump does not need to be ligated and any unnecessary manipulation should be avoided. Intra-operative placement of a nephrostomy tube is time-consuming and should be avoided [101, 172].

Tying off the injured ureteral segment and inserting a percutaneous nephrostomy post-operatively is a viable alternative [378]. Rarely, in cases with severe associated injuries of the ipsilateral kidney, nephrectomy is required.

5.4.2.1 Recommendations for the management of ureteral injury

	LE	GR
A high index of suspicion for ureteral injury in penetrating abdominal trauma is required.	4	A
Simple 'tube' urinary diversion is recommended if repair is not undertaken.	4	C

GR= grade of recommendation; LE = level of evidence.

5.4.3 Bladder trauma

In the acute polytrauma setting, a bladder injury should be treated with bladder drainage by a suprapubic and/or a urethral catheter. Later, definitive treatment can follow as necessary [179]. Ideally, large intraperitoneal bladder ruptures (often associated with unstable pelvic fractures) should be closed primarily and drained, as this will cope with both haemorrhage control and urinary contamination.

Examples of temporary measures that may be necessary include:

- The placement of externalised ureteral stents to provide external urinary drainage in extensive bladder rupture [172];
- Packing and/or arteriography and selective embolisation in unstable patients with severe bladder haemorrhage [172];
- The placement of a pelvic suction drain for urinary evacuation [172].

5.4.3.1 Recommendations for the management of bladder trauma

	LE	GR
Bladder injuries require urinary drainage by either the suprapubic or urethral route.	4	A
Complex bladder injuries in the setting of polytrauma may require temporary 'damage control' measures.	4	A

GR = grade of recommendation; LE = level of evidence.

5.4.4 Urethral injury

Urethral injury of any kind is not life-threatening, but the associated injuries are often severe. In this situation, wherever the location or extent of injury, drainage through a suprapubic or urethral catheter should be obtained without prior imaging [243].

5.4.4.1 Recommendation for the management of urethral injury

	LE	GR
Urethral injuries require urgent urinary drainage by either the suprapubic or urethral route.	4	A

GR= grade of recommendation; LE = level of evidence.

5.4.5 External genital injury

Traditionally, traumatic injuries of the external genitalia have a low priority and management is often deferred [379]. In the polytraumatised patient, the management of these injuries should be guided by the principles of haemorrhage control, debridement and urinary diversion (via a catheter). Delayed organ conservation is possible, particularly in testicular injury [380].

Temporary damage control measures that might be applicable include:

- Compression dressing of the penis [172];
- Packing of penetrating testicular injuries;
- Tampons for vulvar lacerations.

5.5 Mass casualty events

A mass casualty event is one in which the number of injured people is significantly higher than the number of available healthcare providers [381]. A mass casualty disaster does not therefore necessarily involve a large number of victims, but it is related to the disproportion between the number of victims and the size of the medical team available [382, 383].

There is little published data on the best way in which to handle these events. However, recent developments in both the military and civilian settings have led to greater survivability following major trauma [384]. Triage, communication and preparedness are important components for a successful response.

Potential mass casualty events include:

- Transportation systems accidents, e.g. road traffic, aircraft, shipping, railways;
- Natural disasters, e.g. earthquakes, hurricanes, floods, tsunamis;
- Industry, e.g. chemical spills, factory explosions and fires;
- Civilian terrorism.

5.5.1 Triage

Triage after mass casualty events is difficult and involves difficult moral and ethical considerations. Disaster triage requires differentiation of the few critically injured individuals who can be saved by immediate intervention from the many others with non-life-threatening injuries for whom treatment can be delayed. The ethical dilemmas that arise are primarily caused by having to decide who should be actively treated, or subsequently whether to stop treatment, because of injuries deemed unsurvivable or incompatible with survival in the home environment.

Triage sorts patients into four groups [385, 386]:

1. Patients with life-threatening injuries that require immediate intervention, presenting with airway compromise, breathing failure and/or circulatory compromise from ongoing external haemorrhage.
2. Patients with severe but non-life-threatening injuries, in whom treatment can be acceptably delayed, including those with major fractures, vascular injuries of the limbs and large soft tissue wounds.
3. 'Walking wounded', i.e. casualties with minimal injuries.

4. Patients who are so severely injured that treatment would require allocation of resources and time that would deny timely care to other patients with greater survivability. These patients are given minimal or no treatment, and are re-evaluated when resources become available. There is no absolute definition for this group because triage is individualised, according to the number and severity of casualties related to the available resources. The decision to implement this category is decided when sufficient information of the incident is available and is made at the highest level possible.

Triage should be performed at each stage from the pre-hospital setting to the emergency department and repeated as the clinical situation evolves. Ultimately, the individual in charge is responsible for directing specialty surgical teams, including urologists, and assigning them responsibility for specific patients as dictated by the specific injuries.

5.5.2 **Urological role in the mass casualty setting**

Urological consultations during a mass casualty scenario should follow the principles outlined below:

1. Rule out under-triage by the surgeon in charge, and perform a rapid primary survey of every patient.
2. Avoid unnecessary imaging procedures such as CT scans and retrograde urethrography. These procedures should be performed later, after re-evaluation of the patient, and after mass casualty protocols have been suspended.
3. Treat unstable patients who are to have surgery using damage control principles.
4. Stable patients should be transferred to the surgical ward without imaging procedures. Re-evaluate if there is any change in their haemodynamic status, or when possible as dictated by the constraints of the mass casualty event.
5. 'Minimal acceptable' treatment for all urological injuries should be performed in order to transfer patients to the surgical wards and are outlined above in the Section 5.4 Urological injury management in polytrauma.

5.5.3 **Statements and recommendations for mass casualty events**

Statements	LE
Recent large scale military conflicts have raised the standard of practice for trauma patients.	4
The centralisation of trauma and the establishment of trauma centres results in better outcomes for trauma patients.	3
Urologists have an important role to play in the management of polytrauma patients.	4

Recommendations	GR
Damage control surgery should be employed as the standard approach in the management of unstable trauma patients.	A
Medical teams should be well prepared to deal with polytrauma events.	A
All surgical sub-specialists involved in trauma management should be very familiar with the principles of triage and damage control.	A

GR= grade of recommendation; LE = level of evidence.

6. REFERENCES

1. Martínez-Piñero L, Djakovic N, Plas E, et al. EAU guidelines on urological trauma. *Eur Urol* 2010 May;57(5):791-803.
<http://www.ncbi.nlm.nih.gov/pubmed/20122789>
2. Summerton DJ, Kitrey ND, Lumen N, et al. EAU guidelines on iatrogenic trauma. *Eur Urol* 2012 Oct;62(4):628-39.
<http://www.ncbi.nlm.nih.gov/pubmed/22717550>
3. Lumen N, Kuehhas FE, Djakovic N, et al. Review of the Current Management of Lower Urinary Tract Injuries by the EAU Trauma Guidelines Panel. *Eur Urol* 2015 Jan; pii: S0302-2838(14)01391-8. doi: 10.1016/j.eururo.2014.12.035. [Epub ahead of print].
<http://www.ncbi.nlm.nih.gov/pubmed/25576009>

4. Serafetinides E, Kitrey ND, Djakovic N, et al. A Review of the Current Management of Upper Urinary Tract Injuries by the EAU Trauma Guidelines Panel. *Eur Urol* 2015 Jan; pii: S0302-2838(14)01390-6. doi: 10.1016/j.eururo.2014.12.034. [Epub ahead of print].
<http://www.ncbi.nlm.nih.gov/pubmed/25578621>
5. Soreide K. Epidemiology of major trauma. *Br J Surg* 2009 Jul;96(7):697-8.
<http://www.ncbi.nlm.nih.gov/pubmed/19526611>
6. The trauma epidemic. In: *Major Trauma*. Smith J GI, Porter K, eds. Oxford: Oxford University Press.; 2010. p. 2.
7. Thornley S, Kool B, Marshall RJ, et al. Alcohol intake, marijuana use, and sleep deprivation on the risk of falls occurring at home among young and middle-aged adults: a case-crossover study. *N Z Med J* 2014 Nov;127(1406):32-8.
<http://www.ncbi.nlm.nih.gov/pubmed/25447247>
8. Bergen G, Peterson C, Ederer D, et al. Vital signs: health burden and medical costs of nonfatal injuries to motor vehicle occupants - United States, 2012. *MMWR Morb Mortal Wkly Rep* 2014 Oct 10;63(40):894-900.
<http://www.ncbi.nlm.nih.gov/pubmed/25299606>
9. Baverstock, R, Simons, R, McLoughlin, M. Severe blunt renal trauma: a 7-year retrospective review from a provincial trauma centre. *Can J Urol* 2001 Oct;8(5):1372-6.
<http://www.ncbi.nlm.nih.gov/pubmed/11718633>
10. Meng MV, Brandes SB, McAninch JW. Renal trauma: indications and techniques for surgical exploration. *World J Urol* 1999 Apr;17(2):71-7.
<http://www.ncbi.nlm.nih.gov/pubmed/10367364>
11. Bruce LM, Croce MA, Santaniello JM, et al. Blunt renal artery injury: incidence, diagnosis, and management. *Am Surg* 2001 Jun;67(6):550-4;discussion 555-6.
<http://www.ncbi.nlm.nih.gov/pubmed/11409803>
12. Kuan JK, Kaufman R, Wright JL, et al. Renal injury mechanisms of motor vehicle collisions: analysis of the crash injury research and engineering network data set. *J Urol* 2007 Sep;178(3Pt1):935-40; discussion 940.
<http://www.ncbi.nlm.nih.gov/pubmed/17632156>
13. Pereira BM, Ogilvie MP, Gomez-Rodriguez JC, et al. A review of ureteral injuries after external trauma. *Scand J Trauma Resusc Emerg Med* 2010 Feb;18:6.
<http://www.ncbi.nlm.nih.gov/pubmed/20128905>
14. Bjurlin MA, Fantus RJ, Mellett MM, et al. Genitourinary injuries in pelvic fracture morbidity and mortality using the National Trauma Data Bank. *J Trauma* 2009 Nov;67(5):1033-9.
<http://www.ncbi.nlm.nih.gov/pubmed/19901665>
15. Dixon CM. Diagnosis and acute management of posterior urethral disruptions. In: *Traumatic and reconstructive urology*. McAninch JW (ed), Philadelphia: WB Saunders, 1996, pp. 347-355.
16. Brandes SB, Buckman RF, Chelsky MJ, et al. External genitalia gunshot wounds: a ten-year experience with fifty-six cases. *J Trauma* 1995 Aug;39(2):266-71.
<http://www.ncbi.nlm.nih.gov/pubmed/7674395>
17. Moore EE, Shackford SR, Pachter HL, et al. Organ injury scaling: spleen, liver, and kidney. *J Trauma* 1989 Dec;29(12):1664-6.
<http://www.ncbi.nlm.nih.gov/pubmed/2593197>
18. Wutzler S, Maegele M, Marzi I, et al. Association of preexisting medical conditions with in-hospital mortality in multiple-trauma patients. *J Am Coll Surg* 2009 Jul;209(1):75-81.
<http://www.ncbi.nlm.nih.gov/pubmed/19651066>
19. Shoko T, Shiraishi A, Kaji M, et al. Effect of pre-existing medical conditions on in-hospital mortality: analysis of 20,257 trauma patients in Japan. *J Am Coll Surg* 2010 Sep;211(3):338-46.
<http://www.ncbi.nlm.nih.gov/pubmed/20800190>
20. Cline KJ, Mata JA, Venable DD, et al. Penetrating trauma to the male external genitalia. *J Trauma* 1998 Mar;44(3):492-4.
<http://www.ncbi.nlm.nih.gov/pubmed/9529176>
21. CDC. Tetanus wound management. Available at:
<http://www.cdc.gov/vaccines/pubs/pinkbook/downloads/tetanus.pdf>
22. McAninch JW. Genitourinary trauma. *World J Urol* 1999 Apr;17(2):65.
<http://www.ncbi.nlm.nih.gov/pubmed/10367362>
23. Bjurlin MA, Goble SM, Fantus RJ, et al. Outcomes in geriatric genitourinary trauma. *J Am Coll Surg* 2011 Sep;213(3):415-21.
<http://www.ncbi.nlm.nih.gov/pubmed/21723152>

24. Paparel P, N'Diaye A, Laumon B, et al. The epidemiology of trauma of the genitourinary system after traffic accidents: analysis of a register of over 43,000 victims. *BJU Int* 2006 Feb;97(2):338-41.
<http://www.ncbi.nlm.nih.gov/pubmed/16430642>
25. Hurtuk M, Reed RL 2nd, Esposito TJ, et al. Trauma surgeons practice what they preach. The NTDB story on solid organ injury management. *J Trauma* 2006 Aug;61(2):243-54; discussion 254-5.
<http://www.ncbi.nlm.nih.gov/pubmed/16917435>
26. Santucci RA, Fisher MB. The literature increasingly supports expectant (conservative) management of renal trauma--a systematic review. *J Trauma* 2005 Aug;59(2):493-503.
<http://www.ncbi.nlm.nih.gov/pubmed/16294101>
27. Santucci RA, Wessells H, Bartsch G, et al. Evaluation and management of renal injuries: consensus statement of the renal trauma subcommittee. *BJU Int* 2004 May;93(7):937-54.
<http://www.ncbi.nlm.nih.gov/pubmed/15142141>
28. Sangthong B, Demetriades D, Martin M, et al. Management and hospital outcomes of blunt renal artery injuries: analysis of 517 patients from the National Trauma Data Bank. *J Am Coll Surg* 2006 Nov;203(5):612-7.
<http://www.ncbi.nlm.nih.gov/pubmed/17084321>
29. Kansas BT, Eddy MJ, Mydlo JH, et al. Incidence and management of penetrating renal trauma in patients with multiorgan injury: extended experience at an inner city trauma center. *J Urol* 2004 Oct;172(4Pt1):1355-60.
<http://www.ncbi.nlm.nih.gov/pubmed/15371841>
30. Najibi S, Tannast M, Latini JM. Civilian gunshot wounds to the genitourinary tract: incidence, anatomic distribution, associated injuries, and outcomes. *Urology* 2010 Oct;76(4):977-81; discussion 981.
<http://www.ncbi.nlm.nih.gov/pubmed/20605196>
31. Shariat SF, Roehrborn CG, Karakiewicz PI, et al. Evidence-based validation of the predictive value of the American Association for the Surgery of Trauma kidney injury scale. *J Trauma* 2007 Apr;62(4):933-9.
<http://www.ncbi.nlm.nih.gov/pubmed/17426551>
32. Santucci RA, McAninch JW, Safir M, et al. Validation of the American Association for the Surgery of Trauma organ injury severity scale for the kidney. *J Trauma* 2001 Feb;50(2):195-200.
<http://www.ncbi.nlm.nih.gov/pubmed/11242281>
33. Kuan JK, Kaufman R, Wright JL, et al. Renal injury mechanisms of motor vehicle collisions: analysis of the crash injury research and engineering network data set. *J Urol* 2007 Sep;178(3Pt1):935-40; discussion 940.
<http://www.ncbi.nlm.nih.gov/pubmed/17632156>
34. Dugi DD 3rd, Morey AF, Gupta A, et al. American Association for the Surgery of Trauma grade 4 renal injury substratification into grades 4a (low risk) and 4b (high risk). *J Urol* 2010 Feb;183(2):592-7.
<http://www.ncbi.nlm.nih.gov/pubmed/20018329>
35. Buckley JC, McAninch JW. Revision of current American Association for the Surgery of Trauma Renal Injury grading system. *J Trauma* 2011 Jan;70(1):35-7.
<http://www.ncbi.nlm.nih.gov/pubmed/21217478>
36. Cachecho R, Millham FH, Wedel SK. Management of the trauma patient with pre-existing renal disease. *Crit Care Clin* 1994 Jul;10(3):523-36.
<http://www.ncbi.nlm.nih.gov/pubmed/792273629>
37. Cozar JM, Carcamo P, Hidalgo L, et al. [Management of injury of the solitary kidney]. *Arch Esp Urol [Case Reports]*. 1990 Jan-Feb;43(1):15-8. [Article in Spanish].
<http://www.ncbi.nlm.nih.gov/pubmed/2331159>
38. Sebastià MC, Rodríguez-Dobao M, Quiroga S, et al. Renal trauma in occult ureteropelvic junction obstruction: CT findings. *Eur Radiol* 1999;9(4):611-15.
<http://www.ncbi.nlm.nih.gov/pubmed/10354870>
39. Buchberger W, Penz T, Wicke K, et al. [Diagnosis and staging of blunt kidney trauma. A comparison of urinalysis, i.v. urography, sonography and computed tomography]. *Rofo* 1993 Jun;158(6):507-12. [Article in German]
<http://www.ncbi.nlm.nih.gov/pubmed/8507839>
40. Carroll PR, McAninch JW, Klosterman P, et al. Renovascular trauma: risk assessment, surgical management, and outcome. *J Trauma* 1990 May;30(5):547-52; discussion 53-4.
<http://www.ncbi.nlm.nih.gov/pubmed/2342137>

41. Eastham JA, Wilson TG, Ahlering TE. Radiographic evaluation of adult patients with blunt renal trauma. *J Urol* 1992 Aug;148(2Pt1):266-7.
<http://www.ncbi.nlm.nih.gov/pubmed/1635113>
42. Schmidlin FR, Iselin CE, Naimi A, et al. The higher injury risk of abnormal kidneys in blunt renal trauma. *Scand J Urol Nephrol* 1998 Dec;32(6):388-92.
<http://www.ncbi.nlm.nih.gov/pubmed/9925001>
43. Chandhoke PS, McAninch JW. Detection and significance of microscopic hematuria in patients with blunt renal trauma. *J Urol* 1988 Jul;140(1):16-18.
<http://www.ncbi.nlm.nih.gov/pubmed/3379684>
44. Heyns CF. Renal trauma: indications for imaging and surgical exploration. *BJU Int* 2004 May;93(8):1165-70.
<http://www.ncbi.nlm.nih.gov/pubmed/15142132>
45. Mee SL, McAninch JW. Indications for radiographic assessment in suspected renal trauma. *Urol Clin North Am* 1989 May;16(2):187-92.
<http://www.ncbi.nlm.nih.gov/pubmed/2652848>
46. Gaitini D, Razi NB, Ghersin E, et al. Sonographic evaluation of vascular injuries. *J Ultrasound Med* 2008 Jan;27(1):95-107.
<http://www.ncbi.nlm.nih.gov/pubmed/18096735>
47. Valentino M, Serra C, Zironi G, et al. Blunt abdominal trauma: emergency contrast-enhanced sonography for detection of solid organ injuries. *AJR Am J Roentgenol* 2006 May;186(5):1361-7.
<http://www.ncbi.nlm.nih.gov/pubmed/16632732>
48. Bent C, Iyngkaran T, Power N, et al. Urological injuries following trauma. *Clin Radiol* 2008 Dec;63(12):1361-71.
<http://www.ncbi.nlm.nih.gov/pubmed/18996268>
49. Kawashima A, Sandler CM, Corl FM, et al. Imaging of renal trauma: a comprehensive review. *Radiographics* 2001 May-Jun;21(3):557-74.
<http://www.ncbi.nlm.nih.gov/pubmed/11353106>
50. Morey AF, McAninch JW, Tiller BK, et al. Single shot intraoperative excretory urography for the immediate evaluation of renal trauma. *J Urol* 1999 Apr;161(4):1088-92.
<http://www.ncbi.nlm.nih.gov/pubmed/10081844>
51. Dayal M, Gamanagatti S, Kumar A. Imaging in renal trauma. *World J Radiol* 2013 Aug;5(8):275-84.
<http://www.ncbi.nlm.nih.gov/pubmed/24003353>
52. Shima H, Nosaka S, Hayakawa M, et al. [Diagnostic imaging of renal pedicle injury]. *Nippon Igaku Hoshasen Gakkai Zasshi* 1997 Jan;57(1):5-11. [Article in Japanese]
<http://www.ncbi.nlm.nih.gov/pubmed/9038056>
53. Vasile M, Bellin MF, Hélénon O, et al. Imaging evaluation of renal trauma. *Abdom Imaging* 2000 Jul-Aug;25(4):424-30.
<http://www.ncbi.nlm.nih.gov/pubmed/10926198>
54. Uyeda JW, Anderson SW, Sakai O, et al. CT angiography in trauma. *Radiol Clin North Am* 2010 Mar;48(2):423-38.
<http://www.ncbi.nlm.nih.gov/pubmed/20609881>
55. Brown SL, Hoffman DM, Spirnak JP. Limitations of routine spiral computerized tomography in the evaluation of blunt renal trauma. *J Urol* 1998 Dec;160(6Pt1):1979-81.
<http://www.ncbi.nlm.nih.gov/pubmed/9817304>
56. Ortega SJ, Netto FS, Hamilton P, et al. CT scanning for diagnosing blunt ureteral and ureteropelvic junction injuries. *BMC Urol* 2008 Feb;8:3.
<http://www.ncbi.nlm.nih.gov/pubmed/18257927>
57. Velmahos GC, Constantinou C, Tillou A, et al. Abdominal computed tomographic scan for patients with gunshot wounds to the abdomen selected for nonoperative management. *J Trauma* 2005 Nov;59(5):1155-60; discussion 1160-1.
<http://www.ncbi.nlm.nih.gov/pubmed/16385294>
58. Eurin M, Haddad N, Zappa M, et al. Incidence and predictors of missed injuries in trauma patients in the initial hot report of whole-body CT scan. *Injury* 2012 Jan;43(1):73-7.
<http://www.ncbi.nlm.nih.gov/pubmed/21663908>
59. Ku JH, Jeon YS, Kim ME, et al. Is there a role for magnetic resonance imaging in renal trauma? *Int J Urol* 2001 Jun;8(6):261-7.
<http://www.ncbi.nlm.nih.gov/pubmed/11389740>
60. Leppäniemi A, Lamminen A, Tervahartiala P, et al. MRI and CT in blunt renal trauma: an update. *Semin Ultrasound CT MR* 1997 Apr;18(2):129-35.
<http://www.ncbi.nlm.nih.gov/pubmed/9163832>

61. Schmidlin FR, Rohner S, Hadaya K, et al. [The conservative treatment of major kidney injuries]. *Ann Urol (Paris)* 1997;31(5):246-52. [Article in French]
<http://www.ncbi.nlm.nih.gov/pubmed/9480627>
62. Holmes JF, McGahan JP, Wisner DH. Rate of intra-abdominal injury after a normal abdominal computed tomographic scan in adults with blunt trauma. *Am J Emerg Med* 2012 May;30(4):574-9.
<http://www.ncbi.nlm.nih.gov/pubmed/21641163>
63. Thall EH, Stone NN, Cheng DL, et al. Conservative management of penetrating and blunt Type III renal injuries. *Br J Urol* 1996 Apr;77(4):512-7.
<http://www.ncbi.nlm.nih.gov/pubmed/8777609>
64. Alsikafi NF, McAninch JW, Elliott SP, et al. Nonoperative management outcomes of isolated urinary extravasation following renal lacerations due to external trauma. *J Urol* 2006 Dec;176(6Pt1):2494-7.
<http://www.ncbi.nlm.nih.gov/pubmed/17085140>
65. Buckley JC, McAninch JW. Selective management of isolated and nonisolated grade IV renal injuries. *J Urol* 2006 Dec;176(6Pt1):2498-502; discussion 2502.
<http://www.ncbi.nlm.nih.gov/pubmed/17085141>
66. Santucci RA, McAninch JM. Grade IV renal injuries: evaluation, treatment, and outcome. *World J Surg* 2001 Dec;25(12):1565-72.
<http://www.ncbi.nlm.nih.gov/pubmed/11775193>
67. Altman AL, Haas C, Dinchman KH, et al. Selective nonoperative management of blunt grade 5 renal injury. *J Urol* 2000 Jul;164(1):27-30;discussion 30-1.
<http://www.ncbi.nlm.nih.gov/pubmed/10840417>
68. Moudouni SM, Hadj Slimen M, Manunta A, et al. Management of major blunt renal lacerations: is a nonoperative approach indicated? *Eur Urol* 2001 Oct;40(4):409-14.
<http://www.ncbi.nlm.nih.gov/pubmed/11713395>
69. Husmann DA, Morris JS. Attempted nonoperative management of blunt renal lacerations extending through the corticomedullary junction: the short-term and long-term sequelae. *J Urol* 1990 Apr;143(4): 682-4.
<http://www.ncbi.nlm.nih.gov/pubmed/2313792>
70. Elliott SP, Olweny EO, McAninch JW. Renal arterial injuries: a single center analysis of management strategies and outcomes. *J Urol* 2007 Dec;178(6):2451-5.
<http://www.ncbi.nlm.nih.gov/pubmed/17937955>
71. Jawas A, Abu-Zidan FM. Management algorithm for complete blunt renal artery occlusion in multiple trauma patients: case series. *Int J Surg* 2008 Aug;6(4):317-22.
<http://www.ncbi.nlm.nih.gov/pubmed/18590988>
72. Armenakas NA, Duckett CP, McAninch JW. Indications for nonoperative management of renal stab wounds. *J Urol* 1999 Mar;161(3):768-71.
<http://www.ncbi.nlm.nih.gov/pubmed/10022681>
73. Jansen JO, Inaba K, Resnick S, et al. Selective non-operative management of abdominal gunshot wounds: survey of practise. *Injury* 2013 May;44(5):639-44.
<http://www.ncbi.nlm.nih.gov/pubmed/22341771>
74. Bernath AS, Schutte H, Fernandez RR, et al. Stab wounds of the kidney: conservative management in flank penetration. *J Urol* 1983 Mar;129(3):468-70.
<http://www.ncbi.nlm.nih.gov/pubmed/6834529>
75. Wessells H, McAninch JW, Meyer A, et al. Criteria for nonoperative treatment of significant penetrating renal lacerations. *J Urol* 1997 Jan;157(1):24-7.
<http://www.ncbi.nlm.nih.gov/pubmed/8976207>
76. Velmahos GC, Demetriades D, Cornwell EE 3rd, et al. Selective management of renal gunshot wounds. *Br J Surg* 1998 Aug;85(8):1121-4.
<http://www.ncbi.nlm.nih.gov/pubmed/9718011>
77. Baniel J, Schein M. The management of penetrating trauma to the urinary tract. *J Am Coll Surg* 1994 Apr;178(4):417-25.
<http://www.ncbi.nlm.nih.gov/pubmed/8149045>
78. DuBose J, Inaba K, Teixeira PG, et al. Selective non-operative management of solid organ injury following abdominal gunshot wounds. *Injury* 2007 Sep;38(9):1084-90.
<http://www.ncbi.nlm.nih.gov/pubmed/17544428>
79. Shefler A, Gremitzky A, Vainrib M, et al. [The role of nonoperative management of penetrating renal trauma]. *Harefuah* 2007 May;146(5):345-8, 406-7. [Article in Hebrew]
<http://www.ncbi.nlm.nih.gov/pubmed/17674549>

80. Hope WW, Smith ST, Medieros B, et al. Non-operative management in penetrating abdominal trauma: is it feasible at a Level II trauma center? *J Emerg Med* 2012 Jul;43(1):190-5.
<http://www.ncbi.nlm.nih.gov/pubmed/22051843>
81. Nuss GR, Morey AF, Jenkins AC, et al. Radiographic predictors of need for angiographic embolisation after traumatic renal injury. *J Trauma* 2009 Sep;67(3):578-82; discussion 582.
<http://www.ncbi.nlm.nih.gov/pubmed/19741403>
82. Huber J, Pahernik S, Hallscheidt P, et al. Selective transarterial embolisation for posttraumatic renal hemorrhage: a second try is worthwhile. *J Urol* 2011 May;185(5):1751-5.
<http://www.ncbi.nlm.nih.gov/pubmed/21420122>
83. Hotaling JM, Sorensen MD, Smith TG 3rd, et al. Analysis of diagnostic angiography and angioembolization in the acute management of renal trauma using a national data set. *J Urol* 2011 Apr;185(4):1316-20.
<http://www.ncbi.nlm.nih.gov/pubmed/21334643>
84. Shariat SF, Trinh QD, Morey AF, et al. Development of a highly accurate nomogram for prediction of the need for exploration in patients with renal trauma. *J Trauma* 2008 Jun;64(6):1451-8.
<http://www.ncbi.nlm.nih.gov/pubmed/18545108>
85. Husmann DA, Gilling PJ, Pery MO, et al. Major renal lacerations with a devitalized fragment following blunt abdominal trauma: a comparison between nonoperative (expectant) versus surgical management. *J Urol* 1993 Dec;150(6):1774-7.
<http://www.ncbi.nlm.nih.gov/pubmed/8230501>
86. McAninch JW, Carroll PR, Klosterman PW, et al. Renal reconstruction after injury. *J Urol* 1991 May;145(5):932-7.
<http://www.ncbi.nlm.nih.gov/pubmed/2016804>
87. Hotaling JM, Wang J, Sorensen MD, et al. A national study of trauma level designation and renal trauma outcomes. *J Urol* 2012 Feb;187(2):536-41.
<http://www.ncbi.nlm.nih.gov/pubmed/22177171>
88. Broghammer JA, Fisher MB, Santucci RA. Conservative management of renal trauma: a review. *Urology* 2007 Oct;70(4):623-9.
<http://www.ncbi.nlm.nih.gov/pubmed/17991526>
89. Sartorelli KH, Frumiento C, Rogers FB, et al. Nonoperative management of hepatic, splenic, and renal injuries in adults with multiple injuries. *J Trauma* 2000 Jul;49(1):56-61; discussion 61-2.
<http://www.ncbi.nlm.nih.gov/pubmed/10912858>
90. Toutouzas KG, Karaiskakis M, Kaminski A, et al. Nonoperative management of blunt renal trauma: a prospective study. *Am Surg* 2002 Dec;68(12):1097-103.
<http://www.ncbi.nlm.nih.gov/pubmed/12516817>
91. Hammer CC, Santucci RA. Effect of an institutional policy of nonoperative treatment of grades I to IV renal injuries. *J Urol* 2003 May;169(5):1751-3.
<http://www.ncbi.nlm.nih.gov/pubmed/12686825>
92. Robert M, Drianno N, Muir G, et al. Management of major blunt renal lacerations: surgical or nonoperative approach? *Eur Urol* 1996;30(3):335-9.
<http://www.ncbi.nlm.nih.gov/pubmed/8931966>
93. Nash PA, Bruce JE, McAninch JW. Nephrectomy for traumatic renal injuries. *J Urol* 1995 Mar; 153(3 Pt 1):609-11.
<http://www.ncbi.nlm.nih.gov/pubmed/7861494>
94. Gonzalez RP, Falimirski M, Holevar MR, et al. Surgical management of renal trauma: is vascular control necessary? *J Trauma* 1999 Dec;47(6):1039-42; discussion 1042-4.
<http://www.ncbi.nlm.nih.gov/pubmed/10608530>
95. Atala A, Miller FB, Richardson JD, et al. Preliminary vascular control for renal trauma. *Surg Gynecol Obstet* 1991 May;172(5):386-90.
<http://www.ncbi.nlm.nih.gov/pubmed/2028374>
96. Chaabouni MN, Bittard M. [Application of peri-renal prosthesis (vicryl mesh) in the conservative treatment of multiple ruptured kidney fragments.] *Ann Urol* 1996;30(2):61-3.
<http://www.ncbi.nlm.nih.gov/pubmed/8767808>
97. Master VA, et al. Operative management of renal injuries: parenchymal and vascular. *Urol Clin North Am* 2006 Feb; 33(1):21-31, v-vi.
<http://www.ncbi.nlm.nih.gov/pubmed/16488277>
98. Davis KA, Reed RL 2nd, Santaniello J, et al. Predictors of the need for nephrectomy after renal trauma. *J Trauma* 2006 Jan;60(1):164-9; discussion 169-70.
<http://www.ncbi.nlm.nih.gov/pubmed/16456451>

99. Wright JL, Nathens AB, Rivara FP, et al. Renal and extrarenal predictors of nephrectomy from the national trauma data bank. *J Urol* 2006 Mar;175(3Pt1):970-5; discussion 975.
<http://www.ncbi.nlm.nih.gov/pubmed/16469594>
100. DiGiacomo JC, Rotondo MF, Kauder DR, et al. The role of nephrectomy in the acutely injured. *Arch Surg* 2001 Sep;136(9):1045-9.
<http://www.ncbi.nlm.nih.gov/pubmed/11529828>
101. Brandes SB, McAninch JW. Reconstructive surgery for trauma of the upper urinary tract. *Urol Clin North Am* 1999 Feb;26(1):183-99.
<http://www.ncbi.nlm.nih.gov/pubmed/10086060>
102. McAninch JW, Dixon CM, Carroll PR. [The surgical treatment of renal trauma]. *Vestn Khir Im I I Grek* 1990 Nov;145(11):64-72. [Article in Russian]
<http://www.ncbi.nlm.nih.gov/pubmed/1966179>
103. Shekarriz B, Stoller ML. The use of fibrin sealant in urology. *J Urol* 2002 Mar;167(3):1218-25.
<http://www.ncbi.nlm.nih.gov/pubmed/11832701>
104. Knudson MM, Harrison PB, Hoyt DB, et al. Outcome after major renovascular injuries: a Western trauma association multicenter report. *J Trauma* 2000 Dec;49(6):1116-22.
<http://www.ncbi.nlm.nih.gov/pubmed/11130498>
105. Tillou A, Romero J, Asensio JA, et al. Renal vascular injuries. *Surg Clin North Am* 2001 Dec;81(6):417-30.
<http://www.ncbi.nlm.nih.gov/pubmed/11766183>
106. Blankenship JC, Gavant ML, Cox CE, et al. Importance of delayed imaging for blunt renal trauma. *World J Surg* 2001 Dec;25(12):1561-4.
<http://www.ncbi.nlm.nih.gov/pubmed/11775192>
107. McGuire J, Bultitude MF, Davis P, et al. Predictors of outcome for blunt high grade renal injury treated with conservative intent. *J Urol* 2011 Jan;185(1):187-91.
<http://www.ncbi.nlm.nih.gov/pubmed/21074795>
108. Wessells H, Deirmenjian J, McAninch JW. Preservation of renal function after reconstruction for trauma: quantitative assessment with radionuclide scintigraphy. *J Urol* 1997 May;157(5):1583-6.
<http://www.ncbi.nlm.nih.gov/pubmed/9112481>
109. Tasian GE, Aaronson DS, McAninch JW. Evaluation of renal function after major renal injury: correlation with the American Association for the Surgery of Trauma Injury Scale. *J Urol* 2010 Jan;183(1):196-200.
<http://www.ncbi.nlm.nih.gov/pubmed/19913819>
110. Fiard G, Rambeaud JJ, Descotes JL, et al. Long-term renal function assessment with dimercaptosuccinic acid scintigraphy after conservative treatment of major renal trauma. *J Urol* 2012 Apr;187(4):1306-9.
<http://www.ncbi.nlm.nih.gov/pubmed/22341289>
111. Dunfee BL, Lucey BC, Soto JA. Development of renal scars on CT after abdominal trauma: does grade of injury matter? *AJR Am J Roentgenol* 2008 May;190(5):1174-9.
<http://www.ncbi.nlm.nih.gov/pubmed/18430828>
112. Heyns CF, van Vollenhoven P. Increasing role of angiography and segmental artery embolisation in the management of renal stab wounds. *J Urol* 1992 May;147(5):1231-4.
<http://www.ncbi.nlm.nih.gov/pubmed/1569655>
113. Monstrey SJ, Beerthuisen GI, vander Werken C, et al. Renal trauma and hypertension. *J Trauma* 1989 Jan;29(1):65-70.
<http://www.ncbi.nlm.nih.gov/pubmed/2911106>
114. Lebech A, Strange-Vognsen HH. [Hypertension following blunt kidney injury]. *Ugeskr Laeger* 1990 Apr;152(14):994-7. [Article in Danish]
<http://www.ncbi.nlm.nih.gov/pubmed/2183457>
115. Montgomery RC, Richardson JD, Harty JI. Posttraumatic renovascular hypertension after occult renal injury. *J Trauma* 1998 Jul;45(1):106-10.
<http://www.ncbi.nlm.nih.gov/pubmed/9680021>
116. Haas CA, Reigle MD, Selzman AA, et al. Use of ureteral stents in the management of major renal trauma with urinary extravasation: is there a role? *J Endourol* 1998 Dec;12(6):545-9.
<http://www.ncbi.nlm.nih.gov/pubmed/9895260>
117. Matthews LA, Smith EM, Spirnak JP. Nonoperative treatment of major blunt renal lacerations with urinary extravasation. *J Urol* 1997 Jun;157(6):2056-8.
<http://www.ncbi.nlm.nih.gov/pubmed/9146579>

118. Wang KT, Hou CJ, Hsieh JJ, et al. Late development of renal arteriovenous fistula following gunshot trauma – a case report. *Angiology* 1998 May;49(5):415-18.
<http://www.ncbi.nlm.nih.gov/pubmed/9591535>
119. Salazar GM, Walker TG. Evaluation and management of acute vascular trauma. *Tech Vasc Interv Radiol* 2009 Jun;12(2):102-16.
<http://www.ncbi.nlm.nih.gov/pubmed/19853228>
120. Miller DC, Forauer A, Faerber GJ. Successful angioembolisation of renal artery pseudoaneurysms after blunt abdominal trauma. *Urology* 2002 Mar;59(3):444.
<http://www.ncbi.nlm.nih.gov/pubmed/11880095>
121. Harrington TG, Kandel LB. Renal colic following a gunshot wound to the abdomen: the birdshot calculus. *J Urol* 1997 Apr;157(4):1351-2.
<http://www.ncbi.nlm.nih.gov/pubmed/9120940>
122. Rosen MA, McAninch JW. Management of combined renal and pancreatic trauma. *J Urol* 1994 Jul;152(1):22-5.
<http://www.ncbi.nlm.nih.gov/pubmed/8201670>
123. Wessells H, McAninch JW. Effect of colon injury on the management of simultaneous renal trauma. *J Urol* 1996 Jun;155(6):1852-6.
<http://www.ncbi.nlm.nih.gov/pubmed/8618272>
124. Heye S, Vanbeckevoort D, Blockmans D, et al. Iatrogenic main renal artery injury: treatment by endovascular stent-graft placement. *Cardiovasc Intervent Radiol* 2005 Jan-Feb;28(1):93-4.
<http://www.ncbi.nlm.nih.gov/pubmed/15602634>
125. Maleux G, Messiaen T, Stockx L, et al. Transcatheter embolisation of biopsy-related vascular injuries in renal allografts. Long-term technical, clinical and biochemical results. *Acta Radiol* 2003 Jan;44(1):13-7.
<http://www.ncbi.nlm.nih.gov/pubmed/12630992>
126. Albani JM, Novick AC. Renal artery pseudoaneurysm after partial nephrectomy: three case reports and a literature review. *Urology* 2003 Aug;62(2):227-31.
<http://www.ncbi.nlm.nih.gov/pubmed/12893324>
127. Furness PN, Philpott CM, Chorbadian MT, et al. Protocol biopsy of the stable renal transplant: a multicenter study of methods and complication rates. *Transplantation* 2003 Sep 27;76(6):969-73.
<http://www.ncbi.nlm.nih.gov/pubmed/14508363>
128. Barley FL, Kessel D, Nicholson T, et al. Selective embolisation of large symptomatic iatrogenic renal transplant arteriovenous fistula. *Cardiovasc Intervent Radiol* 2006 Nov-Dec;29(6):1084-7.
<http://www.ncbi.nlm.nih.gov/pubmed/16794894>
129. Takahashi M, Humke U, Girndt M, et al. Early posttransplantation renal allograft perfusion failure due to dissection: diagnosis and interventional treatment. *AJR Am J Roentgenol* 2003 Mar;180(3):759-63.
<http://www.ncbi.nlm.nih.gov/pubmed/12591692>
130. Bellman GC. Complications of endopyelotomy. *J Endourol* 1996 Apr;10(2):177-81.
<http://www.ncbi.nlm.nih.gov/pubmed/8728685>
131. Hinshaw JL, Shadid AM, Nakada SY, et al. Comparison of percutaneous and laparoscopic cryoablation for the treatment of solid renal masses. *AJR Am J Roentgenol* 2008 Oct;191(4):1159-68.
<http://www.ncbi.nlm.nih.gov/pubmed/18806159>
132. Phadke RV, Sawlani V, Rastogi H, et al. Iatrogenic renal vascular injuries and their radiological management. *Clin Radiol* 1997 Feb;52(2):119-23.
<http://www.ncbi.nlm.nih.gov/pubmed/9043045>
133. Cohenpour M, Strauss S, Gottlieb P, et al. Pseudoaneurysm of the renal artery following partial nephrectomy: imaging findings and coil embolisation. *Clin Radiol* 2007 Nov;62(11):1104-9.
<http://www.ncbi.nlm.nih.gov/pubmed/17920871>
134. Loffroy R, Guiu B, Lambert A, et al. Management of post-biopsy renal allograft arteriovenous fistulas with selective arterial embolisation: immediate and long-term outcomes. *Clin Radiol* 2008 Jun;63(6):657-65.
<http://www.ncbi.nlm.nih.gov/pubmed/18455557>
135. Ben Meir D, Lask D, Koren R, et al. Intrarenal foreign body presenting as a solid tumor. *Urology* 2003 May;61(5):1035.
<http://www.ncbi.nlm.nih.gov/pubmed/12736036>
136. Nakada SY, Johnson M. Ureteropelvic junction obstruction. Retrograde endopyelotomy. *Urol Clin North Am* 2000 Nov;27(4):677-84.
<http://www.ncbi.nlm.nih.gov/pubmed/11098766>

137. Jones CD, McGahan JP. Computed tomographic evaluation and guided correction of malpositioned nephrostomy catheters. *Abdom Imaging* 1999 Jul-Aug;24(4):422-5.
<http://www.ncbi.nlm.nih.gov/pubmed/10390572>
138. Silberzweig JE, Tey S, Winston JA, et al. Percutaneous renal biopsy complicated by renal capsular artery pseudoaneurysm. *Am J Kidney Dis* 1998 Mar;31(3):533-5.
<http://www.ncbi.nlm.nih.gov/pubmed/9506693>
139. Gupta M, Bellman GC, Smith AD. Massive hemorrhage from renal vein injury during percutaneous renal surgery: endourological management. *J Urol* 1997 Mar;157(3):795-7.
<http://www.ncbi.nlm.nih.gov/pubmed/9072568>
140. El-Nahas AR, Shokeir AA, El-Assmy AM, et al. Post-percutaneous nephrolithotomy extensive hemorrhage: a study of risk factors. *J Urol* 2007 Feb;177(2):576-9.
<http://www.ncbi.nlm.nih.gov/pubmed/17222636>
141. El-Nahas AR, Shokeir AA, Mohsen T, et al. Functional and morphological effects of postpercutaneous nephrolithotomy superselective renal angiographic embolisation. *Urology* 2008 Mar;71(3):408-12.
<http://www.ncbi.nlm.nih.gov/pubmed/18342174>
142. Ghai B, Dureja GP, Arvind P. Massive intraabdominal extravasation of fluid: a life threatening complication following percutaneous nephrolithotomy. *Int Urol Nephrol* 2003;35(3):315-18.
<http://www.ncbi.nlm.nih.gov/pubmed/15160530>
143. Oderich GS, Panneton JM, Hofer J, et al. Iatrogenic operative injuries of abdominal and pelvic veins: a potentially lethal complication. *J Vasc Surg* 2004 May;39(5):931-6.
<http://www.ncbi.nlm.nih.gov/pubmed/15111840>
144. Taneja M, Tan KT. Renal vascular injuries following nephron-sparing surgery and their endovascular management. *Singapore Med J* 2008 Jan;49(1):63-6.
<http://www.ncbi.nlm.nih.gov/pubmed/18204772>
145. Inci K, Cil B, Yazici S, Peynircioglu B, et al. Renal artery pseudoaneurysm: complication of minimally invasive kidney surgery. *J Endourol* 2010 Jan;24(1):149-54.
<http://www.ncbi.nlm.nih.gov/pubmed/19954351>
146. Perini S, Gordon RL, LaBerge JM, et al. Transcatheter embolisation of biopsy-related vascular injury in the transplant kidney: immediate and long-term outcome. *J Vasc Interv Radiol* 1998 Nov-Dec;9(6):1011-9.
<http://www.ncbi.nlm.nih.gov/pubmed/9840051>
147. Nakatani T, Uchida J, Han YS, et al. Renal allograft arteriovenous fistula and large pseudoaneurysm. *Clin Transplant* 2003 Feb;17(1):9-12.
<http://www.ncbi.nlm.nih.gov/pubmed/12588315>
148. Breyer BN, McAninch JW, Elliott SP, et al. Minimally invasive endovascular techniques to treat acute renal hemorrhage. *J Urol* 2008 Jun;179(6):2248-52; discussion 2253.
<http://www.ncbi.nlm.nih.gov/pubmed/18423679>
149. Wang MQ, Xie CM, Wang ZP, et al. [Treatment of acquired arteriovenous fistulas with interventional minimally invasive techniques]. [Article in Chinese]. *Zhonghua Wai Ke Za Zhi* 2004 Jun;42(11):687-91.
<http://www.ncbi.nlm.nih.gov/pubmed/15329261>
150. Morris CS, Bonnevie GJ, Najarian KE. Nonsurgical treatment of acute iatrogenic renal artery injuries occurring after renal artery angioplasty and stenting. *AJR Am J Roentgenol* 2001 Dec;177(6):1353-7.
<http://www.ncbi.nlm.nih.gov/pubmed/11717082>
151. Elliott SP, McAninch JW. Ureteral injuries: external and iatrogenic. *Urol Clin North Am* 2006 Feb;33(1):55-66.
<http://www.ncbi.nlm.nih.gov/pubmed/16488280>
152. McGeady JB, Breyer BN. Current epidemiology of genitourinary trauma. *Urol Clin North Am* 2013 Aug;40(3):323-34.
<http://www.ncbi.nlm.nih.gov/pubmed/23905930>
153. Siram SM, Gerald SZ, Greene WR, et al. Ureteral trauma: patterns and mechanisms of injury of an uncommon condition. *Am J Surg* 2010 Apr;199(4):566-70.
<http://www.ncbi.nlm.nih.gov/pubmed/20359576>
154. Serkin FB, Soderdahl DW, Hernandez J, et al. Combat urologic trauma in US military overseas contingency operations. *J Trauma* 2010 Jul;69 Suppl 1:S175-8.
<http://www.ncbi.nlm.nih.gov/pubmed/20622614>
155. Brandes S, Coburn M, Armenakas N, et al. Diagnosis and management of ureteric injury: an evidence based analysis. *BJU Int* 2004 Aug;94(3):277-89.
<http://www.ncbi.nlm.nih.gov/pubmed/15291852>

156. Chou MT, Wang CJ, Lien RC. Prophylactic ureteral catheterization in gynecologic surgery: a 12-year randomized trial in a community hospital. *Int Urogynecol J Pelvic Floor Dysfunct* 2009 Jun;20(6):689-93.
<http://www.ncbi.nlm.nih.gov/pubmed/19165412>
157. Delacroix SE Jr, Winters JC. Urinary tract injuries: recognition and management. *Clin Colon Rectal Surg* 2010 Jun;23(2):104-12.
<http://www.ncbi.nlm.nih.gov/pubmed/21629628>
158. Visco AG, Taber KH, Weidner AC, et al. Cost-effectiveness of universal cystoscopy to identify ureteral injury at hysterectomy. *Obstet Gynecol* 2001 May;97(5 Pt 1):685-92.
<http://www.ncbi.nlm.nih.gov/pubmed/11339916>
159. Halabi WJ, Jafari MD, Nguyen VQ, et al. Ureteral injuries in colorectal surgery: an analysis of trends, outcomes, and risk factors over a 10-year period in the United States. *Dis Colon Rectum* 2014 Feb;57(2):179-86.
<http://www.ncbi.nlm.nih.gov/pubmed/24401879>
160. Johnson DB, Pearle MS. Complications of ureteroscopy. *Urol Clin North Am* 2004 Feb;31(1):157-71.
<http://www.ncbi.nlm.nih.gov/pubmed/15040412>
161. Schimpf MO, Gottenger EE, Wagner JR. Universal ureteral stent placement at hysterectomy to identify ureteral injury: a decision analysis. *BJOG* 2008 Aug;115(9):1151-8.
<http://www.ncbi.nlm.nih.gov/pubmed/18518875>
162. Gilmour DT, Das S, Flowerdew G. Rates of urinary tract injury from gynecologic surgery and the role of intraoperative cystoscopy. *Obstet Gynecol* 2006 Jun;107(6):1366-72.
<http://www.ncbi.nlm.nih.gov/pubmed/16738165>
163. De Cicco C, Ret Davalos ML, Van Cleynenbreugel B, et al. Iatrogenic ureteral lesions and repair: a review for gynecologists. *J Minim Invasive Gynecol* 2007 Jul-Aug;14(4):428-35.
<http://www.ncbi.nlm.nih.gov/pubmed/17630159>
164. Wu HH, Yang PY, Yeh GP, et al. The detection of ureteral injuries after hysterectomy. *J Minim Invasive Gynecol* 2006 Sep-Oct;13(5):403-8.
<http://www.ncbi.nlm.nih.gov/pubmed/16962522>
165. Pokala N, Delaney CP, Kiran RP, et al. A randomized controlled trial comparing simultaneous intraoperative vs sequential prophylactic ureteric catheter insertion in re-operative and complicated colorectal surgery. *Int J Colorectal Dis* 2007 Jun;22(6):683-7.
<http://www.ncbi.nlm.nih.gov/pubmed/17031654>
166. Jhaveri JK, Penna FJ, Diaz-Insua M, et al. Ureteral injuries sustained during robot-assisted radical prostatectomy. *J Endourol* 2014 Mar;28(3):318-24.
<http://www.ncbi.nlm.nih.gov/pubmed/24147874>
167. Kunkle DA, Kansas BT, Pathak A, et al. Delayed diagnosis of traumatic ureteral injuries. *J Urol* 2006 Dec;176(6 Pt 1):2503-7.
<http://www.ncbi.nlm.nih.gov/pubmed/17085143>
168. Parpala-Sparman T, Paananen I, Santala M, et al. Increasing numbers of ureteric injuries after the introduction of laparoscopic surgery. *Scand J Urol Nephrol* 2008;42(5):422-7.
<http://www.ncbi.nlm.nih.gov/pubmed/18609278>
169. Medina D, Lavery R, Ross SE, et al. Ureteral trauma: preoperative studies neither predict injury nor prevent missed injuries. *J Am Coll Surg* 1998 Jun;186(6):641-4.
<http://www.ncbi.nlm.nih.gov/pubmed/9632150>
170. Lucarelli G, Ditunno P, Bettocchi C, et al. Delayed relief of ureteral obstruction is implicated in the long-term development of renal damage and arterial hypertension in patients with unilateral ureteral injury. *J Urol* 2013 Mar;189(3):960-5.
<http://www.ncbi.nlm.nih.gov/pubmed/23017525>
171. Speicher PJ, Goldsmith ZG, Nussbaum DP, et al. Ureteral stenting in laparoscopic colorectal surgery. *J Surg Res* 2014 Jul;190(1):98-103.
<http://www.ncbi.nlm.nih.gov/pubmed/24656474>
172. Smith TG, 3rd, Coburn M. Damage control maneuvers for urologic trauma. *Urol Clin North Am* 2013 Aug;40(3):343-50.
<http://www.ncbi.nlm.nih.gov/pubmed/23905932>
173. Koukouras D, Petsas T, Liatsikos E, et al. Percutaneous minimally invasive management of iatrogenic ureteral injuries. *J Endourol* 2010 Dec;24(12):1921-7.
<http://www.ncbi.nlm.nih.gov/pubmed/20964484>
174. Burks FN, Santucci RA. Management of iatrogenic ureteral injury. *Ther Adv Urol* 2014 Jun;6(3):115-24.
<http://www.ncbi.nlm.nih.gov/pubmed/24883109>

175. Wenske S, Olsson CA, Benson MC. Outcomes of distal ureteral reconstruction through reimplantation with psoas hitch, Boari flap, or ureteroneocystostomy for benign or malignant ureteral obstruction or injury. *Urology* 2013 Jul;82(1):231-6.
<http://www.ncbi.nlm.nih.gov/pubmed/23642933>
176. Chung BI, Hamawy KJ, Zinman LN, et al. The use of bowel for ureteral replacement for complex ureteral reconstruction: long-term results. *J Urol* 2006 Jan;175(1):179-83; discussion 183-4.
<http://www.ncbi.nlm.nih.gov/pubmed/16406903>
177. Armatys SA, Mellon MJ, Beck SD, et al. Use of ileum as ureteral replacement in urological reconstruction. *J Urol* 2009 Jan;181(1):177-81.
<http://www.ncbi.nlm.nih.gov/pubmed/19013597>
178. Meng MV, Freise CE, Stoller ML. Expanded experience with laparoscopic nephrectomy and autotransplantation for severe ureteral injury. *J Urol* 2003 Apr;169(4):1363-7.
<http://www.ncbi.nlm.nih.gov/pubmed/12629362>
179. Gomez RG, Ceballos L, Coburn M, et al. Consensus statement on bladder injuries. *BJU Int* 2004 Jul;94(1):27-32.
<http://www.ncbi.nlm.nih.gov/pubmed/15217426>
180. Wirth GJ, Peter R, Poletti PA, et al. Advances in the management of blunt traumatic bladder rupture: experience with 36 cases. *BJU Int* 2010 Nov;106(9):1344-9.
<http://www.ncbi.nlm.nih.gov/pubmed/20438556>
181. Deibert CM, Spencer BA. The association between operative repair of bladder injury and improved survival: results from the National Trauma Data Bank. *J Urol* 2011 Jul;186(1):151-5.
<http://www.ncbi.nlm.nih.gov/pubmed/21575961>
182. Ramchandani P, Buckler PM. Imaging of genitourinary trauma. *AJR Am J Roentgenol* 2009 Jun;192(6):1514-23.
<http://www.ncbi.nlm.nih.gov/pubmed/19457813>
183. Avey G, Blackmore CC, Wessells H, et al. Radiographic and clinical predictors of bladder rupture in blunt trauma patients with pelvic fracture. *Acad Radiol* 2006 May;13(5):573-9.
<http://www.ncbi.nlm.nih.gov/pubmed/16627198>
184. Cinman NM, McAninch JW, Porten SP, et al. Gunshot wounds to the lower urinary tract: a single-institution experience. *J Trauma Acute Care Surg* 2013 74(3):725-30; discussion 730-1.
<http://www.ncbi.nlm.nih.gov/pubmed/23425728>
185. Cordon BH, Fracchia JA, Armenakas NA. Iatrogenic nonendoscopic bladder injuries over 24 years: 127 cases at a single institution. *Urology* 2014 Jul;84(1):222-6.
<http://www.ncbi.nlm.nih.gov/pubmed/24857278>
186. Gungorduk K, Asicioglu O, Celikkol O, et al. Iatrogenic bladder injuries during caesarean delivery: a case control study. *J Obstet Gynaecol* 2010;30(7):667-70.
<http://www.ncbi.nlm.nih.gov/pubmed/20925606>
187. Rahman MS, Gasem T, Al Suleiman SA, et al. Bladder injuries during cesarean section in a University Hospital: a 25-year review. *Arch Gynecol Obstet* 2009 Mar;279(3):349-52.
<http://www.ncbi.nlm.nih.gov/pubmed/18648828>
188. Donnez O, Jadoul P, Squifflet J, et al. A series of 3190 laparoscopic hysterectomies for benign disease from 1990 to 2006: evaluation of complications compared with vaginal and abdominal procedures. *BJOG* 2009 Mar;116(4):492-500.
<http://www.ncbi.nlm.nih.gov/pubmed/19016683>
189. Vakili B, Chesson RR, Kyle BL, et al. The incidence of urinary tract injury during hysterectomy: a prospective analysis based on universal cystoscopy. *Am J Obstet Gynecol* 2005 May;192(5):1599-604.
<http://www.ncbi.nlm.nih.gov/pubmed/15902164>
190. Aloï IP, Lais A, Caione P. Bladder injuries following inguinal canal surgery in infants. *Pediatr Surg Int* 2010 Dec;26(12):1207-10.
<http://www.ncbi.nlm.nih.gov/pubmed/20820790>
191. Honore C, Souadka A, Goéré D, et al. HIPEC for peritoneal carcinomatosis: does an associated urologic procedure increase morbidity? *Ann Surg Oncol* 2012 Jan;19(1):104-9.
<http://www.ncbi.nlm.nih.gov/pubmed/21638092>
192. Welk BK, Herschorn S. Are male slings for post-prostatectomy incontinence a valid option? *Curr Opin Urol* 2010 Nov;20(6):465-70.
<http://www.ncbi.nlm.nih.gov/pubmed/20838219>
193. Maher CF, Feiner B, DeCuyper EM, et al. Laparoscopic sacral colpopexy versus total vaginal mesh for vaginal vault prolapse: a randomized trial. *Am J Obstet Gynecol* 2011 Apr;204(4):360.e1-7.
<http://www.ncbi.nlm.nih.gov/pubmed/21306698>

194. Novara G, Artibani W, Barber MD, et al. Updated systematic review and meta-analysis of the comparative data on colposuspensions, pubovaginal slings, and midurethral tapes in the surgical treatment of female stress urinary incontinence. *Eur Urol* 2010 Aug;58(2):218-38.
<http://www.ncbi.nlm.nih.gov/pubmed/20434257>
195. Ogah J, Cody DJ, Rogerson L. Minimally invasive synthetic suburethral sling operations for stress urinary incontinence in women: a short version Cochrane review. *Neurourol Urodyn* 2011 Mar;30(3):284-91.
<http://www.ncbi.nlm.nih.gov/pubmed/21412819>
196. Long CY, Hsu CS, Wu MP, et al. Comparison of tension-free vaginal tape and transobturator tape procedure for the treatment of stress urinary incontinence. *Curr Opin Obstet Gynecol* 2009 Aug;21(4):342-7.
<http://www.ncbi.nlm.nih.gov/pubmed/19528799>
197. Altman D, Väyrynen T, Engh ME, et al. Anterior colporrhaphy versus transvaginal mesh for pelvic organ prolapse. *N Engl J Med* 2011 May 12;364(19):1826-36.
<http://www.ncbi.nlm.nih.gov/pubmed/21561348>
198. Huang WC, Lin TY, Lau HH, et al. Outcome of transvaginal pelvic reconstructive surgery with Prolift after a median of 2 years' follow-up. *Int Urogynecol J* 2011 Feb;22(2):197-203.
<http://www.ncbi.nlm.nih.gov/pubmed/20821308>
199. Balbay MD, Cimentepe E, Unsal A, et al. The actual incidence of bladder perforation following transurethral bladder surgery. *J Urol* 2005 Dec;174(6):2260-2, discussion 2262-3.
<http://www.ncbi.nlm.nih.gov/pubmed/16280794>
200. Nieder AM, Meibach DS, Kim SS, et al. Transurethral bladder tumor resection: intraoperative and postoperative complications in a residency setting. *J Urol* 2005 Dec;174(6):2307-9.
<http://www.ncbi.nlm.nih.gov/pubmed/16280830>
201. Golan S, Baniel J, Lask D, et al. Transurethral resection of bladder tumour complicated by perforation requiring open surgical repair - clinical characteristics and oncological outcomes. *BJU Int* 2011 Apr;107(7):1065-8.
<http://www.ncbi.nlm.nih.gov/pubmed/20860654>
202. El Hayek OR, Coelho RF, Dall'oglio MF, et al. Evaluation of the incidence of bladder perforation after transurethral bladder tumor resection in a residency setting. *J Endourol* 2009 Jul;23(7):1183-6.
<http://www.ncbi.nlm.nih.gov/pubmed/19530900>
203. Collado A, Chechile GE, Salvador J, et al. Early complications of endoscopic treatment for superficial bladder tumors. *J Urol* 2000 Nov;164(5):1529-32.
<http://www.ncbi.nlm.nih.gov/pubmed/11025697>
204. Frenkl TL, Rackley RR, Vasavada SP, et al. Management of iatrogenic foreign bodies of the bladder and urethra following pelvic floor surgery. *Neurourol Urodyn* 2008;27(6):491-5.
<http://www.ncbi.nlm.nih.gov/pubmed/18537142>
205. Rafique M. Intravesical foreign bodies: review and current management strategies. *Urol J* 2008 Fall;5(4):223-31.
<http://www.ncbi.nlm.nih.gov/pubmed/19101894>
206. Morey AF, Iverson AJ, Swan A, et al. Bladder rupture after blunt trauma: guidelines for diagnostic imaging. *J Trauma* 2001 Oct;51(4):683-6.
<http://www.ncbi.nlm.nih.gov/pubmed/11586159>
207. Tonkin JB, Tisdale BE, Jordan GH. Assessment and initial management of urologic trauma. *Med Clin North Am* 2011 Jan;95(1):245-51.
<http://www.ncbi.nlm.nih.gov/pubmed/21095427>
208. Manikandan R, Lynch N, Grills RJ. Percutaneous peritoneal drainage for intraperitoneal bladder perforations during transurethral resection of bladder tumors. *J Endourol* 2003 Dec;17(10):945-7.
<http://www.ncbi.nlm.nih.gov/pubmed/14744369>
209. Foley C, Patki P, Boustead G. Unrecognized bladder perforation with mid-urethral slings. *BJU Int* 2010 Nov;106(10):1514-8.
<http://www.ncbi.nlm.nih.gov/pubmed/20518762>
210. Quagliano PV, Delair SM, Malhotra AK. Diagnosis of blunt bladder injury: A prospective comparative study of computed tomography cystography and conventional retrograde cystography. *J Trauma* 2006 Aug;61(2):410-21; discussion 421-2.
<http://www.ncbi.nlm.nih.gov/pubmed/16917459>
211. Alperin M, Mantia-Smaldone G, Sagan ER. Conservative management of postoperatively diagnosed cystotomy. *Urology* 2009 May;73(5):1163.e17-9.
<http://www.ncbi.nlm.nih.gov/pubmed/18514295>

212. Daneshgari F, Kong W, Swartz M. Complications of mid urethral slings: important outcomes for future clinical trials. *J Urol* 2008 Nov;180(5):1890-7.
<http://www.ncbi.nlm.nih.gov/pubmed/18801499>
213. Bekker MD, Bevers RF, Elzevier HW. Transurethral and suprapubic mesh resection after Prolift bladder perforation: a case report. *Int Urogynecol J* 2010 Oct;21(10):1301-3.
<http://www.ncbi.nlm.nih.gov/pubmed/20204325>
214. Pansadoro A, Franco G, Laurenti C, et al. Conservative treatment of intraperitoneal bladder perforation during transurethral resection of bladder tumor. *Urology* 2002 Oct;60(4):682-4.
<http://www.ncbi.nlm.nih.gov/pubmed/12385934>
215. Wu CW, Lin CH, Lin CH. One-stage posttraumatic bladder reconstruction and soft-tissue coverage of the lower abdomen or perineum. *Ann Plast Surg* 2010 Jan;64(1):65-8.
<http://www.ncbi.nlm.nih.gov/pubmed/20023456>
216. Traxer O, Pasqui F, Gattegno B, et al. Technique and complications of transurethral surgery for bladder tumours. *BJU Int* 2004 Sep;94(4):492-6.
<http://www.ncbi.nlm.nih.gov/pubmed/15329099>
217. Stav K, Dwyer PL, Rosamilia A, et al. Risk factors for trocar injury to the bladder during mid urethral sling procedures. *J Urol* 2009 Jul;182(1):174-9.
<http://www.ncbi.nlm.nih.gov/pubmed/19450824>
218. Araco F, Gravante G, Piccione E. Bladder erosion after 2 years from cystocele repair with type Ipolypropylene mesh. *Int Urogynecol J Pelvic Floor Dysfunct* 2009 Jun;20(6):731-3.
<http://www.ncbi.nlm.nih.gov/pubmed/18815720>
219. Inaba K, Okoye OT, Bowder T, et al. Prospective evaluation of the utility of routine postoperative cystogram after traumatic bladder injury. *J Trauma Acute Care Surg* 2013 Dec;75(6):1019-23.
<http://www.ncbi.nlm.nih.gov/pubmed/24256676>
220. Inaba K, McKenney, Munera F, et al. Cystogram follow-up in the management of traumatic bladder disruption. *J Trauma* 2006 Jan;60(1):23-8.
<http://www.ncbi.nlm.nih.gov/pubmed/16456432>
221. Mundy A, Andrich D. Urethral trauma. Part I: introduction, history, anatomy, pathology, assessment and emergency management. *BJUI* 2011 Aug;108(3):310-27
<http://www.ncbi.nlm.nih.gov/pubmed/21771241>
222. Kashefi C, Messer K, Barden R, et al. Incidence and prevention of iatrogenic urethral injuries: *J Urol* 2008 Jun;179(6):2254-7.
<http://www.ncbi.nlm.nih.gov/pubmed/18423712>
223. Fenton AS, Morey AF, Aviles R, et al. Anterior urethral stricture: etiology and characteristics. *Urology* 2005 Jun;65(6):1055-8.
<http://www.ncbi.nlm.nih.gov/pubmed/15913734>
224. Buddha S. Complication of urethral catheterisation. *Lancet* 2005 Mar;365(9462):909.
<http://www.ncbi.nlm.nih.gov/pubmed/15752537>
225. Hammarsten J, Lindqvist K. Suprapubic catheter following transurethral resection of the prostate: a way to decrease the number of urethral strictures and improve the outcome of operations. *J Urol* 1992 Mar;147(3):648-51.
<http://www.ncbi.nlm.nih.gov/pubmed/1538447>
226. Katz G, Milgalter E, Landau Y, et al. Prevention of urethral strictures following coronary artery bypass graft surgery. *Urology* 1992 May;39(5):433-5.
<http://www.ncbi.nlm.nih.gov/pubmed/1580032>
227. Thomas AZ, Giri SK, Meagher D, et al. Avoidable iatrogenic complications of urethral catheterization and inadequate intern training in a tertiary-care teaching hospital. *BJU Int* 2009 Oct;104(8):1109-12.
<http://www.ncbi.nlm.nih.gov/pubmed/19338562>
228. Vicente J, Rosales A, Montlleó M, et al. Value of electrical dispersion as a cause of urethral stenosis after endoscopic surgery. *Eur Urol* 1992;21(4):280-3.
<http://www.ncbi.nlm.nih.gov/pubmed/1459149>
229. Hammarsten J, Lindqvist K, Sunzel H. Urethral strictures following transurethral resection of the prostate. The role of the catheter. *Br J Urol* 1989 Apr;63(4):397-400.
<http://www.ncbi.nlm.nih.gov/pubmed/2713622>
230. Rassweiler J, Teber D, Kuntz R, et al. Complications of transurethral resection of the prostate (TURP)-- incidence, management, and prevention. *Eur Urol* 2006 Nov;50(5):969-79; discussion 980.
<http://www.ncbi.nlm.nih.gov/pubmed/16469429>
231. Eltabey MA, Sherif H, Hussein AA. Holmium laser enucleation versus transurethral resection of the prostate. *Can J Urol* 2010 Dec;17(6):5447-52.
<http://www.ncbi.nlm.nih.gov/pubmed/21172109>

232. Elliott SP, Meng MV, Elkin EP, et al; CaPSURE investigators. Incidence of urethral stricture after primary treatment for prostate cancer: data from CaPSURE. *J Urol* 2007 Aug;178(2):529-34.
<http://www.ncbi.nlm.nih.gov/pubmed/17570425>
233. Park R, Martin S, Goldberg JD, et al. Anastomotic strictures following radical prostatectomy: insights into incidence, effectiveness of intervention, effect on continence, and factors predisposing to occurrence. *Urology* 2001 Apr;57(4):742-6.
<http://www.ncbi.nlm.nih.gov/pubmed/11306394>
234. Msezane LP, Reynolds WS, Gofrit ON, et al. Bladder neck contracture after robot-assisted laparoscopic radical prostatectomy: evaluation of incidence and risk factors and impact on urinary function. *J Endourol* 2008 Jan;22(1):97-104.
<http://www.ncbi.nlm.nih.gov/pubmed/18326071>
235. Ficarra V, Novara G, Artibani W, et al. Retropubic, laparoscopic, and robot-assisted radical prostatectomy: a systematic review and cumulative analysis of comparative studies. *Eur Urol* 2009 May;55(5):1037-63.
<http://www.ncbi.nlm.nih.gov/pubmed/19185977>
236. Chrouser KL, Leibovich BC, Sweat SD, et al. Urinary fistulas following external radiation or permanent brachytherapy for the treatment of prostate cancer. *J Urol* 2005 Jun;173(6):1953-7.
<http://www.ncbi.nlm.nih.gov/pubmed/15879789>
237. Marguet C, Raj GV, Brashears JH, et al. Rectourethral fistula after combination radiotherapy for prostate cancer. *Urology* 2007 May;69(5):898-901.
<http://www.ncbi.nlm.nih.gov/pubmed/17482930>
238. Gómez-Iturriaga Piña A, Crook J, Borg J, et al. Median 5 year follow-up of 125iodine brachytherapy as monotherapy in men aged <or=55 years with favorable prostate cancer. *Urology* 2010 Jun;75(6):1412-6.
<http://www.ncbi.nlm.nih.gov/pubmed/20035986>
239. Fonteyne V, Villeirs G, Lumen N, et al. Urinary toxicity after high dose intensity modulated radiotherapy as primary therapy for prostate cancer. *Radiother Oncol* 2009 Jul;92(1):42-7.
<http://www.ncbi.nlm.nih.gov/pubmed/19356817>
240. Shelley M, Wilt TJ, Coles B, et al. Cryotherapy for localised prostate cancer. *Cochrane Database Syst Rev* 2007 Jul 18;(3):CD005010.
<http://www.ncbi.nlm.nih.gov/pubmed/17636783>
241. Polat O, Gül O, Aksoy Y, et al. Iatrogenic injuries to ureter, bladder and urethra during abdominal and pelvic operations. *Int Urol Nephrol* 1997;29(1):13-8.
<http://www.ncbi.nlm.nih.gov/pubmed/9203032>
242. Hautmann RE, de Petriconi RC, Volkmer BG. 25 years of experience with 1,000 neobladders: longterm complications. *J Urol* 2011 Jun;185(6):2207-12.
<http://www.ncbi.nlm.nih.gov/pubmed/21497841>
243. Chapple C, Barbagli G, Jordan G, et al. Consensus statement on urethral trauma. *BJU Int* 2004 Jun;93(9):1195-202.
<http://www.ncbi.nlm.nih.gov/pubmed/15180604>
244. Brandes S. Initial management of anterior and posterior urethral injuries. *Urol Clin North Am* 2006 Feb;33(1):87-95, vii.
<http://www.ncbi.nlm.nih.gov/pubmed/16488283>
245. Park S, McAninch JW. Straddle injuries to the bulbar urethra: management and outcomes in 78 patients. *J Urol* 2004 Feb;171(2 Pt 1):722-5.
<http://www.ncbi.nlm.nih.gov/pubmed/14713796>
246. Elgammal MA. Straddle injuries to the bulbar urethra: management and outcome in 53 patients. *Int Braz J Urol* 2009 Jul-Aug;35(4):450-8.
<http://www.ncbi.nlm.nih.gov/pubmed/19719861>
247. Kommu SS, Illahi I, Mumtaz F. Patterns of urethral injury and immediate management. *Curr Opin Urol* 2007 Nov;17(6):383-9.
<http://www.ncbi.nlm.nih.gov/pubmed/17921771>
248. Rosenstein DI, Alsikafi NF. Diagnosis and classification of urethral injuries. *Urol Clin North Am* 2006 33(1):73-85, vi-vii.
<http://www.ncbi.nlm.nih.gov/pubmed/16488282>
249. Phonsombat S, Master VA, McAninch JW. Penetrating external genitalia trauma: a 30-year single institution experience. *J Urology* 2008 Jul;180(1):192-5.
<http://www.ncbi.nlm.nih.gov/pubmed/18499189>

250. Simhan J, Rothman J, Canter D, et al. Gunshot wounds to the scrotum: a large single-institutional 20-year experience. *BJU Int* 2012 Jun;109(11):1704-7.
<http://www.ncbi.nlm.nih.gov/pubmed/21992688>
251. Kunkle DA, Lebed BD, Mydlo JH, et al. Evaluation and management of gunshot wounds of the penis: 20-year experience at an urban trauma center. *J Trauma* 2008 Apr;64(4):1038-42.
<http://www.ncbi.nlm.nih.gov/pubmed/18404072>
252. Bjurlin MA, Kim DY, Zhao LC, et al. Clinical characteristics and surgical outcomes of penetrating external genital injuries. *J Trauma Acute Care Surg* 2013 Mar;74(3):839-44.
<http://www.ncbi.nlm.nih.gov/pubmed/23425745>
253. Amit A, Arun K, Bharat B, et al. Penile fracture and associated urethral injury: Experience at a tertiary care hospital. *Can Urol Assoc J* 2013 Mar-Apr;7(3-4):E168-70.
<http://www.ncbi.nlm.nih.gov/pubmed/23589751>
254. Lumen N, Hoebeke P, Willemssen P, et al. Etiology of urethral stricture disease in the 21st century. *J Urol* 2009 Sep;182(3):983-7.
<http://www.ncbi.nlm.nih.gov/pubmed/19616805>
255. Palminteri E, Berdondini E, Verze P, et al. Contemporary urethral stricture characteristics in the developed world. *Urology* 2013 Jan;81(1):191-6.
<http://www.ncbi.nlm.nih.gov/pubmed/23153951>
256. Basta AM, Blackmore CC and Wessells H. Predicting urethral injury from pelvic fracture patterns in male patients with blunt trauma. *J Urol* 2007 Feb;177(2):571-5.
<http://www.ncbi.nlm.nih.gov/pubmed/17222635>
257. Koraitim MM, Marzouk ME, Atta MA, et al. Risk factors and mechanism of urethral injury in pelvic fractures. *Br J Urol* 1996 Jun;77(6):876-80.
<http://www.ncbi.nlm.nih.gov/pubmed/8705225>
258. Mundy A, Andrich D. Pelvic fracture-related injuries of the bladder neck and prostate: their nature, cause and management. *BJU Int* 2010 May;105(9):1302-8.
<http://www.ncbi.nlm.nih.gov/pubmed/19874306>
259. Tausch TJ, Cavalcanti AG, Soderdahl DW, et al. Gunshot wound injuries of the prostate and posterior urethra: reconstructive armamentarium. *J Urol* 2007 Oct;178(4 Pt 1):1346-8.
<http://www.ncbi.nlm.nih.gov/pubmed/17706720>
260. Koraitim MM. Predictors of erectile dysfunction post pelvic fracture urethral injuries: a multivariate analysis. *Urology* 2013 May;81(5):1081-5.
<http://www.ncbi.nlm.nih.gov/pubmed/23465164>
261. Feng C, Xu YM, Yu JJ, et al. Risk factors for erectile dysfunction in patients with urethral strictures secondary to blunt trauma. *J Sex Med* 2008 Nov;5(11):2656-61.
<http://www.ncbi.nlm.nih.gov/pubmed/18564154>
262. Metze M, Tiemann AH, Josten C. Male sexual dysfunction after pelvic fracture. *J Trauma* 2007 Aug;63(2):394-401.
<http://www.ncbi.nlm.nih.gov/pubmed/17693842>
263. Koraitim MM, Reda IS. Role of magnetic resonance imaging in assessment of posterior urethral distraction defects. *Urology* 2007 Sep;70:403-6.
<http://www.ncbi.nlm.nih.gov/pubmed/17905082>
264. Mundy AR, Andrich DE. Urethral trauma. Part II: Types of injury and their management. *BJU Int* 2011 Sep;108(5):630-50. [No abstract available.]
<http://www.ncbi.nlm.nih.gov/pubmed/21854524>
265. Figler B, Hoffer CE, Reisman W, et al. Multi-disciplinary update on pelvic fracture associated bladder and urethral injuries. *Injury* 2012 Aug;43(8):1242-9.
<http://www.ncbi.nlm.nih.gov/pubmed/22592152>
266. Koraitim MM. Pelvic fracture urethral injuries: the unresolved controversy. *J Urol* 1999 May; 161(5):1433-41.
<http://www.ncbi.nlm.nih.gov/pubmed/10210368>
267. Hadjizacharia P, Inaba K, Teixeira PG, et al. Evaluation of immediate endoscopic realignment as a treatment modality for traumatic urethral injuries. *J Trauma* 2008 Jun;64(6):1443-9.
<http://www.ncbi.nlm.nih.gov/pubmed/18545107>
268. Rieder J, Brusky J, Tran V, et al. Review of intentionally self-inflicted, accidental and iatrogenic foreign objects in the genitourinary tract. *Urol Int* 2010;84(4):471-5.
<http://www.ncbi.nlm.nih.gov/pubmed/20224259>
269. Kielb SJ, Voeltz ZL and Wolf JS. Evaluation and management of traumatic posterior urethral disruption with flexible cystourethroscopy. *J Trauma* 2001 Jan;50(1):36-40.
<http://www.ncbi.nlm.nih.gov/pubmed/11253761>

270. Mazaris EM, Livadas K, Chalikopoulos D, et al. Penile fractures: immediate surgical approach with a midline ventral incision. *BJU Int* 2009 Aug;104(4):520-3.
<http://www.ncbi.nlm.nih.gov/pubmed/19239439>
271. Kamdar C, Mooppan UM, Kim H, et al. Penile fracture: preoperative evaluation and surgical technique for optimal patient outcome. *BJU Int* 2008;102(11):1640-4;discussion 1644.
<http://www.ncbi.nlm.nih.gov/pubmed/18710448>
272. Mouraviev VB, Coburn M, Santucci RA. The treatment of posterior urethral disruption associated with pelvic fractures: comparative experience of early realignment versus delayed urethroplasty. *J Urol* 2005 Mar;173(3):873-6.
<http://www.ncbi.nlm.nih.gov/pubmed/15711301>
273. Derouiche A, Belhaj K, Hentati H, et al. Management of penile fractures complicated by urethral rupture. *Int J Impot Res* 2008 Jan-Feb;20(1):111-4.
<http://www.ncbi.nlm.nih.gov/pubmed/17673928>
274. Jack GS, Garraway I, Reznichek R, et al. Current treatment options for penile fractures. *Rev Urol* 2004 Summer;6(3):114-20.
<http://www.ncbi.nlm.nih.gov/pubmed/16985591>
275. Cavalcanti AG, Krambeck R, Araújo A, et al. Management of urethral lesions in penile blunt trauma. *Int J Urol* 2006 Sep;13(9):1218-20.
<http://www.ncbi.nlm.nih.gov/pubmed/16984556>
276. Koraitim MM. Pelvic fracture urethral injuries: evaluation of various methods of management. *J Urol* Oct;156(4):1288-91.
<http://www.ncbi.nlm.nih.gov/pubmed/8808856>
277. Leddy LS, Vanni AJ, Wessells H, et al. Outcomes of endoscopic realignment of pelvic fracture associated urethral injuries at a level 1 trauma center. *J Urol* 2012 Jul;188(1):174-8.
<http://www.ncbi.nlm.nih.gov/pubmed/22591965>
278. Moudouni SM, Patard JJ, Manunta A, et al. Early endoscopic realignment of post-traumatic posterior urethral disruption. *Urology* 2001 Apr;57(4):628-32.
<http://www.ncbi.nlm.nih.gov/pubmed/11306365>
279. Kulkarni SB, Barbagli G, Kulkani JS, et al. Posterior urethral stricture after pelvic fracture urethral distraction defects in developing and developed countries, and choice of surgical technique. *J Urol* 2010 Mar;183(3):1049-54.
<http://www.ncbi.nlm.nih.gov/pubmed/20092843>
280. Koraitim MM. Unsuccessful outcomes after posterior urethroplasty: definition, diagnosis, and treatment. *Urology* 2012 May;79(5):1168-73.
<http://www.ncbi.nlm.nih.gov/pubmed/22449452>
281. Sofer M, Mabweesh NJ, Ben-Chaim J, et al. Long-term results of early endoscopic realignment of complete posterior urethral disruption. *J Endourol* 2010 Jul;24(7):1117-21.
<http://www.ncbi.nlm.nih.gov/pubmed/20590470>
282. Singh BP, Andankar MG, Swain SK, et al. Impact of prior urethral manipulation on outcome of anastomotic urethroplasty for post-traumatic urethral stricture. *Urology* 2010 Jan;75(1):179-82.
<http://www.ncbi.nlm.nih.gov/pubmed/19854488>
283. Lumen N, Hoebeke P, Troyer BD, et al. Perineal anastomotic urethroplasty for posttraumatic urethral stricture with or without previous urethral manipulations: a review of 61 cases with long-term followup. *J Urol* 2009 Mar;181(3):1196-200.
<http://www.ncbi.nlm.nih.gov/pubmed/19152939>
284. Mundy AR. The role of delayed primary repair in the acute management of pelvic fracture injuries of the urethra. *Br J Urol* 1991 Sep;68(3):273-6.
<http://www.ncbi.nlm.nih.gov/pubmed/1913069>
285. Aboutaieb R, Sarf I, Dakir M, et al. [Surgical treatment of traumatic ruptures of the posterior urethra.] *Prog Urol* 2000 Feb;10(1):58-64. [Article in French.]
<http://www.ncbi.nlm.nih.gov/pubmed/10785920>
286. Sfaxi M, El Atat R, Ben Hassine L, et al. [Surgical treatment of post-traumatic complete urethral rupture: deferred urgent urethral suture or delayed repair?] *Prog Urol* 2006 Sep;16(4):464-9. [Article in French.]
<http://www.ncbi.nlm.nih.gov/pubmed/17069041>
287. Elliott DS, Barrett DM. Long-term followup and evaluation of primary realignment of posterior urethral disruptions. *J Urol* 1997 Mar;157(3):814-6.
<http://www.ncbi.nlm.nih.gov/pubmed/9072573>

288. Culty T, Boccon-Gibod L. Anastomotic urethroplasty for posttraumatic urethral stricture: previous urethral manipulation has a negative impact on the final outcome. *J Urol* 2007 Apr;177(4):1374-7. <http://www.ncbi.nlm.nih.gov/pubmed/17382735>
289. Webster GD, Ramon J. Repair of pelvic fracture posterior urethral defects using an elaborated perineal approach: experience with 74 cases. *J Urol* 1991 Apr;145(4):744-8. <http://www.ncbi.nlm.nih.gov/pubmed/2005693>
290. Kizer WS, Armenakas NA, Brandes SB, et al. Simplified reconstruction of posterior urethral disruption defects: limited role of supracrural rerouting. *J Urol* 2007 Apr;177(4):1378-81;discussion 1381-2. <http://www.ncbi.nlm.nih.gov/pubmed/17382736>
291. Koraitim MM. On the art of anastomotic posterior urethroplasty: a 27-year experience. *J Urol* 2005 Jan;173(1):135-9. <http://www.ncbi.nlm.nih.gov/pubmed/15592055>
292. Cooperberg MR, McAninch JW, Alsikafi NF, et al. Urethral reconstruction for traumatic posterior urethral disruption: outcomes of a 25-year experience. *J Urol* 2007 Nov;178(5):2006-10. <http://www.ncbi.nlm.nih.gov/pubmed/17869302>
293. Webster GD, Ramon J, Kreder KJ. Salvage posterior urethroplasty after failed initial repair of pelvic fracture membranous urethral defects. *J Urol* 1990 Dec;144(6):1370-2. <http://www.ncbi.nlm.nih.gov/pubmed/2231930>
294. MacDiarmid S, Rosario D, Chapple CR. The importance of accurate assessment and conservative management of the open bladder neck in patients with post-pelvic fracture membranous urethral distraction defects. *Br J Urol* 1995 Jan;75(1):65-7. <http://www.ncbi.nlm.nih.gov/pubmed/7850300>
295. Oosterlinck W, Lumen N, Van Cauwenberghe G. [Surgical treatment of urethral stenoses: technical aspects.] *Ann Urol (Paris)* 2007 Aug;41(4):173-207. [Article in French] <http://www.ncbi.nlm.nih.gov/pubmed/18260607>
296. Fu Q, Zhang J, Sa YL, et al. Recurrence and complications after transperineal bulboprostatic anastomosis for posterior urethral strictures resulting from pelvic fracture: a retrospective study from a urethral referral centre. *BJU Int* 2013 Aug;112(4):E358-63. <http://www.ncbi.nlm.nih.gov/pubmed/23773274>
297. Feng C, Xu YM, Barbagli G, et al. The relationship between erectile dysfunction and open urethroplasty: a systematic review and meta-analysis. *J Sex Med* 2013 Aug;10(8):2060-8. <http://www.ncbi.nlm.nih.gov/pubmed/23656595>
298. Levine J, Wessells H. Comparison of open and endoscopic treatment of posttraumatic posterior urethral strictures. *World J Surg* 2001 Dec;25(12):1597-601. <http://www.ncbi.nlm.nih.gov/pubmed/11775198>
299. Goel MC, Kumar M, Kapoor R. Endoscopic management of traumatic posterior urethral stricture: early results and followup. *J Urol* 1997 Jan;157(1):95-7. <http://www.ncbi.nlm.nih.gov/pubmed/8976224>
300. Singh O, Gupta SS, Mathur RK. Urogenital fistulas in women: 5-year experience at a single center. *Urol J* 2010 Winter;7(1):35-9. <http://www.ncbi.nlm.nih.gov/pubmed/20209454>
301. Gökalp A, Yildirim I, Aydur E, et al. How to manage acute urethral false passage due to intermittent catheterization in spinal cord injured patients who refused insertion of an indwelling catheter. *J Urol* 2003 Jan;169(1):203-6. <http://www.ncbi.nlm.nih.gov/pubmed/12478136>
302. Maheshwari PN, Shah HN. Immediate endoscopic management of complete iatrogenic anterior urethral injuries: a case series with long-term results. *BMC Urol* 2005 Nov;5:13. <http://www.ncbi.nlm.nih.gov/pubmed/16281970>
303. Pansadoro V, Emiliozzi P. Iatrogenic prostatic urethral strictures: classification and endoscopic treatment. *Urology* 1999 Apr;53(4):784-9. <http://www.ncbi.nlm.nih.gov/pubmed/10197857>
304. Monga M, Hellstrom WJ. Testicular Trauma. *Adolesc Med* 1996 Feb;7(1):141-148. <http://www.ncbi.nlm.nih.gov/pubmed/10359963>
305. Frauscher F, Klauser A, Stenzl A, et al. US findings in the scrotum of extreme mountain bikers. *Radiology* 2001 May;219(2):427-31. <http://www.ncbi.nlm.nih.gov/pubmed/11323467>
306. de Peretti F, Cambas PM, Veneau B, et al. [Fuel tanks of motorcycles. Role in severe trauma of the pelvis.] *Presse Med* 1993 Jan;22(2):61-3. [Article in French] <http://www.ncbi.nlm.nih.gov/pubmed/8493205>

307. Herrmann B, Crawford J. Genital injuries in prepubertal girls from inline skating accidents. *Pediatrics* 2002 Aug;110(2 Pt 1):e16.
<http://www.ncbi.nlm.nih.gov/pubmed/12165615>
308. Lawson JS, Rotem T, Wilson SF. Catastrophic injuries to the eyes and testicles in footballers. *Med J Aust* 1995 Sep;163(5):242-4.
<http://www.ncbi.nlm.nih.gov/pubmed/7565208>
309. Selikowitz SM. Penetrating high-velocity genitourinary injuries. Part I. Statistics mechanism and renal wounds. *Urology* 1977 Apr;9(4):371-6.
<http://www.ncbi.nlm.nih.gov/pubmed/855062>
310. Hudak SJ, Hakim S. Operative management of wartime genitourinary injuries at Balad Air Force Theater Hospital, 2005 to 2008. *J Urol* 2009 Jul;182(1):180-3.
<http://www.ncbi.nlm.nih.gov/pubmed/19450817>
311. Cass AS, Ferrara L, Wolpert J, et al. Bilateral testicular injury from external trauma. *J Urol* 1988 Dec;140(6):1435-6.
<http://www.ncbi.nlm.nih.gov/pubmed/3193512>
312. McAninch JW, Kahn RI, Jeffrey RB, et al. Major traumatic and septic genital injuries. *J Trauma* 1984 Apr;24(4):291-8.
<http://www.ncbi.nlm.nih.gov/pubmed/6368854>
313. Michielsen D, Van Hee R, Neetens C, et al. Burns to the genitalia and the perineum. *J Urol* 1998 Feb;159(2):418-9.
<http://www.ncbi.nlm.nih.gov/pubmed/9649253>
314. Nelius T, Armstrong ML, Rinard K, et al. Genital piercings: diagnostic and therapeutic implications for urologists. *Urology* 2011 Nov;78(5):998-1007.
<http://www.ncbi.nlm.nih.gov/pubmed/22054364>
315. Goldman HB, Idom CB Jr, Dmochowski RR. Traumatic injuries of the female external genitalia and their association with urological injuries. *J Urol* 1998 Mar;159(3):956-9.
<http://www.ncbi.nlm.nih.gov/pubmed/9474191>
316. Husmann DA. Editorial Comment. *J Urol* 1998;159:959
317. Donovan JF, Kaplan WE. The therapy of genital trauma by dog bite. *J Urol* 1989 May;141(5):1163-5.
<http://www.ncbi.nlm.nih.gov/pubmed/2651716>
318. Presutti RJ. Prevention and treatment of dog bites. *Am Fam Physician* 2001 Apr; 63(8):1567-72.
<http://www.ncbi.nlm.nih.gov/pubmed/11327433>
319. Talan DA, Citron DM, Abrahamian FM, et al. Bacteriologic analysis of infected dog and cat bites. Emergency Medicine Animal Bite Infection Study Group. *N Engl J Med* 1999 Jan;340(2):85-92.
<http://www.ncbi.nlm.nih.gov/pubmed/9887159>
320. Presutti RJ. Bite wounds. Early treatment and prophylaxis against infectious complications. *Postgrad Med* 1997 Apr;101(4):243-4, 246-52, 254.
<http://www.ncbi.nlm.nih.gov/pubmed/9126216>
321. Lewis KT, Stiles M. Management of cat and dog bites. *Am Fam Physician* 1995 Aug;52(2):479-85, 489-90.
<http://www.ncbi.nlm.nih.gov/pubmed/7625323>
322. Dreesen DW, Hanlon CA. Current recommendations for the prophylaxis and treatment of rabies. *Drugs* 1998 Nov;56(5):801-9.
<http://www.ncbi.nlm.nih.gov/pubmed/9829154>
323. Anderson CR. Animal bites. Guidelines to current management. *Postgrad Med* 1992 Jul;92(1): 134-6,139-46,149.
<http://www.ncbi.nlm.nih.gov/pubmed/1614928>
324. Guidelines for the Management of Human Bite Injuries. Health Protection Agency North West 2007.
http://www.hpa.org.uk/web/HPAwebFile/HPAweb_C/1194947350692
325. McGregor MJ, Du Mont J, Myhr TL. Sexual assault forensic medical examination: is evidence related to successful prosecution? *Ann Emerg Med* 2002 Jun;39(6):639-47.
<http://www.ncbi.nlm.nih.gov/pubmed/12023707>
326. Okur H, Küçükaydin M, Kazez A, et al. Genitourinary tract injuries in girls. *Br J Urol* 1996 Sep;78(3):446-9.
<http://www.ncbi.nlm.nih.gov/pubmed/8881959>
327. Dardamissis E, Gee A, Kaczmarek E, et al on behalf of the North West Policy Group. Guidance for healthcare professionals on dealing with injuries where teeth break the skin. Health Care Protection Agency, October 2007.
http://www.hpa.org.uk/web/HPAwebFile/HPAweb_C/1194947350692

328. A national protocol for sexual assault medical forensic examinations adults/adolescents. U.S. Dept of Justice. Office on Violence Against Women, September 2004.
<http://www.ncjrs.gov/pdffiles1/ovw/206554.pdf>
329. Zargooshi J. Penile fracture in Kermanshah, Iran: report of 172 cases. *J Urol* 2000 Aug;164(2):364-6.
<http://www.ncbi.nlm.nih.gov/pubmed/10893586>
330. Haas CA, Brown SL, Spirnak JP. Penile fracture and testicular rupture. *World J Urol* 1999 Apr;17(2):101-6.
<http://www.ncbi.nlm.nih.gov/pubmed/10367369>
331. Nicolaisen GS, Melamud A, Williams RD, et al. Rupture of the corpus cavernosum: surgical management. *J Urol* 1983 Nov;130(5):917-9.
<http://www.ncbi.nlm.nih.gov/pubmed/6632099>
332. Tsang T, Demby AM. Penile fracture with urethral injury. *J Urol* 1992 Feb;147(2):466-8.
<http://www.ncbi.nlm.nih.gov/pubmed/1732623>
333. Mydlo JH, Hayyeri M, Macchia RJ. Urethrography and cavernosography imaging in a small series of penile fractures: a comparison with surgical findings. *Urology* 1998 Apr;51(4):616-9.
<http://www.ncbi.nlm.nih.gov/pubmed/9586616>
334. Lee SH, Bak CW, Choi MH, et al. Trauma to male genital organs: a 10-year review of 156 patients, including 118 treated by surgery. *BJU Int* 2008 Jan;101(2):211-5.
<http://www.ncbi.nlm.nih.gov/pubmed/17922859>
335. Karadeniz T, Topsakal M, Ariman A, et al. Penile fracture: differential diagnosis, management and outcome. *Br J Urol* 1996 Feb;77(2):279-81.
<http://www.ncbi.nlm.nih.gov/pubmed/8800899>
336. Fedel M, Venz S, Andreessen R, et al. The value of magnetic resonance imaging in the diagnosis of suspected penile fracture with atypical clinical findings. *J Urol* 1996 Jun;155(6):1924-7.
<http://www.ncbi.nlm.nih.gov/pubmed/8618289>
337. Pretorius ES, Siegelman ES, Ramchandani P, et al. MR imaging of the penis. *Radiographics* 2001 Oct;21 Spec No:S283-98, discussion S298-9.
<http://www.ncbi.nlm.nih.gov/pubmed/11598264>
338. Uder M, Gohl D, Takahashi M, et al. MRI of penile fracture: diagnosis and therapeutic follow-up. *Eur Radiol* 2002 Jan;12(1):113-20.
<http://www.ncbi.nlm.nih.gov/pubmed/11868085>
339. Summerton DJ, Campbell A, Minhas S, et al. Reconstructive surgery in penile trauma and cancer. *Nat Clin Pract Urol* 2005 Aug;2(8):391-7.
<http://www.ncbi.nlm.nih.gov/pubmed/16474736>
340. Orvis BR, McAninch JW. Penile rupture. *Urol Clin North Am* 1989 May;16(2):369-75.
<http://www.ncbi.nlm.nih.gov/pubmed/2652861>
341. Babaei AR, Safarinejad MR. Penile replantation, science or myth? A systematic review. *Urol J* 2007 Spring;4(2):62-5.
<http://www.ncbi.nlm.nih.gov/pubmed/17701923>
342. Lee JY, Cass AS, Streitz JM. Traumatic dislocation of testes and bladder rupture. *Urology* 1992 Dec; 40(6):506-8.
<http://www.ncbi.nlm.nih.gov/pubmed/1466102>
343. Nagarajan VP, Pranikoff K, Imahori SC, et al. Traumatic dislocation of testis. *Urology* 1983 Nov;22(5):521-4.
<http://www.ncbi.nlm.nih.gov/pubmed/6649208>
344. Pollen JJ, Funckes C. Traumatic dislocation of the testes. *J Trauma* 1982 Mar;22(3):247-9.
<http://www.ncbi.nlm.nih.gov/pubmed/7069812>
345. Shefi S, Mor Y, Dotan ZA, et al. Traumatic testicular dislocation: a case report and review of published reports. *Urology* 1999 Oct;54(4):744.
<http://www.ncbi.nlm.nih.gov/pubmed/10754145>
346. Tiguert R, Harb JF, Hurley PM, et al. Management of shotgun injuries to the pelvis and lower genitourinary system. *Urology* 2000 Feb;55(2):193-7.
<http://www.ncbi.nlm.nih.gov/pubmed/10688077>
347. Altarac S. Management of 53 cases of testicular trauma. *Eur Urol* 1994;25(2):119-23.
<http://www.ncbi.nlm.nih.gov/pubmed/8137851>
348. Cass AS, Luxenberg M. Value of early operation in blunt testicular contusion with hematocele. *J Urol* 1988 Apr;139(4):746-7.
<http://www.ncbi.nlm.nih.gov/pubmed/3352037>
349. Cass AS, Luxenberg M. Testicular injuries. *Urology* 1991 Jun;37(6):528-30.
<http://www.ncbi.nlm.nih.gov/pubmed/2038785>

350. Wasko R, Goldstein AG. Traumatic rupture of the testicle. *J Urol* 1966 May;95(5):721-3.
<http://www.ncbi.nlm.nih.gov/pubmed/5935538>
351. Andipa E, Liberopoulos K, Asvestis C. Magnetic resonance imaging and ultrasound evaluation of penile and testicular masses. *World J Urol* 2004 Nov;22(5):382-91.
<http://www.ncbi.nlm.nih.gov/pubmed/15300391>
352. Corrales JG, Corbel L, Cipolla B, et al. Accuracy of ultrasound diagnosis after blunt testicular trauma. *J Urol* 1993 Dec;150(6):1834-6.
<http://www.ncbi.nlm.nih.gov/pubmed/8080482>
353. Fournier GR Jr, Laing FC, McAninch JW. Scrotal ultrasonography and the management of testicular trauma. *Urol Clin North Am* 1989 May;16(2):377-85.
<http://www.ncbi.nlm.nih.gov/pubmed/2652862>
354. Kratzik C, Hainz A, Kuber W, et al. Has ultrasound influenced the therapy concept of blunt scrotal trauma? *J Urol* 1989 Nov;142(5):1243-6.
<http://www.ncbi.nlm.nih.gov/pubmed/2681835>
355. Martinez-Piñeiro L Jr, Cerezo E, Cozar JM, et al. Value of testicular ultrasound in the evaluation of blunt scrotal trauma without haematocele. *Br J Urol* 1992 Mar;69(3):286-90.
<http://www.ncbi.nlm.nih.gov/pubmed/1568102>
356. Micallef M, Ahmad I, Ramesh N, et al. Ultrasound features of blunt testicular injury. *Injury* 2001 Jan;32(1):23-6.
<http://www.ncbi.nlm.nih.gov/pubmed/11164397>
357. Mulhall JP, Gabram SG, Jacobs LM. Emergency management of blunt testicular trauma. *Acad Emerg Med* 1995 Jul;2(7):639-43.
<http://www.ncbi.nlm.nih.gov/pubmed/8521212>
358. Patil MG, Onuora VC. The value of ultrasound in the evaluation of patients with blunt scrotal trauma. *Injury* 1994 Apr;25(3):177-8.
<http://www.ncbi.nlm.nih.gov/pubmed/8168890>
359. Muglia V, Tucci S Jr, Elias J Jr, et al. Magnetic resonance imaging of scrotal diseases: when it makes the difference. *Urology* 2002 Mar;59(3):419-23.
<http://www.ncbi.nlm.nih.gov/pubmed/11880084>
360. Altarac S. A case of testicle replantation. *J Urol* 1993 Nov;150(5 Pt 1):1507-8.
<http://www.ncbi.nlm.nih.gov/pubmed/8411440>
361. Sotto LS, Collins RJ. Perigenital Hematomas; analysis of forty-seven consecutive cases. *Obstet Gynecol* 1958 Sep;13:259-63.
<http://www.ncbi.nlm.nih.gov/pubmed/13578292>
362. McWilliams GD, Hill MJ, Dietrich CS 3rd. Gynecologic emergencies. *Surg Clin North Am* 2008 Apr;88(2):265-83.
<http://www.ncbi.nlm.nih.gov/pubmed/18381113>
363. Virgili A, Bianchi A, Mollica G, et al. Serious hematoma of the vulva from a bicycle accident. A case report. *J Reprod Med* 2000 Aug;45(8):662-4.
<http://www.ncbi.nlm.nih.gov/pubmed/10986686>
364. Monstrey SJ, vander Werken C, Debruyne FM, et al. Urological trauma and severe associated injuries. *Br J Urol* 1987 Nov;60(5):393-8.
<http://www.ncbi.nlm.nih.gov/pubmed/3427315>
365. Mackenzie E, Rivara FP, Jurkovich GJ, et al. A National Evaluation of the Effect of Trauma-Center Care on Mortality. *N Engl J Med* 2006 Jan;354(4):366-378.
<http://www.ncbi.nlm.nih.gov/pubmed/16436768>
366. Catterson EJ, Carty MJ, Weaver, et al. Boston Bombings: a surgical view of lessons learnt from combat Casualty care and the applicability to Boston's terrorist attack. *J Craniofac Surg* 2013 Jul;24(4):1061-7.
<http://www.ncbi.nlm.nih.gov/pubmed/23851738>
367. Dutton RP, Cooper C, Jones A, et al. Multidisciplinary rounds shorten length of stay for trauma patients. *J Trauma* 2003 Nov;55(5):913-9.
<http://www.ncbi.nlm.nih.gov/pubmed/14608165>
368. Mankuola JK, Grange PC, Kooiman G, et al. Centralisation of major trauma: an opportunity for acute urology services in the UK. *BJU Int* 2012 Jan;109(2):173-4. [No abstract available]
<http://www.ncbi.nlm.nih.gov/pubmed/22212283>
369. Feliciano DV, Moore EE, Mattox KL. In: Trauma damage control. Mattox KL, Feliciano DV, Moore EE(eds). Trauma, 4th edn, New York: McGraw-Hill, 2000, Chapter 39, pp. 907-931.
370. Hirshberg A, Mattox KL. 'Damage control' in trauma surgery. *Br J Surg* 1993 Dec;80(12):1501-2.
<http://www.ncbi.nlm.nih.gov/pubmed/8298911>

371. Rignault DP. Recent progress in surgery for the victims of disaster, terrorism, and war--Introduction. *World J Surg* 1992 Sep-Oct;16(5):885-7.
<http://www.ncbi.nlm.nih.gov/pubmed/1462624>
372. Rotondo MF, Schwab CW, McGonigal MD, et al. 'Damage control': an approach for improved survival in exsanguinating penetrating abdominal injury. *J Trauma* 1993 Sep;35(3):375-82.
<http://www.ncbi.nlm.nih.gov/pubmed/8371295>
373. Mercer SJ, Whittle CL, Mahoney PF. Lessons from the battlefield: human factors in defence anaesthesia. *Br J Anaesth* 2010 Jul;105(1):9-20.
<http://www.ncbi.nlm.nih.gov/pubmed/20551025>
374. Holcomb JB, Helling TS, Hirshberg A. Military, civilian and rural application of the damage control philosophy. *Mil Med* 2001 Jun;166(6):490-3.
<http://www.ncbi.nlm.nih.gov/pubmed/11413725>
375. Brandes SB, McAninch JW. Renal trauma: a practical guide to evaluation and management. *ScientificWorldJournal* 2004 Jun;4 Suppl 1:31-40.
<http://www.ncbi.nlm.nih.gov/pubmed/15349524>
376. Hirshberg A, Mattox KL. *Top Knife: the Art and Craft of Trauma Surgery*. TFM Publishing Limited 2005, Chapter 7, pp. 107-112.
377. Best CD, Petrone P, Buscarini M, et al. Traumatic ureteral injuries: a single institution experience validating the American Association for the Surgery of Trauma-Organ Injury Scale grading scale. *J Urol* 2005 Apr;173(4):1202-5.
<http://www.ncbi.nlm.nih.gov/pubmed/15758748>
378. Hirshberg A, Wall MJ Jr, Mattox KL. Planned reoperation for trauma: a two year experience with 124 consecutive patients. *J Trauma* 1994 Sep;37(3):365-9.
<http://www.ncbi.nlm.nih.gov/pubmed/8083894>
379. Van der Horst C, Martinez Portillio FJ, Seif C, et al. Male genital injury: diagnostics and treatment. *BJU Int* 2004 May;93(7):927-30.
<http://www.ncbi.nlm.nih.gov/pubmed/15142139>
380. Gross M. Rupture of the testicle: the importance of early surgical treatment. *J Urol* 1969 Feb;101(2):196. [No abstract available]
<http://www.ncbi.nlm.nih.gov/pubmed/5765482>
381. Slater MS, Trunkey DD. Terrorism in America. An evolving threat. *Arch Surg* 1997 Oct;132(10):1059-66.
<http://www.ncbi.nlm.nih.gov/pubmed/9336502>
382. Caro D. Major disasters. *Lancet* 1974 Nov;30;2(7892):1309-10.
<http://www.ncbi.nlm.nih.gov/pubmed/4139541>
383. Weightl JA, Krantz BE, Ali J, et al. *Advanced Trauma Life Support Student Course Manual*. American College of Surgeons Committee on Trauma, 6th edn. Chicago, 1997.
384. *Treating Injury and Illness arising on Military Operations*. National Audit Office. February 2010.
385. Frykberg ER. Medical management of disasters and mass casualties from terrorist bombings: how can we cope? *J Trauma* 2002 Aug;53(2):201-12.
<http://www.ncbi.nlm.nih.gov/pubmed/12169923>
386. Jacobs LM Jr, Ramp JM, Breay JM. An emergency medical system approach to disaster planning. *J Trauma* 1979 Mar;19(3):157-62.
<http://www.ncbi.nlm.nih.gov/pubmed/458880>

7. CONFLICT OF INTEREST

All members of the Urological Trauma Guidelines working group have provided disclosure statements of all relationships that they have that might be perceived as a potential source of a conflict of interest. This information is publically accessible through the European Association of Urology website: <http://www.uroweb.org/guidelines/online-guidelines/>. This guidelines document was developed with the financial support of the European Association of Urology. No external sources of funding and support have been involved. The EAU is a non-profit organisation and funding is limited to administrative assistance and travel and meeting expenses. No honoraria or other reimbursements have been provided.

