

Guidelines on **Testicular Cancer**

P. Albers (chair), W. Albrecht, F. Algaba,
C. Bokemeyer, G. Cohn-Cedermark, K. Fizazi,
A. Horwich, M.P. Laguna, N. Nicolai, J. Oldenburg

TABLE OF CONTENTS

PAGE

1.	BACKGROUND	4
1.1	Methodology	4
1.2	Publication history	5
1.3	Potential conflict of interest statement	5
2.	PATHOLOGICAL CLASSIFICATION	6
3.	DIAGNOSIS	6
3.1	Clinical examination	6
3.2	Imaging of the testis	6
3.3	Serum tumour markers at diagnosis	7
3.4	Inguinal exploration and orchidectomy	7
3.5	Organ-sparing surgery	7
3.6	Pathological examination of the testis	8
3.7	Diagnosis and treatment of testicular intraepithelial neoplasia (TIN)	8
3.8	Screening	8
4.	STAGING	8
4.1	Diagnostic tools	8
4.2	Serum tumour markers: post-orchidectomy half-life kinetics	9
4.3	Retroperitoneal, mediastinal and supraclavicular lymph nodes and viscera	9
4.4	Staging and prognostic classifications	10
4.5	Prognostic risk factors	12
4.6	Impact on fertility and fertility-associated issues	13
5.	GUIDELINES FOR THE DIAGNOSIS AND STAGING OF TESTICULAR CANCER	13
6.	TREATMENT: STAGE I GERM CELL TUMOURS	13
6.1	Stage I seminoma	13
6.1.1	Surveillance	13
6.1.2	Adjuvant chemotherapy	14
6.1.3	Adjuvant radiotherapy	14
6.1.4	Retroperitoneal lymph node dissection (RPLND)	14
6.1.5	Risk-adapted treatment	14
6.2	Guidelines for the treatment of seminoma stage I	15
6.3	NSGCT stage I	15
6.3.1	Surveillance	15
6.3.2	Primary chemotherapy	15
6.3.3	Risk-adapted treatment	16
6.3.4	Retroperitoneal lymph node dissection	16
6.4	CS1S with (persistently) elevated serum tumour markers	17
6.5	Guidelines for the treatment of NSGCT stage I	17
7.	TREATMENT: METASTATIC GERM CELL TUMOURS	19
7.1	Low-volume metastatic disease (stage IIA/B)	19
7.1.1	Stage IIA/B seminoma	19
7.1.2	Stage IIA/B non-seminoma	19
7.2	Advanced metastatic disease	20
7.2.1	Primary chemotherapy	20
7.3	Restaging and further treatment	21
7.3.1	Restaging	21
7.3.2	Residual tumour resection	21
7.3.3	Quality of surgery	22
7.3.4	Consolidation chemotherapy after secondary surgery	22
7.4	Systemic salvage treatment for relapse or refractory disease	22
7.4.1	Late relapse (≥ 2 years after end of first-line treatment)	24
7.5	Salvage surgery	24
7.6	Treatment of brain metastases	24

7.7	Guidelines for the treatment of metastatic germ cell tumours	25
8.	FOLLOW-UP AFTER CURATIVE THERAPY	25
8.1	General considerations	25
8.2	Follow-up: stage I non-seminoma	26
8.2.1	Follow-up investigations during surveillance	26
8.2.2	Follow-up after nerve-sparing RPLND	27
8.2.3	Follow-up after adjuvant chemotherapy	27
8.3	Follow-up: stage I seminoma	27
8.3.1	Follow-up after radiotherapy	27
8.3.2	Follow-up during surveillance	28
8.3.3	Follow-up after adjuvant chemotherapy	28
8.4	Follow-up: stage II and advanced (metastatic) disease	28
9.	TESTICULAR STROMAL TUMOURS	29
9.1	Background	29
9.2	Methods	29
9.3	Classification	29
9.4	Leydig cell tumours	29
9.4.1	Epidemiology	29
9.4.2	Pathology of Leydig cell tumours	30
9.4.3	Diagnosis	30
9.4.4	Treatment	30
9.4.5	Follow-up	30
9.5	Sertoli cell tumour	30
9.5.1	Epidemiology	30
9.5.2	Pathology of Sertoli cell tumours	31
9.5.2.1	Classification	31
9.5.3	Diagnosis	31
9.5.4	Treatment	31
9.5.5	Follow-up	32
9.6	Granulosa cell tumour	32
9.7	Thecoma/fibroma group of tumours	32
9.8	Other sex cord/gonadal stromal tumours	32
9.9	Tumours containing germ cell and sex cord/gonadal stromal (gonadoblastoma)	32
9.10	Miscellaneous tumours of the testis	32
9.10.1	Tumours of ovarian epithelial types	32
9.10.2	Tumours of the collecting ducts and rete testis	32
9.10.3	Tumours (benign and malignant) of non-specific stroma	32
10.	REFERENCES	33
10.1	Germ cell tumours	33
10.2	Non-germ cell tumours	53
11.	ABBREVIATIONS USED IN THE TEXT	55

1. BACKGROUND

Testicular cancer represents between 1% and 1.5% of male neoplasms and 5% of urological tumours in general, with 3-10 new cases occurring per 100,000 males/per year in Western society (1-3). An increase in the incidence of testicular cancer was detected during the 1970s and 1980s, particularly in Northern European countries, and there is a clear trend towards an increased testicular cancer incidence in the last 30 years in the majority of the industrialised countries in North America, Europe and Oceania, although surprising differences in incidence rates are seen between neighbouring countries (4,5). Data from the Surveillance Epidemiology and End Results (SEER) Program during the years 1973 to 1998 show a continuing increased risk among Caucasian men in the USA only for seminoma (6).

Only 1-2% of cases are bilateral at diagnosis. The histological type varies, although there is a clear predominance (90-95%) of germ cell tumours (1). Peak incidence is in the third decade of life for non-seminoma, and in the fourth decade for pure seminoma. Familial clustering has been observed, particularly among siblings (7).

Genetic changes have been described in patients with testicular cancer. A specific genetic marker (an isochromosome of the short arm of chromosome 12 - i(12p) - has been described in all histological types of germ cell tumours (7). Intratubular germ cell neoplasia (testicular intraepithelial neoplasia, TIN) shows the same chromosomal changes, and alterations in the p53 locus have been found in 66% of cases of TIN (8).

A deregulation in the pluripotent programme of foetal germ cells (identified by specific markers such as M2A, C-KIT and OCT4/NANOG) is probably responsible for the development of TIN and germ cell neoplasia. There is overlap in the development to seminoma and embryonal carcinoma as shown by genome-wide expression analysis and detection of alpha-fetoprotein (AFP) mRNA in some atypical seminoma (9,10). Continued genome-wide screening studies and gene expression analysis data suggest testis cancer specific gene mutations on chromosomes 4, 5, 6 and 12 (namely expressing SPRY4, kit-Ligand and Synaptopodin) (11-13).

Epidemiological risk factors for the development of testicular tumours are: a history of cryptorchidism or undescended testis (testicular dysgenesis syndrome), Klinefelter's syndrome, familial history of testicular tumours among first-grade relatives (father/brothers), the presence of a contralateral tumour or TIN, and infertility (14-20). Tallness was associated with a risk of germ cell cancer, although further confirmation is needed (21,22).

Testicular tumours show excellent cure rates. The main factors contributing to this are: careful staging at the time of diagnosis; adequate early treatment based on chemotherapeutic combinations, with or without radiotherapy and surgery; and very strict follow-up and salvage therapies. In the past decades, a decrease in the mean time delay to diagnosis and treatment has been observed (23). In the treatment of testicular cancer, the choice of centre where this treatment is going to be administered is of utmost importance. Although early stages can be successfully treated in a non-reference centre, the relapse rate is higher (24). In poor prognosis non-seminomatous germ cell tumours, it has been shown that overall survival within a clinical trial depended on the number of patients treated at the participating centre (worse < 5 patients enrolled) (25). In the same context, the frequency of post-chemotherapy residual tumour resection is associated with perioperative mortality and overall survival (26,27).

1.1 Methodology

A multidisciplinary team of urologists, medical oncologists, radiotherapists and a pathologist were involved in producing this text, which is based on a structured review of the literature from January 2008 until December 2010 for both the germ cell tumour and non-germ cell sections. Also, data from meta-analyses, Cochrane evidence, and the recommendations of the European Germ Cell Cancer Collaborative Group (EGCCCG) Meeting in Amsterdam in November 2006 have been included (28-31). A validation scoping search with a focus on the available level 1 (systematic reviews and meta-analyses of randomised controlled trials [RCTs]) data was carried out in Medline and Embase on the Dialog-Datastar platform, covering a time frame of 2009 through September 2010. The searches used the controlled terminology of the respective databases. Both MeSH and Emtree were analysed for relevant terms.

References used in the text have been assessed according to their level of scientific level of evidence (LE) (Table 1), and guidelines have been given a grade of recommendation (GR) (Table 2) according to the Oxford Centre for Evidence-based Medicine Levels of Evidence (32). The aim of grading recommendations is to provide transparency between the underlying evidence and the recommendation given.

Table 1: Level of evidence*

Level	Type of evidence
1a	Evidence obtained from meta-analysis of randomised trials
1b	Evidence obtained from at least one randomised trial
2a	Evidence obtained from one well-designed controlled study without randomisation
2b	Evidence obtained from at least one other type of well-designed quasi-experimental study
3	Evidence obtained from well-designed non-experimental studies, such as comparative studies, correlation studies and case reports
4	Evidence obtained from expert committee reports or opinions or clinical experience of respected authorities

* Modified from Sackett et al. (32).

It should be noted that when recommendations are graded, the link between the LE and GR is not directly linear. Availability of RCTs may not necessarily translate into a GR: A where there are methodological limitations or disparity in published results.

Alternatively, absence of high LE does not necessarily preclude a GR: A, if there is overwhelming clinical experience and consensus. In addition, there may be exceptional situations where corroborating studies cannot be performed, perhaps for ethical or other reasons and in this case unequivocal recommendations are considered helpful for the reader. The quality of the underlying scientific evidence - although a very important factor - has to be balanced against benefits and burdens, values and preferences and cost when a grade is assigned (33-35).

The European Association of Urology Guidelines Office do not perform cost assessments, nor can they address local/national preferences in a systematic fashion. But whenever this data is available, the expert panels will include the information.

Table 2: Grade of recommendation*

Grade	Nature of recommendations
A	Based on clinical studies of good quality and consistency addressing the specific recommendations and including at least one randomised trial
B	Based on well-conducted clinical studies, but without randomised clinical trials
C	Made despite the absence of directly applicable clinical studies of good quality

*Modified from Sackett et al. (32).

1.2 Publication history

The content of these guidelines has not changed with respect to the previous version, but for assessing the currency of the references used; replacing old references by more recent publications. This resulted in the inclusion of 5 new references. No changes in the recommendations were made. The EAU published a first guideline on Testicular Cancer in 2001 with limited updates achieved in 2002, 2004, a major update in 2005, followed by limited updates in 2008, 2009 and 2010. Review papers have been published in the society scientific journal *European Urology*, the latest version dating to 2011 (36). Since 2008, the Testicular Guidelines contain a separate chapter on testicular stromal tumours.

A quick reference document presenting the main findings of the Testicular Cancer guidelines is also available, following the large text updates. All texts can be viewed and downloaded for personal use at the EAU website: <http://www.uroweb.org/guidelines/online-guidelines/>.

1.3 Potential conflict of interest statement

The expert panel have submitted potential conflict of interest statements which can be viewed on the EAU website: <http://www.uroweb.org/guidelines/>.

2. PATHOLOGICAL CLASSIFICATION

The recommended pathological classification (modified from the 2004 version of the World Health Organization [WHO] guidance) is shown below (37).

1. **Germ cell tumours**
 - Intratubular germ cell neoplasia, unclassified type (IGCNU)
 - Seminoma (including cases with syncytiotrophoblastic cells)
 - Spermatocytic seminoma (mention if there is sarcomatous component)
 - Embryonal carcinoma
 - Yolk sac tumour
 - Choriocarcinoma
 - Teratoma (mature, immature, with malignant component)
 - Tumours with more than one histological type (specify percentage of individual components).
2. **Sex cord/gonadal stromal tumours**
 - Leydig cell tumour
 - Malignant Leydig cell tumour
 - Sertoli cell tumour
 - lipid-rich variant
 - sclerosing
 - large cell calcifying
 - Malignant Sertoli cell tumour
 - Granulosa cell tumour
 - adult type
 - juvenile type
 - Thecoma/fibroma group of tumours
 - Other sex cord/gonadal stromal tumours
 - incompletely differentiated
 - mixed
 - Tumours containing germ cell and sex cord/gonadal stromal (gonadoblastoma).
3. **Miscellaneous non-specific stromal tumours**
 - Ovarian epithelial tumours
 - Tumours of the collecting ducts and rete testis
 - Tumours (benign and malignant) of non-specific stroma.

3. DIAGNOSIS

3.1 Clinical examination

Testicular cancer generally affects young men in their third or fourth decade of life. It normally appears as a painless, unilateral mass in the scrotum or the casual finding of an intrascrotal mass (38). In ~20% of cases, the first symptom is scrotal pain, and up to 27% of patients with testicular cancer may have local pain (1).

Occasionally, trauma to the scrotum may reveal the presence of a testicular mass. Gynaecomastia appears in 7% of cases and is more common in non-seminomatous tumours. Back and flank pain are present in about 11% of cases (1).

In about 10% of cases, a testicular tumour can mimic an orchioepididymitis, with consequent delay of the correct diagnosis (1,2). Ultrasound (US) must be performed in any doubtful case. Physical examination reveals the features of the mass and must always be carried out in conjunction with a general examination in order to find possible (supraclavicular) distant metastases, a palpable abdominal mass or gynaecomastia. A correct diagnosis must be established in all patients with an intrascrotal mass (39).

3.2 Imaging of the testis

Currently, diagnostic US serves to confirm the presence of a testicular mass and to explore the contralateral testis. Its sensitivity in detecting a testicular tumour is almost 100%, and it has an important role in determining whether a mass is intra- or extratesticular (40). Ultrasound is an inexpensive test and should be performed even in the presence of a testicular tumour that is clinically evident (41).

Ultrasound of the testis has to be performed in young men without a palpable testicular mass who have retroperitoneal or visceral masses or elevated serum human chorionic gonadotrophin (hCG) or AFP or in men consulting for fertility problems (42-44).

Ultrasound may be recommended in the follow-up of patients at risk (45), when other risk factors than microlithiasis are present (e.g. size < 12 ml or atrophy, inhomogeneous parenchyma). Solely, the presence of microlithiasis is not an indication for a regular scrotal US (46).

In the absence of other risk factors (< 12 ml (atrophy), maldescent testis), testicular microlithiasis is not an indication for biopsy or further US screening (45,47).

Magnetic resonance imaging (MRI) offers higher sensitivity and specificity than US for diagnosing tumours (40,48). MRI of the scrotum offers a sensitivity of 100% and a specificity of 95-100% (49), but its high cost does not justify its use for diagnosis.

3.3 Serum tumour markers at diagnosis

Serum tumour markers are prognostic factors and contribute to diagnosis and staging (50). The following markers should be determined:

- AFP (produced by yolk sac cells);
- hCG (expression of trophoblasts);
- LDH (lactate dehydrogenase).

In all tumours, there is an increase in these markers in 51% of cases of testicular cancer (23,38). Alphafetoprotein increases in 50-70% of patients with non-seminomatous germ cell tumour (NSGCT), and a rise in hCG is seen in 40-60% of patients with NSGCT. About 90% of non-seminomatous tumours present with a rise in one or two of the markers. Up to 30% of seminomas can present or develop an elevated hCG level during the course of the disease (51,52).

Lactate dehydrogenase is a less specific marker, and its concentration is proportional to tumour volume. Its level may be elevated in 80% of patients with advanced testicular cancer (51). It should be noted that negative marker levels do not exclude the diagnosis of a germ cell tumour. Other markers studied include placental alkaline phosphatase (PLAP), which may be of value in monitoring patients with pure seminoma. Cytogenetic and molecular markers are available in specific centres, but at present only contribute to research studies. Measurement of serum AFP, hCG and LDH is mandatory, while that of PLAP is optional.

3.4 Inguinal exploration and orchidectomy

Every patient with a suspected testicular mass must undergo inguinal exploration with exteriorisation of the testis within its tunics. Orchidectomy with division of the spermatic cord at the internal inguinal ring must be performed if a malignant tumour is found. If the diagnosis is not clear, a testicular biopsy (an enucleation of the intraparenchymal tumour) is taken for frozen (fresh tissue) section histological examination.

In cases of disseminated disease and life-threatening metastases, it is current practice to start with up-front chemotherapy, and orchidectomy may be delayed until clinical stabilisation has occurred.

3.5 Organ-sparing surgery

Although organ-sparing surgery is not indicated in the presence of non-tumoural contralateral testis, it can be attempted in special cases with all the necessary precautions.

In synchronous bilateral testicular tumours, metachronous contralateral tumours, or in a tumour in a solitary testis with normal pre-operative testosterone levels, organ preserving surgery can be performed when the tumour volume is less than 30% of the testicular volume and surgical rules are respected. In those cases, the rate of associated TIN is high (at least up to 82%), and all patients must be treated with adjuvant radiotherapy (16-20 Gy) at some point (53).

Infertility will result after radiotherapy and the risk of long-term Leydig cell insufficiency after radiotherapy of a solitary testis is increased (54). Radiation treatment may be delayed in fertile patients who wish to father children. The option must be carefully discussed with the patient and surgery performed in a centre with experience (55,56).

3.6 Pathological examination of the testis

Mandatory pathological requirements:

- Macroscopic features: side, testis size, maximum tumour size, and macroscopic features of epididymis, spermatic cord, and tunica vaginalis.
- Sampling: a 1 cm² section for every centimetre of maximum tumour diameter, including normal macroscopic parenchyma (if present), albuginea and epididymis, with selection of suspected areas. At least one proximal and one distal section of spermatic cord plus any suspected area.
- Microscopic features and diagnosis: histological type (specify individual components and estimate amount as percentage) according to WHO 2004 (37):
 - presence or absence of peri-tumoural venous and/or lymphatic invasion;
 - presence or absence of albuginea, tunica vaginalis, rete testis, epididymis or spermatic cord invasion;
 - presence or absence of intratubular germ cell neoplasia (TIN) in non-tumour parenchyma intratubular germ cell neoplasia.
- pT category according to Tumour Node Metastasis (TNM) 2009 (57).
- Immunohistochemical studies: in seminoma and mixed germ cell tumour, AFP and hCG.

Advisable immunohistochemical markers, in cases of doubt, are:

- in seminoma: cytokeratins (CAM 5.2), PLAP, c-kit;
- in intratubular germ cell neoplasia: PLAP, c-kit;
- other advisable markers: chromogranine A (Cg A), Ki-1 (MIB-1).

3.7 Diagnosis and treatment of testicular intraepithelial neoplasia (TIN)

Contralateral biopsy has been advocated to rule out the presence of TIN (58). Although this is routine policy in some countries, the low incidence of TIN and contralateral metachronous testicular tumours (up to 9% and approximately 2.5%, respectively) (59,60), the morbidity of TIN treatment, and the fact that most of these metachronous tumours are at a low stage at presentation make it controversial to recommend a systematic contralateral biopsy in all patients (61-63). It is still difficult to reach a consensus on whether the existence of contralateral TIN must be identified in all cases. However, biopsy of the contralateral testis should be offered to high-risk patients for contralateral TIN with a testicular volume of < 12 mL, a history of cryptorchidism, or poor spermatogenesis (Johnson Score 1-3). A contralateral biopsy is not necessary in patients > 40 years (64-69). A double biopsy is preferred to increase sensitivity (66).

Once TIN is diagnosed, local radiotherapy (16-20 Gy in fractions of 2 Gy) is the treatment of choice in solitary testis. Because this may produce infertility, the patient must be carefully counselled before treatment commences (61,70). In addition to infertility, Leydig cell function and testosterone production may be impaired long-term following radiotherapy for TIN (55). Radiation treatment may be delayed in fertile patients who wish to father children (66). Patients have to be informed that a testicular tumour may arise in spite of a negative biopsy (71).

If TIN is diagnosed and the contralateral testis is healthy, the options for management are orchidectomy or close observation (with a risk of 50% in 5 years to develop a testicular cancer) (72).

3.8 Screening

Although there are no surveys proving the advantages of screening programmes, it has been demonstrated that stage and prognosis are directly related to early diagnosis. In the presence of clinical risk factors, self physical examination by the affected individual is advisable.

4. STAGING

4.1 Diagnostic tools

To determine the presence of metastatic or occult disease, the half-life kinetics of serum tumour markers must be assessed, the nodal pathway must be screened, and the presence of visceral metastases ruled out.

Consequently, it is mandatory to assess:

- the post-orchidectomy half-life kinetics of serum tumour markers;
- the status of retroperitoneal and supraclavicular lymph nodes, and the liver;
- the presence or absence of mediastinal nodal involvement and lung metastases;
- the status of brain and bone, if any suspicious symptoms are present.

The mandatory tests are:

- serial blood sampling;
- abdominopelvic and chest computed tomography (CT).

4.2 Serum tumour markers: post-orchidectomy half-life kinetics

The mean serum half-life of AFP and hCG is 5-7 days and 2-3 days, respectively (51). Tumour markers have to be re-evaluated after orchidectomy to determine half-life kinetics. Marker decline in patients with clinical stage I disease should be assessed until normalisation has occurred. Markers before start of chemotherapy are important to classify the patient according to the International Germ Cell Cancer Collaborative Group (IGCCCG) risk classification. The persistence of elevated serum tumour markers after orchidectomy might indicate the presence of metastatic disease (macro- or microscopically), while the normalisation of marker levels after orchidectomy does not rule out the presence of tumour metastases. During chemotherapy, the markers should decline; persistence has an adverse prognostic value.

4.3 Retroperitoneal, mediastinal and supraclavicular lymph nodes and viscera

Retroperitoneal and mediastinal lymph nodes are best assessed by means of a CT. The supraclavicular nodes are best assessed by physical examination.

Abdominopelvic CT offers a sensitivity of 70-80% in determining the state of the retroperitoneal nodes. Its accuracy depends on the size of the nodes; sensitivity and the negative predictive value increase using a 3 mm threshold to define metastatic nodes in the landing zones (69). Those figures decrease slightly in stages I and II (70,73), with a rate of understaging of 25-30% (74). New generations of CT devices do not seem to improve the sensitivity.

Magnetic resonance imaging (MRI) produces similar results to CT in the detection of retroperitoneal nodal enlargement (75,76). Again, the main objections to its routine use are its high cost and limited availability. Nevertheless, MRI can be helpful when abdominopelvic CT or US are inconclusive (75), when CT is contraindicated because of allergy to contrast media, or when the physician or the patient are concerned about radiation dose. MRI is an optional test, and there are currently no indications for its systematic use in the staging of testicular cancer.

A chest CT is the most sensitive way to evaluate the thorax and mediastinal nodes. This exploration has to be recommended in all patients with testicular cancer because up to 10% of cases can present with small subpleural nodes that are not visible radiologically (77). A CT has high sensitivity but low specificity (75).

There is no evidence to support the use of the fluorodeoxyglucose (FDG)-PET in the staging of testis cancer (78,79). It is recommended in the follow-up of patients with seminoma with any residual mass at least 6 weeks after chemotherapy in order to decide on watchful waiting or active treatment (80-83). The use of FDG-PET is not recommended in the re-staging of patients with non-seminomatous tumours after chemotherapy (84,85).

Other examinations, such as brain or spinal CT, bone scan or liver US, should be performed if there is suspicion of metastases to these organs. A CT or MRI of the skull is advisable in patients with NSGCT and multiple lung metastases and poor prognosis IGCCCG risk group. Table 3 shows the recommended tests at staging.

Table 3: Recommended tests for staging at diagnosis

Test	Recommendation	GR
Serum tumour markers	AFP hCG LDH	A
Abdominopelvic CT	All patients	A
Chest CT	All patients	A
Testis US (bilateral)	All patients	A
Bone scan	In case of symptoms	
Brain scan (CT/MRI)	In case of symptoms and patients with metastatic disease with multiple lung metastases and high beta-hCG values	

Further investigations	
Fertility investigations: Total testosterone LH FSH Semen analysis	B
Sperm banking should be offered	A

AFP = Alpha fetoprotein; hCG = human chorionic gonadotrophin; LDH = lactate dehydrogenase; CT = computed tomography; LH = luteinising hormone; FSH = follicle-stimulating hormone; MRI = Magnetic Resonance Imaging; US = Ultrasound.

4.4 Staging and prognostic classifications

The staging system recommended in these guidelines is the 2009 TNM of the International Union Against Cancer (UICC) (Table 4) (57). This includes:

- determination of the anatomical extent of disease;
- assessment of serum tumour markers, including nadir values of hCG, AFP and LDH after orchidectomy (S category);
- clear definition of regional nodes;
- some N-category modifications related to node size.

Table 4: TNM classification for testicular cancer (UICC, 2009, 7th edn [57])

pT	Primary tumour¹
pTX	Primary tumour cannot be assessed (see note 1)
pT0	No evidence of primary tumour (e.g. histological scar in testis)
pTis	Intratubular germ cell neoplasia (testicular intraepithelial neoplasia)
pT1	Tumour limited to testis and epididymis without vascular/lymphatic invasion: tumour may invade tunica albuginea but not tunica vaginalis
pT2	Tumour limited to testis and epididymis with vascular/lymphatic invasion, or tumour extending through tunica albuginea with involvement of tunica vaginalis
pT3	Tumour invades spermatic cord with or without vascular/lymphatic invasion
pT4	Tumour invades scrotum with or without vascular/lymphatic invasion
N	Regional lymph nodes clinical
NX	Regional lymph nodes cannot be assessed
N0	No regional lymph node metastasis
N1	Metastasis with a lymph node mass 2 cm or less in greatest dimension or multiple lymph nodes, none more than 2 cm in greatest dimension
N2	Metastasis with a lymph node mass more than 2 cm but not more than 5 cm in greatest dimension, or multiple lymph nodes, any one mass more than 2 cm but not more than 5 cm in greatest dimension
N3	Metastasis with a lymph node mass more than 5 cm in greatest dimension
pN	Pathological
pNX	Regional lymph nodes cannot be assessed
pN0	No regional lymph node metastasis
pN1	Metastasis with a lymph node mass 2 cm or less in greatest dimension and 5 or fewer positive nodes, none more than 2 cm in greatest dimension
pN2	Metastasis with a lymph node mass more than 2 cm but not more than 5 cm in greatest dimension; or more than 5 nodes positive, none more than 5 cm; or evidence of extranodal extension of tumour
pN3	Metastasis with a lymph node mass more than 5 cm in greatest dimension
M	Distant metastasis
MX	Distant metastasis cannot be assessed
M0	No distant metastasis
M1	Distant metastasis
M1a	Non-regional lymph node(s) or lung
M1b	Other sites
S	Serum tumour markers
Sx	Serum marker studies not available or not performed
S0	Serum marker study levels within normal limits

		LDH (U/l)	hCG (mIU/mL)	AFP (ng/mL)
	S1	< 1.5 x N and	< 5,000 and	< 1,000
	S2	1.5-10 x N or	5,000-50,000 or	1,000-10,000
	S3	> 10 x N or	> 50,000 or	> 10,000

N indicates the upper limit of normal for the LDH assay.

LDH = lactate dehydrogenase; hCG = human chorionic gonadotrophin; AFP = alpha-fetoprotein.

¹Except for pTis and pT4, where radical orchidectomy is not always necessary for classification purposes, the extent of the primary tumour is classified after radical orchidectomy; see pT. In other circumstances, TX is used if no radical orchidectomy has been performed.

According to the 2009 TNM classification, stage I testicular cancer includes the following substages:

Stage grouping

Stage 0	pTis	N0	M0	S0,SX
Stage I	pT1-T4	N0	M0	SX
Stage IA	pT1	N0	M0	S0
Stage IB	pT2 - pT4	N0	M0	S0
Stage IS	Any patient/TX	N0	M0	S1-3
Stage II	Any patient/TX	N1-N3	M0	SX
Stage IIA	Any patient/TX	N1	M0	S0
	Any patient/TX	N1	M0	S1
Stage IIB	Any patient/TX	N2	M0	S0
	Any patient/TX	N2	M0	S1
Stage IIC	Any patient/TX	N3	M0	S0
	Any patient/TX	N3	M0	S1
Stage III	Any patient/TX	Any N	M1a	SX
Stage IIIA	Any patient/TX	Any N	M1a	S0
	Any patient/TX	Any N	M1a	S1
Stage IIIB	Any patient/TX	N1-N3	M0	S2
	Any patient/TX	Any N	M1a	S2
Stage IIIC	Any patient/TX	N1-N3	M0	S3
	Any patient/TX	Any N	M1a	S3
	Any patient/TX	Any N	M1b	Any S

Stage IA patients have primary tumours limited to the testis and epididymis, with no evidence of microscopic vascular or lymphatic invasion by tumour cells on microscopy, no sign of metastases on clinical examination or imaging, and post-orchidectomy serum tumour marker levels within normal limits. Marker decline in patients with clinical stage I disease should be assessed until normalisation. Stage IB patients have a more locally invasive primary tumour, but no sign of metastatic disease. Stage IS patients have persistently elevated (and usually increasing) serum tumour marker levels after orchidectomy, which is evidence of subclinical metastatic disease (or possibly a second germ cell tumour in the remaining testis). If serum tumour marker levels are declining according to the expected half-life decay after orchidectomy, the patient is usually followed up until normalisation.

In large population-based patient series, 75-80% of seminoma patients, and about 55% of patients with NSGCT cancer have stage I disease at diagnosis (86,87). True stage IS (persistently elevated or increasing serum marker levels after orchidectomy) is found in about 5% of non-seminoma patients. If a staging retroperitoneal lymph node dissection (RPLND) was to be performed in stage IS patients, nearly all patients would be found to have pathological stage II disease (pN+) (1,7,86,88).

In 1997, the IGCCCG defined a prognostic factor-based staging system for metastatic testis tumour based on identification of some clinical independent adverse factors. This staging system has been incorporated

into the TNM Classification and uses histology, location of the primary tumour, location of metastases and prechemotherapy marker levels in serum as prognostic factors to categorise patients into 'good', 'intermediate' or 'poor' prognosis (Table 5) (89).

Table 5: Prognostic-based staging system for metastatic germ cell cancer (International Germ Cell Cancer Collaborative Group)*

Good-prognosis group	
<i>Non-seminoma (56% of cases)</i> 5-year PFS 89% 5-year survival 92%	<i>All of the following criteria:</i> <ul style="list-style-type: none"> • Testis/retroperitoneal primary • No non-pulmonary visceral metastases • AFP < 1,000 ng/mL • hCG < 5,000 IU/L (1,000 ng/mL) • LDH < 1.5 x ULN
<i>Seminoma (90% of cases)</i> 5-year PFS 82% 5-year survival 86%	<i>All of the following criteria:</i> <ul style="list-style-type: none"> • Any primary site • No non-pulmonary visceral metastases • Normal AFP • Any hCG • Any LDH
Intermediate prognosis group	
<i>Non-seminoma (28% of cases)</i> 5 years PFS 75% 5-year survival 80%	<ul style="list-style-type: none"> • Testis/retroperitoneal primary • No non-pulmonary visceral metastases • AFP 1,000 - 10,000 ng/mL or • hCG 5,000 - 50,000 IU/L or • LDH 1.5 - 10 x ULN
<i>Seminoma (10% of cases)</i> 5-year PFS 67% 5-year survival 72%	<i>All of the following criteria:</i> <ul style="list-style-type: none"> • Any primary site • Non-pulmonary visceral metastases • Normal AFP • Any hCG • Any LDH
Poor prognosis group	
<i>Non-seminoma (16% of cases)</i> 5-year PFS 41% 5-year survival 48%	<i>Any of the following criteria:</i> <ul style="list-style-type: none"> • Mediastinal primary • Non-pulmonary visceral metastases • AFP > 10,000 ng/mL or • hCG > 50,000 IU/L (10,000 ng/mL) or • LDH > 10 x ULN
<i>Seminoma</i>	No patients classified as poor prognosis

*Pre-chemotherapy serum tumour markers should be assessed immediately prior to the administration of chemotherapy (same day).

PFS = progression-free survival; AFP = alpha-fetoprotein; hCG = human chorionic gonadotrophin; LDH = lactate dehydrogenase.

4.5 Prognostic risk factors

Retrospectively, for seminoma stage I, tumour size (> 4 cm) and invasion of the rete testis have been identified as predictors for relapse in a pooled analysis (29). However, these risk factors have not been validated in a prospective setting except that the absence of both factors indicated a low recurrence rate (6%) (90).

For non-seminoma stage I, vascular or lymphatic invasion of the primary tumour is the most important predictor of occult metastatic disease. The proliferation rate, as well as the percentage of embryonal carcinoma, are additional predictors that improve upon the positive and negative predictive value of vascular invasion (91,92).

The significant prognostic pathological risk factors for stage I and clinical risk factors for metastatic disease are listed in Table 6.

Table 6: Prognostic factors for occult metastatic disease in testicular cancer

	For seminoma	For non-seminoma
Pathological (for stage I)		
Histopathological type	<ul style="list-style-type: none"> • Tumour size (> 4 cm) • Invasion of the rete testis 	<ul style="list-style-type: none"> • vascular/lymphatic invasion of the primary tumour • Proliferation rate > 70% • Percentage of embryonal carcinoma > 50%
Clinical (for metastatic disease)		
<ul style="list-style-type: none"> • Primary location • Elevation of tumour marker levels • Presence of non-pulmonary visceral metastasis 		

4.6 Impact on fertility and fertility-associated issues

Sperm abnormalities are frequently found in patients with testis tumours. Furthermore, chemotherapy and radiation treatment can also impair fertility. In patients in the reproductive age group, pre-treatment fertility assessment (testosterone, luteinising hormone [LH] and FSH levels) should be performed, and semen analysis and cryopreservation should be offered. If cryopreservation is desired, it should preferably be performed before orchidectomy, but in any case prior to chemotherapy treatment (54,93-99).

In cases of bilateral orchidectomy or low testosterone levels after treatment of TIN, life-long testosterone supplementation is necessary (100). Patients with unilateral or bilateral orchidectomy should be offered a testicular prosthesis (101). For more detailed information, the reader is referred to the EAU Male Infertility Guidelines (102).

5. GUIDELINES FOR THE DIAGNOSIS AND STAGING OF TESTICULAR CANCER

	GR
Testicular US is a mandatory assessment	A
Orchidectomy and pathological examination of the testis are necessary to confirm the diagnosis and to define the local extension (pT category). In a life-threatening situation due to extensive metastasis, chemotherapy must be started before orchidectomy.	A
Serum determination of tumour markers (AFP, hCG, and LDH) must be performed both before and 5-7 days after orchidectomy for staging and prognostic reasons	A
The state of the retroperitoneal, mediastinal and supraclavicular nodes and viscera must be assessed in testicular cancer.	A

AFP = *alpha-fetoprotein*; hCG = *human chorionic gonadotrophin*; LDH = *lactate dehydrogenase*;
US = *Ultrasound*.

6. TREATMENT: STAGE I GERM CELL TUMOURS

6.1 Stage I seminoma

After modern staging procedures, about 15-20% of stage I seminoma patients have subclinical metastatic disease, usually in the retroperitoneum, and will relapse after orchidectomy alone.

6.1.1 Surveillance

Several prospective non-randomised surveillance studies have been conducted during the past decade, the largest study from Canada with > 1,500 patients (103). Previous analysis from four studies showed an actuarial 5 years' relapse-free rate of 82.3%. The Princess Margaret Hospital series (n = 1559) showed an overall relapse

rate in unselected patients of 16.8%. The actuarial relapse rate is in the order of 15-20% at 5 years, and most of the relapses are first detected in infra-diaphragmatic lymph nodes (104).

In patients with low risk (tumour size \leq 4 cm and no rete testis invasion) the recurrence under surveillance is as low as 6% (105).

Chemotherapy, according to the IGCCCG classification, is a possible treatment for seminoma relapse under surveillance. However, 70% of patients with relapse are suitable for treatment with radiotherapy alone because of small volume disease at the time of recurrence. Patients who relapse again can be effectively treated with chemotherapy (106).

The overall cancer-specific survival rate reported under surveillance performed by experienced centres is 97-100% for seminoma stage I (104,106). The main drawback of surveillance is the need for more intensive follow-up, especially with repeated imaging examinations of the retroperitoneal lymph nodes, for at least 5 years after orchidectomy. This compares with the very low risk of subdiaphragmatic relapse after adjuvant radiotherapy.

There is a small but clinically significant risk of relapse more than 5 years after orchidectomy for stage I seminoma, which supports the need for long term surveillance.

6.1.2 Adjuvant chemotherapy

A joint trial by the Medical Research Council (MRC) and the European Organisation for Research and Treatment of Cancer (EORTC) (MRC TE 19 trial), which compared one cycle of carboplatin (area under curve [AUC] 7) with adjuvant radiotherapy, did not show a significant difference with regard to recurrence rate, time to recurrence and survival after a median follow-up of 4 years (107-109). Therefore, adjuvant carboplatin therapy using a dosage of one course AUC 7 is an alternative to radiotherapy or surveillance in stage I seminoma (104,107-109). Two courses of adjuvant carboplatin seem to further reduce the relapse rate to the order of 1-3% (110,111), but further experience and long-term observation are needed.

6.1.3 Adjuvant radiotherapy

Seminoma cells are extremely radiosensitive. Adjuvant radiotherapy to a para-aortic (PA) field or to a hockeystick field (para-aortic and ipsilateral iliac nodes), with moderate doses (total 20-24 Gy), will reduce the relapse rate to 1-3% (112-115). After modern radiotherapy, nearly all relapses will first occur outside the irradiated field (supradiaphragmatic lymph nodes or in the lungs) (112-115). Based on the results of a large randomised MRC trial, Fossa et al. (112,113) recommended radiotherapy to a PA field as standard treatment for patients with testicular seminoma stage I, T1-T3 and with undisturbed lymphatic drainage. Acute toxicity was reduced and the sperm count within the first 18 months was significantly higher after PA irradiation than after irradiation of the traditional dog-leg field. On the other hand, the relapse rate in the iliac lymph nodes was about 2% (all of them on the right side) after PA and 0% after dog-leg irradiation. Another possible site of failure is in the left renal hilum. PA irradiation should be tailored according to the site of the primary tumour. Adjuvant irradiation of supradiaphragmatic lymph nodes is not indicated in seminoma stage I.

With regard to the irradiation dose, the MRC recently finished a large randomised trial of 20 Gy versus 30 Gy PA radiation in stage I seminoma that showed equivalence for both doses in terms of recurrence rates (113). The rate of severe radiation-induced long-term toxicity is $<$ 2%. Moderate chronic gastrointestinal (GI) side-effects are seen in ~5% of patients, and moderate acute GI toxicity in ~60% (112). The main concern surrounding adjuvant radiotherapy is the increased risk of radiation-induced second non-germ cell malignancies (116-120).

A scrotal shield can be of benefit during adjuvant radiotherapy in order to prevent scattered radiation toxicity in the contralateral testis (119).

6.1.4 Retroperitoneal lymph node dissection (RPLND)

In a prospective, non-randomised study comparing radiotherapy and RPLND in stage I seminoma, there was a trend towards a higher incidence of retroperitoneal relapses (9.5%) after RPLND as primary treatment. Therefore, this policy should not be recommended in stage I seminoma (121).

6.1.5 Risk-adapted treatment

Using tumour size $>$ 4 cm and rete testis invasion, patients with seminoma stage I may be subdivided into a low- and high-risk group of occult metastatic disease. Patients with and without both risk factors have a risk of occult disease of 32% and 12%, respectively. These risk factors were introduced by an analysis of retrospective trials (29). A prospective trial based on these risk factors (no risk factors: surveillance; both risk

factors: two courses of carboplatin AUC 7) showed the feasibility of a risk-adapted approach. Early data with limited follow-up indicate that patients without either risk factor have a 6.0% risk of relapse at 5 years. Patients in the high risk group treated with carboplatin experienced a 1.4% relapse rate at mean follow-up of 34 months (122).

However, given the fact that cure is achieved in ~100% in patients with stage I seminoma whatever therapy used (adjuvant radiotherapy, adjuvant chemotherapy, or surveillance) and that the relapse rate in large surveillance series not using risk factors is ~15-20%, indicates a risk of over-treatment.

Therefore, the therapeutic decision should be shared with an informed patient.

6.2 Guidelines for the treatment of seminoma stage I

	GR
Surveillance is the recommended management option (if facilities available and patient compliant).	A*
Carboplatin-based chemotherapy (one course at AUC 7) is recommended.	B
Adjuvant treatment is not recommended for patients at very low risk.	A
Radiotherapy is not recommended as adjuvant treatment.	A

**Upgraded following panel consensus.*

6.3 NSGCT stage I

Up to 30% of NSGCT patients with clinical stage I (CS1) disease have subclinical metastases and will relapse if surveillance alone is applied after orchidectomy.

6.3.1 Surveillance

Improvements in clinical staging and follow-up methods, and the availability of effective salvage treatment with cisplatin-based chemotherapy and post-chemotherapy surgery, have led to studies of only close surveillance after orchidectomy in CS1 NSGCT patients. The largest reports of the surveillance strategy indicate a cumulative relapse rate of ~30%, with 80% of relapses occurring during the first 12 months of follow-up, 12% during the second year and 6% during the third year, decreasing to 1% during the fourth and fifth years, and occasionally even later (123-127). About 35% of relapsing patients have normal levels of serum tumour markers at relapse. About 60% of relapses are in the retroperitoneum. Despite very close follow-up, 11% of relapsing patients presented with large-volume recurrent disease.

The somewhat lower relapse rates reported from surveillance studies compared with some series of patients staged by RPLND (128) can be explained by the fact that some patients (presumably at risk) are excluded once surveillance is advised. Based on the overall cancer-specific survival data, surveillance within an experienced surveillance programme may be offered to patients with non-risk stratified clinical stage I non-seminoma as long as they are compliant and informed about the expected recurrence rate as well as the salvage treatment (129,130).

6.3.2 Primary chemotherapy

Several studies involving two courses of chemotherapy with cisplatin, etoposide and bleomycin (PEB) as primary treatment for high-risk patients (having ~50% risk of relapse) have been reported (131-136). In these series, involving > 200 patients, some with a median follow-up of nearly 8 years (131), a relapse rate of only 2.7% was reported, with very little long-term toxicity. Two cycles of cisplatin-based adjuvant chemotherapy do not seem to adversely affect fertility or sexual activity (137). However, the very-long term (> 20 years) side effects of adjuvant chemotherapy in this setting are currently unknown, and this should be taken in consideration for decision-making; especially the long-term cardio-vascular effects of chemotherapy in GCT survivors (138).

It is important to be aware of slow-growing retroperitoneal teratomas after primary chemotherapy (139).

The results of cost analyses comparing surveillance, RPLND and primary chemotherapy show different results among the reported studies, possibly because of differences in intensity and costs related to follow-up procedures (140). With a low frequency of follow-up CTs (a surveillance strategy which has been proven to be effective in non-seminoma CS1), the costs of follow-up can be considerably reduced (141).

6.3.3 **Risk-adapted treatment**

Risk-adapted treatment is based on the risk factor vascular invasion. Stratifying patients with CS1 NSGCT according to their presumed risk of relapse is a rational option, as several studies have reported similar survival rates and a final cure rate close to 100% with all available treatment options using the risk-stratifying approach (131-136,142-145). Risk-adapted treatment is therefore an equally effective alternative treatment of choice in CS1 NSGCT.

If the risk-adapted policy is applied, patients with vascular invasion are recommended to undergo adjuvant chemotherapy with two cycles of PEB, and patients without vascular invasion are recommended to undergo surveillance. Only if patients or doctors are not willing to accept the consequent risk-adapted treatment, or if there are circumstances that militate against the risk-adapted treatment option, should the remaining treatments be considered.

Thus, the decision about treatment should be based on a thorough discussion with the patient, taking into account the described advantages and disadvantages, as well as the individual situation of the patient and/or the treatment centre. The Swedish-Norwegian Testicular Cancer Project (SWENOTECA) recently showed that in a large population-based study with a risk-adapted approach within a management programme and a median follow-up of 4.7 years, the relapse rate was 3.2% for patients with vascular invasion treated with only one adjuvant PEB (146). Taken together, ~300 patients with high-risk CS I have been adjuvantly treated with 1 x PEB with a follow-up of > 5 yrs. As long as 1 x PEB has not been proven superior or at least equivalent to 2 courses PEB, this adjuvant treatment cannot be recommended outside of a clinical trial or a prospective registry.

6.3.4 **Retroperitoneal lymph node dissection**

If RPLND is performed, ~30% of patients are found to have retroperitoneal lymph node metastases, which corresponds to pathological stage II (PS2) disease (147-149). If no retroperitoneal metastases are found at RPLND (PS1), ~10% of the PS1 patients relapse at distant sites (92,129,150-152).

The main predictor of relapse in CS1 NSGCT managed by surveillance, for having PS2 disease and for relapse in PS1 after RPLND, is histopathological evidence of vascular invasion by tumour cells in, or near, the primary tumour in the testis (92,124,129,152,153). The presence of vascular invasion seems to be a very robust parameter, and is clinically usable even without centralised review by an expert panel (143,152). Vascular invasion was the most predictive of stage in a multifactorial analysis. The absence of vascular invasion has a negative predictive value of 77%, thus allowing for surveillance in low-risk compliant patients (92).

Patients without vascular invasion constitute ~50-70% of the CS1 population, and these patients have only a 15-20% risk of relapse on surveillance, compared with a 50% relapse rate in patients with vascular invasion. The risk of relapse for PS1 patients is < 10% for those without vascular invasion and ~30% for those with vascular invasion (143,152,154,155).

If CS1 patients with PS2 are followed up only after RPLND, ~30% relapse, mainly at sites outside the abdomen and pelvis. The risk of relapse depends upon the amount of retroperitoneal disease resected (156-158). If two (or more) courses of cisplatin-based chemotherapy are given adjuvant to RPLND in PS2 cases, the relapse rate is reduced to < 2%, including teratoma relapse (129,153,159). The risk of retroperitoneal relapse after a properly performed nerve-sparing RPLND is very low (< 2%), as is the risk of ejaculatory disturbance or other significant side-effects (153,156,157).

The follow-up after RPLND is much simpler and less costly than that carried out during post-orchidectomy surveillance because of the reduced need for abdominal CT scans (153). If there is a rare indication to perform a staging RPLND, a laparoscopic or robot-assisted RPLND is feasible in expert hands. This minimal-invasive approach cannot be recommended as a standard approach outside of a specialised laparoscopic centre (160-163). In a randomised comparison of RPLND with one course of PEB chemotherapy, adjuvant chemotherapy significantly increased the 2-year recurrence-free survival to 99.41% (confidence interval [CI] 95.87%, 99.92%) as opposed to surgery, which had a 2-year recurrence-free survival of 92.37% (CI 87.21%, 95.50%). The difference was 7.04%, CI 2.52%, 11.56%. The hazard ratio to experience a tumour recurrence with surgery as opposed to chemotherapy was 7.937, CI 1.808, 34.48. Therefore, one course of adjuvant PEB is superior to RPLND with regard to recurrence rates in patients unstratified for risk factors (164). In the SWENOTECA data mentioned in section 7.3.3 it was also found that one adjuvant PEB reduced the number of recurrences to 3.2% in the high-risk and to 1.4% in the low-risk patients (146).

6.4 CS1S with (persistently) elevated serum tumour markers

Serum tumour markers should be followed closely until levels fall into the reference values according to the expected half-life values for AFP and hCG. If the marker level increases after orchidectomy, the patient has residual disease. If RPLND is performed, up to 87% of these patients have pathologically documented nodes in the retroperitoneum (165). An US examination of the contralateral testicle must be performed, if this was not done initially.

The treatment of true CS1S patients is still controversial. They may be treated with three courses of primary PEB chemotherapy and with follow-up as for CS1B patients (high risk, see below) after primary chemotherapy (166), or by RPLND (141). The presence of vascular invasion may strengthen the indication for primary chemotherapy as most CS1S with vascular invasion will need chemotherapy sooner or later anyway.

6.5 Guidelines for the treatment of NSGCT stage I

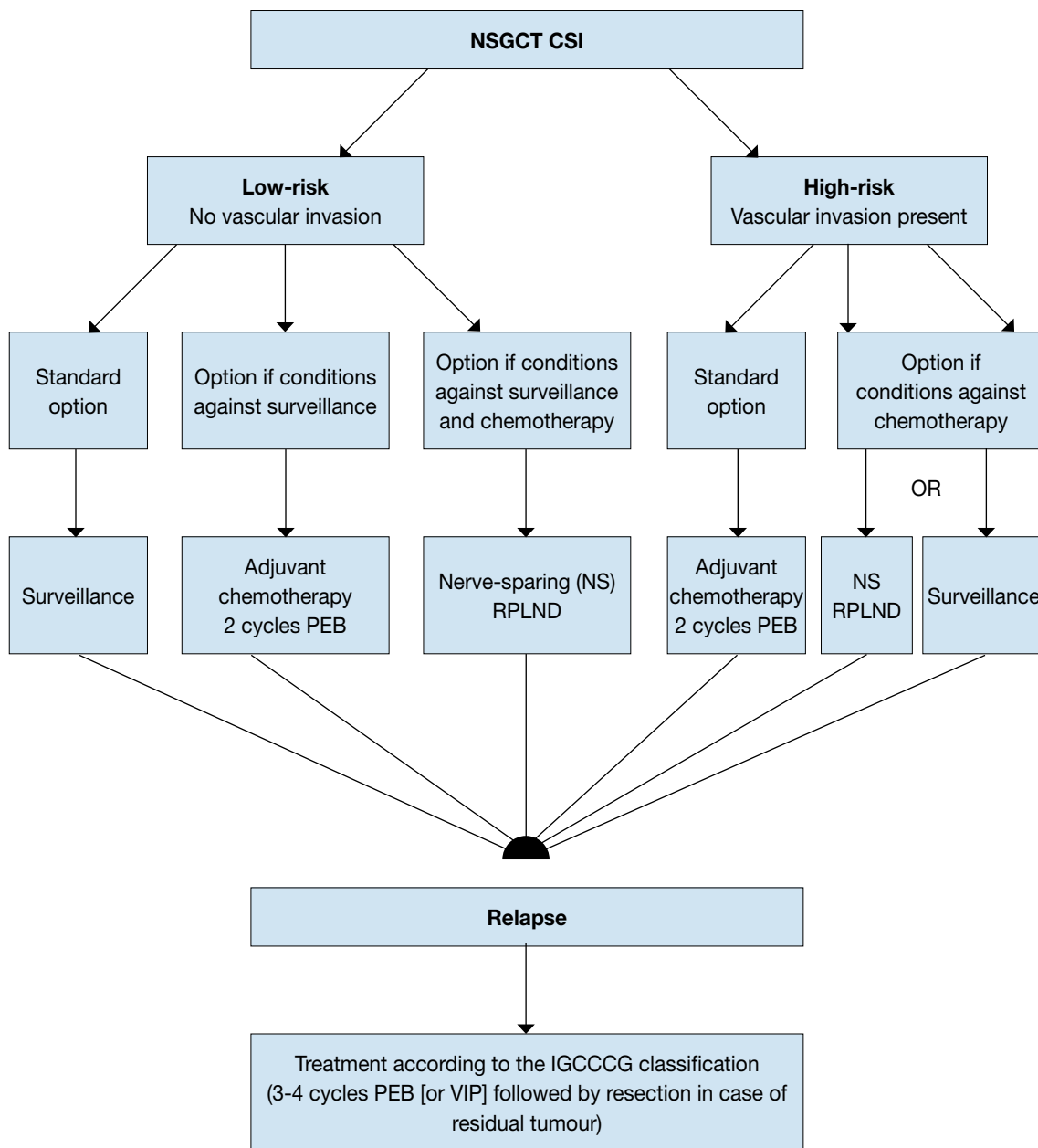
Table 7: Risk-adapted treatments for CS1 based on vascular invasion

NSGCT stage 1	GR
CS1 risk-adapted treatments based on vascular invasion or surveillance without using risk factors are recommended treatment options.	A
Risk-adapted treatments for CS1 based on vascular invasion	
CS1A (pT1, no vascular invasion): low risk	
If the patient is willing and able to comply with a surveillance policy, long-term (at least 5 years) close follow-up should be recommended.	A*
In low-risk patients not willing (or suitable) to undergo surveillance, adjuvant chemotherapy or nerve-sparing RPLND are treatment options. If RPLND reveals PN+ (nodal involvement) disease, chemotherapy with two courses of PEB should be considered.	A
CS1B (pT2-pT4): high risk	
Primary chemotherapy with two courses of PEB should be recommended (one course of PEB within a clinical trial or registry).	A*
Surveillance or nerve-sparing RPLND in high-risk patients remains an option for those not willing to undergo adjuvant chemotherapy. If pathological stage II is revealed at RPLND, further chemotherapy should be considered.	A

**Upgraded following panel consensus.*

CS = clinical stage; PEB = cisplatin, eposide, bleomycin; RPLND = retroperitoneal lymph node dissection.

Figure 1: Treatment algorithm after orchidectomy according to individual risk factors in patients with NSGCT CSI (31)



PEB = cisplatin, etoposide, bleomycin; CS = clinical stage; IGCCCG = International Germ Cell Cancer Collaborative Group; RPLND = nerve sparing; NSGCT = non-seminomatous germ cell tumour; VIP = etoposide, cisplatin, ifosfamide.

7. TREATMENT: METASTATIC GERM CELL TUMOURS

The treatment of metastatic germ cell tumours depends on:

- the histology of the primary tumour;
- prognostic groups as defined by the IGCCCG based on 5,202 non-seminoma and 660 seminoma cases (Table 5) (167).

7.1 Low-volume metastatic disease (stage IIA/B)

7.1.1 Stage IIA/B seminoma

So far, the standard treatment for stage IIA/B seminoma has been radiotherapy. The radiation dose delivered in stage IIA and IIB is approximately 30 Gy and 36 Gy, respectively. The standard radiation field compared with stage I will be extended from the PA region to the ipsilateral iliac field (the hockey-stick field). In stage IIB, the lateral borders should include the metastatic lymph nodes with a safety margin of 1.0-1.5 cm. This technique yields a relapse-free survival in stage IIA and IIB of 92% and 90%, respectively. Overall survival is almost 100% (168,169). Conversely, dose reduction to 27 Gy has been associated with 11% of relapses (106).

In stage IIB, chemotherapy (4 x etoposide and cisplatin [EP] or 3 x PEB in good prognosis) is an alternative to radiotherapy. Although more toxic in the short term, 4 x EP or 3 x PEB achieve a similar level of disease control (170). Single-agent carboplatin is not an alternative to standard EP or PEB chemotherapy (171).

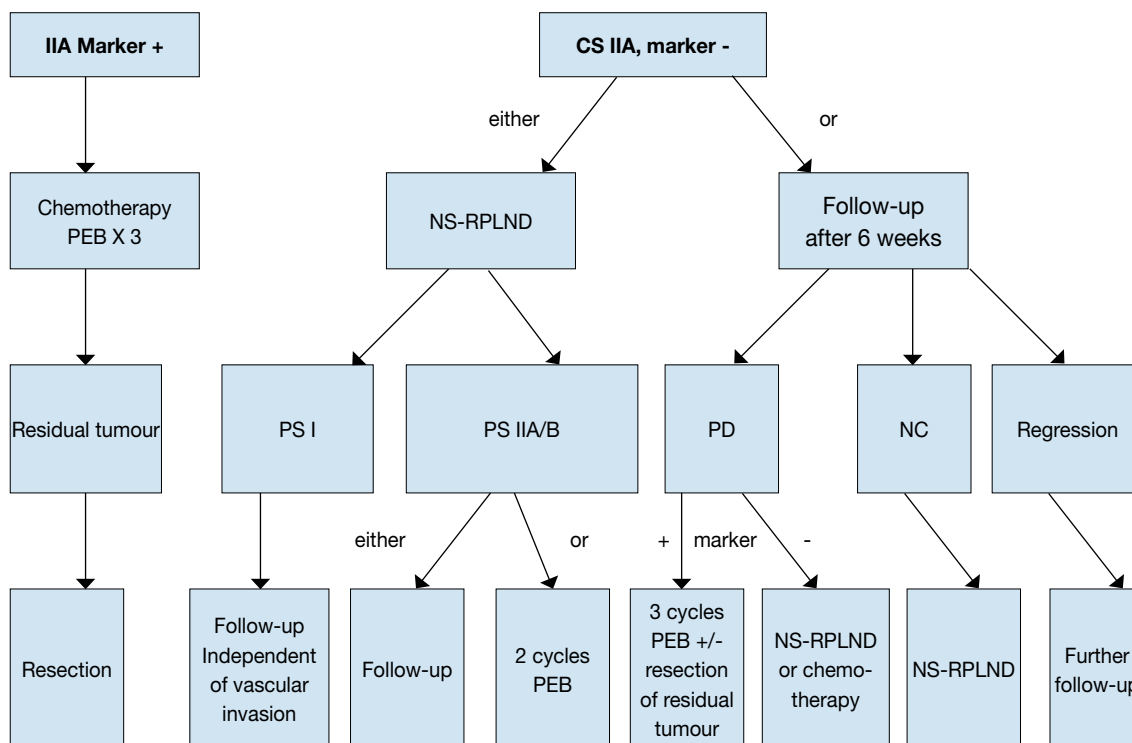
7.1.2 Stage IIA/B non-seminoma

There is a general consensus that treatment should start with initial chemotherapy in all advanced cases of NSGCT except for stage II NSGCT disease without elevated tumour markers, which alternatively can be managed by primary RPLND or surveillance to clarify stage (172,173).

If surveillance is chosen, one follow-up after 6 weeks is indicated to document whether the lesion is growing, remaining stable or shrinking. A shrinking lesion is likely to be of non-malignant origin and should be observed further. A stable or growing lesion indicates either teratoma or an undifferentiated malignant tumour. If the lesion is growing without a corresponding increase in the tumour markers AFP or beta-hCG, RPLND should be performed by an experienced surgeon because of suspected teratoma. Patients with a growing lesion and a concomitant increase in the tumour markers AFP or beta-hCG should not undergo surgery; they require chemotherapy with PEB according to the treatment algorithm for patients with metastatic disease and IGCCCG recommendations (174-176) (Figure 2). An alternative to the surveillance strategy in marker-negative II A/B non-seminoma with suspicion of an undifferentiated malignant tumour is a (CT-guided) biopsy, if technically possible. There is insufficient published data on PET scans in this situation.

Patients not willing to undergo primary chemotherapy have the option of primary nerve-sparing RPLND with adjuvant chemotherapy (two cycles of PEB) in case of metastatic disease (pII A/B). Primary chemotherapy and primary RPLND are comparable options in terms of outcome but side-effects and toxicity are different, allowing for involvement of the patient in selecting the treatment of choice (177). The cure rate with either approach will be close to 98% (159,178-183).

Figure 2: Treatment options in patients with non-seminoma clinical stage IIA (32)



PEB = cisplatin, etoposide, bleomycin; NS = nerve-sparing; RPLND = retroperitoneal lymph node dissection; PS = pathological stage; PD = progressive disease; NC = no change.

7.2 Advanced metastatic disease

7.2.1 Primary chemotherapy

The primary treatment of choice for advanced disease is three or four cycles of PEB combination chemotherapy (Table 8), depending on the IGCCCG risk classification (see Table 5). This regimen has proven superiority to cisplatin, vinblastine and bleomycin (PVB) in patients with advanced disease (184-186). Data support a 3-day regimen of administering combination chemotherapy to be equally effective as a 5-day regimen, but associated with increased toxicity when four cycles are used (187).

Table 8: PEB regimen (interval 21 days)

Drug	Dosage	Duration of cycles
Cisplatin	20 mg/m ²	Days 1-5*
Etoposide	100 mg/m ²	Days 1-5
Bleomycin	30 mg	Days 1, 8, 15

*Plus hydration.

PEB = cisplatin, etoposide, bleomycin.

For patients with a 'good prognosis', according to the IGCCCG Classification (167), standard treatment consists of three cycles of PEB, and only in very selected cases where bleomycin is contraindicated, four cycles of EP (167,186-190). A randomised trial from the GETUG suggested that when the PEB regimen is being used in this setting the mortality was half that of EP, although the difference did not reach statistical significance (190,191). Therapy should be given without reduction of the doses at 21-day intervals; delaying the following chemotherapy cycle is justified only in cases of fever with granulocytopenia < 1000/mm³ or thrombocytopenia < 100,000/IU. There is no indication for prophylactic application of haematopoietic growth factors such as, for example, granulocyte colony-stimulating factor (G-CSF). However, if infectious complications have occurred during chemotherapy, prophylactic administration of G-CSF is recommended for the following cycles (188,192).

The 'intermediate prognosis' group in the IGCCCG has been defined as patients with a 5-year survival rate of ~80%. The available data support four cycles of PEB as standard treatment (167,193).

For patients with a 'poor prognosis', standard treatment consists of four cycles of PEB. Four cycles of cisplatin, etoposide and ifosfamide (PEI) have the same effect, but are more myelotoxic (194,195). The 5-year progression-free survival is between 45% and 50%. Three randomised trials have shown no advantage in high-dose chemotherapy for the overall group of 'poor prognosis' patients (196-198). However, patients with a slow marker decline after the first or second cycle may represent a prognostically inferior subgroup with a potential role for dose-intensified chemotherapy after detection of inadequate marker decline (196). More aggressive chemotherapy may also be investigated in a very poor prognostic group (e. g. primary mediastinal germ cell tumours or synchronous brain metastasis).

Since a matched-pair analysis resulted in a better survival rate (199-201), poor prognosis patients should still be treated in ongoing prospective trials, investigating the value of dose intensified or high-dose chemotherapy (e. g. the international GETUG 13 trial [EU-20502, NCT00104676]).

Patients meeting 'poor-prognosis' criteria should therefore be transferred to a reference centre because a better outcome was reported for intermediate and poor prognosis patients who had been treated within a clinical trial in a high volume centre (25). There are no general recommendations for treatment modifications for patients with a poor general condition (Karnofsky < 50%) or extended liver infiltration (> 50%). Patients with extended pulmonary infiltration are at risk for acute respiratory distress syndrome: adapting the doses of the PEB regimen in the first cycle of chemotherapy (only 3 days of EP without bleomycin) was suggested to reduce the risk of early death in this setting (202).

7.3 Restaging and further treatment

7.3.1 Restaging

Restaging is performed by imaging investigations and re-evaluation of tumour markers. At marker decline and stable or regressive tumour manifestation, chemotherapy will be completed (three or four cycles, depending on the initial stage) (167,203,204). In the case of marker decline but growing metastases, resection of the tumour is obligatory after termination of induction therapy, other than in an emergency, according to local tumour growth (205).

Only with documented marker increase after two courses of chemotherapy is an early crossover of therapy indicated. These patients are usually candidates for new drugs trials (199,206). Patients with a low-level hCG marker plateau post-treatment should be observed to see whether complete normalisation occurs. Patients with a low plateau serum AFP level after chemotherapy, surgery of residual masses should be performed, with post-surgery AFP monitoring. Salvage chemotherapy is indicated for documented marker rise only (207,208).

7.3.2 Residual tumour resection

A residual mass of seminoma should not be primarily resected, irrespective of the size, but controlled by imaging investigations and tumour markers (209-215).

FDG-PET has a high negative predictive value in patients with residual masses after treatment of seminoma but false positive results can be a problem and scans should not be performed < 2 months after chemotherapy. In patients with residuals of > 3 cm, FDG-PET should be performed in order to gain more information on the viability of these residuals. In patients with residuals of < 3 cm, the use of FDG-PET is optional (216).

On progression, salvage therapy is indicated (chemotherapy, salvage surgery, radiotherapy) (217-221). In patients with concurrent hCG elevation, progressing seminoma after first-line chemotherapy should be treated by salvage chemotherapy (or radiotherapy if only small volume recurrence is present). Progressing patients without hCG progression should undergo histological verification (e. g. by biopsy or open surgery) before salvage chemotherapy is given.

In the case of non-seminoma and complete remission after chemotherapy (no tumour visible), residual tumour resection is not indicated (222-229). The long-term relapse rate in this patient group is 6-9%, however, one third of the late relapsing patients will not survive (229).

In the case of any visible residual mass and marker normalisation, surgical resection is indicated. In patients with lesions < 1 cm, there still is an increased risk of residual cancer or teratoma (230) although the role of surgery in this setting is debated. In persistent larger volume retroperitoneal disease, all areas of primary metastatic sites must be completely resected within 4-6 weeks of completion of chemotherapy. If technically feasible, a nerve-sparing procedure should be performed (222,229-238).

Overall, following PEB induction chemotherapy, only 10% of residual masses contain viable cancer, 50%

contain mature teratoma, and 40% contain necrotic-fibrotic tissue. As yet, no imaging investigations, including PET or a prognosis model, are able to predict histological differentiation of the non-seminomatous residual tumour. Thus, residual tumour resection is mandatory in all patients with residual disease > 1 cm (223-225,237-247).

The extent of surgery should be based on the risk of relapse of an individual patient and quality of life issues (232). If possible, all the masses should be resected, because a complete resection, in the setting of viable malignant cells, is more critical than recourse to post-operative chemotherapy (248). There is growing evidence that “template” resections in selected patients yield equivalent long-term results compared to bilateral systematic resections in all patients (249,250). However, the mere resection of the residual tumour (so called “lumpectomy”) should not be performed.

The histology may diverge in different organ sites (240). Resection of contralateral pulmonary lesions is not mandatory in case pathologic examination of the lesions from the first lung shows complete necrosis (251).

7.3.3 **Quality of surgery**

Post-chemotherapy surgery is demanding and frequently needs ad hoc vascular interventions (like vena cava or aortic prosthesis). Therefore, patients should be referred to specialised centres capable of interdisciplinary surgery (hepatic resections, vessel replacement, spinal neurosurgery, thoracic surgery). Patients treated within such centres benefit from a significant reduction in perioperative mortality from 6% to 0.8% (26,252). In addition, specialised urologic surgeons are capable to reduce the local recurrence rate from 16% to 3% (253) with a higher rate of complete resections.

7.3.4 **Consolidation chemotherapy after secondary surgery**

After resection of necrosis or mature/immature teratoma, no further treatment is required. In the case of incomplete resection of other germ cell tumour pathologies, two adjuvant cycles of conventionally dosed cisplatin-based chemotherapy may be given in certain subgroups (e.g. ‘poor prognosis’ patients) (248,254) (caution: cumulative doses of bleomycin). After complete resection of ‘vital’ tumour < 10% of the total volume, especially in patients with an initially good prognosis group according to IGCCCG, the relapse rate is very low and adjuvant chemotherapy is not beneficial for preventing further relapse. The prognosis will definitely deteriorate if vital malignant neoplasm is found in resection specimens after second- and third-line chemotherapy. In this latter situation, post-operative chemotherapy is not indicated and is unable to improve the prognosis (236,241).

7.4 **Systemic salvage treatment for relapse or refractory disease**

Cisplatin-based combination salvage chemotherapy will result in long-term remissions for about 50% of the patients who relapse after first-line chemotherapy (255). The regimens of choice are four cycles of PEI/VIP (etoposide, ifosfamide, cisplatin), four cycles of TIP (paclitaxel, ifosfamide, cisplatin) or four cycles of VeIP (vinblastine, ifosfamide, cisplatin) (Table 9).

A randomised trial showed no benefit in progression-free survival nor overall survival in patients treated with 3 cycles of VeIP plus 1 cycle of high-dose chemotherapy, compared with 4 cycles of VeIP (256). At present, it is impossible to determine whether conventionally dosed cisplatin-based combination chemotherapy is sufficient as first-salvage treatment or whether early intensification of first-salvage treatment with high-dose chemotherapy should be attempted. However, there is evidence from large retrospective analyses that there are different prognostic groups in case of relapse after first line chemotherapy (257-259). An international randomised trial of high-dose versus conventional dose chemotherapy in patients with first-line relapse is planned. It is therefore of the utmost importance that these rare patients are treated within clinical trials and at experienced centres.

Table 9: Standard PEI/VIP, TIP and VeIP chemotherapy (interval 21 days)

Chemotherapy agents	Dosage	Duration of cycles
PEI/VIP	20 mg/m ²	Days 1-5
Cisplatin*	75-100 mg/m ²	Days 1-5
Etoposide	1.2 g/m ²	Days 1-5
Ifosfamide†		
TIP		
Paclitaxel	250 mg/m ² ^{xx}	24 hour continuous infusion day 1
Ifosfamide†	1.5 g/ m ²	Days 2-5
Cisplatin*	25 mg/m ²	Days 2-5
VeIP		
Vinblastin	0.11 mg/kg	Days 1 + 2
Ifosfamide†	1.2 g/m ²	Days 1-5
Cisplatin*	20 mg/m ²	Days 1-5

PEI/VIP = cisplatin, etoposide, ifosfamide; TIP = paclitaxel, ifosfamide, cisplatin; VeIP = vinblastine, ifosfamide, cisplatin.

*Plus hydration.

†Plus mesna protection.

^{xx} An MRC schedule uses paclitaxel at 175mg/m² in a 3 hour infusion (260).

Conventionally dosed salvage chemotherapy may achieve long-term remissions in 15-40% of patients, depending on individual risk factors (208,261-263).

The IGCCCG-2 prognostic score comprised of 7 important factors as listed in Table 10 (seminoma vs. non-seminoma histology, primary tumour site, response to initial chemotherapy, duration of progression-free interval, AFP marker level at salvage, HCG marker level at salvage, and the presence of liver, bone, or brain metastases at salvage). Using these factors, 5 risk groups (very low risk = -1 points; low risk = 0 points; intermediate-risk = 1-2 points, high risk = 3-4 points; and very high risk ≥ 5 points) were identified with significant differences in PFS and OS. Table 11 illustrates the 5 risk groups and the corresponding 2-year PFS and 3-year OS rates (264).

Table 10: IGCCCG-2 (Lorch-Beyer) Score Construction (258)

Points	-1	0	1	2	3
Variable					
Histology	Seminoma	Non-seminoma			
Primary site		Gonadal	Retroperitoneal		Mediastinal
Response		CR/PRm-	PRm+/SD	PD	
PFI		> 3 months	3 months		
AFP salvage		Normal	< 1000	1000	
HCG salvage		< 1000	1000		
LBB		No	Yes		

AFP = alpha-fetoprotein; hCG = human chorionic gonadotrophin; IGCCCG = International Germ Cell Cancer Collaborative Group; LBB = alkaline extract of *L. barbarum*; PFI = platinum-free interval.

Table 11: PFS and OS estimates for all patients according to IGCCCG-2 prognostic score (258)

	n	%	HR	2-years PFS	3-years OS
Score (n=1435)					
Very Low	76	5.30	1	75.1	77.0
Low	257	17.9	2.07	52.6	69.0
Intermediate	646	45.0	2.88	42.8	57.3
High	351	24.5	4.81	26.4	31.7
Very High	105	7.3	8.95	11.5	14.7
<i>Missing</i>	159				

IGCCCG = International Germ Cell Cancer Collaborative Group; OS = overall survival; PSF = progression-free survival.

Salvage therapy with VeIP is probably not superior to other conventionally dosed cisplatin-based combination regimens (251,254,255). Recently, paclitaxel and gemcitabine have proved to be active in the treatment of refractory germ cell tumours; both drugs are synergistic with cisplatin (265-267).

Depending on the presence of adverse prognostic factors, the results of salvage therapy after first-line cisplatin-based treatment are unsatisfactory (208,268). Although some phase II trials indicate a 10% improvement in survival with early intensification of first-salvage treatment using high-dose chemotherapy, others fail to demonstrate such improvement (260,269-272).

High dose chemotherapy offered no advantage as first salvage treatment according to the results of the randomised IT 94 trial in good prognosis patients (256). Patients with good prognostic features should therefore be offered conventional-dose first salvage treatment. However, several phase II trials, as well as one retrospectively matched-pair analysis, have shown an improvement in survival in poor-prognosis patients with early intensification of first-salvage treatment using high-dose chemotherapy (257,262,273,274). All of these patients should, if possible, be entered into ongoing studies to define the optimal approach to salvage treatment, and should be referred to centres experienced in caring for relapse and/or refractory patients (275,276).

7.4.1 Late relapse (≥ 2 years after end of first-line treatment)

Late relapse is defined as any patient relapsing more than 2 years following chemotherapy for metastatic non-seminoma. If technically feasible, all non-seminoma patients with late relapse should undergo immediate radical surgery of all lesions, irrespective of the level of their tumour markers to resect completely all undifferentiated germ-cell tumour, mature teratoma or secondary non-germ cell cancer (140,277). Patients with rapidly rising HCG may present an exception for immediate surgery and may benefit from induction salvage chemotherapy before complete resection. If the lesions are not completely resectable, biopsies should be obtained for histological assessment, and salvage chemotherapy should be initiated according to the histological results. In these cases consultation of an experienced pathologist is required to avoid misinterpretation of the therapeutic morphological changes in the germ cell neoplasms (278). If the patient responds to salvage chemotherapy, secondary surgery should be conducted whenever possible. In the case of unresectable, but localised, refractory disease, radiotherapy can be considered. To avoid excess mortality, late relapses should be treated only at centres experienced in managing such patients (279).

7.5 Salvage surgery

Residual tumours after salvage chemotherapy should be resected if possible. In the case of marker progression after salvage treatment and a lack of other chemotherapeutic options, resection of residual tumours ('desperation surgery') should be considered if complete resection of all tumour seems feasible (about 25% long-term survival may be achieved) (207,233,241,244,280-289).

7.6 Treatment of brain metastases

Brain metastases occur in the frame of a systemic relapse and rarely as an isolated relapse. The long-term survival of patients presenting with brain metastases at initial diagnosis is poor (30-40%), but even poorer is the development of a brain metastasis as a recurrent disease (the 5-year survival-rate is 2-5%) (290,291). Chemotherapy is the initial treatment in this case, and some data support the use of consolidation radiotherapy, even in the case of a total response after chemotherapy (292). Surgery can be considered in the case of a persistent solitary metastasis, depending on the systemic state, the histology of the primary tumour and the location of the metastasis.

7.7 Guidelines for the treatment of metastatic germ cell tumours

	GR
Low volume NSGCT stage IIA/B with elevated markers should be treated like 'good or intermediate prognosis' advanced NSGCT, with three or four cycles of PEB.	A
In stage IIA/B without marker elevation, histology can be gained by RPLND or biopsy. A repeat staging can be performed after six weeks of surveillance before final decision on further treatment.	B
In metastatic NSGCT (> stage IIC) with a good prognosis, three courses of PEB is the primary treatment of choice.	A
In metastatic NSGCT with an intermediate or poor prognosis, the primary treatment of choice is four courses of standard PEB and inclusion in clinical trials is strongly recommended.	A
Surgical resection of residual masses after chemotherapy in NSGCT is indicated in the case of visible residual masses and when serum levels of tumour markers are normal or normalising.	A
Seminoma CSII A/B can initially be treated with radiotherapy. When necessary, chemotherapy can be used as a salvage treatment with the same schedule as for the corresponding prognostic groups of NSGCT.	A
In seminoma stage CS IIB, chemotherapy (4 x EP or 3 x PEB, in good prognosis) is an alternative to radiotherapy. It appears that 4 x EP or 3 x PEB achieve a similar level of disease control.	B
Seminoma stage IIC and higher should be treated with primary chemotherapy according to the same principles used for NSGCT.	A

EP = eposide, cisplatin; GR = grade of recommendation; NSGCT = non-seminomatous germ cell tumour; PEB = cisplatin, eposide, bleomycin; RPLND = retroperitoneal lymph node dissection.

8. FOLLOW-UP AFTER CURATIVE THERAPY

8.1 General considerations

The selection of the test to be performed in follow-up should adhere to the following principles (293):

- the interval between examination and duration of testing should be consistent with the time of maximal risk of recurrence and the natural history of the tumour;
- the tests should be directed at the most likely sites of recurrence and should have a high predictive value, both positive and negative;
- therapy should be available that will result in cure of the recurrence, significant prolongation of life or palliation of symptoms. The initiation of earlier therapy should improve the outcome compared with therapy given when the patient becomes symptomatic from the tumour recurrence;
- the increased risk of second malignancy, both in the primary site and in other tissues that may have been exposed to the same carcinogens, or in which there is epidemiological evidence of increased risk, should also guide the ordering of tests. Malignant and non-malignant complications of therapy must also be considered. Such testing should also be performed with a frequency and duration consistent with the nature of the risk, and include only tests with high positive- and negative-predictive values.

The following considerations apply in a general manner for the selection of an appropriate schedule and testing in the follow-up of all stages of testis tumour.

- Most recurrences after curative therapy will occur in the first 2 years; surveillance should therefore be most frequent and intensive during this time.
- Late relapses can occur beyond 5 years, and therefore yearly follow-up for life may be advocated.
- After RPLND, relapse in the retroperitoneum is rare, the most likely site of recurrence being the chest.
- The value of a plain radiography chest has been recently questioned in the follow-up of patients with disseminated disease after complete remission (294,295).
- CT of the chest has a higher predictive value than plain radiography chest (295).
- The results of therapy are dependent on the bulk of disease; thus an intensive strategy to detect asymptomatic disease may be justifiable.
- After chemotherapy or radiotherapy, there is a long-term risk of the development of secondary malignancies.

- Exposure to diagnostic X-rays causes second malignancies (296). Thus, the frequency of CT scans should generally be reduced and any exposure to X-rays should be well justified in a patient cohort with a very long life-expectancy after successful treatment.
- In specialised centres, CT can be substituted by MRI. However, MRI is a protocol-dependent method and, thus, should be performed in the same institution with a standardised protocol.
- With special expertise, US may be used as a method to screen the retroperitoneum during follow-up. However, the method is very much dependent on the investigator and cannot be recommended as general method during follow-up.
- Longer follow-up in patients after radiotherapy and chemotherapy is justified to detect late toxicities (e.g. cardio-vascular, endocrine).

A number of interdisciplinary organisations have presented recommendations for follow-up of testicular cancer patients (297-299). The follow-up tables presented below (Tables 12-15) present the minimum follow-up criteria and should therefore be considered as a GR A.

8.2 Follow-up: stage I non-seminoma

Approximately 5% of patients with CS1 NSGCT present with elevated levels of tumour markers after orchidectomy, and up to 25-30% relapse during the first 2 years (5,132,152,155,178,300-303).

The follow-up schedule will differ depending on which of the three possible treatment strategies was chosen:

- surveillance;
- nerve-sparing RPLND;
- adjuvant chemotherapy.

8.2.1 Follow-up investigations during surveillance

The results of a surveillance policy depend upon a careful pre-operative staging procedure and follow-up management. In a 'wait and see' policy, relapses will occur in 30% of cases. Of these relapses, 80% will occur in the first 12 months after orchidectomy, and approximately 12% during the second year. The median time to relapse is 6 months (range 1-62 months), but relapses after 3-5 years, and even later, can still occur, with an annual rate of 4% (113,114). Relapse occurs mainly in the retroperitoneum: approximately 70% of patients have evident metastases in the retroperitoneum, and 10% in the mediastinum and lungs (304). Sometimes the only indication is an elevated level of tumour markers.

A randomised trial of two versus five CTs has been published by the MRC recommending the reduction of imaging during surveillance in this stage to one CT scan at 3 months after orchidectomy, and another at 12 months. The trial, with a cohort of 414 patients, was powered to exclude a 3% probability of detecting a patient during surveillance only, with a relapse presenting already-metastatic disease with 'intermediate' or 'poor' prognosis features. Relapses were detected in 15% with two CTs, and 20% with five CTs; 1.6% of these patients had 'intermediate' or 'poor' prognosis features. Only 10% of patients had high-risk features (vascular invasion). In summary, this first randomised trial yielded level 1 evidence for a minimum follow-up in patients with CS1 non-seminoma (142). The recommended follow-up schedule (Table 12) includes the minimum requirements for imaging, and adds recommendations for other surveillance tests.

Table 12: Recommended follow-up schedule in a surveillance policy: stage I non-seminoma

Procedure	Year			
	1	2	3-5	6-10
Physical examination	4 times	4 times	Once/year	Once/year
Tumour markers	4 times	4 times	Once/year	Once/year
Plain radiography chest	Twice	Twice		
Abdominopelvic CT	Twice (at 3 and 12 months)			

CT= computed tomography.

During the initial post-treatment phase, follow-up consists of regular clinical examinations, the monitoring of serum tumour markers, and imaging investigations. The frequency and type of the examinations depend on the estimated risk of relapse, the chosen treatment strategy, and the time that has elapsed since completion of therapy, and should be modified according to these risks. However, only limited information about the optimal follow-up strategy exists, and currently recommendations can only be given for seminoma (305).

For low-risk stage I non-seminoma, two abdominopelvic CTs during the first year seem sufficient to detect relapses at an early stage (142). The significance of additional CTs remains uncertain. No studies are available that address the optimal monitoring of such patients by serum tumour markers (AFP, beta-hCG).

8.2.2 Follow-up after nerve-sparing RPLND

Retroperitoneal relapse after a properly performed nerve-sparing RPLND is rare. RPLND should eliminate the retroperitoneal nodes as a site of relapse and thus the need for repeated abdominal CTs. The US Testicular Cancer Intergroup study data show retroperitoneal relapse in 7/264 patients with pathological stage I disease (and 20 pulmonary relapses); four of these seven had no marker elevation (306). In the Indiana series, only one relapse in 559 cases was reported (307). If a relapse occurs, it is generally in the chest, neck or at the margins of the surgical field.

Pulmonary relapses occur in 10-12% of patients, and > 90% of those relapses occur within 2 years of RPLND (87,308). However, the low rate of retroperitoneal relapse after RPLND can only be achieved by surgery in specialised centres, as shown by the high in-field relapse rate (7/13 relapses) in the German randomised trial of RPLND versus one course of PEB (164). The recommended minimum follow-up schedule is shown in Table 13.

Table 13: Recommended follow-up schedule after retroperitoneal lymphadenectomy or adjuvant chemotherapy: stage I non-seminoma

Procedure	Year			
	1	2	3-5	6-10
Physical examination	4 times	4 times	Once/year	Once/year
Tumour markers	4 times	4 times	Once/year	Once/year
Plain radiography chest	Twice	Twice		
Abdominopelvic CT	Once	Once		

CT = computed tomography.

8.2.3 Follow-up after adjuvant chemotherapy

Prospective reports with long-term follow-up after adjuvant chemotherapy have shown a low relapse rate of about 3% (132,133,300,301). In a randomised trial with one course of PEB versus RPLND, the relapse rate with adjuvant chemotherapy was 1% (2/174 patients, one with marker relapse, one with mature teratoma in the retroperitoneum) (164). The need for repeated and long-term assessment of the retroperitoneum is still not clear. Owing to the risk of developing a late, slow-growing teratoma in the retroperitoneum after adjuvant chemotherapy, an abdominal CT should still be performed (see Table 13).

8.3 Follow-up: stage I seminoma

The majority of patients with seminoma (70-80%) present with clinical stage I disease at diagnosis. In 15-20% of cases, there is nodal radiological involvement at the level of the retroperitoneum, and only 5% of patients present with distant metastasis.

The relapse rate ranges from 1-20%, depending on the post-orchidectomy therapy chosen. Only up to 30% of seminomas present with elevation of hCG at diagnosis or in the course of the disease. Consequently, in most cases, measurement of blood markers will not be a reliable test for follow-up (309). The treatment options post-orchidectomy in stage I seminoma are retroperitoneal radiotherapy, surveillance and adjuvant chemotherapy. Due to extreme radio- and chemosensitivity, high cure rates of almost 100% are reached with each of the approaches, even in cases of relapse. The costs of the different therapies vary, as do the expected side-effects (310-312).

8.3.1 Follow-up after radiotherapy

Low doses of radiotherapy (20-24 Gy) limited to the retroperitoneal or the hockey-stick field achieve an overall survival rate of approximately 99% at 5-10 years (113-115,313,315). The rate of relapse is 1-2% and the most common time of presentation is within 18 months of treatment (113,116,312,315,316), although late relapses have also been described (317). The site of relapse is mainly at the supradiaphragmatic lymph nodes, mediastinum, lungs or bones. In a small proportion of cases, the tumour will relapse in the inguinal or external iliac nodes. After para-aortic field RT there is also a pelvic node relapse pattern.

The side-effects of radiotherapy include temporary impaired spermatogenesis, GI symptoms (peptic ulceration),

and induction of second malignancies (312,318,319). Up to 50% of patients can develop moderate toxicity grade I-II (309). The schedule of follow-up is described in Table 14.

Table 14: Recommended follow-up schedule for post-orchidectomy surveillance, radiotherapy or chemotherapy: stage I seminoma

Procedure	Year			
	1	2	3-4	5-10
Physical examination	3 times	3 times	Once/year	Once/year
Tumour markers	3 times	3 times	Once/year	Once/year
Plain radiography chest	Twice	Twice		
Abdominopelvic CT	Twice	Twice		

CT = computed tomography.

8.3.2 Follow-up during surveillance

The actuarial risk of relapse at 5 years ranges between 6% (low risk) and 20% (119,330-334). There is no increased risk of death. The median time to relapse ranges from 12-18 months, but up to 29% of relapses can develop later than this (103,325). The sites of relapse are the PA lymph nodes in up to 82% of cases; the pelvic lymph nodes, inguinal nodes and lungs can also be affected (103,138,326-329). Due to the high and often late rate of relapse, close and active follow-up is mandatory for at least 5 years (330) (see Table 14).

8.3.3 Follow-up after adjuvant chemotherapy

One or two courses of carboplatin-based chemotherapy is an effective alternative treatment in stage I seminoma. The relapse rate is 1.9-4.5%. In general, this treatment is well tolerated, with only mild, acute and intermediate-term toxicity (330,331). Long-term data on late relapses and survival are missing (see Table 14).

8.4 Follow-up: stage II and advanced (metastatic) disease

The more advanced the nodal stage of the disease, the higher the likelihood of recurrence (159). In general, the primary tumour bulk governs the outcome for patients with NSGCT (332). In stage II NSGCT, regardless of the treatment policy adopted, excellent survival rates of 97% are reached provided that relapse is identified as soon as possible (172,173,179).

In advanced metastatic germ cell tumours, the extent of the disease correlates with the response to therapy and with survival. The combination of cisplatin-based chemotherapy and surgery (aggressive multimodality) achieves cure rates between 65-85%, depending on the initial extent of disease (333,334). Complete response rates to chemotherapy are in the order of 50-60% (333); another 20-30% of patients could be rendered disease-free with post-chemotherapy surgery (335).

The main reasons for failure of therapy in advanced NSGCT are (332,336,337):

- the presence of bulky disease not responding completely to chemotherapy;
- unresectable residual teratoma after chemotherapy;
- the presence or development of chemoresistant non-germ elements, which account for 8.2% of cases.

Table 15: Recommended minimum follow-up schedule in advanced NSGCT and seminoma

Procedure	Year			
	1	2	3-5	Thereafter
Physical examination	4 times	4 times	Twice/year	Once/year
Tumour markers	4 times	4 times	Twice/year	Once/year
Plain radiography chest	4 times	4 times	Twice/year	Once/year
Abdominopelvic CT*†	Twice	Twice	As indicated	As indicated
Chest CT†‡	As indicated	As indicated	As indicated	As indicated
Brain CT§	As indicated	As indicated	As indicated	As indicated

CT = computed tomography.

**An abdominal CT must be performed at least annually if teratoma is found in the retroperitoneum.*

†If the post-chemotherapy evaluation in a seminoma patient shows any mass > 3 cm, the appropriate CT should be repeated 2 and 4 months later to ensure that the mass is continuing to regress. If available, FDG-PET/CT can be performed.

‡A chest CT is indicated if abnormality is detected on a plain radiography chest and after pulmonary resection.

§In patients with headaches, focal neurological findings, or any central nervous system symptoms.

9. TESTICULAR STROMAL TUMOURS

9.1 Background

Testicular stromal tumours are rare and account for only 2-4% of adult testicular tumours. However, only Leydig cell and Sertoli cell tumours are of clinical relevance. As no general recommendations have been published to date, the Testicular Cancer Working Group of the EAU has decided to include these tumours in the EAU Germ Cell Tumour Guidelines. Recommendations for diagnosis and treatment are given only for Leydig and Sertoli cell tumours.

9.2 Methods

A Medline search for Leydig cell tumours (synonym: interstitial cell tumour) and Sertoli cell tumours (synonym: androblastoma) was performed. Approximately 850 papers were found. After excluding pure laboratory work without clinical data, female and paediatric tumours and animal cases, 371 papers and abstracts were reviewed. Double publications and papers with unclear histology or missing data on clinical course were excluded. The majority of the remaining 285 publications are case reports, with only a few papers reporting series of more than 10 cases, most of them published in the pathology literature. The true incidence of stromal tumours therefore remains uncertain, and the proportion of metastatic tumours can only be given approximately.

Nevertheless, the symptoms for pre-operative suspicion of testicular stromal tumours and the characteristics of tumours at high-risk for metastases are sufficiently well established (LE: 2a/2b) to enable recommendations to be made regarding diagnosis and surgical approach. However, no recommendations for appropriate follow-up can be given due to the absence of follow-up data in most reported cases, and the fatal outcome of metastatic tumours, irrespective of the therapy chosen.

The individual publications have been rated according to LE (see above).

The literature research for clinical data on Leydig cell tumours resulted in 193 publications dealing with more than 480 tumours in adults, including three publications (1-3) reporting larger series on a total of 90 patients. Follow-up data of > 2 years are available for ~80 patients.

The literature research for clinical data on Sertoli cell tumours resulted in 93 publications dealing with more than 260 tumours in adults, including three publications (from the same group) (4-6) reporting on a total of 80 patients. Follow-up data of > 2 years are available in < 40 patients.

9.3 Classification

The non-germ cell tumours of the testicle include the sex cord/gonadal stromal tumours and the miscellaneous non-specific stromal tumours. The different histological subtypes of testicular tumours are defined according to the WHO classification 2004 (adapted) (7).

9.4 Leydig cell tumours

9.4.1 Epidemiology

Leydig cell tumours constitute ~1-3% of adult testicular tumours (2,8) and 3% of testicular tumours in infants and children (8). The tumour is most common in the third to sixth decade in adults, with a similar incidence observed in every decade. Another peak incidence is seen in children aged between 3 and 9 years.

Only 3% of Leydig cell tumours are bilateral (2). Occasionally, they occur in patients with Klinefelter's syndrome (8).

9.4.2 **Pathology of Leydig cell tumours**

Leydig cell tumours are the most common type of sex cord/gonadal stromal tumours. Histopathologically, they are well outlined and usually up to 5 cm in diameter. They are also solid, coloured yellow to tan, with haemorrhage and/or necrosis present in 30% of cases. Microscopically, the cells are polygonal, with eosinophilic cytoplasm with occasional Reinke crystals, regular nucleus, solid arrangement and capillary stroma. The cells express vimentin, inhibin, protein S-100, steroid hormones, calretinin and cytokeratin (focally) (7).

About 10% of Leydig cell tumours are malignant tumours, which present with the following parameters:

- large size (> 5 cm);
- cytological atypia;
- increased mitotic activity (> 3 per 10 high-power field [HPF]);
- increased MIB-1 expression (18.6% vs 1.2% in benign);
- necrosis;
- vascular invasion (9);
- infiltrative margins;
- extension beyond the testicular parenchyma;
- DNA aneuploidy (1,10).

9.4.3 **Diagnosis**

Patients either present with a painless enlarged testis or the tumour is an incidental US finding. In up to 80% of cases, hormonal disorders with high oestrogen and oestradiol levels and low testosterone, increased levels of LH and FSH are reported (11,12), while negative results are always obtained for the testicular germ cell tumour-markers AFP, hCG, LDH and PLAP. Approximately 30% of patients present with gynaecomastia (13,14). Only 3% of tumours are bilateral (2). Leydig cell tumours must be distinguished from the multinodular tumour-like and often bilaterally occurring lesions of the androgenital syndrome (15).

Diagnostic work-up must include markers, hormones (at least testosterone, LH and FSH; if not conclusive, additionally oestrogen, oestradiol, progesterone and cortisol), US of both testes, and CT of chest and abdomen. On US, it may be possible to observe well-defined, small, hypoechoic lesions with hypervascularisation, but the appearance is variable and is indistinguishable from germ cell tumours (16,17). The proportion of metastatic tumours in all published case reports is only 10%. Within three larger series with longer follow-up, 18 metastatic tumours were found in a total of 83 cases (21.7%) (1-3). Histopathological signs of malignancy have been depicted above (see 4.2) (1,10). In addition, patients of older age have a greater risk of harbouring a tumour of malignant potential.

9.4.4 **Treatment**

Asymptomatic testicular tumours of small volume are often misinterpreted as germ cell tumours, and inguinal orchidectomy is performed. It is highly recommended to perform an organ-sparing procedure in every small intraparenchymal lesion in order to obtain the histological diagnosis. Especially in patients with symptoms of gynaecomastia or hormonal disorders, a non germ-cell tumour should be considered and immediate orchidectomy avoided (18). In cases of germ cell tumour in either frozen (fresh tissue) section or paraffin histology, orchidectomy is recommended as long as a contralateral normal testicle is present.

In stromal tumours with histological signs of malignancy, especially in patients of older age, orchidectomy and retroperitoneal lymphadenectomy is recommended to prevent metastases (19). Without histological signs of malignancy, an individualised surveillance strategy after orchidectomy is recommended (CT follow-up may be most appropriate since specific tumour markers are not available).

Tumours that have metastasised to lymph nodes, lung, liver or bone respond poorly to chemotherapy or radiation and survival is poor (19).

9.4.5 **Follow-up**

Recommendations for appropriate follow-up cannot be given because of the lack of follow-up data in most reported cases and the lethal outcome of metastatic tumours, irrespective of the therapy chosen.

9.5 **Sertoli cell tumour**

9.5.1 **Epidemiology**

Sertoli cell tumours account for < 1% of testicular tumours, and the mean age at diagnosis is around 45 years, with rare cases under 20 years of age (4,20). On rare occasions, these tumours may develop in patients with androgen insensitivity syndrome and Peutz-Jeghers syndrome.

9.5.2 **Pathology of Sertoli cell tumours**

The tumour is well circumscribed, yellow, tan or white, with an average diameter of 3.5 cm (4). Microscopically, the cells are eosinophilic to pale with vacuolated cytoplasm. The nuclei are regular with grooves and there may be inclusions. The arrangement of the cells is tubular or solid; a cord-like or retiform pattern is possible. The stroma is fine and capillary, but in some cases a sclerosing aspect predominates. The cells express vimentin, cytokeratins, inhibin (40%) and protein S-100 (30%) (4).

The rate of malignant tumours ranges from 10-22%, and < 50 cases have been reported (21-23). Signs of a malignant Sertoli tumour are:

- large size (> 5 cm);
- pleomorphic nuclei with nucleoli;
- increased mitotic activity (> 5 per 10 HPF);
- necrosis;
- vascular invasion.

9.5.2.1 **Classification**

Three subtypes have been described (20):

- the classic Sertoli cell tumour (4);
- the large cell calcifying form with characteristic calcifications (5,24);
- the rare sclerosing form (6,25).

9.5.3 **Diagnosis**

Patients present either with an enlarged testis or the tumour is an incidental US finding (26). Most classic Sertoli tumours are unilateral and unifocal. Hormonal disorders are infrequent, although gynaecomastia is sometimes seen (4). The testicular tumour-markers AFP, hCG, LDH and PLAP are always negative.

Diagnostic work-up must include tumour markers, hormones (at least testosterone, LH and FSH; if not conclusive, additionally oestrogen, oestradiol, progesterone and cortisol), US of both testes and CT of chest and abdomen.

Sertoli cell tumours are generally hypoechoic on US, but they can be of variant appearance and therefore cannot be safely distinguished from germ cell tumours (20). Only the large cell calcifying form has a characteristic image with brightly echogenic foci due to calcification (27,28).

The large cell calcifying form is diagnosed in younger men and is associated with genetic syndromes (Carney's complex [29] and Peutz-Jeghers syndrome [30]) or, in ~40% of cases, endocrine disorders. A total of 44% of cases are bilateral, either synchronous or metachronous, and 28% show multifocality (24).

The characteristics of metastatic tumours have been depicted above (24,25). However, among patients whose tumours have been histopathologically classified as 'malignant' using these or similar characteristics (i.e. 18.8% of tumours in all reported cases), only 7% showed metastatic disease during follow-up.

In the largest series with the longest follow-up, 7.5% of patients had been classified as 'malignant' at primary diagnosis and 11.7% showed metastatic disease long-term (4). In general, affected patients are of higher age, tumours are nearly always palpable, and show more than one sign of malignancy (4).

Up to 20% of the large cell sclerosing form are malignant. There are some hints that discrimination between an early- and late-onset type may define a different risk for metastatic disease (5.5 vs. 23%) (20). Metastases in the infrequent sclerosing subtype are rare.

9.5.4 **Treatment**

Testicular tumours of small volume, otherwise asymptomatic, are often misinterpreted as germ cell tumours and inguinal orchidectomy is performed. It is highly recommended to proceed with an organ-sparing approach in small intraparenchymal testicular lesions until final histology is available. Especially in patients with symptoms of gynaecomastia or hormonal disorders or typical imaging on US (calcifications, small circumscribed tumours), organ-sparing surgery should be considered. Secondary orchidectomy can be performed if final pathology reveals a non-stromal (e.g. germ cell) tumour. Organ-sparing surgical approaches are justified as long as the remaining testicular parenchyma is sufficient for endocrine (and in stromal tumours also exocrine) function.

In tumours with histological signs of malignancy, especially in patients of older age, orchidectomy and retroperitoneal lymphadenectomy are recommended to prevent metastases (19). Without signs of malignancy,

an individualised surveillance strategy after orchidectomy is recommended (CT may be most appropriate since specific tumour-markers are not available). Tumours metastasising to lymph nodes, lung or bone respond poorly to chemotherapy or radiation, and survival is poor.

9.5.5 **Follow-up**

Recommendations for appropriate follow-up cannot be given because of the lack of follow-up data in most reported cases and the lethal outcome of metastatic tumours, irrespective of the therapy chosen.

9.6 **Granulosa cell tumour**

This is a rare tumour, with two variants: juvenile and adult.

- The juvenile type is benign. It is the most frequent congenital testicle tumour and represents 6.6% of all prepubertal testicular neoplasms. The cystic appearance is characteristic of this tumour type (31).
- With the adult type, the average age at presentation is 44 years. The typical morphology is of a homogeneous, yellow-grey tumour, with elongated cells with grooves in microfollicular and Call-Exner body arrangements.

Malignant tumours represent ~20% of cases. They are usually > 7 cm diameter. Vascular invasion and necrosis are features suggestive of malignant biology (32).

9.7 **Thecoma/fibroma group of tumours**

These tumours are very rare and benign (7).

9.8 **Other sex cord/gonadal stromal tumours**

Sex cord/gonadal stromal tumours may be incompletely differentiated or mixed forms.

There is limited experience with incompletely differentiated sex cord/gonadal stromal tumours and no cases of reported metastasis (7). In mixed tumour forms, all the histological components should be reported. However, the clinical behaviour is most likely to reflect the predominant pattern or the most aggressive component of the tumour (33).

9.9 **Tumours containing germ cell and sex cord/gonadal stromal (gonadoblastoma)**

If the arrangement of the germ cells are in a nested pattern and the rest of the tumour is composed of sex cord/gonadal stroma, the term gonadoblastoma is used. It is most frequent in gonadal dysgenesis with ambiguous genitalia. Bilateral tumours are present in 40% of cases. The prognosis correlates with the invasive growth of the germinal component (34).

In the case of a diffuse arrangement of the different components, there are some doubts about the neoplastic nature of the germinal cells and some authors consider them to be entrapped rather than neoplastic (35).

9.10 **Miscellaneous tumours of the testis**

9.10.1 **Tumours of ovarian epithelial types**

These tumours resemble the epithelial tumours of the ovary. A cystic appearance with occasional mucinous material can be observed. Microscopically, the aspect is identical to their ovarian counterparts, and their evolution is similar to that of the different epithelial ovarian subtypes. Some Brenner types can be malignant (7).

9.10.2 **Tumours of the collecting ducts and rete testis**

These tumours are very rare. Benign (adenoma) and malignant (adenocarcinoma) have been reported, with malignant tumours showing local growth with a mortality rate of 56% (18).

9.10.3 **Tumours (benign and malignant) of non-specific stroma**

These are very uncommon and have a similar criteria, prognosis and treatment as do the soft tissue sarcomas.

10. REFERENCES

10.1 Germ cell tumours

1. La Vecchia C, Bosetti C, Lucchini F, et al. Cancer Mortality in Europe, 2000-2004, and an overview of trends since 1995. *Ann Oncol* 2010 Jun;21(6):1323-60.
<http://www.ncbi.nlm.nih.gov/pubmed/19948741>
2. Cancer Incidence in Five Continents, Vol IX. Curado MP, Edwards B, Shin R, et al eds. IARC Scientific Publication 2007, No. 160.
<http://www.iarc.fr/en/publications/pdfs-online/epi/index.php>
3. Engholm G, Ferlay J, Christensen N, et al. NORDCAN--a Nordic tool for cancer information, planning, quality control and research. *Acta Oncol* 2010 Jun;49(5):725-36.
<http://www.ncbi.nlm.nih.gov/pubmed/20491528>
4. Jemal A, Siegel R, Ward E, et al. Cancer Statistics, 2009. *CA Cancer J Clin* 2009 Jul-Aug;59(4):225-49.
<http://www.ncbi.nlm.nih.gov/pubmed/19474385>
5. Huyghe E, Matsuda T, Thonneau P. Increasing incidence of testicular cancer worldwide: a review. *J Urol* 2003 Jul;170(1):5-11.
<http://www.ncbi.nlm.nih.gov/pubmed/12796635>
6. McGlynn KA, Devesa SS, Sigurdson AJ, et al. Trends in the incidence of testicular germ cell tumours in the United States. *Cancer* 2003 Jan;97(1):63-70.
<http://www.ncbi.nlm.nih.gov/pubmed/12491506>
7. Bosl GJ, Motzer RJ. Testicular germ-cell cancer. *N Engl J Med* 1997 Nov;337(4):242-53. [No abstract available]
<http://www.ncbi.nlm.nih.gov/pubmed/9227931>
8. Kuczyk MA, Serth J, Bokemeyer C, et al. Alterations of the p53 tumour suppressor gene in carcinoma in situ of the testis. *Cancer* 1996 Nov;78(9):1958-66.
<http://www.ncbi.nlm.nih.gov/pubmed/8909317>
9. Looijenga LH, Gillis AJ, Stoop H, et al. Relevance of microRNAs in normal and malignant development, including human testicular germ cell tumours. *Int J Androl* 2007 Aug;30(4):304-14; discussion 314-15.
<http://www.ncbi.nlm.nih.gov/pubmed/17573854>
10. Reuter VE. Origins and molecular biology of testicular germ cell tumors. *Mod Pathol* 2005 Feb;18(Suppl 2):S51-S60.
<http://www.ncbi.nlm.nih.gov/pubmed/15761466>
11. Rapley EA, Turnbull C, Al Olama AA, et al. UK Testicular Cancer Collaboration. A genome-wide association study of testicular germ cell tumor. *Nat Genet* 2009 Jul;41(7):807-10.
<http://www.ncbi.nlm.nih.gov/pubmed/19483681>
12. Kanetsky PA, Mitra N, Vardhanabhuti S, et al. Common variation in KITLG and at 5q31.3 predisposes to testicular germ cell cancer. *Nat Genet* 2009 Jul;41(7):811-5.
<http://www.ncbi.nlm.nih.gov/pubmed/19483682>
13. Korkola JE, Houldsworth J, Feldman DR, et al. Identification and validation of a gene expression signature that predicts outcome in adult men with germ cell tumors. *J Clin Oncol* 2009 Nov;27(31):5240-7.
<http://www.ncbi.nlm.nih.gov/pubmed/19770384>
14. Osterlind A, Berthelsen JG, Abildgaard N, et al. Risk of bilateral testicular germ cell tumours in Denmark: 1960-1984. *J Natl Cancer Inst* 1991 Oct;83(19):1391-5.
<http://www.ncbi.nlm.nih.gov/pubmed/1656057>
15. Møller H, Prener A, Skakkebaek NE. Testicular cancer, cryptorchidism, inguinal hernia, testicular atrophy and genital malformations: case-control studies in Denmark. *Cancer Causes Control* 1996 Mar;7(2):264-74.
<http://www.ncbi.nlm.nih.gov/pubmed/8740739>
16. Dieckmann KP, Pichlmeier U. The prevalence of familial testicular cancer: An analysis of two patient populations and a review of the literature. *Cancer* 1997 Nov;80(10):1954-60.
<http://www.ncbi.nlm.nih.gov/pubmed/9366298>
17. Forman D, Oliver RT, Brett AR, et al. Familial testicular cancer: a report of the UK family register, estimation of risk and a HLA class 1 sib-pair analysis. *Br J Cancer* 1992 Feb;65(2):255-62.
<http://www.ncbi.nlm.nih.gov/pubmed/1739626>
18. Weestergaard T, Olsen JH, Frisch M, et al. Cancer risk in fathers and brothers of testicular cancer patients in Denmark. A population based study. *Int J Cancer* 1996 May;66(5):627-31.
<http://www.ncbi.nlm.nih.gov/pubmed/8647624>

19. Dieckmann KP, Loy V, Buttner P. Prevalence of bilateral germ cell tumours and early detection based on contralateral testicular intra-epithelial neoplasia. *Br J Urol* 1993 Mar;71(3):340-5.
<http://www.ncbi.nlm.nih.gov/pubmed/8386582>
20. Peng X, Zeng Z, Peng S, et al. The Association risk of male subfertility and testicular cancer: A systematic review. *PLoS ONE* 4(5):e5591.
<http://www.ncbi.nlm.nih.gov/pubmed/19440348>
21. Dieckmann KP, Hartmann JT, Classen J, et al. Tallness is associated with risk of testicular cancer: evidence for the nutrition hypothesis. *Br J Cancer* 2008 Nov;99(9):1517-21.
<http://www.ncbi.nlm.nih.gov/pubmed/18827809>
22. Dieckmann KP, Hartmann JT, Classen J, et al. Is increased body mass index associated with the incidence of testicular germ cell cancer? *J Cancer Res Clin Oncol* 2009 May;135(5):731-8.
<http://www.ncbi.nlm.nih.gov/pubmed/19002497>
23. Wanderas EH, Tretli S, Fossa SD. Trends in incidence of testicular cancer in Norway 1955-1992. *Eur J Cancer* 1995 Nov;31A(12):2044-8.
<http://www.ncbi.nlm.nih.gov/pubmed/8562163>
24. Jones A, Fergus JN, Chapman J, et al. Is surveillance for stage I germ cell tumours of the testis appropriate outside a specialist centre? *BJU Int* 1999 Jul;84(1):79-84.
<http://www.ncbi.nlm.nih.gov/pubmed/10444129>
25. Collette L, Sylvester RJ, Stenning SP, et al. Impact of the treating institution on survival of patients with "poor-prognosis" metastatic nonseminoma. European Organization for Research and Treatment of Cancer Genitourinary Tract Cancer Collaborative Group and the Medical Research Council Testicular Cancer Working Party. *J Natl Cancer Inst* 1999 May;91(10):839-46.
<http://www.ncbi.nlm.nih.gov/pubmed/10340903>
26. Capitanio U, Jeldres C, Perrotte P, et al. Population-based study of perioperative mortality after retroperitoneal lymphadenectomy for nonseminomatous testicular germ cell tumors. *Urology* 2009 Aug;74(2):373-7.
<http://www.ncbi.nlm.nih.gov/pubmed/19501893>
27. Fléchon A, Tavernier E, Boyle H, et al. Long-term oncological outcome after post-chemotherapy retroperitoneal lymph node dissection in men with metastatic nonseminomatous germ cell tumour. *BJU Int* 2010 Sep;106(6):779-85.
<http://www.ncbi.nlm.nih.gov/pubmed/20089110>
28. Warde P, Specht L, Horwich A, et al. Prognostic factors for relapse in stage I seminoma managed by surveillance: a pooled analysis. *J Clin Oncol* 2002 Nov;20(22):4448-52.
<http://www.ncbi.nlm.nih.gov/pubmed/12431967>
29. Shelley MD, Burgon K, Mason MD. Treatment of testicular germ-cell cancer: a cochrane evidence-based systematic review. *Cancer Treat Rev* 2002 Oct;28(5):237-53.
<http://www.ncbi.nlm.nih.gov/pubmed/12435371>
30. Krege S, Beyer J, Souchon R, et al. European consensus conference on diagnosis and treatment of germ cell cancer: a report of the second meeting of the European Germ Cell Cancer Consensus group (EGCCCG): part I. *Eur Urol* 2008 Mar;53(3):478-96.
<http://www.ncbi.nlm.nih.gov/pubmed/18191324>
31. Krege S, Beyer J, Souchon R, et al. European consensus conference on diagnosis and treatment of germ cell cancer: a report of the second meeting of the European Germ Cell Cancer Consensus Group (EGCCCG): part II. *Eur Urol* 2008 Mar;53(3):497-513.
<http://www.ncbi.nlm.nih.gov/pubmed/18191015>
32. Oxford Centre for Evidence-based Medicine Levels of Evidence (May 2001). Produced by Bob Phillips, Chris Ball, Dave Sackett, Doug Badenoch, Sharon Straus, Brian Haynes, Martin Dawes since November 1998. [Accessed January 2014]
<http://www.cebm.net/index.aspx?o=1025>
33. Atkins D, Best D, Briss PA, et al. GRADE Working Group. Grading quality of evidence and strength of recommendations. *BMJ* 2004 Jun;328(7454):1490.
<http://www.ncbi.nlm.nih.gov/pubmed/15205295>
34. Guyatt GH, Oxman AD, Vist GE, et al. GRADE: an emerging consensus on rating quality of evidence and strength of recommendations. *BMJ* 2008 Apr;336(7650):924-6.
<http://www.ncbi.nlm.nih.gov/pubmed/18436948>
35. Guyatt GH, Oxman AD, Kunz R, et al. GRADE Working Group. Going from evidence to recommendations. *BMJ* 2008 May;336(7652):1049-51.
<http://www.ncbi.nlm.nih.gov/pmc/articles/PMC2376019/?tool=pubmed>

36. Albers P, Albrecht W, Algaba F, et al. European Association of Urology. EAU guidelines on testicular cancer: 2011 update. *Eur Urol* 2011 Aug;60(2):304-19.
<http://www.ncbi.nlm.nih.gov/pubmed/21632173>
37. WHO histological classification of testis tumours, In: Eble JN, Sauter G, Epstein JI, Sesterhenn IA, eds. *Pathology & Genetics. Tumours of the urinary system and male genital organs*. Lyons: IARC Press, 2004: 218, pp. 250-262.
<http://www.iarc.fr/en/publications/pdfs-online/pat-gen/bb7/index.php>
38. Germa-Lluch JR, Garcia del Muro X, Maroto P, et al. Spanish Germ-Cell Cancer Group (GG). Clinical pattern and therapeutic results achieved in 1490 patients with germ-cell tumours of the testis: the experience of the Spanish Germ-Cell Cancer Group (GG). *Eur Urol* 2002 Dec;42(6):553-62.
<http://www.ncbi.nlm.nih.gov/pubmed/12477650>
39. Richie JP, Birnholz J, Garnick MB. Ultrasonography as a diagnostic adjunct for the evaluation of masses in the scrotum. *Surg Gynecol Obstet* 1982 May;154(5):695-8.
<http://www.ncbi.nlm.nih.gov/pubmed/7071705>
40. Kim W, Rosen MA, Langer JE, et al. US-MR Imaging correlation in pathologic conditions of the scrotum. *Radiographics* 2007 Sep-Oct;27(5):1239-53.
<http://www.ncbi.nlm.nih.gov/pubmed/17848688>
41. Shaw J. Diagnosis and treatment of testicular cancer. *Am Fam Physician* 2008 Feb;77(4):469-74.
<http://www.ncbi.nlm.nih.gov/pubmed/18326165>
42. Angulo JC, Gonzalez J, Rodriguez N, et al. Clinicopathological study of regressed testicular tumors (apparent extragonadal germ cell neoplasms). *J Urol* 2009 Nov;182(5):2303-10.
<http://www.ncbi.nlm.nih.gov/pubmed/19762049>
43. Scholz M, Zehender M, Thalmann GN, et al. Extragonadal retroperitoneal germ cell tumor: evidence of origin in testis. *Ann Oncol* 2002 Jan;13(1):121-4.
<http://www.ncbi.nlm.nih.gov/pubmed/11863093>
44. Mancini M, Carmignani L, Gazzano G, et al. High prevalence of testicular cancer in azoospermic men without spermatogenesis. *Hum Reprod* 2007 Apr; 22(4):1042-6.
<http://www.ncbi.nlm.nih.gov/pubmed/17220165>
45. Elzinga-Tinke JE, Sirre ME, Looijenga LH, et al. The predictive value of testicular ultrasound abnormalities for carcinoma in situ of the testis in men at risk for testicular cancer. *Int J Androl* 2010 Aug;33(4):597-603.
<http://www.ncbi.nlm.nih.gov/pubmed/19845800>
46. DeCastro BJ, Peterson AC, Costabile RA. A 5-year followup study of asymptomatic men with testicular microlithiasis. *J Urol* 2008 Apr;179(4):1420-3.
<http://www.ncbi.nlm.nih.gov/pubmed/18289592>
47. Montgomery JS, Bloom DA. The diagnosis and management of scrotal masses. *Med Clin North Am* 2011 Jan;95(1):235-44.
<http://www.ncbi.nlm.nih.gov/pubmed/21095426>
48. Cassidy FH, Ishioka KM, McMahon CJ, et al. MR imaging of scrotal tumors and pseudotumors. *Radiographics* 2010 May;30(3):665-83.
<http://www.ncbi.nlm.nih.gov/pubmed/20462987>
49. Johnson JO, Mattrey RF, Phillipson J. Differentiation of seminomatous from nonseminomatous testicular tumours with MR imaging. *AJR Am J Roentgenol* 1990 Mar;154(3):539-43.
<http://www.ncbi.nlm.nih.gov/pubmed/2106218>
50. Klein EA. Tumour markers in testis cancer. *Urol Clin North Am* 1993 Feb;20(1):67-73.
<http://www.ncbi.nlm.nih.gov/pubmed/7679533>
51. Peyret C. Tumeurs du testicule. Synthèse et recommandations en onco-urologie. *Prog Urol* 1993;2:60-4. [Testicular tumours. Summary of onco-urological recommendations] [Article in French]
52. Javadpour N. The role of biologic markers in testicular cancer. *Cancer* 1980 Apr;45(7 Suppl):1755-61. [No abstract available]
<http://www.ncbi.nlm.nih.gov/pubmed/6154517>
53. Heidenreich A, Weissbach L, Holth W, et al. German Testicular Cancer Study Group. Organ sparing surgery for malignant germ cell tumour of the testis. *J Urol* 2001 Dec;166(6):2161-5.
<http://www.ncbi.nlm.nih.gov/pubmed/11696727>
54. Petersen PM, Giwercman A, Daugaard G, et al. Effect of graded testicular doses of radiotherapy in patients treated for carcinoma-in-situ in the testis. *J Clin Oncol* 2002 Aug;20(6):1537-43.
<http://www.ncbi.nlm.nih.gov/pubmed/11896102>
55. Heidenreich A, Höftl W, Albrecht W, et al. Testis-preserving surgery in bilateral testicular germ cell tumours. *Br J Urol* 1997 Feb;79(2):253-7.
<http://www.ncbi.nlm.nih.gov/pubmed/9052478>

56. Weissbach L. Organ preserving surgery of malignant germ cell tumours. *J Urol* 1995 Jan;153(1):90-3.
<http://www.ncbi.nlm.nih.gov/pubmed/7966800>
57. Sobin LH, Gospodariwicz M, Wittekind C (eds). TNM classification of malignant tumors. UICC International Union Against Cancer, 7th edn. Wiley-Blackwell, 2009 Dec; pp 249-254.
<http://www.uicc.org/tnm/>
58. Dieckmann KP, Loy V. Prevalence of contralateral testicular intraepithelial neoplasia in patients with testicular germ cell neoplasms. *J Clin Oncol* 1996 Dec;14(12):3126-32.
<http://www.ncbi.nlm.nih.gov/pubmed/8955658>
59. Von der Maase H, Rorth M, Walbom-Jorgensen S, et al. Carcinoma-in-situ of contralateral testis in patients with testicular germ cell cancer: study of 27 cases in 500 patients. *Br Med J (Clin Res Ed)* 1986 Nov;293(6559):1398-401.
<http://www.ncbi.nlm.nih.gov/pubmed/3026550>
60. Harland SJ, Cook PA, Fossa SD, et al. Intratubular germ cell neoplasia of contralateral testis in testicular cancer: defining a high risk group. *J Urol* 1998 Oct;160(4):1353-7.
<http://www.ncbi.nlm.nih.gov/pubmed/9751353>
61. Tabernero J, Paz-Ares L, Salazar R, et al. Incidence of contralateral germ cell testicular tumours in South Europe: report of the experience at 2 Spanish university hospitals and review of the literature. *J Urol* 2004 Jan;171(1):164-7.
<http://www.ncbi.nlm.nih.gov/pubmed/14665868>
62. Herr HW, Sheinfeld J. Is biopsy of the contralateral testis necessary in patients with germ cell tumors? *J Urol* 1997 Oct;158(4):1331-4.
<http://www.ncbi.nlm.nih.gov/pubmed/9302113>
63. Albers P, Göll A, Bierhoff E, et al. Clinical course and histopathologic risk factor assessment in patients with bilateral testicular germ cell tumours. *Urology* 1999 Oct;54(4):714-8.
<http://www.ncbi.nlm.nih.gov/pubmed/10510934>
64. Giwercman A, Bruun E, Frimotd-Muller C, et al. Prevalence of carcinoma in situ and other histopathological abnormalities in testes of men with a history of cryptorchidism. *J Urol* 1989 Oct;142(4):998-1001.
<http://www.ncbi.nlm.nih.gov/pubmed/2571738>
65. Heidenreich A, Moul JW. Contralateral testicular biopsy procedure in patients with unilateral testis cancer: is it indicated? *Sem Urol Oncol* 2002 Nov;20(4):234-8.
<http://www.ncbi.nlm.nih.gov/pubmed/12489055>
66. Dieckmann KP, Kulejewski M, Pichlmeier U, et al. Diagnosis of contralateral testicular intraepithelial neoplasia (TIN) in patients with testicular germ cell cancer: systematic two-site biopsies are more sensitive than a single random biopsy. *Eur Urol* 2007 Jan;51(1):175-83;discussion 183-5.
<http://www.ncbi.nlm.nih.gov/pubmed/16814456>
67. Kliesch S, Thomaidis T, Schütte B, et al. Update on the diagnostic safety for detection of testicular intraepithelial neoplasia (TIN). *APMIS* 2003 Jan;111(1):70-4.
<http://www.ncbi.nlm.nih.gov/pubmed/12752238>
68. Classen J, Dieckmann K, Bamberg M, et al. German Testicular Cancer Study Group. Radiotherapy with 16 Gy may fail to eradicate testicular intraepithelial neoplasia: preliminary communication of a dose-reduction trial of the German Testicular Cancer Study Group. *Br J Cancer* 2003 Mar;88(6):828-31.
<http://www.ncbi.nlm.nih.gov/pubmed/12644817>
69. Leibovitch I, Foster RS, Kopecky KK, et al. Improved accuracy of computerized tomography based clinical staging in low stage nonseminomatous germ cell cancer using size criteria of retroperitoneal lymph nodes. *J Urol* 1995 Nov;154(5):1759-63.
<http://www.ncbi.nlm.nih.gov/pubmed/7563341>
70. Jing B, Wallace S, Zornoza J. Metastases to retroperitoneal and pelvic lymph nodes: computed tomography and lymphangiography. *Radiol Clin North Am* 1982 Sep;20(3):511-30. [No abstract available]
<http://www.ncbi.nlm.nih.gov/pubmed/7051132>
71. Souchon R, Gertenbach U, Dieckmann KP, et al. Contralateral testicular cancer in spite of TIN-negative double biopsies and interval cisplatin chemotherapy. *J. Strahlenther Onkol* 2006 May;182(5):289-92.
<http://www.ncbi.nlm.nih.gov/pubmed/16673063>
72. Hoei-Hansen CE, Rajpert-De Meyts E, Daugaard G, et al. Carcinoma in situ testis, the progenitor of testicular germ cell tumours: a clinical review. *Ann Oncol* 2005 Jun;16(6):863-8.
<http://www.ncbi.nlm.nih.gov/pubmed/15821122>

73. Husband JE, Barrett A, Peckham MJ. Evaluation of computed tomography in the management of testicular teratoma. *Br J Urol* 1981 Apr;53(2):179-83.
<http://www.ncbi.nlm.nih.gov/pubmed/7237052>
74. Swanson DA. Role of retroperitoneal lymphadenectomy (RLDN) when patients with nonseminomatous germ cell testicular tumours are at high risk of needing lymph node surgery plus chemotherapy, in Donohue JP (ed.). *Lymph Node Surgery in Urology*. International Society of Urology Reports. Oxford: Isis Medical Media, 1995, pp. 133-140.
75. Ellis JH, Blies JR, Kopecky KK, et al. Comparison of NMR and CT imaging in the evaluation of metastatic retroperitoneal lymphadenopathy from testicular carcinoma. *J Comput Assist Tomogr* 1984 Aug;8(4):709-19.
<http://www.ncbi.nlm.nih.gov/pubmed/6539790>
76. Sohaib SA, Koh DM, Barbachano Y, et al. Prospective assessment of MRI for imaging retroperitoneal metastases from testicular germ cell tumours. *Clin Radiol* 2009 Apr;64(4):362-7.
<http://www.ncbi.nlm.nih.gov/pubmed/19264179>
77. See WA, Hoxie L. Chest staging in testis cancer patients: imaging modality selection based upon risk assessment as determined by abdominal computerized tomography scan results. *J Urol* 1993 Sep;150(3):874-8.
<http://www.ncbi.nlm.nih.gov/pubmed/8345604>
78. de Wit M, Brenner W, Hartmann M, et al. [18F]-FDG-PET in clinical stage I/II non-seminomatous germ cell tumours: results of the German multicentre trial. *Ann Oncol* 2008 Sep;19(9):1619-23.
<http://www.ncbi.nlm.nih.gov/pubmed/18453520>
79. Huddart RA, O'Doherty MJ, Padhani A, et al. NCRI Testis Tumour Clinical Study Group. 18fluorodeoxyglucose positron emission tomography in the prediction of relapse in patients with high-risk, clinical stage I nonseminomatous germ cell tumors: preliminary report of MRC Trial TE22--the NCRI Testis Tumour Clinical Study Group. *J Clin Oncol* 2007 Jul;25(21):3090-5.
<http://www.ncbi.nlm.nih.gov/pubmed/17634488>
80. Cremerius U, Wildberger JE, Borchers H, et al. Does positron emission tomography using 18-fluoro-2-deoxyglucose improve clinical staging of testicular cancer?- Results of a study in 50 patients. *Urology* 1999 Nov;54(5):900-4.
<http://www.ncbi.nlm.nih.gov/pubmed/10565755>
81. Albers P, Bender H, Yilmaz H, et al. Positron emission tomography in the clinical staging of patients with Stage I and II testicular germ cell tumours. *Urology* 1999 Apr;53(4):808-11.
<http://www.ncbi.nlm.nih.gov/pubmed/10197862>
82. De Santis M, Becherer A, Bokemeyer C, et al. 2-18fluoro-deoxy-D-glucose positron emission tomography is a reliable predictor for viable tumor in postchemotherapy seminoma: an update of the prospective multicentric SEMPET trial. *J Clin Oncol* 2004 Mar;22(6):1034-9.
<http://www.ncbi.nlm.nih.gov/pubmed/15020605>
83. Spermon JR, De Geus-Oei LF, Kiemeney LA, et al. The role of (18)fluoro-2-deoxyglucose positron emission tomography in initial staging and re-staging after chemotherapy for testicular germ cell tumours. *BJU Int* 2002 Apr;89(6):549-56.
<http://www.ncbi.nlm.nih.gov/pubmed/11942962>
84. Oechsle K, Hartmann M, Brenner W, et al. German Multicenter Positron Emission Tomography Study Group. [18F]Fluorodeoxyglucose positron emission tomography in nonseminomatous germ cell tumors after chemotherapy: the German multicenter positron emission tomography study group. *J Clin Oncol* 2008 Dec;26(36):5930-5.
<http://www.ncbi.nlm.nih.gov/pubmed/19018083>
85. Hinz S, Schrader M, Kempkensteffen C, et al. The role of positron emission tomography in the evaluation of residual masses after chemotherapy for advanced stage seminoma. *J Urol* 2008 Mar;179(3):936-40;discussion 940.
<http://www.ncbi.nlm.nih.gov/pubmed/18207171>
86. Zagars GK. Management of stage I seminoma: radiotherapy, in Horwich A (ed.). *Testicular Cancer: Investigation and Management*. London: Chapman & Hall Medical, 1999, p. 99.
87. Klepp O, Flodgren P, Maartman-Moe H, et al. Early clinical stages (CS1, CS1Mk+ and CS2A) of non-seminomatous testis cancer. Value of preand postorchidectomy serum tumour marker information in prediction of retroperitoneal lymph node metastases. Swedish-Norwegian Testicular Cancer Project (SWENOTECA). *Ann Oncol* 1990 Jul;1(4):281-8.
<http://www.ncbi.nlm.nih.gov/pubmed/1702312>
88. Schottenfeld D, Warshauer ME, Sherlock S, et al. The epidemiology of testicular cancer in young adults. *Am J Epidemiol* 1980 Aug;112(2):232-46. [No abstract available]
<http://www.ncbi.nlm.nih.gov/pubmed/6106385>

89. International Germ Cell Cancer Collaborative Group. International Germ Cell Consensus Classification: a prognostic factor-based staging system for metastatic germ cell cancers. *J Clin Oncol* 1997 Feb;15(2):594-603.
<http://www.ncbi.nlm.nih.gov/pubmed/9053482>
90. Aparicio J, Germà JR, García del Muro X, et al. Second Spanish Germ Cell Cancer Cooperative Group. Risk-adapted management for patients with clinical stage I seminoma: the Second Spanish Germ Cell Cancer Cooperative Group study. *J Clin Oncol* 2005 Dec;23(34):8717-23.
<http://www.ncbi.nlm.nih.gov/pubmed/16260698>
91. Bokemeyer C, Schmoll HJ. Treatment of clinical stage I testicular cancer and a possible role for new biological prognostic parameters. *J Cancer Res Clin Oncol* 1996;122(10):575-84.
<http://www.ncbi.nlm.nih.gov/pubmed/8879254>
92. Albers P, Siener R, Kliesch S, et al. German Testicular Cancer Study Group. Risk factors for relapse in clinical stage I nonseminomatous testicular germ cell tumours: results of the German Testicular Cancer Study Group Trial. *J Clin Oncol* 2003 Apr;21(8):1505-12.
<http://www.ncbi.nlm.nih.gov/pubmed/12697874>
93. Petersen PM, Giwercman A, Skakkebaek NE, et al. Gonadal function in men with testicular cancer. *Semin Oncol* 1998 Apr;25(2):224-33.
<http://www.ncbi.nlm.nih.gov/pubmed/9562456>
94. De Santis M, Albrecht W, Hörtl W, et al. Impact of cytotoxic treatment on long-term fertility in patients with germ-cell cancer. *Int J Cancer* 1999 Dec;83(6):864-5.
<http://www.ncbi.nlm.nih.gov/pubmed/10597213>
95. Jacobsen KD, Fosså SD, Bjørø TP, et al. Gonadal function and fertility in patients with bilateral testicular germ cell malignancy. *Eur Urol* 2002 Sep;42(3):229-38.
<http://www.ncbi.nlm.nih.gov/pubmed/12234507>
96. Kliesch S, Behre HM, Jürgens H, et al. Cryopreservation of semen from adolescent patients with malignancies. *Med Pediatr Oncol* 1996 Jan;26(1):20-7.
<http://www.ncbi.nlm.nih.gov/pubmed/7494508>
97. Giwercman A, von der Maase H, Rørth M, et al. Semen quality in testicular tumour and CIS in the contralateral testis. *Lancet* 1993 Feb;341(8841):384-5. [No abstract available]
<http://www.ncbi.nlm.nih.gov/pubmed/8094162>
98. Kliesch S, Bergmann M, Hertle L, et al. Semen parameters and testicular pathology in men with testicular cancer and contralateral carcinoma in situ or bilateral testicular malignancies. *Hum Reprod* 1997 Dec;12(12):2830-5.
<http://www.ncbi.nlm.nih.gov/pubmed/9455863>
99. Spermon JR, Kiemeneij LA, Meuleman EJ, et al. Fertility in men with testicular germ cell tumours. *Fertil Steril* 2003 Jun;79(Suppl 3):1543-9.
<http://www.ncbi.nlm.nih.gov/pubmed/12801557>
100. Nieschlag E, Behre HM. Pharmacology and clinical use of testosterone, in Nieschlag E, Behre HM (eds). *Testosterone-Action, Deficiency, Substitution*. Berlin-Heidelberg-New York: Springer, 1999, pp. 92-114.
101. Skoogh J, Steineck G, Cavallin-Ståhl E, et al. on behalf of SWENOTECA. Feelings of loss and uneasiness or shame after removal of a testicle by orchidectomy: a population-based long-term follow-up of testicular cancer survivors. *Int J Androl* 2011 Apr;34(2):183-92.
<http://www.ncbi.nlm.nih.gov/pubmed/20550599>
102. Jungwirth A, Diemer T, Dohle GR, et al. EAU Guidelines on Male Infertility. Edn. presented at the EAU Annual Congress 2013. ISBN 978-90-79754-71-7. Arnhem, The Netherlands.
<http://www.uroweb.org/guidelines/online-guidelines/>
103. Groll RJ, Warde P, Jewett MA. A comprehensive systematic review of testicular germ cell tumor surveillance. *Crit Rev Oncol Hematol* 2007 Dec;64(3):182-97.
<http://www.ncbi.nlm.nih.gov/pubmed/17644403>
104. Aparicio J, García del Muro X, Maroto P, et al. Spanish Germ Cell Cancer Cooperative Group (GG). Multicenter study evaluating a dual policy of postorchidectomy surveillance and selective adjuvant single-agent carboplatin for patients with clinical stage I seminoma. *Ann Oncol* 2003 Jun;14(6):867-72.
<http://www.ncbi.nlm.nih.gov/pubmed/12796024>
105. Chung P, Mayhew LA, Warde P, et al. Genitourinary Cancer Disease Site Group of Cancer Care Ontario's Program in Evidence-based Care. Management of stage I seminomatous testicular cancer: a systematic review. *Clin Oncol (R Coll Radiol)* 2010 Feb;22(1):6-16.
<http://www.ncbi.nlm.nih.gov/pubmed/19775876>

106. Tandstad T, Smaaland R, Solberg A, et al. Management of Seminomatous Testicular Cancer: A Binational Prospective Population-Based Study From the Swedish Norwegian Testicular Cancer Study Group (SWENOTECA). *J Clin Oncol* 2011 Feb;29(6):719-25.
<http://www.ncbi.nlm.nih.gov/pubmed/21205748>
107. Oliver RT, Mead GM, Rustin GJ, et al. Randomized trial of carboplatin versus radiotherapy for stage I seminoma: mature results on relapse and contralateral testis cancer rates in MRC TE19/EORTC 30982 study (ISRCTN27163214). *J Clin Oncol* 2011 Mar;29(8):957-62.
<http://www.ncbi.nlm.nih.gov/pubmed/21282539>
108. Oliver RT, Mason MD, Mead GM, et al. MRC TE19 collaborators and the EORTC 30982 collaborators. Radiotherapy versus single-dose carboplatin in adjuvant treatment of stage I seminoma: a randomised trial. *Lancet* 2005 Jul;366(9482):293-300.
<http://www.ncbi.nlm.nih.gov/pubmed/16039331>
109. Mead GM, Fossa SD, Oliver RT, et al. MRC/EORTC seminoma trial collaborators. Randomized trials in 2466 patients with stage I seminoma: patterns of relapse and follow-up. *J Natl Cancer Inst* 2011 Feb;103(3):241-9.
<http://www.ncbi.nlm.nih.gov/pubmed/21212385>
110. Aparicio J, Germà JR, García del Muro X, et al. The Second Spanish Germ Cell Cancer Cooperative Group. Risk-adapted management for patients with clinical stage I seminoma: the Second Spanish Germ Cell Cancer Cooperative Group study. *J Clin Oncol* 2005 Dec;23(34):8717-23.
<http://www.ncbi.nlm.nih.gov/pubmed/16260698>
111. Schoffski P, Höhn N, Kowalski R, et al. Health-related quality of life (QoL) in patients with seminoma stage I treated with either adjuvant radiotherapy (RT) or two cycles of carboplatinum chemotherapy (CT): Results of a randomized phase III trial of the German Interdisciplinary Working Party on Testicular Cancer. *ASCO Annual Meeting Proceedings. Part 1. J Clin Oncol* 2007;25(Suppl 18S):5050.
http://www.asco.org/ASCOv2/Meetings/Abstracts?&vmview=abst_detail_view&confID=47&abstractID=32158
112. Fosså SD, Horwich A, Russell JM, et al. Optimal planning target volume for stage I testicular seminoma: A Medical Research Council Testicular Tumor Working Group randomized trial. *J Clin Oncol* 1999 Apr;17(4):1146.
<http://www.ncbi.nlm.nih.gov/pubmed/10561173>
113. Jones WG, Fossa SD, Mead GM, et al. A randomized trial of two radiotherapy schedules in the adjuvant treatment of stage I seminoma (MRC TE 18). *Eur J Cancer* 2001;37(Suppl 6):S157, abstr 572. [No abstract available]
[http://dx.doi.org/10.1016/S0959-8049\(01\)81064-9](http://dx.doi.org/10.1016/S0959-8049(01)81064-9) HYPERLINK "http://www.sciencedirect.com/science/help/doi.htm"
114. Melchior D, Hammer P, Fimmers R, et al. Long term results and morbidity of paraaortic compared with paraaortic and iliac adjuvant radiation in clinical stage I seminoma. *Anticancer Res* 2001 Jul-Aug;21(4B):2989-93.
<http://www.ncbi.nlm.nih.gov/pubmed/11712799>
115. Livsey JE, Taylor B, Mobarek N, et al. Patterns of relapse following radiotherapy for stage I seminoma of the testis: implications for follow-up. *Clin Oncol (R Coll Radiol)* 2001;13(4):296-300.
<http://www.ncbi.nlm.nih.gov/pubmed/11554630>
116. Van Leeuwen FE, Stiggelbout AM, van den Belt-Dusebout AW, et al. Second cancer risk following testicular cancer: a follow-up study of 1,909 patients. *Clin Oncol* 1993 Mar;11(3):415-24.
<http://www.ncbi.nlm.nih.gov/pubmed/8445415>
117. Travis LB, Curtis RE, Storm H, et al. Risk of second malignant neoplasms among long-term survivors of testicular cancer. *J Natl Cancer Inst* 1997 Oct;89(19):1429-39.
<http://www.ncbi.nlm.nih.gov/pubmed/9326912>
118. Robinson D, Møller H, Horwich A. Mortality and incidence of second cancers following treatment for testicular cancer. *Br J Cancer* 2007 Feb;96(3):529-33.
<http://www.ncbi.nlm.nih.gov/pubmed/17262080>
119. Bieri S, Rouzaud M, Miralbell R. Seminoma of the testis: is scrotal shielding necessary when radiotherapy is limited to the para-aortic nodes? *Radiother Oncol* 1999 Mar;50(3):349-53.
<http://www.ncbi.nlm.nih.gov/pubmed/10392822>
120. van den Belt-Dusebout AW, de Wit R, Gietema JA, et al. Treatment-specific risks of second malignancies and cardiovascular disease in 5-year survivors of testicular cancer. *J Clin Oncol* 2007 Oct;25(28):4370-8.
<http://www.ncbi.nlm.nih.gov/pubmed/17906202>
121. Warszawski N, Schmucking M. Relapses in early-stage testicular seminoma: radiation therapy versus retroperitoneal lymphadenectomy. *Scan J Urol Nephrol* 1997 Aug;31(4):335-9.
<http://www.ncbi.nlm.nih.gov/pubmed/9290165>

122. Aparicio J, Maroto P, del Muro XG, et al. Risk-adapted treatment in clinical stage I testicular seminoma: the third Spanish Germ Cell Cancer Group study. *J Clin Oncol* 2011 Dec;29(35):4677-81.
<http://www.ncbi.nlm.nih.gov/pubmed/22042940>
123. Freedman LS, Parkinson MC, Jones WG, et al. Histopathology in the prediction of relapse of patients with stage I testicular teratoma treated by orchidectomy alone. *Lancet* 1987 Aug;2(8554):294-8.
<http://www.ncbi.nlm.nih.gov/pubmed/2886764>
124. Read G, Stenning SP, Cullen MH, et al. Medical Research Council prospective study of surveillance for stage I testicular teratoma. *J Clin Oncol* 1992 Nov;10(11):1762-8.
<http://www.ncbi.nlm.nih.gov/pubmed/1403057>
125. Colls BM, Harvey VJ, Skelton L, et al. Late results of surveillance of clinical stage I nonseminoma germ cell testicular tumours: 17 years' experience in a national study in New Zealand. *Br J Urol Int* 1999 Jan;83(1):76-82.
<http://www.ncbi.nlm.nih.gov/pubmed/10233456>
126. Oliver RT, Ong J, Shamash J, et al. Anglian Germ Cell Cancer Group. Long-term follow-up of Anglian Germ Cell Cancer Group surveillance versus patients with Stage 1 nonseminoma treated with adjuvant chemotherapy. *Urology* 2004 Mar;63(3):556-61.
<http://www.ncbi.nlm.nih.gov/pubmed/15028457>
127. Zuniga A, Kakiashvili D, Jewett MA. Surveillance in stage I nonseminomatous germ cell tumours of the testis. *BJU Int* 2009 Nov;104(9 Pt B):1351-6. [No abstract available]
<http://www.ncbi.nlm.nih.gov/pubmed/19840012>
128. Klepp O, Olsson AM, Henrikson H, et al. Prognostic factors in clinical stage I nonseminomatous germ cell tumours of the testis: multivariate analysis of a prospective multicenter study. *J Clin Oncol* 1990 Mar;8(3):509-18.
<http://www.ncbi.nlm.nih.gov/pubmed/1689773>
129. Kakiashvili D, Anson-Cartwright L, Sturgeon JF, et al. Non risk-adapted surveillance management for clinical stage I nonseminomatous testis tumors. *J Urol* 2007;177:278 (abstr #835).
<http://www.ncbi.nlm.nih.gov/pubmed/21190791>
130. Kollmannsberger C, Moore C, Chi KN, et al. Non-risk-adapted surveillance for patients with stage I nonseminomatous testicular germ-cell tumors: diminishing treatment-related morbidity while maintaining efficacy. *Ann Oncol* 2010 Jun;21(6):1296-301.
<http://www.ncbi.nlm.nih.gov/pubmed/19875756>
131. Cullen MH, Stenning SP, Parkinson MC, et al. Short-course adjuvant chemotherapy in high-risk stage I nonseminomatous germ cell tumors of the testis: a Medical Research Council report. *J Clin Oncol* 1996 Apr;14(4):1106-13.
<http://www.ncbi.nlm.nih.gov/pubmed/8648364>
132. Oliver RT, Raja MA, Ong J, et al. Pilot study to evaluate impact of a policy of adjuvant chemotherapy for high risk stage I malignant teratoma on overall relapse rate of stage I cancer patients. *J Urol* 1992 Nov;148(5):1453-6.
<http://www.ncbi.nlm.nih.gov/pubmed/1279211>
133. Studer UE, Fey MF, Calderoni A, et al. Adjuvant chemotherapy after orchidectomy in high-risk patients with clinical stage I nonseminomatous testicular cancer. *Eur Urol* 1993;23(4):444-9.
<http://www.ncbi.nlm.nih.gov/pubmed/7687549>
134. Böhlen D, Borner M, Sonntag RW, et al. Long-term results following adjuvant chemotherapy in patients with clinical stage I testicular nonseminomatous malignant germ cell tumors with high risk factors. *J Urol* 1999 Apr;161(4):1148-52.
<http://www.ncbi.nlm.nih.gov/pubmed/10081858>
135. Pont J, Albrecht W, Postner G, et al. Adjuvant chemotherapy for high-risk clinical stage I nonseminomatous testicular germ cell cancer: long-term results of a prospective trial. *J Clin Oncol* 1996 Feb;14(2):441-8.
<http://www.ncbi.nlm.nih.gov/pubmed/8636755>
136. Chevreau C, Mazerolles C, Soulié M, et al. Long-term efficacy of two cycles of BEP regimen in high-risk stage I nonseminomatous testicular germ cell tumors with embryonal carcinoma and/or vascular invasion. *Eur Urol* 2004 Aug;46(2):209-14.
<http://www.ncbi.nlm.nih.gov/pubmed/15245815>
137. Böhlen D, Burkhard FC, Mills R, et al. Fertility and sexual function following orchidectomy and 2 cycles of chemotherapy for stage I high risk nonseminomatous germ cell cancer. *J Urol* 2001 Feb;165(2):441-4.
<http://www.ncbi.nlm.nih.gov/pubmed/11176393>

138. Huddart RA, Norman A, Shahidi M, et al. Cardiovascular disease as a long-term complication of treatment for testicular cancer. *J Clin Oncol* 2003 Apr;21(8):1513-23.
<http://www.ncbi.nlm.nih.gov/pubmed/12697875>
139. Baniel J, Foster RS, Gonin R, et al. Late relapse of testicular cancer. *J Clin Oncol* 1995 May;13(5):1170-6.
<http://www.ncbi.nlm.nih.gov/pubmed/7537800>
140. Baniel J, Roth BJ, Foster RS, et al. Cost- and risk-benefit considerations in the management of clinical stage I nonseminomatous testicular tumors. *Ann Surg Oncol* 1996 Jan;3(1):86-93.
<http://www.ncbi.nlm.nih.gov/pubmed/8770308>
141. Rustin GJ, Mead GM, Stenning SP, et al. National Cancer Research Institute Testis Cancer Clinical Studies Group. Randomized trial of two or five computed tomography scans in the surveillance of patients with stage I nonseminomatous germ cell tumors of the testis: Medical Research Council Trial TE08, ISRCTN56475197-the National Cancer Research Institute Testis Cancer Clinical Studies Group. *J Clin Oncol* 2007 Apr;25(11):1310-5.
<http://www.ncbi.nlm.nih.gov/pubmed/17416851>
142. Klepp O, Dahl O, Flodgren P et al. Riskadapted treatment of clinical stage 1 non-seminoma testis cancer. *Eur J Cancer* 1997 Jun;33(7):1038-44.
<http://www.ncbi.nlm.nih.gov/pubmed/9376184>
143. Ondrus D, Matoska J, Belan V, et al. Prognostic factors in clinical stage I nonseminomatous germ cell testicular tumors: rationale for different risk-adapted treatment. *Eur Urol* 1998;33(6):562-6.
<http://www.ncbi.nlm.nih.gov/pubmed/9743698>
144. Maroto P, García del Muro X, Aparicio J, et al. Multicentre risk-adapted management for stage I non-seminomatous germ cell tumours. *Ann Oncol* 2005 Dec;16(12):1915-20.
<http://www.ncbi.nlm.nih.gov/pubmed/16126737>
145. Tandstad T, Cohn-Cedermark G, Dahl O, et al. Long-term follow-up after risk-adapted treatment in clinical stage 1 (CS1) nonseminomatous germ-cell testicular cancer (NSGCT) implementing adjuvant CVB chemotherapy. A SWENOTECA study. *Ann Oncol* 2010 Sep;21(9):1858-63.
<http://www.ncbi.nlm.nih.gov/pubmed/20142410>
146. Tandstad T, Dahl O, Cohn-Cedermark G, et al. Risk-adapted treatment in clinical stage I nonseminomatous germ cell testicular cancer: the SWENOTECA management program. *J Clin Oncol* 2009 May;27(13):2122-8.
<http://www.ncbi.nlm.nih.gov/pubmed/19307506>
147. Heidenreich A, Albers P, Hartmann M, et al. German Testicular Cancer Study Group. Complications of primary nerve sparing retroperitoneal lymph node dissection for clinical stage I nonseminomatous germ cell tumours of the testis: experience of the German Testicular Cancer Study Group. *J Urol* 2003 May;169(5):1710-4.
<http://www.ncbi.nlm.nih.gov/pubmed/12686815>
148. Spermon JR, Roeleveld TA, van der Poel HG, et al. Comparison of surveillance and retroperitoneal lymph node dissection in stage I nonseminomatous germ cell tumors. *Urology* 2002 Jun;59(6):923-9.
<http://www.ncbi.nlm.nih.gov/pubmed/12031382>
149. Hendry WF, Norman A, Nicholls J, et al. Abdominal relapse in Stage 1 nonseminomatous germ cell tumours of the testis managed by surveillance or with adjuvant chemotherapy. *BJU Int* 2000 Jul;86(1):89-93.
<http://www.ncbi.nlm.nih.gov/pubmed/10886090>
150. Pizzocaro G, Salvioni R, Zanoni F. Unilateral lymphadenectomy in intraoperative stage I nonseminomatous germinal testis cancer. *J Urol* 1985 Sep;134(3):485-9.
<http://www.ncbi.nlm.nih.gov/pubmed/2993672>
151. Donohue JP, Thornhill JA, Foster RS, et al. Retroperitoneal lymphadenectomy for clinical stage A testis cancer (1965 to 1989): modifications of technique and impact on ejaculation. *J Urol* 1993 Feb;149(2):237-43.
<http://www.ncbi.nlm.nih.gov/pubmed/8381190>
152. Lashley DB, Lowe BA. A rational approach to managing stage I nonseminomatous germ cell cancer. *Urol Clin North Am* 1998 Aug;25(3):405-23.
<http://www.ncbi.nlm.nih.gov/pubmed/9728211>
153. Foster RS, Roth BJ. Clinical stage I nonseminoma: surgery versus surveillance. *Semin Oncol* 1998 Apr;25(2):145-53.
<http://www.ncbi.nlm.nih.gov/pubmed/9562447>
154. Kratzik C, Holtl W, Albrecht W, et al. Risk adapted management for NSGCT stage I: long-term results of a multicenter study. *J Urol* 1996;155:547A.

155. Ondrus D, Goncalves F, Kausitz J, et al. The value of prognostic factors in the management of stage I nonseminomatous germ cell testicular tumors (NSGCTT). *Neoplasma* 1996;43(3):195-7.
<http://www.ncbi.nlm.nih.gov/pubmed/8841507>
156. Donohue JP, Thornhill JA, Foster RS, et al. Clinical stage B non-seminomatous germ cell testis cancer: the Indiana University experience (1965-1989) using routine primary retroperitoneal lymph node dissection. *Eur J Cancer* 1995 Sep;31A(10):1599-604.
<http://www.ncbi.nlm.nih.gov/pubmed/7488408>
157. Richie JP, Kantoff PW. Is adjuvant chemotherapy necessary for patients with stage B1 testicular cancer? *J Clin Oncol* 1991 Aug;9(8):1393-6.
<http://www.ncbi.nlm.nih.gov/pubmed/2072143>
158. Pizzocaro G, Monfardini S. No adjuvant chemotherapy in selected patients with pathological stage II nonseminomatous germ cell tumors of the testis. *J Urol* 1984 Apr;131(4):677-80.
<http://www.ncbi.nlm.nih.gov/pubmed/6200611>
159. Williams SD, Stablein DM, Einhorn LH, et al. Immediate adjuvant chemotherapy versus observation with treatment at relapse in pathological stage II testicular cancer. *N Engl J Med* 1987 Dec;317(23):1433-8.
<http://www.ncbi.nlm.nih.gov/pubmed/2446132>
160. Bianci G, Beltrami P, Giusti G, et al. Unilateral laparoscopic lymph node dissection for clinical stage I nonseminomatous germ cell testicular neoplasm. *Eur Urol* 1998;33(2):190-4.
<http://www.ncbi.nlm.nih.gov/pubmed/9519363>
161. Rassweiler JJ, Frede T, Lenz E, et al. Long-term experience with laparoscopic retroperitoneal lymph node dissection in the management of low-stage testis cancer. *Eur Urol* 2000 Mar;37(3):251-60.
<http://www.ncbi.nlm.nih.gov/pubmed/10720848>
162. Janetschek G, Hobisch A, Peschel R, et al. Laparoscopic retroperitoneal lymph node dissection for clinical stage I non-seminomatous testicular carcinoma: long-term outcome. *J Urol* 2000 Jun;163(6):1793-6.
<http://www.ncbi.nlm.nih.gov/pubmed/10799184>
163. LeBlanc E, Caty A, Dargent D, et al. Extraperitoneal laparoscopic para-aortic lymph node dissection for early stage nonseminomatous germ cell tumors of the testis with introduction of a nerve sparing technique: description and results. *J Urol* 2001 Jan;165(1):89-92.
<http://www.ncbi.nlm.nih.gov/pubmed/11125371>
164. Albers P, Siener R, Krege S, et al. German Testicular Cancer Study Group. Randomized phase III trial comparing retroperitoneal lymph node dissection with one course of bleomycin and etoposide plus cisplatin chemotherapy in the adjuvant treatment of clinical stage I Nonseminomatous testicular germ cell tumors: AUO trial AH 01/94 by the German Testicular Cancer Study Group. *J Clin Oncol* 2008 Jun;26(18):2966-72.
<http://www.ncbi.nlm.nih.gov/pubmed/18458040>
165. Pizzocaro G, Nicolai N, Salvioni R. Marker positive clinical stage I non seminomatous germ cell tumours (NSGCT) of the testis: which primary therapy? *J Urol* 1996;155(Suppl):328A.
166. Davis BE, Herr HW, Fair WR, et al. The management of patients with nonseminomatous germ cell tumors of the testis with serologic disease only after orchidectomy. *J Urol* 1994 Jul;152(1):111-3.
<http://www.ncbi.nlm.nih.gov/pubmed/7515445>
167. International Germ Cell Collaborative Group. International Germ Cell Consensus Classification: a prognostic factor-based staging system for metastatic germ cell cancers. *J Clin Oncol* 1997 Feb;15(2):594-603.
<http://www.ncbi.nlm.nih.gov/pubmed/9053482>
168. Classen J, Schmidberger H, Meisner C, et al. Radiotherapy for stages IIA/B testicular seminoma: final report of a prospective multicenter clinical trial. *J Clin Oncol* 2003 Mar;21(6):1101-6.
<http://www.ncbi.nlm.nih.gov/pubmed/12637477>
169. Chung PW, Gospodarowicz MK, Panzarella T, et al. Stage II testicular seminoma: patterns of recurrence and outcome of treatment. *Eur Urol* 2004 Jun;45(6):754-59;discussion 759-60.
<http://www.ncbi.nlm.nih.gov/pubmed/15149748>
170. Garcia-del-Muro X, Maroto P, Gumà J, et al. Chemotherapy as an alternative to radiotherapy in the treatment of stage IIA and IIB testicular seminoma: a Spanish Germ Cell Cancer Group Study. *J Clin Oncol* 2008 Nov;26(33):5416-21.
<http://www.ncbi.nlm.nih.gov/pubmed/18936476>
171. Krege S, Boergermann C, Baschek R, et al. German Testicular Cancer Study Group (GTCSG). Single agent carboplatin for CS IIA/B testicular seminoma. A phase II study of the German Testicular Cancer Study Group (GTCSG). *Ann Oncol* 2006 Feb;17(2):276-80.
<http://www.ncbi.nlm.nih.gov/pubmed/16254023>

172. Frohlich MW, Small EJ. Stage II nonseminomatous testis cancer: the roles of primary and adjuvant chemotherapy. *Urol Clin North Am* 1998 Aug;25(3):451-9.
<http://www.ncbi.nlm.nih.gov/pubmed/9728214>
173. Baniel J, Donohue JP. Cost and risk benefit considerations in low stage (I and II) nonseminomatous testicular tumours. *AUA Update Series* 1997;26:50-5.
174. Peckham MJ, Hendry WF. Clinical stage II non-seminatous germ cell testicular tumors. Results of management by primary chemotherapy. *Br J Urol* 1985 Dec;57(6):763-8.
<http://www.ncbi.nlm.nih.gov/pubmed/2417652>
175. Logothetis CJ, Samuels ML, Selig DE, et al. Primary chemotherapy followed by a selective retroperitoneal lymphadenectomy in the management of clinical stage II testicular carcinoma: a preliminary report. *J Urol* 1985 Dec;134(6):1127-30.
<http://www.ncbi.nlm.nih.gov/pubmed/2414470>
176. Horwich A, Stenning S. Initial chemotherapy for stage II testicular non-seminoma. *World J Urol* 1994;12(3):148-50.
<http://www.ncbi.nlm.nih.gov/pubmed/7951341>
177. Weissbach L, Bussar-Maatz R, Fletchner H, et al. RPLND or primary chemotherapy in clinical stage IIA/B nonseminomatous germ cell tumors. Results of a prospective multicenter trial including quality of life assessment. *Eur Urol* 2000 May;37(5):582-94.
<http://www.ncbi.nlm.nih.gov/pubmed/10765098>
178. Sternberg CN. Role of primary chemotherapy in stage I and low-volume stage II nonseminomatous germ-cell testis tumors. *Urol Clin North Am* 1993 Feb;20(1):93-109.
<http://www.ncbi.nlm.nih.gov/pubmed/8382000>
179. Horwich A, Norman A, Fisher C, et al. Primary chemotherapy for stage II nonseminomatous germ cell tumors of the testis. *J Urol* 1994 Jan;151(1):72-7.
<http://www.ncbi.nlm.nih.gov/pubmed/8254836>
180. Donohue JP, Thornhill JA, Foster RS, et al. The role of retroperitoneal lymphadenectomy in clinical stage B testis cancer: the Indiana University Experience (1965 to 1989). *J Urol* 1995 Jan;153(1):85-9.
<http://www.ncbi.nlm.nih.gov/pubmed/7966799>
181. Motzer RJ, Sheinfeld J, Mazumdar M, et al. Etoposide and cisplatin adjuvant therapy for patients with pathological stage II germ cell tumors. *J Clin Oncol* 1995 Nov;13(11):2700-4.
<http://www.ncbi.nlm.nih.gov/pubmed/7595727>
182. Hartlapp JH, Weissbach L, Bussar-Maatz R. Adjuvant chemotherapy in nonseminomatous testicular tumour stage II. *Int J Androl* 1987 Feb;10(1):277-84.
<http://www.ncbi.nlm.nih.gov/pubmed/2438221>
183. Logothetis CJ, Swanson DA, Dexeus F, et al. Primary chemotherapy for clinical stage II nonseminomatous germ cell tumors of the testis: a follow-up of 50 patients. *J Clin Oncol* 1987 Jun;5(6):906-11.
<http://www.ncbi.nlm.nih.gov/pubmed/2438389>
184. Saxman SB, Finch D, Gonin R, et al. Long-term follow-up of a phase III study of three versus four cycles of bleomycin, etoposide and cisplatin in favorable-prognosis germ-cell tumors: the Indiana University Experience. *J Clin Oncol* 1998 Feb;16(2):702-6.
<http://www.ncbi.nlm.nih.gov/pubmed/9469360>
185. de Wit R, Stoter G, Kaye SB, et al. Importance of bleomycin in combination chemotherapy for good-prognosis testicular nonseminoma: a randomized study of the European Organization for Research and Treatment of Cancer Genitourinary Tract Cancer Cooperative Group. *J Clin Oncol* 1997 May;15(5):1837-43.
<http://www.ncbi.nlm.nih.gov/pubmed/9164193>
186. Horwich A, Sleijfer DT, Fosså SD, et al. Randomized trial of bleomycin, etoposide and cisplatin compared with bleomycin, etoposide and carboplatin in good-prognosis metastatic nonseminomatous germ cell cancer: a Multiinstitutional Medical Research Council/European Organization for Research and Treatment of Cancer trial. *J Clin Oncol* 1997 May;15(5):1844-52.
<http://www.ncbi.nlm.nih.gov/pubmed/9164194>
187. De Wit R, Roberts JT, Wilkinson PM, et al. Equivalence of three or four cycles of bleomycin, etoposide, and cisplatin chemotherapy and of a 3- or 5- day schedule in good-prognosis germ cell cancer: a randomized study of the European Organization for Research and Treatment of Cancer Genitourinary Tract Cancer Cooperative Group and the Medical research Council. *J Clin Oncol* 2001 Mar;19(6):1629-40.
<http://www.ncbi.nlm.nih.gov/pubmed/11250991>

188. Bokemeyer C, Kuczyk MA, Köhne H, et al. Hematopoietic growth factors and treatment of testicular cancer: biological interactions, routine use and dose-intensive chemotherapy. *Ann Hematol* 1996 Jan;72(1):1-9.
<http://www.ncbi.nlm.nih.gov/pubmed/8605273>
189. Xiao H, Mazumdar M, Bajorin DF, et al. Longterm follow-up of patients with good-risk germ cell tumors treated with etoposide and cisplatin. *J Clin Oncol* 1997 Jul;15(7):2553-8.
<http://www.ncbi.nlm.nih.gov/pubmed/9215824>
190. Culine S, Kerbrat P, Kramar A, et al. Genito-Urinary Group of the French Federation of Cancer Center (GETUG T93BP). Refining the optimal chemotherapy regimen for good-risk metastatic nonseminomatous germ-cell tumors: a randomized trial of the Genito-Urinary Group of the French Federation of Cancer Centers (GETUG T93BP). *Ann Oncol* 2007 May;18(5):917-24.
<http://www.ncbi.nlm.nih.gov/pubmed/17351252>
191. Grimison PS, Stockler MR, Thomson DB, et al. J Natl Cancer Inst 2010. Comparison of two standard chemotherapy regimens for good-prognosis germ cell tumors: updated analysis of a randomized trial. *J Natl Cancer Inst.* 2010 Aug;102(16):1253-62.
<http://www.ncbi.nlm.nih.gov/pubmed/20631341>
192. Fosså SD, Kaye SB, Mead GM, et al. Filgastrim during combination chemotherapy of patients with poor prognosis metastatic germ cell malignancy. European Organization for Research and Treatment of Cancer, Genito-Urinary Group, and the Medical Research Council Testicular Cancer Working Party, Cambridge, United Kingdom. *J Clin Oncol* 1998 Feb;16(2):716-24.
<http://www.ncbi.nlm.nih.gov/pubmed/9469362>
193. De Wit R, Stoter G, Sleijfer DT, et al. Four cycles of BEP vs four cycles of VIP in patients with intermediate-prognosis metastatic testicular non-seminoma: a randomized study of the EORTC Genitourinary Tract Cancer Cooperative Group. European Organization for Research and Treatment of Cancer. *Br J Cancer* 1998 Sep;78(6):828-32.
<http://www.ncbi.nlm.nih.gov/pubmed/9743309>
194. De Wit R, Louwerens M, de Mulder PH, et al. Management of intermediate-prognosis germ-cell cancer: results of a phase I/II study of Taxol-BEP. *Int J Cancer* 1999 Dec;83(6):831-3.
<http://www.ncbi.nlm.nih.gov/pubmed/10597204>
195. Nichols CR, Catalano PJ, Crawford ED, et al. Randomized comparison of cisplatin and etoposide and either bleomycin or ifosfamide in treatment of advanced disseminated germ cell tumors: an Eastern Cooperative Oncology Group, Southwest Oncology Group, and Cancer and Leukemia Group B Study. *J Clin Oncol* 1998 Apr;16(4):1287-93.
<http://www.ncbi.nlm.nih.gov/pubmed/9552027>
196. Motzer RJ, Nichols CJ, Margolin KA, et al. Phase III randomized trial of conventional-dose chemotherapy with or without high-dose chemotherapy and autologous hematopoietic stem-cell rescue as first-line treatment for patients with poor-prognosis metastatic germ cell tumors. *J Clin Oncol* 2007 Jan;25(3):247-56.
<http://www.ncbi.nlm.nih.gov/pubmed/17235042>
197. Droz JP, Kramar A, Biron P, et al. Genito-Urinary Group of the French Federation of Cancer Centers (GETUG). Failure of high-dose cyclophosphamide and etoposide combined with double-dose cisplatin and bone marrow support in patients with high-volume metastatic nonseminomatous germ-cell tumours: mature results of a randomised trial. *Eur Urol* 2007 Mar;51(3):739-46;discussion 747-8.
<http://www.ncbi.nlm.nih.gov/pubmed/17084512>
198. Daugaard G, Skoneczna I, Aass N, et al. A randomized phase III study comparing standard dose BEP with sequential high-dose cisplatin, etoposide, and ifosfamide (VIP) plus stem-cell support in males with poor-prognosis germ-cell cancer. An intergroup study of EORTC, GTCSSG, and Grupo Germinal (EORTC 30974). *Ann Oncol* 2011 May;22(5):1054-61.
<http://www.ncbi.nlm.nih.gov/pubmed/21059637>
199. Motzer RJ, Mazumdar M, Bajorin DF, et al. High-dose carboplatin, etoposide, and cyclophosphamide with autologous bone marrow transplantation in first-line therapy for patients with poor-risk germ cell tumors. *J Clin Oncol* 1997 Jul;15(7):2546-52.
<http://www.ncbi.nlm.nih.gov/pubmed/9215823>
200. Bokemeyer C, Kollmannsberger C, Meisner C, et al. First-line high-dose chemotherapy compared with standard-dose PEB/VIP chemotherapy in patients with advanced germ cell tumors: a multivariate and matched-pair analysis. *J Clin Oncol* 1999 Nov;17(11):3450-6.
<http://www.ncbi.nlm.nih.gov/pubmed/10550141>

201. Fizazi K, Culine S, Kramar A, et al. Early predicted time to normalization of tumor markers predicts outcome in poor-prognosis nonseminomatous germ cell tumors. *J Clin Oncol* 2004 Oct;22(19):3868-76.
<http://www.ncbi.nlm.nih.gov/pubmed/15302906>
202. Massard C, Plantade A, Gross-Goupil M, et al. Poor prognosis nonseminomatous germ-cell tumours (NSGCTs): should chemotherapy doses be reduced at first cycle to prevent acute respiratory distress syndrome in patients with multiple lung metastases? *Ann Oncol* 2010 Aug;21(8):1585-8.
<http://www.ncbi.nlm.nih.gov/pubmed/20181575>
203. Gerl A, Clemm C, Lamerz R, et al. Prognostic implications of tumour marker analysis in non-seminomatous germ cell tumours with poor prognosis metastatic disease. *Eur J Cancer* 1993;29A(7):961-5.
<http://www.ncbi.nlm.nih.gov/pubmed/7684597>
204. Murphy BA, Motzer RJ, Mazumdar M, et al. Serum tumour marker decline is an early predictor of treatment outcome in germ cell tumour patients treated with cisplatin and ifosfamide salvage chemotherapy. *Cancer* 1994 May;73(10):2520-6.
<http://www.ncbi.nlm.nih.gov/pubmed/7513603>
205. André F, Fizazi K, Culine S, et al. The growing teratoma syndrome: results of therapy and long-term follow-up of 33 patients. *Eur J Cancer* 2000 Jul;36(11):1389-94.
<http://www.ncbi.nlm.nih.gov/pubmed/10899652>
206. De Wit R, Collette L, Sylvester R, et al. Serum alpha-fetoprotein surge after the initiation of chemotherapy for non-seminomatous testicular cancer has an adverse prognostic significance. *Br J Cancer* 1998 Nov;78(10):1350-5.
<http://www.ncbi.nlm.nih.gov/pubmed/9823978>
207. Zon RT, Nichols C, Einhorn LH. Management strategies and outcomes of germ cell tumour patients with very high human chorionic gonadotropin levels. *J Clin Oncol* 1998 Apr;16(4):1294-7.
<http://www.ncbi.nlm.nih.gov/pubmed/9552028>
208. Fosså SD, Stenning SP, Gerl A, et al. Prognostic factors in patients progressing after cisplatin-based chemotherapy for malignant non-seminomatous germ cell tumours. *Br J Cancer* 1999 Jul;80(9):1392-9.
<http://www.ncbi.nlm.nih.gov/pubmed/10424741>
209. Fosså SD, Borge L, Aass N, et al. The treatment of advanced metastatic seminoma: experience in 55 cases. *J Clin Oncol* 1987 Jul;5(7):1071-7.
<http://www.ncbi.nlm.nih.gov/pubmed/2439660>
210. Herr HW, Bosl G. Residual mass after after chemotherapy for seminoma: changing concepts of management. *J Urol* 1987 Jun;137(6):1234-5.
<http://www.ncbi.nlm.nih.gov/pubmed/2438431>
211. Hofmockel G, Gruss A, Theiss M. Chemotherapy in advanced seminoma and the role of postcytostatic retroperitoneal lymph node dissection. *Urol Int* 1996;57(1):38-42.
<http://www.ncbi.nlm.nih.gov/pubmed/8840489>
212. Kamat MR, Kulkarni JN, Tongoankar HB, et al. Value of retroperitoneal lymph node dissection in advanced testicular seminoma. *J Surg Oncol* 1992 Sep;51(1):65-7.
<http://www.ncbi.nlm.nih.gov/pubmed/1381455>
213. Loehrer PJ Sr, Birch R, Williams SD, et al. Chemotherapy of metastatic seminoma: the Southeastern Cancer Study Group experience. *J Clin Oncol* 1987 Aug;5(8):1212-20.
<http://www.ncbi.nlm.nih.gov/pubmed/2442317>
214. Motzer R, Bosl G, Heelan R, et al. Residual mass: an indication for further therapy in patients with advanced seminoma following systemic chemotherapy. *J Clin Oncol* 1987 Jul;5(7):1064-70.
<http://www.ncbi.nlm.nih.gov/pubmed/3598610>
215. Peckham MJ, Horwich A, Hendry WF. Advanced seminoma treatment with cisplatin based combination chemotherapy or carboplatin (JM8). *Br J Cancer* 1985 Jul;52(1):7-13.
<http://www.ncbi.nlm.nih.gov/pubmed/3893507>
216. De Santis M, Becherer A, Bokemeyer C, et al. Pont J. 2-18fluoro-deoxy-D-glucose positron emission tomography is a reliable predictor for viable tumor in postchemotherapy seminoma: an update of the prospective multicentric SEMPET trial. *J Clin Oncol* 2004 Mar;22(6):1034-9.
<http://www.ncbi.nlm.nih.gov/pubmed/15020605>
217. Duchesne GM, Stenning SP, Aass N, et al. Radiotherapy after chemotherapy for metastatic seminoma - a diminishing role. MRC Testicular Tumour Working Party. *Eur J Cancer* 1997 May;33(6):829-35.
<http://www.ncbi.nlm.nih.gov/pubmed/9291801>

218. Bamberg M, Classen J. [Value of radiotherapy of residual tumors after chemotherapy of metastatic seminomas] *Strahlenther Onkol* 1998 Aug;174(8):442-3. [Article in German] [No abstract available] <http://www.ncbi.nlm.nih.gov/pubmed/9739390>
219. Puc H, Heelan R, Mazumdar M, et al. Management of residual mass in advanced seminoma: results and recommendations from the Memorial Sloan-Kettering Cancer Center. *J Clin Oncol* 1996 Feb;14(2):454-60. <http://www.ncbi.nlm.nih.gov/pubmed/8636757>
220. Herr HW, Sheinfeld J, Puc HS, et al. Surgery for a post-chemotherapy residual mass in seminoma. *J Urol* 1997 Mar;157(3):860-2. <http://www.ncbi.nlm.nih.gov/pubmed/9072586>
221. Mosharafa AA, Foster RS, Leibovich BC, et al. Is the post-chemotherapy resection of seminomatous elements associated with higher acute morbidity? *J Urol* 2003 Jun;169(6):2126-8. <http://www.ncbi.nlm.nih.gov/pubmed/12771733>
222. Kuczyk M, Machtens S, Stief C, et al. Management of the post-chemotherapy residual mass in patients with advanced stage non-seminomatous germ cell tumors (NSGCT). *Int J Cancer* 1999 Dec;83(6):852-5. <http://www.ncbi.nlm.nih.gov/pubmed/10597210>
223. Fosså SD, Ous S, Lien HH, et al. Post-chemotherapy lymph node histology in radiologically normal patients with metastatic nonseminomatous testicular cancer. *J Urol* 1989 Mar;141(3):557-9. <http://www.ncbi.nlm.nih.gov/pubmed/2918591>
224. Toner GC, Panicek DM, Heelan RT, et al. Adjunctive surgery after chemotherapy for nonseminomatous germ cell tumors: recommendations for patient selection. *J Clin Oncol* 1990 Oct;8(10):1683-94. <http://www.ncbi.nlm.nih.gov/pubmed/2170590>
225. Donohue JP, Rowland RG, Kopecky K, et al. Correlation of computerized tomographic changes and histological findings in 80 patients having radical retroperitoneal lymph node dissection after chemotherapy for testis cancer. *J Urol* 1987 Jun;137(6):1176-9. <http://www.ncbi.nlm.nih.gov/pubmed/3035236>
226. Richie JP. The surgical management of advanced abdominal disease. *Semin Urol* 1984 Nov;2(4):238-43. [No abstract available] <http://www.ncbi.nlm.nih.gov/pubmed/6505446>
227. Stomper PC, Fung CY, Socinski MA, et al. Detection of retroperitoneal metastases in early-stage nonseminomatous testicular cancer: analysis of different CT criteria. *Am J Roentgenol* 1987 Dec;149(6):1187-90. <http://www.ncbi.nlm.nih.gov/pubmed/2825494>
228. Kollmannsberger C, Daneshmand S, So A, et al. Management of disseminated nonseminomatous germ cell tumors with risk-based chemotherapy followed by response-guided postchemotherapy surgery. *J Clin Oncol* 2010 Feb;28(4):537-42. <http://www.ncbi.nlm.nih.gov/pubmed/20026807>
229. Ehrlich Y, Brames MJ, Beck SD, et al. Long-term follow-up of Cisplatin combination chemotherapy in patients with disseminated nonseminomatous germ cell tumors: is a postchemotherapy retroperitoneal lymph node dissection needed after complete remission? *J Clin Oncol* 2010 Feb;28(4):531-6. <http://www.ncbi.nlm.nih.gov/pubmed/20026808>
230. Carver BS, Shayegan B, Serio A, et al. Long-term clinical outcome after postchemotherapy retroperitoneal lymph node dissection in men with residual teratoma. *J Clin Oncol* 2007 Mar;25(9):1033-7. <http://www.ncbi.nlm.nih.gov/pubmed/17261854>
231. Aprikian AG, Herr HW, Bajorin DF, et al. Resection of postchemotherapy residual masses and limited retroperitoneal lymphadenectomy in patients with metastatic testicular nonseminomatous germ cell tumors. *Cancer* 1994 Aug;74(4):1329-34. <http://www.ncbi.nlm.nih.gov/pubmed/8055456>
232. Herr HW. Does necrosis on frozen-section analysis of a mass after chemotherapy justify a limited retroperitoneal resection in patients with advanced testis cancer? *Br J Urol* 1997 Oct;80(4):653-7. <http://www.ncbi.nlm.nih.gov/pubmed/9352708>
233. Hendry WF, A'Hern RP, Hetherington JW, et al. Para-aortic lymphadenectomy after chemotherapy for metastatic non-seminomatous germ cell tumours: prognostic value and therapeutic benefit. *Br J Urol* 1993 Feb;71(2):208-13. <http://www.ncbi.nlm.nih.gov/pubmed/8384914>

234. Wood DP Jr, Herr HW, Heller G, et al. Distribution of retroperitoneal metastases after chemotherapy in patients with nonseminomatous germ cell tumors. *J Urol* 1992 Dec;148(6):1812-5.
<http://www.ncbi.nlm.nih.gov/pubmed/1331547>
235. Baniel J, Foster RS, Rowland RG, et al. Complications of post-chemotherapy retroperitoneal lymph node dissection. *J Urol* 1995 Mar;153(3 Pt 2):976-80.
<http://www.ncbi.nlm.nih.gov/pubmed/7853586>
236. Hartmann JT, Schmoll HJ, Kuczyk MA, et al. Postchemotherapy resections of residual masses from metastatic non-seminomatous germ cell tumors. *Ann Oncol* 1997 Jun;8(6):531-8.
<http://www.ncbi.nlm.nih.gov/pubmed/9261521>
237. Rabbani F, Goldenberg SL, Gleave ME, et al. Retroperitoneal lymphadenectomy for post-chemotherapy residual masses: is a modified dissection and resection of residual masses sufficient? *Br J Urol* 1998 Feb;81(2):295-300.
<http://www.ncbi.nlm.nih.gov/pubmed/9488075>
238. Tekgul S, Ozen HA, Celebi I, et al. Postchemotherapeutic surgery for metastatic testicular germ cell tumors: results of extended primary chemotherapy and limited surgery. *Urology* 1994 Mar;43(3):349-54.
<http://www.ncbi.nlm.nih.gov/pubmed/8134989>
239. Steyerberg EW, Keizer HJ, Fosså SD, et al. Prediction of residual retroperitoneal mass histology after chemotherapy for metastatic nonseminomatous germ cell tumour: multivariate analysis of individual patient data from six study groups. *J Clin Oncol* 1995 May;13(5):1177-87.
<http://www.ncbi.nlm.nih.gov/pubmed/7537801>
240. Hartmann JT, Candelaria M, Kuczyk MA, et al. Comparison of histological results from the resection of residual masses at different sites after chemotherapy for metastatic nonseminomatous germ cell tumours. *Eur J Cancer* 1997 May;33(6):843-7.
<http://www.ncbi.nlm.nih.gov/pubmed/9291803>
241. Stenning SP, Parkinson MC, Fisher C, et al. Postchemotherapy residual masses in germ cell tumor patients: content, clinical features and prognosis. Medical Research Council Testicular Tumour Working Party. *Cancer* 1998 Oct;83(7):1409-19.
<http://www.ncbi.nlm.nih.gov/pubmed/9762943>
242. Weinknecht S, Hartmann M, Weissbach L. [In which marker-positive patients with germ cell tumors is residual tumor resection of value?] *Urologe A* 1998 Nov;37(6):621-4. [Article in German]
<http://www.ncbi.nlm.nih.gov/pubmed/9887490>
243. Hendry WF, Norman AR, Dearnaley DP, et al. Metastatic nonseminomatous germ cell tumors of the testis: results of elective and salvage surgery for patients with residual retroperitoneal masses. *Cancer* 2002 Mar;94(6):1668-76.
<http://www.ncbi.nlm.nih.gov/pubmed/11920527>
244. Sheinfeld J. The role of adjunctive postchemotherapy surgery for nonseminomatous germ-cell tumors: current concepts and controversies. *Semin Urol Oncol* 2002 Nov;20(4):262-71.
<http://www.ncbi.nlm.nih.gov/pubmed/12489059>
245. Foster RS, Donohue JP. Can retroperitoneal lymphadenectomy be omitted in some patients after chemotherapy? *Urol Clin North Am* 1998 Aug;25(3):479-84.
<http://www.ncbi.nlm.nih.gov/pubmed/9728217>
246. Steyerberg EW, Kaiser HJ, Habbema JD. Prediction models for the histology of residual masses after chemotherapy for metastatic testicular cancer. ReHIT Study Group. *Int J Cancer* 1999 Dec;83(6):856-9.
<http://www.ncbi.nlm.nih.gov/pubmed/10597211>
247. Vergouwe Y, Steyerberg EW, De Wit R, et al. External validity of a prediction rule for residual mass histology in testicular cancer: an evaluation for good prognosis patients. *Br J Cancer* 2003 Mar;88(6):843-7.
<http://www.ncbi.nlm.nih.gov/pubmed/12644820>
248. Fizazi K, Tjulandin S, Salvioni R, et al. Viable malignant cells after primary chemotherapy for disseminated nonseminomatous germ cell tumors: prognostic factors and role of postsurgery chemotherapy—results from an international study group. *J Clin Oncol* 2001 May;19(10):2647-57.
<http://www.ncbi.nlm.nih.gov/pubmed/11352956>
249. Steiner H, Peschel R, Bartsch G. Retroperitoneal lymph node dissection after chemotherapy for germ cell tumours: is a full bilateral template always necessary? *BJU Int* 2008 Aug;102(3):310-4.
<http://www.ncbi.nlm.nih.gov/pubmed/18325053>
250. Heidenreich A, Pfister D, Witthuhn R, et al. Postchemotherapy retroperitoneal lymph node dissection in advanced testicular cancer: radical or modified template resection. *Eur Urol* 2009 Jan;55(1):217-24.
<http://www.ncbi.nlm.nih.gov/pubmed/18926622>

251. Besse B, Grunenwald D, Fléchon A, et al. Nonseminomatous germ cell tumors: assessing the need for postchemotherapy contralateral pulmonary resection in patients with ipsilateral complete necrosis. *J Thorac Cardiovasc Surg* 2009 Feb;137(2):448-52.
<http://www.ncbi.nlm.nih.gov/pubmed/19185168>
252. Capitanio U, Jeldres C, Perrotte P, et al. Population-based study of perioperative mortality after retroperitoneal lymphadenectomy for nonseminomatous testicular germ cell tumors. *Urology* 2009 Aug;74(2):373-7.
<http://www.ncbi.nlm.nih.gov/pubmed/19501893>
253. Fléchon A, Tavernier E, Boyle H, et al. Long-term oncological outcome after post-chemotherapy retroperitoneal lymph node dissection in men with metastatic nonseminomatous germ cell tumour. *BJU Int* 2010 Sep;106(6):779-85.
<http://www.ncbi.nlm.nih.gov/pubmed/20089110>
254. Fizazi K, Oldenburg J, Dunant A, et al. Assessing prognosis and optimizing treatment in patients with postchemotherapy viable nonseminomatous germ-cell tumors (NSGCT): results of the sCR2 international study. *Ann Oncol* 2008 Feb;19(2):259-64.
<http://www.ncbi.nlm.nih.gov/pubmed/18042838>
255. Miller KD, Loehrer PJ, Gonin R, et al. Salvage chemotherapy with vinblastine, ifosfamide and cisplatin in recurrent seminoma. *J Clin Oncol* 1997 Apr;15(4):1427-31.
<http://www.ncbi.nlm.nih.gov/pubmed/9193335>
256. Pico JL, Rosti G, Kramar A, et al. Genito-Urinary Group of the French Federation of Cancer Centers (GETUG-FNCLCC), France; European Group for Blood and Marrow Transplantation (EBMT). A randomised trial of high-dose chemotherapy in the salvage treatment of patients failing first-line platinum chemotherapy for advanced germ cell tumours. *Ann Oncol* 2005 Jul;16(7):1152-9.
<http://www.ncbi.nlm.nih.gov/pubmed/15928070>
257. Lorch A, Kollmannsberger C, Hartmann JT, et al. German Testicular Cancer Study Group. Single versus sequential high-dose chemotherapy in patients with relapsed or refractory germ cell tumors: a prospective randomized multicenter trial of the German Testicular Cancer Study Group. *J Clin Oncol* 2007 Jul;25(19):2778-84.
<http://www.ncbi.nlm.nih.gov/pubmed/17602082>
258. International Prognostic Factors Study Group, Lorch A, Beyer J, Bascoul-Mollevi C, et al. Prognostic factors in patients with metastatic germ cell tumors who experienced treatment failure with cisplatin-based first-line chemotherapy. *J Clin Oncol* 2010 Nov;28(33):4906-11.
<http://www.ncbi.nlm.nih.gov/pubmed/20956623>
259. Oechsle K, Lorch A, Honecker F, et al. Patterns of relapse after chemotherapy in patients with high-risk non-seminomatous germ cell tumor. *Oncology* 2010;78(1):47-53.
<http://www.ncbi.nlm.nih.gov/pubmed/20215785>
260. Mead GM, Cullen MH, Huddart R, et al. MRC Testicular Tumour Working Party. A phase II trial of TIP (paclitaxel, ifosfamide and cisplatin) given as second-line (post-BEP) salvage chemotherapy for patients with metastatic germ cell cancer: a medical research council trial. *Br J Cancer* 2005 Jul;93(2):178-84.
<http://www.ncbi.nlm.nih.gov/pubmed/15999102>
261. Loehrer PJ Sr, Gonin R, Nichols CR, et al. Vinblastine plus ifosfamide plus cisplatin as initial salvage-therapy in recurrent germ cell tumour. *J Clin Oncol* 1998 Jul;16(7):2500-4.
<http://www.ncbi.nlm.nih.gov/pubmed/9667270>
262. Beyer J, Rick O, Siegert W, et al. Salvage chemotherapy in relapsed germ cell tumors. *World J Urol* 2001 Apr;19(2):90-3.
<http://www.ncbi.nlm.nih.gov/pubmed/11374323>
263. Schmoll HJ, Beyer J. Prognostic factors in metastatic germ cell tumors. *Semin Oncol* 1998 Apr;25(2):174-85.
<http://www.ncbi.nlm.nih.gov/pubmed/9562450>
264. Segal R, Lukka H, Klotz LH, et al. Cancer Care Ontario Practice Guidelines Initiative Genitourinary Cancer Disease Site Group. Surveillance programs for early stage nonseminomatous testicular cancer: a practice guideline. *Can J Urol* 2001 Feb;8(1):1184-92.
<http://www.ncbi.nlm.nih.gov/pubmed/11268306>
265. Reinhorn LH, Rajhavan D, Kindlen H. A phase I trial of gemcitabine plus paclitaxel combination therapy in patients with refractory advanced germ cell tumours. *Proc ASCO* 1999;18:207A (abstr 796).
266. Motzer RJ, Sheinfeld J, Mazumdar M, et al. Paclitaxel, ifosfamide, and cisplatin second-line therapy for patients with relapsed testicular germ cell cancer. *J Clin Oncol* 2000 Jun;18(12):2413-8.
<http://www.ncbi.nlm.nih.gov/pubmed/10856101>

267. Bokemeyer C, Gerl A, Schöffski P, et al. Gemcitabine in patients with relapse or cisplatin-refractory testicular cancer. *J Clin Oncol* 1999 Feb;17(2):512-6.
<http://www.ncbi.nlm.nih.gov/pubmed/10080593>
268. Beyer J, Schmoll HJ. [Prognosefaktoren bei metastasierten seminomatösen und nichtseminomatösen Hodentumoren.] *Onkologie* 1998;4:518-523. [Prognostic factors in metastatic seminoma and nonseminoma germ-cell tumours] [Article in German]
269. Beyer J, Stenning S, Gerl A, et al. High-dose versus conventional-dose chemotherapy as first-salvage treatment in patients with non-seminomatous germ-cell tumors: a matched-pair analysis. *Ann Oncol* 2002 Apr;13(4):599-605.
<http://www.ncbi.nlm.nih.gov/pubmed/12056711>
270. Bhatia S, Abonour R, Porcu P, et al. High-dose chemotherapy as initial salvage chemotherapy in patients with relapsed testicular cancer. *J Clin Oncol* 2000 Oct;18(19):3346-51.
<http://www.ncbi.nlm.nih.gov/pubmed/11013274>
271. Rosti G, Pico JL, Wandt H, et al. High-dose chemotherapy (HDC) in the salvage treatment of patients failing first-line platinum chemotherapy for advanced germ cell tumours (GCT): first results of a prospective randomised trial of the European Group for Blood and Marrow Transplantation (EBMT): IT-94 study. *Proc Ann Soc Clin Oncol* 2002;21:180a, abstr 716.
http://www.asco.org/ASCOv2/Meetings/Abstracts?&vmview=abst_detail_view&confID=16&abstractID=716
272. Kondagunta GV, Bacik J, Donadio A, et al. Combination of paclitaxel, ifosfamide, and cisplatin is an effective second-line therapy for patients with relapsed testicular germ cell tumors. *J Clin Oncol* 2005 Sep;23(27):6549-55.
<http://www.ncbi.nlm.nih.gov/pubmed/16170162>
273. Motzer RJ, Mazumdar M, Sheinfeld J, et al. Sequential dose-intensive paclitaxel, ifosfamide, carboplatin, and etoposide salvage therapy for germ cell tumor patients. *J Clin Oncol* 2000 Mar;18(6):1173-80.
<http://www.ncbi.nlm.nih.gov/pubmed/10715285>
274. Vaena DA, Abonour R, Einhorn LH. Long-term survival after high-dose salvage chemotherapy for germ cell malignancies with adverse prognostic variables. *J Clin Oncol* 2003 Nov;21(22):4100-4.
<http://www.ncbi.nlm.nih.gov/pubmed/14615439>
275. Beyer J, Bokemeyer C, Schmoll HJ. [Salvagechemotherapie rezidivierender und refraktärer Hodentumoren] *Onkologie* 1998;4:541-546. [Salvage chemotherapy for relapsed and refractory germ cell tumours] [Article in German]
276. Lorch A, Rick O, Wündisch T, et al. High dose chemotherapy as salvage treatment for unresectable late relapse germ cell tumors. *J Urol* 2010 Jul;184(1):168-73.
<http://www.ncbi.nlm.nih.gov/pubmed/20483152>
277. George DW, Foster RS, Hromas RA, et al. Update on late relapse of germ cell tumor: a clinical and molecular analysis. *J Clin Oncol* 2003 Jan;21(1):113-22.
<http://www.ncbi.nlm.nih.gov/pubmed/12506179>
278. Lee AH, Mead GM, Theaker JM. The value of central histopathological review of testicular tumours before treatment. *BJU Int* 1999 Jul;84(1):75-8.
<http://www.ncbi.nlm.nih.gov/pubmed/10444128>
279. Lipphardt ME, Albers P. Late relapse of testicular cancer. *World J Urol* 2004 Apr;22(1):47-54.
<http://www.ncbi.nlm.nih.gov/pubmed/15064970>
280. Tiffany P, Morse MJ, Bosl G, et al. Sequential excision of residual thoracic and retroperitoneal masses after chemotherapy for stage III germ cell tumors. *Cancer* 1986 Mar;57(5):978-83.
<http://www.ncbi.nlm.nih.gov/pubmed/3002596>
281. Cassidy J, Lewis CR, Kaye SB, et al. The changing role of surgery in metastatic non-seminomatous germ cell tumour. *Br J Cancer* 1992 Jan;65(1):127-9.
<http://www.ncbi.nlm.nih.gov/pubmed/1370759>
282. Coogan CL, Foster RS, Rowland RG, et al. Postchemotherapy retroperitoneal lymph node dissection is effective therapy in selected patients with elevated tumour markers after primary chemotherapy alone. *Urology* 1997 Dec;50(6):957-62.
<http://www.ncbi.nlm.nih.gov/pubmed/9426730>
283. Eastham JA, Wilson TG, Russell C, et al. Surgical resection in patients with nonseminomatous germ cell tumour who fail to normalize serum tumour markers after chemotherapy. *Urology* 1994 Jan;43(1):74-80.
<http://www.ncbi.nlm.nih.gov/pubmed/7506856>

284. Gerl A, Clemm C, Schmeller N, et al. Late relapse of germ cell tumors after cisplatin-based chemotherapy. *Ann Oncol* 1997 Jan;8(1):41-7.
<http://www.ncbi.nlm.nih.gov/pubmed/9093706>
285. Kisbenedek L, Bodrogi I, Szeldeli P, et al. Results of salvage retroperitoneal lymphadenectomy (RLA) in the treatment of patients with nonseminomatous germ cell tumours remaining marker positive after inductive chemotherapy. *Int Urol Nephrol* 1995;27(3):325-9.
<http://www.ncbi.nlm.nih.gov/pubmed/7591598>
286. Murphy BR, Breeden ES, Donohue JP, et al. Surgical salvage of chemorefractory germ cell tumors. *J Clin Oncol* 1993 Feb;11(2):324-9.
<http://www.ncbi.nlm.nih.gov/pubmed/8381163>
287. Nichols CR. Treatment of recurrent germ cell tumors. *Semin Surg Oncol* 1999 Dec;17(4):268-74.
<http://www.ncbi.nlm.nih.gov/pubmed/10588856>
288. Ravi R, Ong J, Oliver RT, et al. Surgery as salvage therapy in chemotherapy-resistant nonseminomatous germ cell tumours. *Br J Urol* 1998 Jun;81(6):884-8.
<http://www.ncbi.nlm.nih.gov/pubmed/9666776>
289. Albers P, Ganz A, Hanning E, et al. Salvage surgery of chemorefractory germ cell tumors with elevated tumor markers. *J Urol* 2000 Aug;164(2):381-4.
<http://www.ncbi.nlm.nih.gov/pubmed/10893590>
290. Fosså SD, Bokemeyer C, Gerl A, et al. Treatment outcome of patients with brain metastases from malignant germ cell tumors. *Cancer* 1999 Feb;85(4):988-97.
<http://www.ncbi.nlm.nih.gov/pubmed/10091779>
291. Bokemeyer C, Nowak P, Haupt A, et al. Treatment of brain metastases in patients with testicular cancer. *J Clin Oncol* 1997 Apr;15(4):1449-54.
<http://www.ncbi.nlm.nih.gov/pubmed/9193339>
292. Hartmann JT, Bamberg M, Albers P, et al. Multidisciplinary treatment and prognosis of patients with central nervous metastases (CNS) from testicular germ cell tumour (GCT) origin. *Proc Ann Soc Clin Oncol* 2003;22:400, abstr 1607.
http://www.asco.org/ASCOv2/Meetings/Abstracts?&vmview=abst_detail_view&confID=23&abstractID=103455
293. Edelman MJ, Meyers FJ, Siegel D. The utility of follow-up testing after curative cancer therapy A critical review and economic analysis. *J Gen Intern Med* 1997 May;12(5):318-31.
<http://www.ncbi.nlm.nih.gov/pubmed/9159703>
294. Rathmell AJ, Brand IR, Carey BM, et al. Early detection of relapse after treatment for metastatic germ cell tumour of the testis: an exercise in medical audit. *Clin Oncol (R Coll Radiol)* 1993;5(1):34-8.
<http://www.ncbi.nlm.nih.gov/pubmed/7678749>
295. Gietema JA, Meinardi MT, Sleijfer DT, et al. Routine chest X-rays have no additional value in the detection of relapse during routine follow-up of patients treated with chemotherapy for disseminated non-seminomatous testicular cancer. *Ann Oncol* 2002 Oct;13(10):1616-20.
<http://www.ncbi.nlm.nih.gov/pubmed/12377651>
296. Brenner DJ, Hall EJ. Computed tomography: an increasing source of radiation exposure. *N Engl J Med* 2007 Nov;357(22):2277-84.
<http://www.ncbi.nlm.nih.gov/pubmed/18046031>
297. Schmoll HJ, Jordan K, Huddart R, et al. ESMO Guidelines Working Group. Testicular non-seminoma: ESMO Clinical Practice Guidelines for diagnosis, treatment and follow-up. *Ann Oncol* 2010 May;21 Suppl 5:v147-54.
http://annonc.oxfordjournals.org/content/21/suppl_5/v147.long
298. Schmoll HJ, Jordan K, Huddart R, et al. ESMO Guidelines Working Group. Testicular non-seminoma: ESMO clinical recommendations for diagnosis, treatment and follow-up. *Ann Oncol* 2009 May;20 Suppl 4:89-96.
http://annonc.oxfordjournals.org/content/20/suppl_4/iv89.long
299. Cathomas R, Helbling D, Stenner F, et al. Interdisciplinary evidence-based recommendations for the follow-up of testicular cancer patients: a joint effort. *Swiss Med Wkly* 2010;140 (25-26):356-69.
<http://www.smw.ch/for-readers/archive/backlinks/?url=/docs/pdfcontent/smw-12993.pdf>
300. Pont J, Albrecht W, Postner G, et al. Adjuvant chemotherapy for high-risk clinical stage I nonseminomatous testicular germ cell cancer: long-term results of a prospective trial. *J Clin Oncol* 1996 Feb;14(2):441-8.
<http://www.ncbi.nlm.nih.gov/pubmed/8636755>

301. Böhlen D, Borner M, Sonntag RW, et al. Long-term results following adjuvant chemotherapy in patients with clinical stage I testicular nonseminomatous malignant germ cell tumors with high risk factors. *J Urol* 1999 Apr;161(4):1148-52.
<http://www.ncbi.nlm.nih.gov/pubmed/10081858>
302. Tjan-Heijnen VC, Oosterhof GO, de Wit R, et al. Treatment of germ cell tumours: state of the art. *Eur J Surg Oncol* 1997 Apr;23(2):110-7.
<http://www.ncbi.nlm.nih.gov/pubmed/9158183>
303. Lowe BA. Surveillance versus nerve-sparing retroperitoneal lymphadenectomy in stage I germ cell tumors. *Urol Clin North Am* 1993 Feb;20(1):75-83.
<http://www.ncbi.nlm.nih.gov/pubmed/8381999>
304. Gels ME, Hoekstra HJ, Sleijfer DT, et al. Detection of recurrence in patients with clinical stage I nonseminomatous testicular germ cell tumors and consequences for further follow-up: a single-center 10-year experience. *J Clin Oncol* 1995 May;13(5):1188-94.
<http://www.ncbi.nlm.nih.gov/pubmed/7537802>
305. van As NJ, Gilbert DC, Money-Kyrle J, et al. Evidence-based pragmatic guidelines for the follow-up of testicular cancer: optimising the detection of relapse. *Br J Cancer* 2008 Jun;98(12):1894-902.
<http://www.ncbi.nlm.nih.gov/pubmed/18542063>
306. McLeod DG, Weiss RB, Stablein DM, et al. Staging relationships and outcome in early stage testicular cancer: a report from the Testicular Cancer Intergroup Study. *J Urol* 1991 Jun;145(6):1178-83.
<http://www.ncbi.nlm.nih.gov/pubmed/1851890>
307. Donohue JP, Thornhill JA, Foster RS, et al. Primary retroperitoneal lymph node dissection in clinical stage A non-seminomatous germ cell testis cancer: review of the Indiana University Experience 1965-1989. *Br J Urol* 1993 Mar;71(3):326-35.
<http://www.ncbi.nlm.nih.gov/pubmed/8386580>
308. Schmoll HJ, Weissbach L. [Diagnostik und Therapie von Hodentumouren.] Interdisziplinäre Konsensus-Konferenz, Halle (Saale), 1996. EBM IIa, IIb, III. [Diagnosis and therapy for germ cell tumours] [Article in German]
309. McCaffrey JA, Bajorin DF, Motzer RJ. Risk assessment for metastatic testis cancer. *Urol Clin North Am* 1998 Aug;25(3):389-95.
<http://www.ncbi.nlm.nih.gov/pubmed/9728209>
310. Sharda N, Kinsella T, Ritter MA. Adjuvant radiation versus observation: a cost analysis of alternate management schemes in early stage testicular seminoma. *J Clin Oncol* 1996 Nov;14(11):2933-9.
<http://www.ncbi.nlm.nih.gov/pubmed/8918490>
311. Buchholz TA, Walden TL, Prestidge BR. Cost-effectiveness of posttreatment surveillance after radiation therapy for early stage seminoma. *Cancer* 1998 Mar;82(6):1126-33.
<http://www.ncbi.nlm.nih.gov/pubmed/9506359>
312. Tana S, Cerrotta A, Gardani G, et al. Postsurgical policy in stage I testicular seminoma: cost and benefit of prophylactic irradiation in a long-term experience. *Tumori* 1997 Nov-Dec;83(6):918-21.
<http://www.ncbi.nlm.nih.gov/pubmed/9526584>
313. Sultanem K, Souhami L, Benk V, et al. Para-aortic irradiation only appears to be adequate treatment for patients with stage I seminoma of the testis. *Int J Radiat Oncol Biol Phys* 1998 Jan;40(2):455-9.
<http://www.ncbi.nlm.nih.gov/pubmed/9457835>
314. Kiricuta IC, Sauer J, Bohndorf W. Omission of the pelvic irradiation in stage I testicular seminoma: a study of postorchidectomy paraaortic radiotherapy. *Int J Radiat Oncol Biol Phys* 1996 May;35(2):293-8.
<http://www.ncbi.nlm.nih.gov/pubmed/8635936>
315. Warde P, Gospodarowicz MK, Panzarella T, et al. Stage I testicular seminoma: results of adjuvant irradiation and surveillance. *J Clin Oncol* 1995 Sep;13(9):2255-62.
<http://www.ncbi.nlm.nih.gov/pubmed/7666083>
316. Fosså SD, Aass N, Kaalhus O. Radiotherapy for testicular seminoma stage I: treatment results and long-term post-irradiation morbidity in 365 patients. *Int J Radiat Oncol Biol Phys* 1989 Feb;16(2):383-8.
<http://www.ncbi.nlm.nih.gov/pubmed/2921142>
317. Baniel J, Foster RS, Einhorn LH, et al. Late relapse of clinical stage I testicular cancer. *J Urol* 1995 Oct;154(4):1370-2.
<http://www.ncbi.nlm.nih.gov/pubmed/7658541>
318. Stein ME, Levi M, Drumea K, et al. Radiation-induced tumors in irradiated stage I testicular seminoma: results of a 25-year follow-up (1968-1993). *J Surg Oncol* 1998 Jan;67(1):38-40.
<http://www.ncbi.nlm.nih.gov/pubmed/9457255>

319. Akimoto T, Takahashi I, Takahashi M, et al. Long-term outcome of postorchidectomy radiation therapy for stage I and II testicular seminoma. *Anticancer Res* 1997 Sep-Oct;17(5B):3781-5.
<http://www.ncbi.nlm.nih.gov/pubmed/9427780>
320. Von der Maase H, Specht L, Jacobsen GK, et al. Surveillance following orchidectomy for stage I seminoma of the testis. *Eur J Cancer* 1993;29A(14):1931-4.
<http://www.ncbi.nlm.nih.gov/pubmed/8280484>
321. Horwich A, Alsanjari N, A'Hern, et al. Surveillance following orchidectomy for stage I testicular seminoma. *Br J Cancer* 1992 May;65(5):775-8.
<http://www.ncbi.nlm.nih.gov/pubmed/1586607>
322. Germá Lluch JR, Climent MA, Villavicencio H, et al. Treatment of stage I testicular tumours. *Br J Urol* 1993 Apr;71(4):473-7.
<http://www.ncbi.nlm.nih.gov/pubmed/8499994>
323. Warde PR, Gospodarowicz MK, Goodman PJ, et al. Results of a policy of surveillance in stage I testicular seminoma. *Int J Radiat Oncol Biol Phys* 1993 Sep;27(1):11-5.
<http://www.ncbi.nlm.nih.gov/pubmed/8365931>
324. Allhoff EP, Liedke S, de Riese W, et al. Stage I seminoma of the testis: adjuvant radiotherapy or surveillance? *Br J Urol* 1991 Aug;68(2):190-4.
<http://www.ncbi.nlm.nih.gov/pubmed/1715798>
325. Fosså SD, Chen J, Schonfeld SJ, et al. Risk of contralateral testicular cancer: a population-based study of 29,515 U.S. men. *J Natl Cancer Inst* 2005 Jul;97(14):1056-66.
<http://www.ncbi.nlm.nih.gov/pubmed/16030303>
326. Wierecky J, Kollmannsberger C, Boehlke I, et al. Secondary leukemia after first-line high-dose chemotherapy for patients with advanced germ cell cancer. *J Cancer Res Clin Oncol* 2005 Apr;131(4):255-60.
<http://www.ncbi.nlm.nih.gov/pubmed/15627215>
327. Nuver J, Smit AJ, Sleijfer DT, et al. Left ventricular and cardiac autonomic function in survivors of testicular cancer. *Eur J Clin Invest* 2005 Feb;35(2):99-103.
<http://www.ncbi.nlm.nih.gov/pubmed/15667580>
328. van den Belt-Dusebout AW, Nuver J, de Wit R, et al. Long-term risk of cardiovascular disease in 5-year survivors of testicular cancer. *J Clin Oncol* 2006 Jan;24(3):467-75.
<http://www.ncbi.nlm.nih.gov/pubmed/16421423>
329. Haugnes HS, Aass N, Fosså SD, et al. Components of the metabolic syndrome in long-term survivors of testicular cancer. *Ann Oncol* 2007 Feb;18(2):241-8.
<http://www.ncbi.nlm.nih.gov/pubmed/17060482>
330. Huddart RA, Joffe JK. Preferred treatment for stage I seminoma: a survey of Canadian radiation oncologists. *Clin Oncol (R Coll Radiol)* 2006 Nov;18(9):693-5. [No abstract available]
<http://www.ncbi.nlm.nih.gov/pubmed/17100155>
331. Krege S, Kalund G, Otto T, et al. Phase II study: adjuvant single-agent carboplatin therapy for clinical stage I seminoma. *Eur Urol* 1997;31(4):405-7.
<http://www.ncbi.nlm.nih.gov/pubmed/9187898>
332. Dieckmann KP, Krain J, Küster J, et al. Adjuvant carboplatin treatment for seminoma clinical stage I. *J Cancer Res Clin Oncol* 1996;122(1):63-6.
<http://www.ncbi.nlm.nih.gov/pubmed/8543595>
333. Bukowski RM. Management of advanced and extragonadal germ-cell tumors. *Urol Clin North Am* 1993 Feb;20(1):153-60.
<http://www.ncbi.nlm.nih.gov/pubmed/8381995>
334. Fair W, Dalbagni G, Machele Donat S, et al. Evaluation and follow-up of patients with urologic cancer. AUA Office of Education Publications 9958 PG, 1999.
335. Pizzocaro G. Non-seminomatous germ-cell tumours (NSGCT) of the testis: diagnosis and management, stage by stage. *Eur Urol Update Series* 1997;6:139-45.
336. Sheinfeld J, Bajorin DF, Solomon M. Management of postchemotherapy residual masses in advanced germ cell tumours. *Urol Clin North Am* 1997;3:18-23.
337. Little JS Jr., Foster RS, Ulbright TM, et al. Unusual neoplasms detected in testis cancer patients undergoing post-chemotherapy retroperitoneal lymphadenectomy. *J Urol* 1994 Oct;152(4):1144-9.
<http://www.ncbi.nlm.nih.gov/pubmed/8072083>

10.2 Non-germ cell tumours

1. Chevile JC, Sebo TJ, Lager DJ, et al. Leydig cell tumour of the testis: a clinicopathologic, DNA content, and MIB-1 comparison of nonmetastasizing and metastasizing tumors. *Am J Surg Pathol* 1998 Nov;22(11):1361-7.
<http://www.ncbi.nlm.nih.gov/pubmed/9808128>
2. Kim I, Young RH, Scully RE. Leydig cell tumours of the testis. A clinicopathological analysis of 40 cases and review of the literature. *Am J Surg Pathol* 1985 Mar;9(3):177-92.
<http://www.ncbi.nlm.nih.gov/pubmed/3993830>
3. Matveev BP, Gurarii LL. [Leydig-cell tumors of the testis] *Urol Nefrol (Mosk)* 1997 Jul-Aug;(4):34-6. [Article in Russian]
<http://www.ncbi.nlm.nih.gov/pubmed/9381620>
4. Young RH, Koelliker DD, Scully RE. Sertoli cell tumors of the testis, not otherwise specified: a clinicopathologic analysis of 60 cases. *Am J Surg Pathol* 1998 Jun;22(6):709-21.
<http://www.ncbi.nlm.nih.gov/pubmed/9630178>
5. Proppe KH, Scully RE. Large-cell calcifying Sertoli cell tumour of the testis. *Am J Clin Pathol* 1980 Nov;74(5):607-19.
<http://www.ncbi.nlm.nih.gov/pubmed/7446466>
6. Zukerberg LR, Young RH, Scully RE. Sclerosing Sertoli cell tumour of the testis. A report of 10 cases. *Am J Surg Pathol* 1991 Sep;15(9):829-34.
<http://www.ncbi.nlm.nih.gov/pubmed/1719830>
7. WHO histological classification of testis tumours, In: Eble JN, Sauter G, Epstein JI, Sesterhenn IA (eds). *Pathology & Genetics. Tumours of the urinary system and male genital organs*. Lyon: IARC Press, 2004: 218, pp. 250-262.
<http://www.iarc.fr/en/publications/pdfs-online/pat-gen/bb7/index.php>
8. Ulbright TM, Amin MB, Young RH. Tumours of the testis, adnexia, spermatic cord and scrotum. *AFIP*1999.
9. Chevile JC, Sebo TJ, Lager DJ, et al. Leydig cell tumour of the testis: a clinicopathologic, DNA content, and MIB-1 comparison of nonmetastasizing and metastasizing tumors. *Am J Surg Pathol* 1998 Nov;22(11):1361-7.
<http://www.ncbi.nlm.nih.gov/pubmed/9808128>
10. McCluggage WG, Shanks JH, Arthur K, et al. Cellular proliferation and nuclear ploidy assessments augment established prognostic factors in predicting malignancy in testicular Leydig cell tumours. *Histopathology* 1998 Oct;33(4):361-8.
<http://www.ncbi.nlm.nih.gov/pubmed/9822927>
11. Mineur P, de Cooman S, Hustin J, et al. Feminizing testicular Leydig cell tumour: hormonal profile before and after unilateral orchidectomy. *J Clin Endocrinol Metab* 1987 Apr;64(4):686-91.
<http://www.ncbi.nlm.nih.gov/pubmed/3818898>
12. Reznik Y, Rieu M, Kuhn JM, et al. Luteinizing hormone regulation by sex steroids in men with germinal and Leydig cell tumours. *Clin Endocrinol (Oxf)* 1993 May;38(5):487-93.
<http://www.ncbi.nlm.nih.gov/pubmed/8392454>
13. Bercovici JP, Nahoul K, Tater D, et al. Hormonal profile of Leydig cell tumors with gynecomastia. *J Clin Endocrinol Metab* 1984 Oct;59(4):625-30.
<http://www.ncbi.nlm.nih.gov/pubmed/6434575>
14. Haas GP, Pittaluga S, Gomella L, et al. Clinical occult Leydig cell tumour presenting with gynecomastia. *J Urol* 1989 Nov;142(5):1325-7.
<http://www.ncbi.nlm.nih.gov/pubmed/2810523>
15. Ruthgers JL, Young RH, Scully RE. The testicular 'tumour' of the adrenogenital syndrome. A report of six cases and review of the literature on testicular masses in patients with adrenocortical disorders. *Am J Surg Pathol* 1988 Jul;12(7):503-13.
<http://www.ncbi.nlm.nih.gov/pubmed/3291624>
16. Maizlin ZV, Belenky A, Kunichezky M, et al. Leydig cell tumors of the testis: gray scale and color Doppler sonographic appearance. *J Ultrasound Med* 2004 Jul;23(7):959-64.
<http://www.ncbi.nlm.nih.gov/pubmed/15292565>
17. Ponce de León Roca J, Algaba Arrea F, Bassas Arnau L, et al. [Leydig-cell tumour of the testis] *Arch Esp Urol* 2000 Jul-Aug;53(6):453-8. [Article in Spanish]
<http://www.ncbi.nlm.nih.gov/pubmed/11002512>
18. Sánchez-Chapado M, Angulo JC, Haas GP. Adenocarcinoma of the rete testis. *Urology* 1995 Oct;46(4):468-75.
<http://www.ncbi.nlm.nih.gov/pubmed/7571213>

19. Mosharafa AA, Foster RS, Bihrlle R, et al. Does retroperitoneal lymph node dissection have a curative role for patients with sex cord-stromal testicular tumors? *Cancer* 2003 Aug;98(4):753-7.
<http://www.ncbi.nlm.nih.gov/pubmed/12910519>
20. Giglio M, Medica M, De Rose AF, et al. Testicular Sertoli cell tumours and relative sub-types. Analysis of clinical and prognostic features. *Urol Int* 2003;70(3):205-10.
<http://www.ncbi.nlm.nih.gov/pubmed/12660458>
21. Jacobsen GK. Malignant Sertoli cell tumours of the testis. *J Urol Pathol* 1993;1:233-55.
22. Kratzer SS, Ulbright TM, Talerman A, et al. Large cell calcifying Sertoli cell tumour of the testis: contrasting features of six malignant and six benign tumors and a review of the literature. *Am J Surg Pathol* 1997 Nov;21(11):1271-80.
<http://www.ncbi.nlm.nih.gov/pubmed/9351565>
23. Henley JD, Young RH, Ulbright TM. Malignant Sertoli cell tumours of the testis: a study of 13 examples of a neoplasm frequently misinterpreted as seminoma. *Am J Surg Pathol* 2002 May;26:541-50.
<http://www.ncbi.nlm.nih.gov/pubmed/11979085>
24. Plata C, Algaba F, Andújar M, et al. Large cell calcifying Sertoli cell tumour of the testis. *Histopathology* 1995 Mar;26(3):255-9.
<http://www.ncbi.nlm.nih.gov/pubmed/7541015>
25. Anderson GA. Sclerosing Sertoli cell tumour of the testis: a distinct histological subtype. *J Urol* 1995 Nov;154(5):1756-8.
<http://www.ncbi.nlm.nih.gov/pubmed/7563340>
26. Grabrilove JL, Freiberg EK, Leiter E, et al. Feminizing and non-feminizing Sertoli cell tumors. *J Urol* 1980 Dec;124(6):757-67. [No abstract available]
<http://www.ncbi.nlm.nih.gov/pubmed/7003168>
27. Gierke CL, King BF, Bostwick DG, et al. Large-cell calcifying Sertoli cell tumour of the testis: appearance at sonography. *AJR Am J Roentgenol* 1994 Aug;163(2):373-5. [No abstract available]
<http://www.ncbi.nlm.nih.gov/pubmed/8037034>
28. Chang B, Borer JG, Tan PE, et al. Large-cell calcifying Sertoli cell tumour of the testis: case report and review of the literature. *Urology* 1998 Sep;52(3):520-2.
<http://www.ncbi.nlm.nih.gov/pubmed/9730477>
29. Washecka R, Dresner MI, Honda SA. Testicular tumors in Carney's complex. *J Urol* 2002 Mar;167(3):1299-302.
<http://www.ncbi.nlm.nih.gov/pubmed/11832717>
30. Young S, Gooneratne S, Straus FH 2nd, et al. Feminizing Sertoli cell tumors in boys with Peutz-Jeghers syndrome. *Am J Surg Pathol* 1995 Jan;19(1):50-8.
<http://www.ncbi.nlm.nih.gov/pubmed/7802138>
31. Kaplan GW, Cromie WJ, Kelalis PP, et al. Gonadal stromal tumors: a report of the Prepubertal Testicular Tumours Registry. *J Urol* 1986 Jul;136(1Pt2):300-2.
<http://www.ncbi.nlm.nih.gov/pubmed/3723681>
32. Al-Bozom IA, El-Faqih SR, Hassan SH, et al. Granulosa cell tumour of the adult type. A case report and review of the literature of a very rare testicular tumour. *Arch Pathol Lab Med* 2000 Oct;124(10):1525-8.
<http://www.ncbi.nlm.nih.gov/pubmed/11035589>
33. Perito PE, Ciancio G, Civantos F, et al. Sertoli-Leydig cell testicular tumour: case report and review of sex cord/gonadal stromal tumour histogenesis. *J Urol* 1992 Sep;148(3):883-5.
<http://www.ncbi.nlm.nih.gov/pubmed/1512847>
34. Scully RE. Gonadoblastoma. A review of 74 cases. *Cancer* 1970 Jun;25(6):1340-56. [No abstract available]
<http://www.ncbi.nlm.nih.gov/pubmed/4193741>
35. Ulbright TM, Strigley JR, Reuter VE, et al. Sex-cord-stromal tumours of the testis with entrapped germ cells: a lesion mimicking unclassified mixed germ cell sex cord-stromal tumors. *Am J Surg Pathol* 2000 Apr;24(4):535-42.
<http://www.ncbi.nlm.nih.gov/pubmed/10757400>

11. ABBREVIATIONS USED IN THE TEXT

This list is not comprehensive to the most common abbreviations.

AFP	alpha-fetoprotein
AUC	area under curve
Cg A	chromogranine A
CI	confidence interval
CS	clinical stage
CT	computed tomography
EAU	European Association of Urology
EBM	evidence-based medicine
EP	etoposide, cisplatin
EORTC	European Organisation for Research and Treatment of Cancer
FDG-PET	fluorodeoxyglucose-positron emission tomography
FSH	follicle-stimulating hormone
GI	gastrointestinal
G-CSF	granulocyte colony-stimulating factor
GR	grade of recommendation
hCG	human chorionic gonadotrophin
HPF	high-power field
IGCCCCG	International Germ Cell Cancer Collaborative Group
LE	level of evidence
LH	luteinising hormone
LDH	lactate dehydrogenase
MRC	Medical Research Council
MRI	magnetic resonance imaging
NSGCT	non-seminomatous germ cell tumour
PA	para-aortic
PEB	cisplatin, etoposide, bleomycin
PEI	cisplatin, etoposide, ifosfamide
PET	positron emission tomography
PFS	progression-free survival
PS	pathological stage
PLAP	placental alkaline phosphatase
PVB	cisplatin, vinblastine, bleomycin
RPLND	retroperitoneal lymph node dissection
SWENOTECA	Swedish-Norwegian Testicular Cancer Project
TIN	testicular intraepithelial neoplasia pathological definition: undifferentiated intratubular germ cell carcinoma
TIP	paclitaxel, ifosfamide, cisplatin
TNM	Tumour Node Metastasis
UICC	International Union Against Cancer
ULN	upper limit of normal
US	ultrasound
VelP	vinblastine, ifosfamide, cisplatin
WHO	World Health Organization
VIP	(VP-16) etoposide, ifosfamide, cisplatin

Conflict of interest

All members of the Testicular Cancer Guidelines working group have provided disclosure statements of all relationships that they have that might be perceived as a potential source of a conflict of interest. This information is publically accessible through the European Association of Urology website. This guidelines document was developed with the financial support of the European Association of Urology. No external sources of funding and support have been involved. The EAU is a non-profit organisation and funding is limited to administrative assistance and travel and meeting expenses. No honoraria or other reimbursements have been provided.

