

# Guidelines on Urological Trauma

D. Lynch, L. Martinez-Piñero, E. Plas, E. Serafetinidis,  
L. Turkeri, R. Santucci, M. Hohenfellner

# TABLE OF CONTENTS

# PAGE

1.	RENAL TRAUMA	5
1.1	Background	5
1.2	Mode of injury	5
1.2.1	Injury classification	5
1.3	Diagnosis: initial emergency assessment	6
1.3.1	History and physical examination	6
1.3.1.1	Guidelines on history and physical examination	7
1.3.2	Laboratory evaluation	7
1.3.2.1	Guidelines on laboratory evaluation	7
1.3.3	Imaging: criteria for radiographic assessment in adults	7
1.3.3.1	Ultrasonography	7
1.3.3.2	Standard intravenous pyelography (IVP)	8
1.3.3.3	One shot intraoperative intravenous pyelography (IVP)	8
1.3.3.4	Computed tomography (CT)	8
1.3.3.5	Magnetic resonance imaging (MRI)	9
1.3.3.6	Angiography	9
1.3.3.7	Radionuclide scans	9
1.3.3.8	Guidelines on radiographic assessment	9
1.4	Treatment	10
1.4.1	Indications for renal exploration	10
1.4.2	Operative findings and reconstruction	10
1.4.3	Non-operative management of renal injuries	11
1.4.4	Guidelines on management of renal trauma	11
1.4.5	Post-operative care and follow-up	11
1.4.5.1	Guidelines on post-operative management and follow-up	12
1.4.6	Complications	12
1.4.6.1	Guidelines on management of complications	12
1.4.7	Paediatric renal trauma	12
1.4.7.1	Guidelines on management of paediatric trauma	13
1.4.8	Renal injury in the polytrauma patient	13
1.4.8.1	Guidelines on management of polytrauma with associated renal injury	14
1.5	Suggestions for future research studies	14
1.6	Algorithms	14
1.7	References	17
2.	URETERAL TRAUMA	27
2.1	Introduction	27
2.2	Aetiology	27
2.3	Diagnosis	27
2.3.1	Clinical diagnosis	27
2.3.2	Radiological diagnosis	27
2.4	Classification	27
2.5	Management	28
2.5.1	Partial injuries	28
2.5.2	Complete injuries	28
2.5.3	Sterile surgery	29
2.5.3.1	Uretero-ureterostomy	29
2.5.3.2	Ureterocalycostomy	29
2.5.3.3	Transuretero-ureterostomy	29
2.5.3.4	Ureteroneocystostomy with Boari flap	29
2.5.3.5	Ureterocystostomy and psoas hitch	30
2.5.3.6	Ileal interposition graft	30
2.5.3.7	Autotransplantation	30
2.5.3.8	Nephrectomy	30
2.6	References	31

3.	BLADDER TRAUMA	31
3.1	Background	31
3.2	Classification	32
3.3	Risk factors	32
3.4	Diagnosis	32
3.4.1	Macroscopic (gross) haematuria	33
3.4.2	Microscopic haematuria	33
3.4.3	Cystography	33
3.4.4	Excretory urography (intravenous pyelogram)	34
3.4.5	Ultrasound	34
3.4.6	Computed tomography (CT)	34
3.4.7	Angiography	34
3.4.8	Magnetic resonance imaging (MRI)	34
3.5	Treatment	34
3.5.1	Blunt trauma: extraperitoneal rupture	34
3.5.2	Blunt trauma: intraperitoneal rupture	35
3.5.3	Penetrating injuries	35
3.6	Recommendations	35
3.6.1	General	35
3.6.2	Diagnosis	35
3.6.3	Treatment	35
3.7	References	35
4.	URETHRAL TRAUMA	39
4.1	Anatomical and aetiological considerations	39
4.1.1	Posterior urethral injuries	39
4.1.1.1	Stable pelvic fracture	39
4.1.1.2	Unstable pelvic fractures	39
4.1.1.3	Urethral injuries in children	42
4.1.1.4	Urethral injuries in women	42
4.1.1.5	Penetrating injuries to the perineum	42
4.1.2	Anterior urethral injuries	42
4.1.2.1	Blunt trauma	42
4.1.2.2	Intercourse-related trauma	42
4.1.2.3	Penetrating trauma	43
4.1.2.4	Constriction band-related trauma	43
4.1.2.5	Iatrogenic trauma	43
4.2.	Diagnosis: initial emergency assessment	43
4.2.1	Clinical assessment	43
4.2.1.1	Blood at the meatus	43
4.2.1.2	Blood at the vaginal introitus	43
4.2.1.3	Haematuria	43
4.2.1.4	Pain on urination or inability to void	43
4.2.1.5	Haematoma or swelling	43
4.2.1.6	High-riding prostate	44
4.2.2	Radiographic examination	44
4.2.3	Endoscopic examination	44
4.3.	Management	44
4.3.1	Anterior urethral injuries	44
4.3.1.1	Blunt injuries	44
4.3.1.2	Open injuries	45
4.3.1.2.1	Male urethral injuries	45
4.3.1.2.2	Female urethral injuries	45
4.3.2	Posterior urethral injuries	45
4.3.2.1	Partial urethral rupture	46
4.3.2.2	Complete urethral rupture	46
4.3.2.3	Primary realignment	46
4.3.2.4	Immediate open urethroplasty	48
4.3.2.5	Delayed primary urethroplasty	48
4.3.2.6	Delayed urethroplasty	49

	Distraction defects longer than 7-8 cm	
	Fistulae	
	Synchronous anterior urethral stricture	
	Urinary incontinence	
	4.3.2.7 Reconstruction of failed repair of posterior urethral rupture	49
	4.3.2.8 Delayed endoscopic optical incision	50
4.4	Recommendations for treatment: algorithms	50
4.5	Suggestion for future prospective study	51
4.6	References	54
5.	GENITAL TRAUMA	63
5.1	Background	63
5.2	Pathophysiology	64
	5.2.1 Blunt trauma	64
	5.2.2 Penetrating trauma	64
5.3	Risk factors	65
5.4	Diagnosis	65
	5.4.1 Blunt renal trauma	65
	5.4.1.1 Penile fracture	65
	5.4.2 Blunt testicular trauma	65
	5.4.3 Blunt female trauma	66
	5.4.4 Penetrating trauma	66
5.5	Treatment	66
	5.5.1 Penile trauma	66
	5.5.1.1 Blunt trauma	66
	5.5.1.2 Penetrating trauma	66
	5.5.2 Testicular trauma	66
	5.5.2.1 Blunt trauma	66
	5.5.2.2 Penetrating trauma	67
	5.5.3 Vulvar injuries	67
5.6.	References	67
5.7	Recommendations	71
6.	ABBREVIATIONS	71

# 1. RENAL TRAUMA

## 1.1 Background

Trauma is defined as the morbid condition of body produced by external violence. Physicians with different specialties (General Surgery, Urology, Traumatology) evaluate and treat the trauma patient, as a high level of expertise is required to prevent mortality and reduce morbidity.

Renal trauma occurs in approximately 1-5% of all traumas (1,2). The kidney is the most commonly injured genitourinary and abdominal organ, with the male to female ratio being 3:1(3-5). Renal trauma can be acutely life-threatening, but the majority of renal injuries are mild and can be managed conservatively. Advances in the imaging and staging of trauma, as well as in treatment strategies during the last 20 years, have decreased the need for surgical intervention and increased renal preservation (6).

## 1.2 Mode of injury

The mechanism of renal injuries is classified as blunt or penetrating. The distribution of blunt and penetrating injuries depends on the location of the reference centre. In rural settings, blunt trauma can account for the largest percentage of renal injuries (90-95%)(7). In urban settings, the percentage of penetrating injuries can increase to 20% (8) or higher.

Blunt trauma is usually secondary to motor vehicle accidents, falls, vehicle-associated pedestrian accidents, contact sports and assault. Traffic accidents are the major cause for almost half of blunt renal injuries (4,5). Brandes et al. in a 20-year review of renal injuries following free falls found a rate of 16.4% (9).

Renal lacerations and renal vascular injuries make up only 10-15% of all blunt renal injuries. Isolated renal artery injury following blunt abdominal trauma is extremely rare and accounts for less than 0.1% of all trauma patients (10).

Schmidlin et al. developed an experimental model to study force transmission and stress distribution of the injured kidney and developed a hypothesis that a bending mechanism may be responsible for most blunt injuries. Maximum stress concentrations were caused by the combined effect of the applied force and the reaction generated by the liquid-filled inner renal compartment. Trauma to the injured kidney tends to concentrate at the renal periphery in this model, a finding which is often confirmed in explorations of severely damaged organs (11).

Renal artery occlusion is associated with rapid deceleration injuries. In theory, the kidney is displaced causing renal artery traction; the resulting tear in the inelastic intima and subsequent haemorrhage into the vessel wall leads to thrombosis. Compression of the renal artery between the anterior abdominal wall and the vertebral bodies may result in thrombosis of the renal artery (12).

Gunshot and stab wounds represent the most common causes of penetrating injuries. In most cases, they result from interpersonal violence. Renal injuries from penetrating trauma tend to be more severe and less predictable than those from blunt trauma. Bullets, because of their higher kinetic energy, have the potential for greater parenchymal destruction and are most often associated with multiple-organ injuries (13). Renal injuries in recent wars are reported to be the commonest among urogenital organs. Most are found to be associated with major abdominal injuries and the rate of nephrectomies is relatively high (25-33%) (14,15).

### 1.2.1 Injury classification

Classifying renal injuries helps to standardize different groups of patients, select appropriate therapy and predict results. A total of 26 classifications for renal injuries have been presented in the literature in the past 50 years (16), but the committee on organ injury scaling of the American Association for the Surgery of Trauma (AAST) has developed a renal-injury scaling system that is now widely used (17). Renal injuries are classified as Grade 1 to 5 (Table 1.1). Abdominal computed tomography (CT) or direct renal exploration is used to accomplish injury classification. Most recent clinical research and publications in the field of renal trauma have adopted this classification. In a retrospective review, the AAST scaling system was determined as the most important variable predicting the need for kidney repair or removal (18).

**Table 1.1: AAST renal injury grading scale (17)**

Grade	Description of injury
1	Contusion or non-expanding subcapsular haematoma No laceration
2	Non-expanding perirenal haematoma Cortical laceration < 1 cm deep without extravasation
3	Cortical laceration > 1 cm without urinary extravasation
4	Laceration: through corticomedullary junction into collecting system <b>or</b> Vascular: segmental renal artery or vein injury with contained haematoma, or partial vessel laceration or vessel thrombosis
5	Laceration: shattered kidney <b>or</b> Vascular: renal pedicle or avulsion

### 1.3 Diagnosis: Initial emergency assessment

Initial assessment of the trauma patient should include securing of the airway, controlling external bleeding and resuscitation of shock as required. In many cases, physical examination is carried out simultaneous to stabilization of the patient. When renal injury is suspected, further evaluation is required for a prompt diagnosis.

#### 1.3.1 History and physical examination

Direct history is obtained from conscious patients. Witnesses and emergency personnel can provide valuable information regarding unconscious or seriously injured patients. Possible indicators of major renal injury include a rapid deceleration event (fall, high-speed motor vehicle accidents) and a direct blow to the flank. In assessing trauma patients after motor vehicle accidents, the history should include the vehicle's speed and whether the patient was a passenger or pedestrian.

In penetrating injuries, important information includes the size of the weapon in stabbings and the type and calibre of weapon used in gunshot wounds since high-velocity projectiles have the potential for more extensive damage.

The medical history should be as detailed as possible, as pre-existing organ dysfunction can negatively effect on trauma patient outcome (19). In the early resuscitation phase, special consideration should be given to preexisting renal disease (20). Another point of interest is the functioning renal mass of the trauma patient, as there are numerous case reports in the literature regarding renal trauma and the subsequent complications of solitary kidneys (21).

Pre-existing renal abnormality makes renal injury more likely following trauma. Any known pre-existing renal pathology should be registered. Hydronephrosis due to ureteropelvic junction abnormality, renal calculi, cysts and tumours are the most common reported entities that may complicate a minor renal injury (22). The overall percentage of these cases varies from 3.5% to 21.8% (23,24).

Physical examination is the basis for the initial assessment of each trauma patient. Haemodynamic stability is the primary criterion for the management of all renal injuries. Shock is defined as a systolic blood pressure of less than 90 mmHg found at any time during an adult patient's evaluation. Vital signs should be recorded throughout diagnostic evaluation.

Physical examination may reveal obvious penetrating trauma from stab wound to the lower thoracic back, flanks and upper abdomen, or bullet entry or exit wounds in this area. In stab wounds, the extent of the entrance wound will not accurately reflect the depth of penetration. Blunt trauma to the back, flank, lower thorax, or upper abdomen may result in renal injury. The following findings on physical examination may indicate possible renal involvement:

1. Haematuria
2. Flank pain
3. Flank ecchymoses
4. Flank abrasions
5. Fractured ribs
6. Abdominal distension
7. Abdominal mass
8. Abdominal tenderness.

### 1.3.1.1 GUIDELINES ON HISTORY AND PHYSICAL EXAMINATION

- Haemodynamic stability should be decided upon admission
- History should be taken from conscious patients, witnesses, and rescue team personnel regarding the time and setting of the incident.
- Past renal surgery, and known pre-existing renal abnormalities (ureteropelvic junction obstruction, large cysts, lithiasis) should be recorded
- A thorough examination of thorax, abdomen, flanks and back for penetrating wounds should be obtained
- Findings on physical examination, such as haematuria, flank pain, flank abrasions and ecchymoses, fractured ribs, abdominal tenderness, distension or mass, may indicate possible renal involvement.

### 1.3.2 Laboratory evaluation

The trauma patient is evaluated by a series of laboratory tests. Urinalysis, value of haematocrit and baseline creatinine are the most important tests for evaluating renal trauma.

Urinalysis is considered the basic test in the evaluation of patients with suspected renal trauma. Haematuria is the presence of an abnormal quantity of red blood cells in the urine and is usually the first indicator of renal injury. Microscopic haematuria in the trauma setting may be defined as greater than 5 red blood cells per high-power field (rbc/hpf), while gross haematuria is the finding of urine that is readily visible as containing blood.

Haematuria is a hallmark sign of renal injury, but is neither sensitive nor specific enough for differentiating minor and major injuries. It does not necessarily correlate with the degree of injury (25). Major renal injury, such as disruption of the ureteropelvic junction, renal pedicle injuries or segmental arterial thrombosis may occur without haematuria (26). In a study by Eastham, 9% of patients with stab wounds and resultant proven renal injury did not manifest haematuria (27). Haematuria out of proportion to the history of trauma may suggest pre-existing renal pathology (28).

Urine dipstick is an acceptably reliable and rapid test to evaluate haematuria. Studies have shown false-negative result rates ranging from 2.5% to 10% that result from the dipstick test for haematuria (29). Serial haematocrit determination is a method of continuous evaluation of the trauma patient. Initial haematocrit in association with vital signs implies the need for emergency resuscitation. The decrease in haematocrit and the requirements for blood transfusions is an indirect sign of the rate of blood loss and along with the patient's response to resuscitation is valuable in the decision-making process.

As most trauma patients are evaluated within 1 hour after injury, creatinine measurement reflects renal function prior to the injury. An increased creatinine usually reflects pre-existing renal pathology.

### 1.3.2.1 GUIDELINES ON LABORATORY EVALUATION

- Urine from a patient with suspected renal injury should be inspected grossly and then by dipstick analysis
- Serial haematocrit measurement indicates blood loss. However, until evaluation is complete, it will not be clear whether it is due to renal trauma or/and associated injuries
- Creatinine measurement may highlight patients with impaired renal function prior to injury.

### 1.3.3 Imaging: criteria for radiographic assessment in adults

Decisions about radiographic imaging in cases of suspected renal trauma are based on the clinical findings and the mechanism of injury. Since the majority of renal injuries are not significant and resolve without any intervention, many attempts have been made to identify patients who could be spared the discomfort, radiation exposure, possible allergic reaction, and expense of a radiographic evaluation (30).

There is mounting evidence that some patients following blunt renal trauma do not require radiographic evaluation. Patients with microscopic haematuria and no shock after blunt trauma have a low likelihood of concealing significant renal injury (31). The indications for radiographic evaluation are gross haematuria, microscopic haematuria and shock, or presence of major associated injuries (30,32). However, patients with a history of rapid deceleration injury with clinical indicators of renal trauma or associated injuries also need immediate imaging to rule out ureteral avulsion or renal pedicle injury (9).

Patients with penetrating trauma to the torso have a high incidence of significant renal injuries. If renal injury is clinically suspected on the basis of an entry or exit wound, renal imaging should be performed, regardless of the degree of haematuria (30,33).

#### 1.3.3.1 Ultrasonography

Ultrasonography is a popular imaging modality in the initial evaluation of abdominal trauma. While it provides a quick, non-invasive, low-cost means of detecting peritoneal fluid collections, without exposure to radiation or contrast agents (34), the role of ultrasound in the radiographic evaluation of renal trauma has been widely

questioned. Its limitations stem from the difficulty in obtaining good acoustic windows on the trauma patient who has sustained numerous associated injuries. The results are also highly dependent on the operator. Ultrasound scans can detect renal lacerations but cannot definitely assess their depth and extent and do not provide functional information about renal excretion or urine leakage.

Despite the drawbacks of the method, ultrasound scans can be conveniently used during the primary assessment of renal injuries (35). During the evaluation of blunt trauma patients, ultrasound scans were more sensitive and specific than standard intravenous pyelography (IVP) in minor renal trauma (36). In another study comparing the results of ultrasound scans and IVP, the sensitivity of ultrasound decreased as the severity of the trauma increased, while that of IVP remained high for all degrees of severity (37).

Another possible role for ultrasound may be for serially evaluating stable renal injuries for the resolution of urinomas and retroperitoneal haematomas (38). Ultrasound might be considered suitable for the routine followup of renal parenchymal lesions or haematoma in the intensive care unit.

In conclusion, since ultrasound scans are used in the triage of patients with blunt abdominal trauma, they can be helpful in identifying which patients require a more aggressive radiological exploration to obtain a diagnosis of certainty (25,39,40). Ultrasound findings do not provide sufficient evidence for a definite answer on the severity of renal injuries.

#### *1.3.3.2 Standard intravenous pyelography (IVP)*

Formal IVP has been the preferred imaging study for evaluating renal trauma until its replacement by CT. While standard IVP is no longer the study of choice for the evaluation of renal trauma, we acknowledge that in some centers it may be the only study available. In these situations, IVP should establish the presence or absence of one or both of the kidneys, clearly define the renal parenchyma, and outline the collecting system. In order to stage renal trauma, the IVP should include nephrotomograms, delineate the renal contour, and visualize the excretion of contrast material from both kidneys into the renal pelvis and ureter. Non-visualization, contour deformity, or extravasation of contrast implies a major renal injury and should prompt further radiological evaluation with CT or less-commonly, angiography if available.

The most significant findings on IVP are non-function and extravasation. Non-function is usually a sign of extensive trauma to the kidney, pedicle injury (vascular avulsion or thrombosis) or a severely shattered kidney. Extravasation of the contrast medium also implies a severe degree of trauma, involving the capsule, parenchyma and collecting system. Other less reliable signs are delayed excretion, incomplete filling, calyceal distortion and obscuring of the renal shadow. The sensitivity of IVP is high (> 92%) for all degrees of trauma severity (37).

#### *1.3.3.3 One shot intraoperative intravenous pyelography (IVP)*

Unstable patients selected for immediated operative intervention (and thus unable to have a CT scan) should undergo one-shot IVP in the operating suite. The technique consists of a bolus intravenous injection of 2 ml/kg radiographic contrast followed by a single plain film taken after 10 minutes. The study is safe, efficient, and of high quality in the majority of cases. It provides important information for decision-making in the critical time of urgent laparotomy, concerning the injured kidney, as well as the presence of a normal functioning kidney on the contralateral side (41).

While the majority of experts advocate their use, not all studies have shown the one shot IVP to be necessary. In cases of penetrating abdominal trauma Patel et al. found that the positive predictive value of the study was only 20%. (80% of patients with normal one-shot IVP findings had renal injuries not detected by one shot IVP [42]). The authors concluded that one-shot IVP is of no significant value in assessing penetrating abdominal trauma patients who undergo exploratory laparotomy for associated intra-abdominal injuries, and should be reserved only for patients with a flank wound or gross haematuria following penetrating trauma (43).

#### *1.3.3.4 Computed tomography (CT)*

Computed tomography is the gold standard method for the radiographic assessment of stable patients with renal trauma, though it may not be available in all settings, and is time-consuming. The higher cost of CT scans is a also major disadvantage, but CT is more sensitive and specific than IVP, ultrasonography or angiography (44). In a retrospective study, Qin et al. found that the positive rate during evaluation of 298 patients was 95.6% by CT, 90.9% by double-dose intravenous IVP and 78.8% by ultrasound (35).

Computed tomography more accurately defines the location of injuries, easily detects contusions and devitalized segments, visualizes the entire retroperitoneum and any associated haematomas, and simultaneously provides a view of both the abdomen and pelvis. It demonstrates superior anatomical detail, including the depth and location of renal laceration and presence of associated abdominal injuries, and establishes the presence and location of the contralateral kidney (45). Computed tomography is particularly useful in evaluating traumatic injuries to kidneys with pre-existing abnormalities (22,46).

Intravenous contrast should be administered concurrently for renal evaluation. A lack of contrast



enhancement of the injured kidney is a hallmark of renal pedicle injury. In cases where this typical finding is not demonstrated, central parahilar haematoma increases the possibility of renal pedicle injury. This sign should be considered even if the renal parenchyma is well-enhanced (47). Renal vein injury remains one injury that is difficult to diagnose with any type of radiographic study; however, the presence on CT of a large haematoma, medial to the kidney and displacing the renal vasculature, should raise the suspicion of venous injury.

The development and increasing availability of spiral CT has changed the diagnostic evaluation of trauma patients. Spiral CT provides shorter scanning time and thus fewer artifacts in the examinations of patients who cannot co-operate adequately (48). Three-dimensional post-processing modalities allow the assessment of the renal vascular pedicle by CT angiography and improve the demonstration of complex lacerations of the renal parenchyma. However, injury to the renal collecting system may be missed during routine spiral CT. In all cases of suspected renal trauma evaluated with spiral CT, repeat scans of the kidneys should be performed 10-15 minutes after contrast injection (49).

#### 1.3.3.5 Magnetic resonance imaging (MRI)

While MRI is not used in the vast majority of renal trauma patients, Leppaniemi et al. investigated the use of high-field strength MRI (1.0 T) in the evaluation of blunt renal trauma. Magnetic resonance imaging scans were accurate in finding perirenal haematomas, assessing the viability of renal fragments, and detecting pre-existing renal abnormalities, but failed to visualize urinary extravasation on initial examination. The authors concluded that MRI could replace CT in patients with iodine allergy and could be used for initial staging if CT was not available (50). In a recent study comparing CT and MRI findings, the latter clearly revealed renal fracture with non-viable fragment and was able to detect focal renal laceration not detected on CT due to perirenal haematoma (51).

However, MRI is not the first choice in managing the patient with trauma, because it requires longer imaging time, increases the cost, and limits access to the patient in the magnet during the examination. Thus, MRI may be useful in renal trauma only if CT is not available, in patients with iodine allergy, or in the very few cases where the findings on CT are equivocal.

#### 1.3.3.6 Angiography

Computed tomography has largely replaced the use of angiography for staging renal injuries, since angiography is less specific, more time-consuming and more invasive. Angiography, however, is more specific for defining the exact location and degree of vascular injuries and may be preferable when planning selective embolization for the management of persistent or delayed haemorrhage from branching renal vessels (46).

Angiography can define renal lacerations, extravasation and pedicle injury. Additionally, it is the test of choice for evaluating renal venous injuries. The most common indication for arteriography is non-visualization of a kidney on IVP after major blunt renal trauma when a CT is not available. Common causes for nonvisualization are:

- Total avulsion of the renal vessels (usually presents with life-threatening bleeding)
- Renal artery thrombosis
- Severe contusion causing major vascular spasm.

Angiography is also indicated in stable patients to assess pedicle injury, if the findings on CT are unclear, and for those who are candidates for radiological control of haemorrhage (27).

#### 1.3.3.7 Radionuclide scans

Radionuclide scans may be helpful to document renal blood flow in the trauma patient with severe allergy to iodinated contrast material (46), but are not generally used or needed.

### 1.3.3.8 GUIDELINES ON RADIOGRAPHIC ASSESSMENT

- Blunt trauma patients with macroscopic or microscopic haematuria (at least 5 rbc/hpf) with hypotension (systolic blood pressure < 90mmHg) should undergo radiographic evaluation
- Radiographic evaluation is also recommended for all patients with a history of rapid deceleration injury and/or significant associated injuries
- All patients with any degree of haematuria after penetrating abdominal or thoracic injury require urgent renal imaging
- Ultrasonography can be informative during the primary evaluation of polytrauma patients and for the follow-up of recuperating patients, although more data is required to universally suggest this modality
- A CT scan with enhancement of intravenous contrast material is the best imaging study for diagnosis and staging renal injuries in haemodynamically stable patients
- Unstable patients who require emergency surgical exploration should undergo a one-shot IVP with

bolus intravenous injection of 2 ml/kg contrast

- Formal IVP, MRI and radiographic scintigraphy are acceptable second-line alternatives of imaging renal trauma when CT is not available
- Angiography can be used for diagnosis and simultaneous selective embolization of bleeding vessels.

## 1.4 Treatment

### 1.4.1 Indications for renal exploration

The goal of management of patients with renal injuries is to minimize morbidity and to preserve renal function. Thus, renal exploration should be undertaken selectively. The condition of the patient remains the absolute determinant in the decision for initial observation versus surgical intervention. However, the management of renal injury is usually influenced by the decision to explore or observe associated abdominal injuries (4,52).

A life-threatening haemodynamic instability due to renal haemorrhage is an absolute indication for renal exploration, irrespective of the mode of injury (53,54). Other indications include an expanding or pulsatile perirenal haematoma identified at exploratory laparotomy performed for associated injuries (this finding heralds a Grade 5 vascular injury and is quite rare). A one-shot, intra-operative IVP can provide valuable information. Poor visualization or any other abnormality of the injured kidney is an indication for exploration. Grade 5 vascular renal injuries are by definition regarded as an absolute indication for exploration, however a single report suggesting that patients who are haemodynamically stable at presentation, but with a Grade 5 parenchymal injury (shattered kidney) after blunt trauma might be safely treated conservatively (55). More research on this rare entity is required before definitive recommendations are given, and each patient must be treated individually for the best outcomes.

The management of major renal injuries with urinary extravasation and devitalized fragments is controversial. Since these injuries are very uncommon, published series report on small numbers of patients. In recent years, it seems as though it has been recognized that most major injuries heal with non-operative treatment (56). Moudouni et al. suggest that an initial conservative approach is feasible in stable patients with devitalized fragments (57). These injuries, however, are associated with an increased rate of complications and late surgery (58). Persistent extravasation or urinoma are usually managed successfully with endourological techniques. Inconclusive renal imaging and a pre-existing renal abnormality or an incidentally diagnosed tumour may require surgery even after relatively minor renal injury (23,28).

### 1.4.2 Operative findings and reconstruction

The overall exploration rate for blunt trauma is less than 10% (1,53), and may be even lower in the future as more centers adopt a very conservative approach to the management of these patients (59,60). The goal of renal exploration following renal trauma is control of hemorrhage and renal salvage. Most experienced authors suggest the transperitoneal approach (53,61,62). Access to the renal vascular pedicle is best obtained through the posterior parietal peritoneum, which is incised over the aorta, just medial to the inferior mesenteric vein.

Temporary vascular occlusion before opening of Gerota's fascia is a safe and effective method during exploration and renal reconstruction (63). It tends to lower blood loss and nephrectomy rate, and appears not to increase postoperative azotaemia or mortality (64). Renal reconstruction is feasible in most cases. The overall rate of patients who have a nephrectomy during exploration is around 13%, usually in patients with higher rates of shock, injury severity scores and mortality rates (62). The mortality in this group of patients is associated with the overall severity of the injury and is not a consequence of the renal injury itself (65). In gunshot injuries caused by a high-velocity bullet, reconstruction may be difficult and nephrectomy may be required (13).

Renorrhaphy is the most common reconstructive technique. Partial nephrectomy is required when nonviable tissue is detected. Watertight closure of the collecting system if open may be desirable, although some experts merely close the parenchyma over the injured collecting system with good results. If renal capsule is not preserved, an omental pedicle flap or perirenal fat bolster may be used for coverage (66). In a review by Shekarriz et al. the use of fibrin sealant in traumatic renal reconstruction proved to be helpful (67). Newly-developed hemostatic sealants which have proven useful in open and laparoscopic partial nephrectomy (68), may also be helpful but are largely unproven. In all cases, drainage of the ipsilateral retroperitoneum is recommended to provide an outlet for any temporary urinary leak.

Renovascular injuries are uncommon. They are associated with extensive associated trauma and increased peri- and post-operative mortality and morbidity. In a recent review, Knudson et al. found that after blunt trauma, repair of Grade 5 vascular injury was seldom if ever effective (69). Repair may be attempted in those very rare cases in which there is a solitary kidney or the patient has sustained bilateral injuries (70). In all other cases, nephrectomy appears to be the treatment of choice (71).

Arteriography with selective renal embolization for haemorrhage control is a reasonable alternative to laparotomy provided no other indication for immediate surgery exists (72). The rate of successful haemostasis by embolization is reported identical in blunt and penetrating injuries (73,74).

#### 1.4.3 Non-operative management of renal injuries

As the indications for renal exploration become clearer, non-operative management has become the treatment of choice for the majority of renal injuries. In stable patients, supportive care with bed-rest, hydration and antibiotics is the preferred initial approach. Primary conservative management is associated with a lower rate of nephrectomy, without any increase in the immediate or long-term morbidity (75). The failure of conservative therapy is relatively low (5%) (3).

All Grade 1 and 2 renal injuries can be managed non-operatively, whether they are due to blunt or penetrating trauma. Therapy of Grade 3 injuries has been controversial for many years. Improved results in all recent studies support expectant treatment (76-78). The majority of patients with Grades 4 and 5 renal injuries present with major associated injuries, with resultant high exploration and nephrectomy rates (79), although emerging data indicates that many of these patients can be managed safely with an expectant approach (59,60,80).

Penetrating wounds have traditionally been approached surgically. However, stable patients should undergo complete staging to define the full extent of the injury. Renal gunshot injuries should be explored only if they involve the hilum or are accompanied by signs of continued bleeding, ureteral injuries, or renal pelvis lacerations (81). Low-velocity gunshot and stab wounds of minor degree may be managed conservatively with an acceptably good outcome (82). Meanwhile, tissue damage from high-velocity gunshot injuries may be more extensive and the majority of patients present with major associated injuries. Haemodynamic instability requiring a nephrectomy is a very common situation (13).

In 1983, Bernath et al. suggested that if the site of penetration by stab wound was posterior to the anterior axillary line, 88% of such renal injuries could be managed non-operatively (83). In another study, analysis suggested that injuries to the flank were more likely to be Grade 3 while injuries to the abdomen were more likely to be Grade 1. A systematic approach based on clinical, laboratory and radiological evaluation may minimize negative exploration without increasing morbidity from missed injury (54). Renal stab wounds producing major renal injuries (Grade 3 or higher) are more unpredictable and they are associated with a higher rate of delayed complications if treated expectantly (84).

#### 1.4.4 GUIDELINES ON MANAGEMENT OF RENAL TRAUMA

- Stable patients, following Grade 1 – 4 blunt renal trauma, should be managed conservatively with bed-rest, prophylactic antibiotics, and continuous monitoring of vital signs until haematuria resolves
- Stable patients, following Grade 1 – 3 stab and low-velocity gunshot wounds after complete staging, should be selected for expectant management
- Indications for surgical management include:
  1. Haemodynamic instability
  2. Exploration for associated injuries
  3. Expanding or pulsatile perirenal haematoma identified during laparotomy
  4. Grade 5 injury
  5. Incidental finding of pre-existing renal pathology requiring surgical therapy.
- Renal reconstruction should be attempted in cases where the primary goal of controlling haemorrhage is achieved and a sufficient amount of renal parenchyma is viable.

#### 1.4.5 Post-operative care and follow-up

Patients who are successfully treated conservatively carry some risk of presenting with complications. This risk correlates with increasing grade. Repeat imaging 2-4 days after trauma minimizes the risk of missed complications, especially in Grade 3 – 5 blunt renal injuries (85). However, the utility of frequent CT scanning after injury has never been satisfactorily proven. CT scans should always be performed on patients with fever, unexplained decreasing haematocrit, or significant flank pain.

Nuclear renal scans are useful for documenting and tracking functional recovery in patients following renal reconstruction before discharge from hospital (86). To detect many of the delayed complications, an excretory urogram is recommended within 3 months of major renal injury, although benefit to the patient has not yet been proven in the literature. Follow-up should involve physical examination, urinalysis, individualized radiological investigation, serial blood pressure measurement and serum determination of renal function (53,57). It is recommended that follow-up examinations should continue until healing is documented and laboratory findings stabilized, although checking for latent renovascular hypertension may need to continue for years.

Literature is generally inadequate on the subject of long-term consequences of trauma on renal tissue. It appears that on histopathological evaluation, renal tissue may appear dystrophic following some cases of conservative management of minor renal injuries (87).

#### 1.4.5.1 GUIDELINES ON POST-OPERATIVE MANAGEMENT AND FOLLOW-UP

- Repeat imaging is recommended for all hospitalized patients within 2 to 4 days following significant renal trauma (although no specific data exists). Repeat imaging is always recommended in cases of fever, flank pain, or dropping haematocrit.
- Nuclear scintigraphy before discharge from the hospital is useful for documenting functional recovery
- Within 3 months of major renal injury, patients' follow-up should involve:
  1. Physical examination
  2. Urinalysis
  3. Individualized radiological investigation
  4. Serial blood pressure measurement
  5. Serum determination of renal function
- Long-term follow-up should be decided on a case-by-case basis but should minimally involve monitoring for renovascular hypertension

#### 1.4.6 Complications

Early complications occur within the first month after injury and can be bleeding, infection, perinephric abscess, sepsis, urinary fistula, hypertension, urinary extravasation and urinoma. Delayed complications include bleeding, hydronephrosis, calculus formation, chronic pyelonephritis, hypertension, arteriovenous fistula, hydronephrosis and pseudoaneurysms.

Delayed retroperitoneal bleeding usually occurs within several weeks of an injury or procedure and may be life-threatening. Selective angiographic embolization is the preferred treatment (88).

Perinephric abscess formation is usually best managed by percutaneous drainage, although open drainage may sometimes be required (53). Percutaneous management of complications may pose less risk of renal loss than re-operation, which may lead to nephrectomy when infected tissues make reconstruction difficult.

Hypertension may occur acutely as a result of external compression from perirenal haematoma (Page kidney), or chronically because of compressive scar formation. Renin-mediated hypertension may occur as a long-term complication; aetiologies include renal artery thrombosis, segmental arterial thrombosis, renal artery stenosis (Goldblatt kidney), devitalized fragments and arteriovenous fistulae. Arteriography is informative in cases of post-traumatic hypertension (89). Treatment is required if hypertension persists and may include medical management, excision of the ischaemic parenchymal segment, vascular reconstruction or total nephrectomy. The frequency of post-traumatic hypertension is estimated to be less than 5% in all published series (90,91).

Urinary extravasation after renal reconstruction often subsides without intervention as long as ureteral obstruction and infection are not present. Ureteral, retrograde stenting may improve drainage and allow healing (92). Persistent urinary extravasation from an otherwise viable kidney after blunt trauma often responds to stent placement and/or percutaneous drainage as necessary (56).

Arteriovenous fistulas usually present with delayed onset of significant haematuria, most often after penetrating trauma. Percutaneous embolization is often effective for symptomatic arteriovenous fistulas, but larger ones may require surgery (93). The development of pseudoaneurysm is a rare complication following blunt renal trauma. In numerous case reports, transcatheter embolization appears to be a reliable minimally invasive solution (94,95). Acute renal colic from a retained missile has been reported, and may be managed endoscopically if possible (96). Other unusual late complications, such as duodenal obstruction, may result from retroperitoneal haematoma following blunt renal trauma (97).

#### 1.4.6.1 GUIDELINES ON MANAGEMENT OF COMPLICATIONS

- Complications following renal trauma require a thorough radiographic evaluation
- Medical management and minimal invasive techniques should be the first choice for the management of complications
- Renal salvage should be the surgeon's aim for patients in whom surgical intervention is necessary.

#### 1.4.7 Paediatric renal trauma

Blunt renal trauma is the most common injury seen in children and accounts for more than 90% of renal injuries in the paediatric population (98-100). Children are more susceptible to renal trauma than adults. Differences in anatomy and physiology, as well as the higher incidence of pre-existing renal disease, make children more likely to sustain injury. The kidneys are lower in the abdomen, less well-protected by the lower ribs and muscles of the flank and abdomen, more mobile, have less protective perirenal fat and are proportionately larger in the abdomen than adults (101-103).

History and physical examination are very important factors in the evaluation of the paediatric patient with suspected renal trauma. Unlike adults, hypotension is an unreliable sign in children, as an outpouring of catecholamines can maintain blood pressure despite a significant volume of blood loss. Hypotension in children is rare and significant injury can be present despite stable blood pressure (104). Another important difference from adults is that children with microscopic haematuria or normal urinalyses and stable vital signs may sustain significant renal injury (105,106). Haematuria is an important clinical sign of pediatric renal injury and is directly related to the severity of renal injury and the presence of associated injuries (107).

The radiographic evaluation of children with suspected renal trauma is still controversial. Stein et al. proposed that all paediatric patients with any degree of haematuria should be evaluated for renal trauma (108). In contrast, Morey et al. concluded that significant injuries are unlikely in the absence of gross or significant microscopic haematuria (> 50 rbc/hpf) (109). Nguyen et al. proposed a low threshold for renal imaging following renal trauma. The instances should include patients with blunt abdominal trauma with any level of haematuria, patients with associated abdominal injury, regardless of the urinalysis findings, and patients with normal urinalyses for whom the mechanism of injury has a high index of suspicion for renal trauma (i.e. rapid deceleration event, direct flank trauma, falls from a height) (106). Santucci et al. after studying 720 pediatric trauma cases concluded that the decision for imaging based on the adult criteria of gross hematuria, shock and significant deceleration injury is appropriate (110).

Ultrasound is considered a reliable method for screening and following the course of renal injury of paediatric patients with blunt renal trauma in Europe, although is it used much less frequently in the United States (111,112). Ultrasound is used in some centers mostly in stable cases, with abnormal urinalyses and/or findings suggestive of a major injury (113). The diagnostic accuracy of IVP is superior to the diagnostic accuracy of ultrasound, and should be performed as an emergency procedure if CT scan is not available (114). The best imaging modality, however, is CT and those with multiple injuries or suspected renal trauma should be evaluated by contrast-enhanced CT if possible (115,116). The use of MRI in paediatric patients with vesicoureteral reflux found that MRI at 1.5 T was better than dimercaptosuccinic acid (DMSA) scans in detecting small renal parenchymal lesions (117), although MRI has little proven use in the acute management of the trauma patient.

Conservative treatment for Grade 1-2 renal injuries is clearly defined and should be managed expectantly (118). Non-operative management results in an excellent long-term outcome in the majority of cases (119). Non-operative management of severe renal injuries in children is an option, but requires close clinical observation, serial CT and the clinical presence to reassess the overall condition continuously to adjust treatment accordingly. Haemodynamic instability and a diagnosed Grade 5 injury are the strongest indications for operative management (59,120). Stable patients with urinary extravasation can be also managed expectantly since most urinomas resolve spontaneously. In cases where there is persistent leakage, ureteral stent placement or percutaneous drainage is feasible and curative in most cases. Major kidney trauma has significant consequences on the opposite side. Posttraumatic functional evaluation by DMSA scintigraphy 8 days after major injury is a valid prognostic indicator (121).

Buckley and McAninch presented an algorithm for management of pediatric renal injuries based on the 25 year experience of the San Francisco General Hospital which is highly recommended (119) (Figure 3).

Mild renal injuries do not require follow-up imaging. In contrast, follow-up is recommended for patients with major injuries since there is increased risk for delayed complications and loss of renal function (122,123). The majority of patients with severe renal injuries develop parenchymal scars. Radionuclide scans, such as DMSA, may be useful in the early diagnosis of scars and consequent hypertension (124).

#### **1.4.7.1 GUIDELINES ON MANAGEMENT OF PAEDIATRIC TRAUMA**

- Indications for radiographic evaluation of children suspected for renal trauma include:
  1. Blunt and penetrating trauma patients with any level of haematuria
  2. Patients with associated abdominal injury regardless of the urinalysis findings
  3. Patients with normal urinalyses who sustained a rapid deceleration event, direct flank trauma, or fall from height
- Ultrasonography is considered a reliable method of screening and monitoring blunt renal injuries, by some researchers, but is not universally accepted
- CT scans is the imaging study of choice for staging renal injuries
- Haemodynamic instability and a diagnosed Grade 5 injury are absolute indications for surgical exploration.

#### **1.4.8 Renal injury in the polytrauma patient**

Approximately 8-10% of blunt and penetrating abdominal injuries involve the kidneys. The incidence of associated injury in penetrating renal trauma ranges from 77-100%. Gunshot wounds are associated with organ injury more often than stab wounds (8,125). The majority of patients with penetrating renal trauma have

associated adjacent organ injuries that may complicate treatment. In the absence of an expanding hematoma with hemodynamic instability, associated multiorgan injuries do not increase the risk of nephrectomy (126).

Blunt and penetrating trauma equally contributed to combined renal and pancreatic injury, as reported by Rosen et al.. Renal preservation was achieved in most patients and the complication rate of the series was 15% (127). A similar rate of complications (16%) was reported in patients with simultaneous colon and renal injury. In a report reviewing this combination of injuries over a period of 17 years, 58% of patients underwent an exploration, with nephrectomies performed in 16% of explorations (128).

Renal injuries seem to be rather rare in patients with blunt chest trauma. In a recent study with polytrauma patients, conservative management was safely attempted in polytrauma patients without increasing morbidity (129). In polytrauma patients undergoing partial or total nephrectomy, there is no increased mortality or renal failure rate (130).

#### **1.4.8.1 GUIDELINES ON MANAGEMENT OF POLYTRAUMA PATIENTS WITH ASSOCIATED RENAL INJURY**

- Polytrauma patients with associated renal injuries should be evaluated on the basis of the most threatening injury
- In cases where the decision for surgical intervention is made, all associated injuries should be evaluated simultaneously
- The decision for conservative management should regard all injuries independently.

#### **1.5 Suggestions for future research studies**

- In some cases, conservative management fails and patients undergo delayed exploration. A study evaluating the epidemiological, clinical and laboratory findings of these patients, as well as the operative findings should be able to highlight prognostic factors for the non-operative management of renal injuries.
- Another future study objective should be blunt trauma Grade 5 patients, as it appears that some of them may benefit from non-operative management.
- Safety and long-term effectiveness of minimal invasive techniques in isolated renal injuries.
- Necessity and nature of followup imaging
- Value of antibiotics administration in low Grade renal injuries selected for conservative management
- Value of one shot IVP in penetrating injuries

#### **1.6 Algorithms**

The algorithms given in Figures 1 and 2 are suggested for the treatment of blunt and penetrating renal injuries in adults.

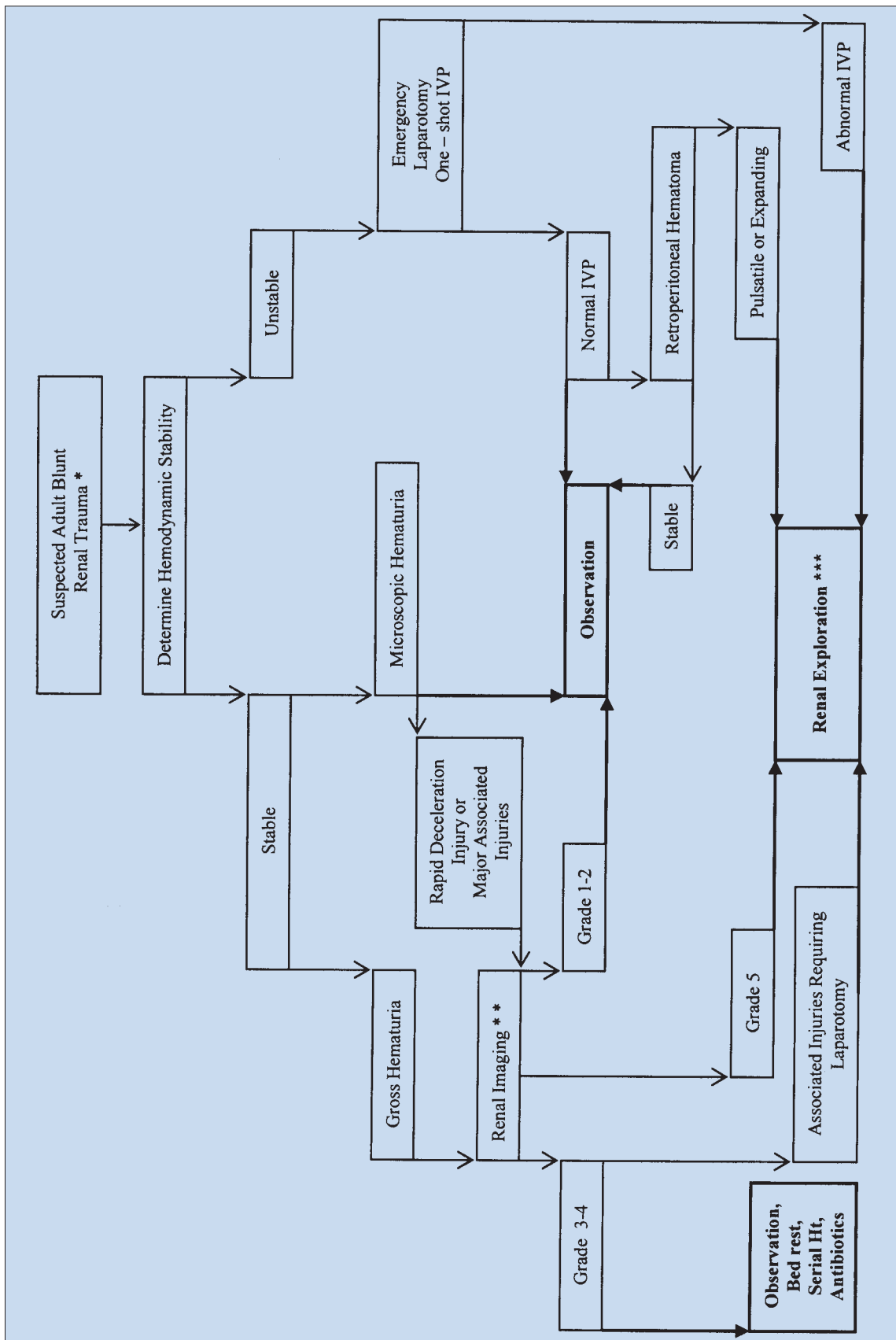


Figure 1: Evaluation of blunt renal trauma in adults

\*Suspected renal trauma results from reported mechanism of injury and physical examination.

\*\* Renal imaging: CT scans are the gold standard for evaluating blunt and penetrating renal injuries in stable patients. In settings where the method is not available, the urologist should rely on other imaging modalities (IVP, angiography, radiographic scintigraphy, MRI).

\*\*\* Renal exploration: Although renal salvage is a primary goal for the urologist, decisions concerning the viability of the organ and the type of reconstruction are made during the operation.

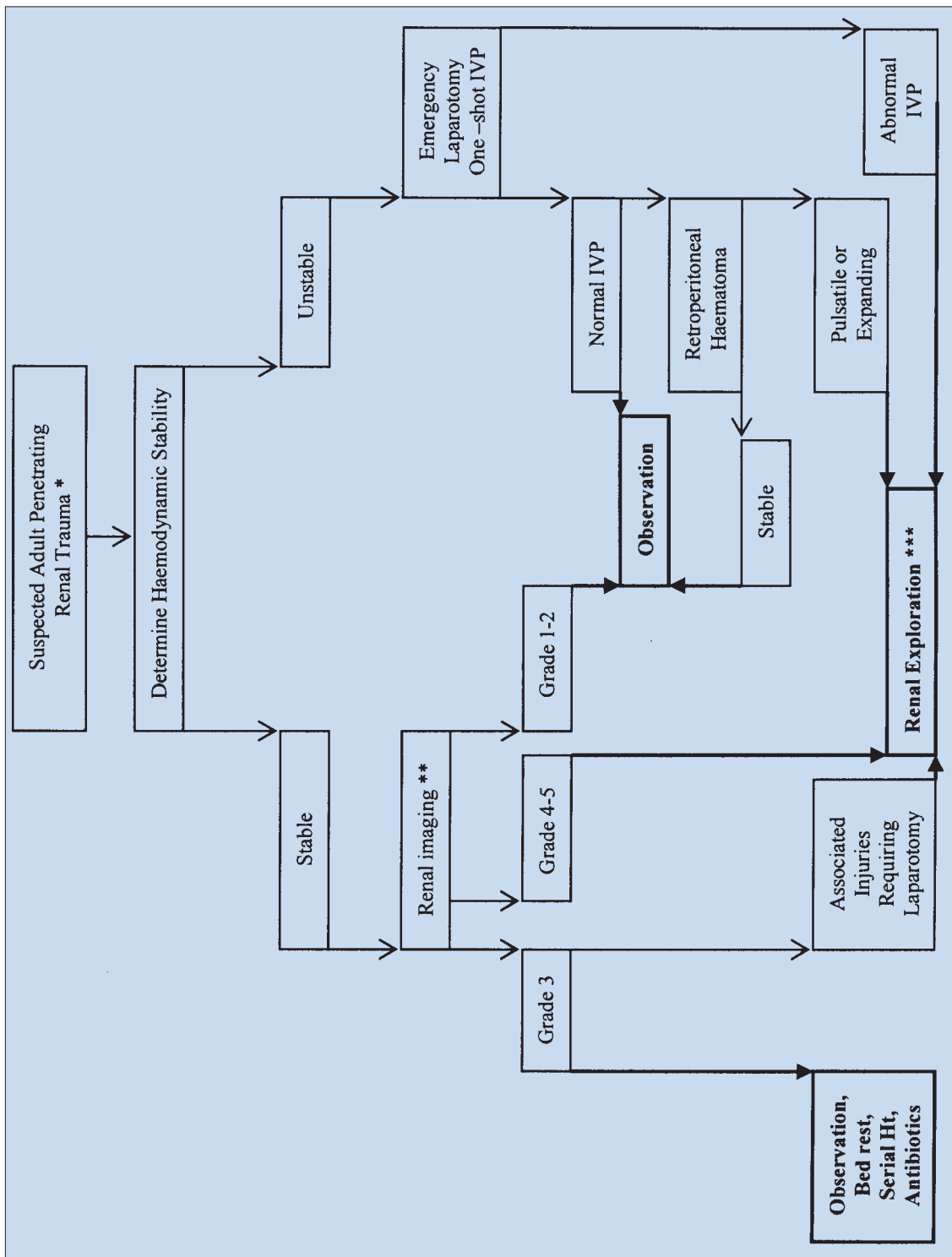


Figure 2: Evaluation of penetrating renal trauma in adults

\*Suspected renal trauma results from reported mechanism of injury and physical examination.

\*\* Renal imaging: CT scans are the gold standard for evaluating blunt and penetrating renal injuries in stable patients. In settings where the method is not available, the urologist should rely on other imaging modalities (IVP, angiography, radiographic scintigraphy, MRI).

\*\*\* Renal exploration: Although renal salvage is a primary goal for the urologist, decisions concerning the viability of the organ and the type of reconstruction are made during the operation.



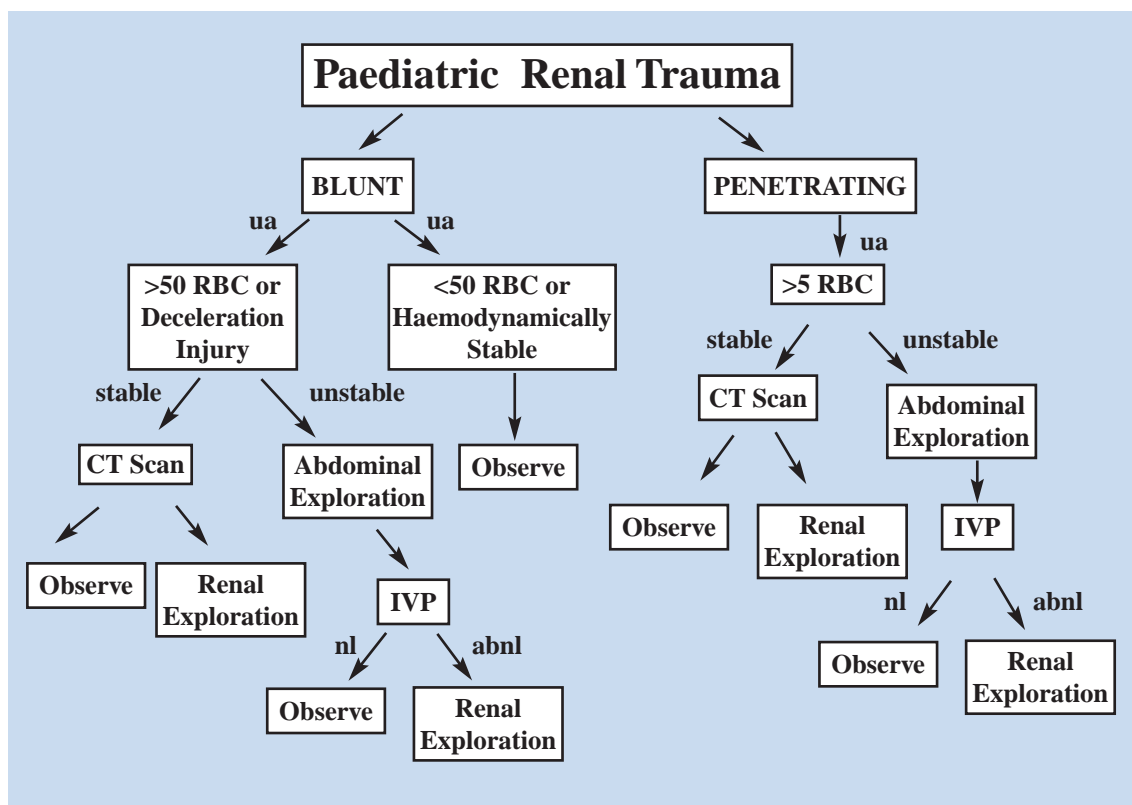


Figure 3. Algorithm for paediatric renal trauma management. ua, urinalysis. nl, normal. abnl, abnormal (119).

## 1.7 References

1. Baverstock R, Simons R, McLoughlin M. Severe blunt renal trauma: a 7-year retrospective review from a provincial trauma centre. *Can J Urol* 2001;8(5):1372–1376.  
[http://www.ncbi.nlm.nih.gov/entrez/query.fcgi?cmd=Retrieve&db=PubMed&list\\_uids=11718633&dopt=Abstract](http://www.ncbi.nlm.nih.gov/entrez/query.fcgi?cmd=Retrieve&db=PubMed&list_uids=11718633&dopt=Abstract)
2. Meng MV, Brandes SB, McAninch JW. Renal trauma: indications and techniques for surgical exploration. *World J Urol* 1999;17(2):71–77.  
[http://www.ncbi.nlm.nih.gov/entrez/query.fcgi?cmd=Retrieve&db=PubMed&list\\_uids=10367364&dopt=Abstract](http://www.ncbi.nlm.nih.gov/entrez/query.fcgi?cmd=Retrieve&db=PubMed&list_uids=10367364&dopt=Abstract)
3. Herschorn S, Radomski SB, Shoskes DA, Mahoney J, Hirshberg E, Klotz L. Evaluation and treatment of blunt renal trauma. *J Urol* 1991;146(2):274–276; discussion 276–277.  
[http://www.ncbi.nlm.nih.gov/entrez/query.fcgi?cmd=Retrieve&db=PubMed&list\\_uids=1856915&dopt=Abstract](http://www.ncbi.nlm.nih.gov/entrez/query.fcgi?cmd=Retrieve&db=PubMed&list_uids=1856915&dopt=Abstract)
4. Kristjansson A, Pedersen J. Management of blunt renal trauma. *Br J Urol* 1993;72(5 Pt2):692–696.  
[http://www.ncbi.nlm.nih.gov/entrez/query.fcgi?cmd=Retrieve&db=PubMed&list\\_uids=8281396&dopt=Abstract](http://www.ncbi.nlm.nih.gov/entrez/query.fcgi?cmd=Retrieve&db=PubMed&list_uids=8281396&dopt=Abstract)
5. Danuser H, Wille S, Zoscher G, Studer U. How to treat blunt kidney ruptures: primary open surgery or conservative treatment with deferred surgery when necessary? *Eur Urol* 2001;39(1):9–14.  
[http://www.ncbi.nlm.nih.gov/entrez/query.fcgi?cmd=Retrieve&db=PubMed&list\\_uids=11173932&dopt=Abstract](http://www.ncbi.nlm.nih.gov/entrez/query.fcgi?cmd=Retrieve&db=PubMed&list_uids=11173932&dopt=Abstract)
6. Santucci RA, McAninch JW. Diagnosis and management of renal trauma: past, present, and future. *J Am Coll Surg* 2000;191(4):443–451.  
[http://www.ncbi.nlm.nih.gov/entrez/query.fcgi?cmd=Retrieve&db=pubmed&dopt=Abstract&list\\_uids=11030250&query\\_hl=5](http://www.ncbi.nlm.nih.gov/entrez/query.fcgi?cmd=Retrieve&db=pubmed&dopt=Abstract&list_uids=11030250&query_hl=5)
7. Krieger JN, Algood CB, Mason JT, Copass MK, Ansell JS. Urological trauma in the Pacific Northwest: etiology, distribution, management and outcome. *J Urol* 1984;132(1):70–73.  
[http://www.ncbi.nlm.nih.gov/entrez/query.fcgi?cmd=Retrieve&db=PubMed&list\\_uids=6726964&dopt=Abstract](http://www.ncbi.nlm.nih.gov/entrez/query.fcgi?cmd=Retrieve&db=PubMed&list_uids=6726964&dopt=Abstract)
8. Sagalowsky AI, McConnell JD, Peters PC. Renal trauma requiring surgery: an analysis of 185 cases. *J Trauma* 1983;23(2):128–131.  
[http://www.ncbi.nlm.nih.gov/entrez/query.fcgi?cmd=Retrieve&db=PubMed&list\\_uids=6827631&dopt=Abstract](http://www.ncbi.nlm.nih.gov/entrez/query.fcgi?cmd=Retrieve&db=PubMed&list_uids=6827631&dopt=Abstract)

9. Brandes SB, McAninch JW. Urban free falls and patterns of renal injury: a 20-year experience with 396 cases. *J Trauma* 1999;47(4):643–649; discussion 649–650.  
[http://www.ncbi.nlm.nih.gov/entrez/query.fcgi?cmd=Retrieve&db=PubMed&list\\_uids=10528597&dopt=Abstract](http://www.ncbi.nlm.nih.gov/entrez/query.fcgi?cmd=Retrieve&db=PubMed&list_uids=10528597&dopt=Abstract)
10. Bruce LM, Croce MA, Santaniello JM, Miller PR, Lyden SP, Fabian TC. Blunt renal artery injury: incidence, diagnosis, and management. *Am Surg* 2001;67(6):550–554; discussion 555–556.  
[http://www.ncbi.nlm.nih.gov/entrez/query.fcgi?cmd=Retrieve&db=PubMed&list\\_uids=11409803&dopt=Abstract](http://www.ncbi.nlm.nih.gov/entrez/query.fcgi?cmd=Retrieve&db=PubMed&list_uids=11409803&dopt=Abstract)
11. Schmidlin F, Farshad M, Bidaut L, Barbezat M, Becker C, Niederer P, Graber P. Biomechanical analysis and clinical treatment of blunt renal trauma. *Swiss Surg* 1998;5:237–243.  
[http://www.ncbi.nlm.nih.gov/entrez/query.fcgi?cmd=Retrieve&db=PubMed&list\\_uids=9816934&dopt=Abstract](http://www.ncbi.nlm.nih.gov/entrez/query.fcgi?cmd=Retrieve&db=PubMed&list_uids=9816934&dopt=Abstract)
12. Sullivan MJ, Stables DP. Renal artery occlusion from trauma. *JAMA* 1972;221(11):1282.  
[http://www.ncbi.nlm.nih.gov/entrez/query.fcgi?cmd=Retrieve&db=PubMed&list\\_uids=5068639&dopt=Abstract](http://www.ncbi.nlm.nih.gov/entrez/query.fcgi?cmd=Retrieve&db=PubMed&list_uids=5068639&dopt=Abstract)
13. Ersay A, Akgun Y. Experience with renal gunshot injuries in a rural setting. *Urology* 1999;54(6):972–975.  
<http://www.ncbi.nlm.nih.gov/entrez/query.fcgi?CMD=&DB=PubMed>
14. Abu-Zidan FM, Al-Tawheed A, Ali YM. Urologic injuries in the Gulf War. *Int Urol Nephrol* 1999;31(5):577–583.  
[http://www.ncbi.nlm.nih.gov/entrez/query.fcgi?cmd=Retrieve&db=PubMed&list\\_uids=10755347&dopt=Abstract](http://www.ncbi.nlm.nih.gov/entrez/query.fcgi?cmd=Retrieve&db=PubMed&list_uids=10755347&dopt=Abstract)
15. Tucak A, Lukacevic T, Kuvezdic H, Petek Z, Novak R. Urogenital wounds during the war in Croatia in 1991/1992. *J Urol* 1995;153(1):121–122.  
[http://www.ncbi.nlm.nih.gov/entrez/query.fcgi?cmd=Retrieve&db=PubMed&list\\_uids=7966742&dopt=Abstract](http://www.ncbi.nlm.nih.gov/entrez/query.fcgi?cmd=Retrieve&db=PubMed&list_uids=7966742&dopt=Abstract)
16. Lent V. What classification is appropriate in renal trauma? *Eur Urol* 1996;30(3):327–334.  
[http://www.ncbi.nlm.nih.gov/entrez/query.fcgi?cmd=Retrieve&db=PubMed&list\\_uids=8931965&dopt=Abstract](http://www.ncbi.nlm.nih.gov/entrez/query.fcgi?cmd=Retrieve&db=PubMed&list_uids=8931965&dopt=Abstract)
17. Moore EE, Shackford SR, Pachter HL, McAninch JW, Browner BD, Champion HR, Flint LM, Gennarelli TA, Malangoni MA, Ramenofsky ML, et al. Organ injury scaling: spleen, liver, and kidney. *J Trauma* 1989;29(12):1664–1666.  
[http://www.ncbi.nlm.nih.gov/entrez/query.fcgi?cmd=Retrieve&db=PubMed&list\\_uids=2593197&dopt=Abstract](http://www.ncbi.nlm.nih.gov/entrez/query.fcgi?cmd=Retrieve&db=PubMed&list_uids=2593197&dopt=Abstract)
18. Santucci RA, McAninch JW, Safir M, Mario LA, Service S, Segal MR. Validation of the American Association for the Surgery of Trauma organ injury severity scale for the kidney. *J Trauma* 2001;50(2):195–200.  
[http://www.ncbi.nlm.nih.gov/entrez/query.fcgi?cmd=Retrieve&db=PubMed&list\\_uids=11242281&dopt=Abstract](http://www.ncbi.nlm.nih.gov/entrez/query.fcgi?cmd=Retrieve&db=PubMed&list_uids=11242281&dopt=Abstract)
19. Sacco WJ, Copes WS, Bain LW Jr, MacKenzie EJ, Frey CF, Hoyt DB, Weigelt JA, Champion HR. Effect of preinjury illness on trauma patient survival outcome. *J Trauma* 1993;35(4):538–542; discussion 542–543.  
[http://www.ncbi.nlm.nih.gov/entrez/query.fcgi?cmd=Retrieve&db=PubMed&list\\_uids=8411276&dopt=Abstract](http://www.ncbi.nlm.nih.gov/entrez/query.fcgi?cmd=Retrieve&db=PubMed&list_uids=8411276&dopt=Abstract)
20. Cachecho R, Millham FH, Wedel SK. Management of the trauma patient with pre-existing renal disease. *Crit Care Clin* 1994;10(3):523–536.  
[http://www.ncbi.nlm.nih.gov/entrez/query.fcgi?cmd=Retrieve&db=PubMed&list\\_uids=7922736&dopt=Abstract](http://www.ncbi.nlm.nih.gov/entrez/query.fcgi?cmd=Retrieve&db=PubMed&list_uids=7922736&dopt=Abstract)
21. Cozar JM, Carcamo P, Hidalgo L, Navarro J, Garcia-Matres MJ, Ortin M, Martinez-Pineiro JA. [Management of injury of the solitary kidney.] *Arch Esp Urol* 1990;43(1):15–18. [Spanish]  
[http://www.ncbi.nlm.nih.gov/entrez/query.fcgi?cmd=Retrieve&db=PubMed&list\\_uids=2331159&dopt=Abstract](http://www.ncbi.nlm.nih.gov/entrez/query.fcgi?cmd=Retrieve&db=PubMed&list_uids=2331159&dopt=Abstract)
22. Sebastia MC, Rodriguez-Dobao M, Quiroga S, Pallisa E, Martinez-Rodriguez M, Alvarez-Castells A. Renal trauma in occult ureteropelvic junction obstruction: CT findings. *Eur Radiol* 1999;9(4):611–615.  
[http://www.ncbi.nlm.nih.gov/entrez/query.fcgi?cmd=Retrieve&db=PubMed&list\\_uids=10354870&dopt=Abstract](http://www.ncbi.nlm.nih.gov/entrez/query.fcgi?cmd=Retrieve&db=PubMed&list_uids=10354870&dopt=Abstract)
23. Bahloul A, Krid M, Trifa M, Mosbah AT, Mhiri MN. [Contusions to the pathologic kidney.] A retrospective study, apropos of 34 cases. *Ann Urol (Paris)* 1997;31(5):253–258. [French]  
[http://www.ncbi.nlm.nih.gov/entrez/query.fcgi?cmd=Retrieve&db=PubMed&list\\_uids=9480628&dopt=Abstract](http://www.ncbi.nlm.nih.gov/entrez/query.fcgi?cmd=Retrieve&db=PubMed&list_uids=9480628&dopt=Abstract)

24. Giannopoulos A, Serafetinides E, Alamanis C, Constantinides C, Anastasiou I, Dimopoulos C. [Urogenital lesions diagnosed incidentally during evaluation for blunt renal injuries.] *Prog Urol* 1999;9(3):464–469. [French]  
[http://www.ncbi.nlm.nih.gov/entrez/query.fcgi?cmd=Retrieve&db=PubMed&list\\_uids=10434318&dopt=Abstract](http://www.ncbi.nlm.nih.gov/entrez/query.fcgi?cmd=Retrieve&db=PubMed&list_uids=10434318&dopt=Abstract)
25. Buchberger W, Penz T, Wicke K, Eberle J. [Diagnosis and staging of blunt kidney trauma. A comparison of urinalysis, i. v. urography, sonography and computed tomography.] *Rofo Fortschr Geb Rontgenstr Neuen Bildgeb Verfahr* 1993;158(6):507–512. [German]  
[http://www.ncbi.nlm.nih.gov/entrez/query.fcgi?cmd=Retrieve&db=PubMed&list\\_uids=8507839&dopt=Abstract](http://www.ncbi.nlm.nih.gov/entrez/query.fcgi?cmd=Retrieve&db=PubMed&list_uids=8507839&dopt=Abstract)
26. Carroll PR, McAninch JW, Klosterman P, Greenblatt M. Renovascular trauma: risk assessment, surgical management, and outcome. *J Trauma* 1990;30(5):547–552; discussion 553–554.  
[http://www.ncbi.nlm.nih.gov/entrez/query.fcgi?cmd=Retrieve&db=PubMed&list\\_uids=2342137&dopt=Abstract](http://www.ncbi.nlm.nih.gov/entrez/query.fcgi?cmd=Retrieve&db=PubMed&list_uids=2342137&dopt=Abstract)
27. Eastham JA, Wilson TG, Larsen DW, Ahlering TE. Angiographic embolization of renal stab wounds. *J Urol* 1992;148(2 Pt 1):268–270.  
[http://www.ncbi.nlm.nih.gov/entrez/query.fcgi?cmd=Retrieve&db=PubMed&list\\_uids=1635114&dopt=Abstract](http://www.ncbi.nlm.nih.gov/entrez/query.fcgi?cmd=Retrieve&db=PubMed&list_uids=1635114&dopt=Abstract)
28. Schmidlin FR, Iselin CE, Naimi A, Rohner S, Borst F, Farshad M, Niederer P, Graber P. The higher injury risk of abnormal kidneys in blunt renal trauma. *Scand J Urol Nephrol* 1998;32(6):388–392.  
[http://www.ncbi.nlm.nih.gov/entrez/query.fcgi?cmd=Retrieve&db=PubMed&list\\_uids=9925001&dopt=Abstract](http://www.ncbi.nlm.nih.gov/entrez/query.fcgi?cmd=Retrieve&db=PubMed&list_uids=9925001&dopt=Abstract)
29. Chandhoke PS, McAninch JW. Detection and significance of microscopic hematuria in patients with blunt renal trauma. *J Urol* 1988;140(1):16–18.  
[http://www.ncbi.nlm.nih.gov/entrez/query.fcgi?cmd=Retrieve&db=PubMed&list\\_uids=3379684&dopt=Abstract](http://www.ncbi.nlm.nih.gov/entrez/query.fcgi?cmd=Retrieve&db=PubMed&list_uids=3379684&dopt=Abstract)
30. Miller KS, McAninch JW. Radiographic assessment of renal trauma: our 15-year experience. *J Urol* 1995;154(2 Pt 1):352–355.  
[http://www.ncbi.nlm.nih.gov/entrez/query.fcgi?cmd=Retrieve&db=PubMed&list\\_uids=7609096&dopt=Abstract](http://www.ncbi.nlm.nih.gov/entrez/query.fcgi?cmd=Retrieve&db=PubMed&list_uids=7609096&dopt=Abstract)
31. Hardeman SW, Husmann DA, Chinn HK, Peters PC. Blunt urinary tract trauma: identifying those patients who require radiological diagnostic studies. *J Urol* 1987;138(1):99–101.  
[http://www.ncbi.nlm.nih.gov/entrez/query.fcgi?cmd=Retrieve&db=PubMed&list\\_uids=3599230&dopt=Abstract](http://www.ncbi.nlm.nih.gov/entrez/query.fcgi?cmd=Retrieve&db=PubMed&list_uids=3599230&dopt=Abstract)
32. McAndrew JD, Corriere JN Jr. Radiographic evaluation of renal trauma: evaluation of 1103 consecutive patients. *Br J Urol* 1994;73(4):352–354.  
[http://www.ncbi.nlm.nih.gov/entrez/query.fcgi?cmd=Retrieve&db=PubMed&list\\_uids=8199819&dopt=Abstract](http://www.ncbi.nlm.nih.gov/entrez/query.fcgi?cmd=Retrieve&db=PubMed&list_uids=8199819&dopt=Abstract)
33. Mee SL, McAninch JW. Indications for radiographic assessment in suspected renal trauma. *Urol Clin North Am* 1989;16(2):187–192.  
[http://www.ncbi.nlm.nih.gov/entrez/query.fcgi?cmd=Retrieve&db=PubMed&list\\_uids=2652848&dopt=Abstract](http://www.ncbi.nlm.nih.gov/entrez/query.fcgi?cmd=Retrieve&db=PubMed&list_uids=2652848&dopt=Abstract)
34. Brown DF, Rosen CL, Wolfe RE. Renal ultrasonography. *Emerg Med Clin North Am* 1997;15(4):877–893.  
[http://www.ncbi.nlm.nih.gov/entrez/query.fcgi?cmd=Retrieve&db=PubMed&list\\_uids=9391497&dopt=Abstract](http://www.ncbi.nlm.nih.gov/entrez/query.fcgi?cmd=Retrieve&db=PubMed&list_uids=9391497&dopt=Abstract)
35. Qin R, Wang P, Qin W, Wang H, Chen B. Diagnosis and treatment of renal trauma in 298 patients. *Chin J Traumatol* 2002;5(1):21–23.  
[http://www.ncbi.nlm.nih.gov/entrez/query.fcgi?cmd=Retrieve&db=PubMed&list\\_uids=11835751&dopt=Abstract](http://www.ncbi.nlm.nih.gov/entrez/query.fcgi?cmd=Retrieve&db=PubMed&list_uids=11835751&dopt=Abstract)
36. Arena F, Peracchia G, di Stefano C, Sebastio N, Cortellini P. [The role of echotomography in minor renal traumatology.] *Acta Biomed Ateneo Parmense* 1997;68(3-4):53–57. [Italian]  
[http://www.ncbi.nlm.nih.gov/entrez/query.fcgi?cmd=Retrieve&db=PubMed&list\\_uids=10068351&dopt=Abstract](http://www.ncbi.nlm.nih.gov/entrez/query.fcgi?cmd=Retrieve&db=PubMed&list_uids=10068351&dopt=Abstract)
37. Abel ME, Chiu YS, Russell TR, Volpe PA. Autologous fibrin glue in the treatment of rectovaginal and complex fistulas. *Dis Colon Rectum* 1993;36(5): 447–449.  
[http://www.ncbi.nlm.nih.gov/entrez/query.fcgi?cmd=Retrieve&db=pubmed&dopt=Abstract&list\\_uids=8482163&query\\_hl=3&itool=pubmed\\_docsum](http://www.ncbi.nlm.nih.gov/entrez/query.fcgi?cmd=Retrieve&db=pubmed&dopt=Abstract&list_uids=8482163&query_hl=3&itool=pubmed_docsum)

38. Pollack HM, Wein AJ. Imaging of renal trauma. *Radiology* 1989;172(2):297–308.  
[http://www.ncbi.nlm.nih.gov/entrez/query.fcgi?cmd=Retrieve&db=PubMed&list\\_uids=2664858&dopt=Abstract](http://www.ncbi.nlm.nih.gov/entrez/query.fcgi?cmd=Retrieve&db=PubMed&list_uids=2664858&dopt=Abstract)
39. McGahan JP, Richards JR, Jones CD, Gerscovich EO. Use of ultrasonography in the patient with acute renal trauma. *J Ultrasound Med* 1999;18(3):207–213; quiz 215–216.  
[http://www.ncbi.nlm.nih.gov/entrez/query.fcgi?cmd=Retrieve&db=PubMed&list\\_uids=10082355&dopt=Abstract](http://www.ncbi.nlm.nih.gov/entrez/query.fcgi?cmd=Retrieve&db=PubMed&list_uids=10082355&dopt=Abstract)
40. Rosales A, Arango O, Coronado J, Vesa J, Maristany J, Gelabert A. The use of ultrasonography as the initial diagnostic exploration in blunt renal trauma. *Urol Int* 1992;48(2):134–137.  
[http://www.ncbi.nlm.nih.gov/entrez/query.fcgi?cmd=Retrieve&db=PubMed&list\\_uids=1585506&dopt=Abstract](http://www.ncbi.nlm.nih.gov/entrez/query.fcgi?cmd=Retrieve&db=PubMed&list_uids=1585506&dopt=Abstract)
41. Morey AF, McAninch JW, Tiller BK, Duckett CP, Carroll PR. Single shot intraoperative excretory urography for the immediate evaluation of renal trauma. *J Urol* 1999;161(4):1088–1092.  
[http://www.ncbi.nlm.nih.gov/entrez/query.fcgi?cmd=Retrieve&db=PubMed&list\\_uids=10081844&dopt=Abstract](http://www.ncbi.nlm.nih.gov/entrez/query.fcgi?cmd=Retrieve&db=PubMed&list_uids=10081844&dopt=Abstract)
42. Patel VG, Walker ML. The role of “one-shot” intravenous pyelogram in evaluation of penetrating abdominal trauma. *Am Surg* 1997;63(4):350–353.  
[http://www.ncbi.nlm.nih.gov/entrez/query.fcgi?cmd=Retrieve&db=PubMed&list\\_uids=9124757&dopt=Abstract](http://www.ncbi.nlm.nih.gov/entrez/query.fcgi?cmd=Retrieve&db=PubMed&list_uids=9124757&dopt=Abstract)
43. Nagy KK, Brenneman FD, Krosner SM, Fildes JJ, Roberts RR, Joseph KT, Smith RF, Barrett J. Routine pre-operative “one-shot” intravenous pyelography is not indicated in all patients with penetrating abdominal trauma. *J Am Coll Surg* 1997;185(6):530–533.  
[http://www.ncbi.nlm.nih.gov/entrez/query.fcgi?cmd=Retrieve&db=PubMed&list\\_uids=9404875&dopt=Abstract](http://www.ncbi.nlm.nih.gov/entrez/query.fcgi?cmd=Retrieve&db=PubMed&list_uids=9404875&dopt=Abstract)
44. Bretan PN Jr, McAninch JW, Federle MP, Jeffrey RB Jr. Computerized tomographic staging of renal trauma: 85 consecutive cases. *J Urol* 1986;136(3):561–565.  
[http://www.ncbi.nlm.nih.gov/entrez/query.fcgi?cmd=Retrieve&db=PubMed&list\\_uids=3735529&dopt=Abstract](http://www.ncbi.nlm.nih.gov/entrez/query.fcgi?cmd=Retrieve&db=PubMed&list_uids=3735529&dopt=Abstract)
45. Steinberg DL, Jeffrey RB, Federle MP, McAninch JW. The computerized tomography appearance of renal pedicle injury. *J Urol* 1984;132(6):1163–1164.  
[http://www.ncbi.nlm.nih.gov/entrez/query.fcgi?cmd=Retrieve&db=PubMed&list\\_uids=6502811&dopt=Abstract](http://www.ncbi.nlm.nih.gov/entrez/query.fcgi?cmd=Retrieve&db=PubMed&list_uids=6502811&dopt=Abstract)
46. Kawashima A, Sandler CM, Corl FM, West OC, Tamm EP, Fishman EK, Goldman SM. Imaging of renal trauma: a comprehensive review. *Radiographics* 2001;21(3):557–574.  
[http://www.ncbi.nlm.nih.gov/entrez/query.fcgi?cmd=Retrieve&db=PubMed&list\\_uids=11353106&dopt=Abstract](http://www.ncbi.nlm.nih.gov/entrez/query.fcgi?cmd=Retrieve&db=PubMed&list_uids=11353106&dopt=Abstract)
47. Shima H, Nosaka S, Hayakawa M, Kawaguchi H, Wakabayashi M, Saeki M, Yamaguchi T, Nakajima Y, Ishikawa T. [Diagnostic imaging of renal pedicle injury.] *Nippon Igaku Hoshasen Gakkai Zasshi* 1997;57(1):5–11. [Japanese]  
[http://www.ncbi.nlm.nih.gov/entrez/query.fcgi?cmd=Retrieve&db=PubMed&list\\_uids=9038056&dopt=Abstract](http://www.ncbi.nlm.nih.gov/entrez/query.fcgi?cmd=Retrieve&db=PubMed&list_uids=9038056&dopt=Abstract)
48. Vasile M, Bellin MF, Helenon O, Mourey I, Cluzel P. Imaging evaluation of renal trauma. *Abdom Imaging* 2000;25(4):424–430.  
[http://www.ncbi.nlm.nih.gov/entrez/query.fcgi?cmd=Retrieve&db=PubMed&list\\_uids=10926198&dopt=Abstract](http://www.ncbi.nlm.nih.gov/entrez/query.fcgi?cmd=Retrieve&db=PubMed&list_uids=10926198&dopt=Abstract)
49. Brown SL, Hoffman DM, Spirnak JP. Limitations of routine spiral computerized tomography in the evaluation of blunt renal trauma. *J Urol* 1998;160(6 Pt 1):1979–1981.  
[http://www.ncbi.nlm.nih.gov/entrez/query.fcgi?cmd=Retrieve&db=PubMed&list\\_uids=9817304&dopt=Abstract](http://www.ncbi.nlm.nih.gov/entrez/query.fcgi?cmd=Retrieve&db=PubMed&list_uids=9817304&dopt=Abstract)
50. Leppaniemi A, Lamminen A, Tervahartiala P, Salo J. MRI and CT in blunt renal trauma: an update. *Semin Ultrasound CT MR* 1997;18(2):129–135.  
[http://www.ncbi.nlm.nih.gov/entrez/query.fcgi?cmd=Retrieve&db=PubMed&list\\_uids=9163832&dopt=Abstract](http://www.ncbi.nlm.nih.gov/entrez/query.fcgi?cmd=Retrieve&db=PubMed&list_uids=9163832&dopt=Abstract)
51. Ku JH, Jeon YS, Kim ME, Lee NK, Park YH. Is there a role for magnetic resonance imaging in renal trauma? *Int J Urol* 2001;8(6):261–267.  
[http://www.ncbi.nlm.nih.gov/entrez/query.fcgi?cmd=Retrieve&db=PubMed&list\\_uids=11389740&dopt=Abstract](http://www.ncbi.nlm.nih.gov/entrez/query.fcgi?cmd=Retrieve&db=PubMed&list_uids=11389740&dopt=Abstract)

52. Husmann DA, Gilling PJ, Perry MO, Morris JS, Boone TB. Major renal lacerations with a devitalized fragment following blunt abdominal trauma: a comparison between nonoperative (expectant) versus surgical management. *J Urol* 1993;150(6):1774–1777.  
[http://www.ncbi.nlm.nih.gov/entrez/query.fcgi?cmd=Retrieve&db=PubMed&list\\_uids=8230501&dopt=Abstract](http://www.ncbi.nlm.nih.gov/entrez/query.fcgi?cmd=Retrieve&db=PubMed&list_uids=8230501&dopt=Abstract)
53. McAninch JW, Carroll PR, Klosterman PW, Dixon CM, Greenblatt MN. Renal reconstruction after injury. *J Urol* 1991;145(5):932–937.  
[http://www.ncbi.nlm.nih.gov/entrez/query.fcgi?cmd=Retrieve&db=PubMed&list\\_uids=2016804&dopt=Abstract](http://www.ncbi.nlm.nih.gov/entrez/query.fcgi?cmd=Retrieve&db=PubMed&list_uids=2016804&dopt=Abstract)
54. Armenakas NA, Duckett CP, McAninch JW. Indications for nonoperative management of renal stab wounds. *J Urol* 1999;161(3):768–771.  
[http://www.ncbi.nlm.nih.gov/entrez/query.fcgi?cmd=Retrieve&db=PubMed&list\\_uids=10022681&dopt=Abstract](http://www.ncbi.nlm.nih.gov/entrez/query.fcgi?cmd=Retrieve&db=PubMed&list_uids=10022681&dopt=Abstract)
55. Altman AL, Haas C, Dinchman KH, Spirnak JP. Selective nonoperative management of blunt grade 5 renal injury. *J Urol* 2000;164(1):27–30; discussion 30–31.  
[http://www.ncbi.nlm.nih.gov/entrez/query.fcgi?cmd=Retrieve&db=PubMed&list\\_uids=10840417&dopt=Abstract](http://www.ncbi.nlm.nih.gov/entrez/query.fcgi?cmd=Retrieve&db=PubMed&list_uids=10840417&dopt=Abstract)
56. Matthews LA, Smith EM, Spirnak JP. Nonoperative treatment of major blunt renal lacerations with urinary extravasation. *J Urol* 1997;157(6):2056–2058.  
[http://www.ncbi.nlm.nih.gov/entrez/query.fcgi?cmd=Retrieve&db=PubMed&list\\_uids=9146579&dopt=Abstract](http://www.ncbi.nlm.nih.gov/entrez/query.fcgi?cmd=Retrieve&db=PubMed&list_uids=9146579&dopt=Abstract)
57. Moudouni SM, Hadj Slimen M, Manunta A, Patard J, Guiraud PH, Guille F, Bouchot O, Lobel B. Management of major blunt renal lacerations: is a non-operative approach indicated? *Eur Urol* 2001;40(4):409–414.  
[http://www.ncbi.nlm.nih.gov/entrez/query.fcgi?cmd=Retrieve&db=PubMed&list\\_uids=11713395&dopt=Abstract](http://www.ncbi.nlm.nih.gov/entrez/query.fcgi?cmd=Retrieve&db=PubMed&list_uids=11713395&dopt=Abstract)
58. Husmann DA, Morris JS. Attempted nonoperative management of blunt renal lacerations extending through the corticomedullary junction: the short-term and long-term sequelae. *J Urol* 1990;143(4):682–684.  
[http://www.ncbi.nlm.nih.gov/entrez/query.fcgi?cmd=Retrieve&db=PubMed&list\\_uids=2313792&dopt=Abstract](http://www.ncbi.nlm.nih.gov/entrez/query.fcgi?cmd=Retrieve&db=PubMed&list_uids=2313792&dopt=Abstract)
59. Rogers CG, Knight V, MacUra KJ, Ziegfeld S, Paidas CN, Mathews RI. High-grade renal injuries in children—is conservative management possible? *Urology* 2004;64(3):574–9.  
[http://www.ncbi.nlm.nih.gov/entrez/query.fcgi?cmd=Retrieve&db=pubmed&dopt=Abstract&list\\_uids=15351596&query\\_hl=13&itool=pubmed\\_docsum](http://www.ncbi.nlm.nih.gov/entrez/query.fcgi?cmd=Retrieve&db=pubmed&dopt=Abstract&list_uids=15351596&query_hl=13&itool=pubmed_docsum)
60. Hammer CC, Santucci RA. Effect of an institutional policy of nonoperative treatment of grades I to IV renal injuries. *J Urol* 2003;169(5):1751–1753.  
[http://www.ncbi.nlm.nih.gov/entrez/query.fcgi?cmd=Retrieve&db=pubmed&dopt=Abstract&list\\_uids=12686825&query\\_hl=15&itool=pubmed\\_docsum](http://www.ncbi.nlm.nih.gov/entrez/query.fcgi?cmd=Retrieve&db=pubmed&dopt=Abstract&list_uids=12686825&query_hl=15&itool=pubmed_docsum)
61. Robert M, Drianno N, Muir G, Delbos O, Guiter J. Management of major blunt renal lacerations: surgical or non-operative approach? *Eur Urol* 1996;30(3):335–339.  
[http://www.ncbi.nlm.nih.gov/entrez/query.fcgi?cmd=Retrieve&db=PubMed&list\\_uids=8931966&dopt=Abstract](http://www.ncbi.nlm.nih.gov/entrez/query.fcgi?cmd=Retrieve&db=PubMed&list_uids=8931966&dopt=Abstract)
62. Nash PA, Bruce JE, McAninch JW. Nephrectomy for traumatic renal injuries. *J Urol* 1995;153(3 Pt 1):609–611.  
[http://www.ncbi.nlm.nih.gov/entrez/query.fcgi?cmd=Retrieve&db=PubMed&list\\_uids=7861494&dopt=Abstract](http://www.ncbi.nlm.nih.gov/entrez/query.fcgi?cmd=Retrieve&db=PubMed&list_uids=7861494&dopt=Abstract)
63. Gonzalez RP, Falimirski M, Holevar MR, Evankovich C. Surgical management of renal trauma: is vascular control necessary? *J Trauma* 1999;47(6):1039–1042; discussion 1042–1044.  
[http://www.ncbi.nlm.nih.gov/entrez/query.fcgi?cmd=Retrieve&db=PubMed&list\\_uids=10608530&dopt=Abstract](http://www.ncbi.nlm.nih.gov/entrez/query.fcgi?cmd=Retrieve&db=PubMed&list_uids=10608530&dopt=Abstract)
64. Atala A, Miller FB, Richardson JD, Bauer B, Harty J, Amin M. Preliminary vascular control for renal trauma. *Surg Gynecol Obstet* 1991;172(5):386–390.  
[http://www.ncbi.nlm.nih.gov/entrez/query.fcgi?cmd=Retrieve&db=PubMed&list\\_uids=2028374&dopt=Abstract](http://www.ncbi.nlm.nih.gov/entrez/query.fcgi?cmd=Retrieve&db=PubMed&list_uids=2028374&dopt=Abstract)
65. DiGiacomo JC, Rotondo MF, Kauder DR, Schwab CW. The role of nephrectomy in the acutely injured. *Arch Surg* 2001;136(9):1045–1049.  
[http://www.ncbi.nlm.nih.gov/entrez/query.fcgi?cmd=Retrieve&db=PubMed&list\\_uids=11529828&dopt=Abstract](http://www.ncbi.nlm.nih.gov/entrez/query.fcgi?cmd=Retrieve&db=PubMed&list_uids=11529828&dopt=Abstract)

66. McAninch JW, Dixon CM, Carroll PR. [The surgical treatment of renal trauma.] *Vestn Khir Im I I Grek* 1990;145(11):64–72. [Russian]  
[http://www.ncbi.nlm.nih.gov/entrez/query.fcgi?cmd=Retrieve&db=PubMed&list\\_uids=1966179&dopt=Abstract](http://www.ncbi.nlm.nih.gov/entrez/query.fcgi?cmd=Retrieve&db=PubMed&list_uids=1966179&dopt=Abstract)
67. Shekarriz B, Stoller ML. The use of fibrin sealant in urology. *J Urol* 2002;167(3):1218–1225.  
[http://www.ncbi.nlm.nih.gov/entrez/query.fcgi?cmd=Retrieve&db=PubMed&list\\_uids=11832701&dopt=Abstract](http://www.ncbi.nlm.nih.gov/entrez/query.fcgi?cmd=Retrieve&db=PubMed&list_uids=11832701&dopt=Abstract)
68. Richter F, Schnorr D, Deger S, Trk I, Roigas J, Wille A, Loening SA. Improvement of hemostasis in open and laparoscopically performed partial nephrectomy using a gelatin matrix-thrombin tissue sealant (FloSeal). *Urology* 2003;61(1):73–7  
[http://www.ncbi.nlm.nih.gov/entrez/query.fcgi?cmd=Retrieve&db=pubmed&dopt=Abstract&list\\_uids=12559270&query\\_hl=19&itool=pubmed\\_docsum](http://www.ncbi.nlm.nih.gov/entrez/query.fcgi?cmd=Retrieve&db=pubmed&dopt=Abstract&list_uids=12559270&query_hl=19&itool=pubmed_docsum)
69. Knudson MM, Harrison PB, Hoyt DB, Shatz DV, Zietlow SP, Bergstein JM, Mario LA, McAninch JW. Outcome after major renovascular injuries: a Western trauma association multicenter report. *J Trauma* 2000;49(6):1116–1122.  
[http://www.ncbi.nlm.nih.gov/entrez/query.fcgi?cmd=Retrieve&db=PubMed&list\\_uids=11130498&dopt=Abstract](http://www.ncbi.nlm.nih.gov/entrez/query.fcgi?cmd=Retrieve&db=PubMed&list_uids=11130498&dopt=Abstract)
70. Tillou A, Romero J, Asensio JA, Best CD, Petrone P, Roldan G, Rojo E. Renal vascular injuries. *Surg Clin North Am* 2001;81(6):1417–1430.  
[http://www.ncbi.nlm.nih.gov/entrez/query.fcgi?cmd=Retrieve&db=PubMed&list\\_uids=9894257&dopt=Abstract](http://www.ncbi.nlm.nih.gov/entrez/query.fcgi?cmd=Retrieve&db=PubMed&list_uids=9894257&dopt=Abstract)
71. el Khader K, Bouchot O, Mhidia A, Guille F, Lobel B, Buzelin JM. [Injuries of the renal pedicle: is renal revascularization justified?] *Prog Urol* 1998;8(6):995–1000. [French]  
[http://www.ncbi.nlm.nih.gov/entrez/query.fcgi?cmd=Retrieve&db=PubMed&list\\_uids=9894257&dopt=Abstract](http://www.ncbi.nlm.nih.gov/entrez/query.fcgi?cmd=Retrieve&db=PubMed&list_uids=9894257&dopt=Abstract)
72. Hagiwara A, Sakaki S, Goto H, Takenega K, Fukushima H, Matuda H, Shimazaki S. The role of interventional radiology in the management of blunt renal injury: a practical protocol. *J Trauma* 2001;51(3):526–531.  
[http://www.ncbi.nlm.nih.gov/entrez/query.fcgi?cmd=Retrieve&db=PubMed&list\\_uids=11535904&dopt=Abstract](http://www.ncbi.nlm.nih.gov/entrez/query.fcgi?cmd=Retrieve&db=PubMed&list_uids=11535904&dopt=Abstract)
73. Velmahos GC, Chahwan S, Falabella A, Hanks SE, Demetriades D. Angiographic embolization for intraperitoneal and retroperitoneal injuries. *World J Surg* 2000;24(5):539–545.  
[http://www.ncbi.nlm.nih.gov/entrez/query.fcgi?cmd=Retrieve&db=PubMed&list\\_uids=10787073&dopt=Abstract](http://www.ncbi.nlm.nih.gov/entrez/query.fcgi?cmd=Retrieve&db=PubMed&list_uids=10787073&dopt=Abstract)
74. Sofocleous CT, Hinrichs C, Hubbi B, Brountzos E, Kaul S, Kannarkat G, Bahramipour P, Barone A, Contractor DG, Shah T. Angiographic findings and embolotherapy in renal arterial trauma. *Cardiovasc Intervent Radiol* 2005;28:39–47.
75. Schmidlin FR, Rohner S, Hadaya K, Iselin CE, Vermeulen B, Khan H, Farshad M, Niederer P, Graber P. [The conservative treatment of major kidney injuries.] *Ann Urol* 1997;31(5):246–252. [French]  
[http://www.ncbi.nlm.nih.gov/entrez/query.fcgi?cmd=Retrieve&db=PubMed&list\\_uids=9480627&dopt=Abstract](http://www.ncbi.nlm.nih.gov/entrez/query.fcgi?cmd=Retrieve&db=PubMed&list_uids=9480627&dopt=Abstract)
76. el Khader K, Mhidia A, Ziade J, Patard JJ, Guille F, Lobel B. [Conservative treatment of stage III kidney injuries.] *Acta Urol Belg* 1998;66(4):25–28. [French]  
[http://www.ncbi.nlm.nih.gov/entrez/query.fcgi?cmd=Retrieve&db=PubMed&list\\_uids=10083630&dopt=Abstract](http://www.ncbi.nlm.nih.gov/entrez/query.fcgi?cmd=Retrieve&db=PubMed&list_uids=10083630&dopt=Abstract)
77. Thall EH, Stone NN, Cheng DL, Cohen EL., Fine EM, Leventhal I, Aldoroty RA. Conservative management of penetrating and blunt Type III renal injuries. *Br J Urol* 1996;77(4):512–517.  
[http://www.ncbi.nlm.nih.gov/entrez/query.fcgi?cmd=Retrieve&db=PubMed&list\\_uids=8777609&dopt=Abstract](http://www.ncbi.nlm.nih.gov/entrez/query.fcgi?cmd=Retrieve&db=PubMed&list_uids=8777609&dopt=Abstract)
78. Cheng DL, Lazan D, Stone N. Conservative treatment of type III renal trauma. *J Trauma* 1994;36(4):491–494.  
[http://www.ncbi.nlm.nih.gov/entrez/query.fcgi?cmd=Retrieve&db=PubMed&list\\_uids=8158708&dopt=Abstract](http://www.ncbi.nlm.nih.gov/entrez/query.fcgi?cmd=Retrieve&db=PubMed&list_uids=8158708&dopt=Abstract)
79. Santucci RA, McAninch JW. Grade IV renal injuries: evaluation, treatment, and outcome. *World J Surg* 2001;25(12):1565–1572.  
[http://www.ncbi.nlm.nih.gov/entrez/query.fcgi?cmd=Retrieve&db=PubMed&list\\_uids=11775193&dopt=Abstract](http://www.ncbi.nlm.nih.gov/entrez/query.fcgi?cmd=Retrieve&db=PubMed&list_uids=11775193&dopt=Abstract)
80. Serafetinides E, Mitropoulos D, Constantinedes C. et al. Management of renal gunshot injuries (RGI). *J Urol* 2004;171:20.

81. Velmahos GC, Demetriades D, Cornwell EE 3rd, Belzberg H, Belzberg H, Murray J, Asensio J, Berne TV. Selective management of renal gunshot wounds. *Br J Surg* 1998;85(8):1121–1124.  
[http://www.ncbi.nlm.nih.gov/entrez/query.fcgi?cmd=Retrieve&db=PubMed&list\\_uids=9718011&dopt=Abstract](http://www.ncbi.nlm.nih.gov/entrez/query.fcgi?cmd=Retrieve&db=PubMed&list_uids=9718011&dopt=Abstract)
82. Baniel J, Schein M. The management of penetrating trauma to the urinary tract. *J Am Coll Surg* 1994;178(4):417–425.  
[http://www.ncbi.nlm.nih.gov/entrez/query.fcgi?cmd=Retrieve&db=PubMed&list\\_uids=8149045&dopt=Abstract](http://www.ncbi.nlm.nih.gov/entrez/query.fcgi?cmd=Retrieve&db=PubMed&list_uids=8149045&dopt=Abstract)
83. Bernath AS, Schutte H, Fernandez RR, Addonizio JC. Stab wounds of the kidney: conservative management in flank penetration. *J Urol* 1983;129(3):468–470.  
[http://www.ncbi.nlm.nih.gov/entrez/query.fcgi?cmd=Retrieve&db=PubMed&list\\_uids=6834529&dopt=Abstract](http://www.ncbi.nlm.nih.gov/entrez/query.fcgi?cmd=Retrieve&db=PubMed&list_uids=6834529&dopt=Abstract)
84. Wessells H, McAninch JW, Meyer A, Bruce J. Criteria for nonoperative treatment of significant penetrating renal lacerations. *J Urol* 1997;157(1):24–27.  
[http://www.ncbi.nlm.nih.gov/entrez/query.fcgi?cmd=Retrieve&db=PubMed&list\\_uids=8976207&dopt=Abstract](http://www.ncbi.nlm.nih.gov/entrez/query.fcgi?cmd=Retrieve&db=PubMed&list_uids=8976207&dopt=Abstract)
85. Blankenship JC, Gavant ML, Cox CE, Chauhan RD, Gingrich JR. Importance of delayed imaging for blunt renal trauma. *World J Surg* 2001;25(12):1561–1564.  
[http://www.ncbi.nlm.nih.gov/entrez/query.fcgi?cmd=Retrieve&db=PubMed&list\\_uids=11775192&dopt=Abstract](http://www.ncbi.nlm.nih.gov/entrez/query.fcgi?cmd=Retrieve&db=PubMed&list_uids=11775192&dopt=Abstract)
86. Wessells H, Deirmenjian J, McAninch JW. Preservation of renal function after reconstruction for trauma: quantitative assessment with radionuclide scintigraphy. *J Urol* 1997;157(5):1583–1586.  
[http://www.ncbi.nlm.nih.gov/entrez/query.fcgi?cmd=Retrieve&db=PubMed&list\\_uids=9112481&dopt=Abstract](http://www.ncbi.nlm.nih.gov/entrez/query.fcgi?cmd=Retrieve&db=PubMed&list_uids=9112481&dopt=Abstract)
87. Pruthi RS, Issa MM, Kabalin JN, Terris MK. Renal masses presenting 25 and 50 years following blunt renal trauma. *Urol Int* 1998;61(1):43–46.  
[http://www.ncbi.nlm.nih.gov/entrez/query.fcgi?cmd=Retrieve&db=PubMed&list\\_uids=9792983&dopt=Abstract](http://www.ncbi.nlm.nih.gov/entrez/query.fcgi?cmd=Retrieve&db=PubMed&list_uids=9792983&dopt=Abstract)
88. Heyns CF, van Vollenhoven P. Increasing role of angiography and segmental artery embolization in the management of renal stab wounds. *J Urol* 1992;147(5):1231–1234.  
[http://www.ncbi.nlm.nih.gov/entrez/query.fcgi?cmd=Retrieve&db=PubMed&list\\_uids=1569655&dopt=Abstract](http://www.ncbi.nlm.nih.gov/entrez/query.fcgi?cmd=Retrieve&db=PubMed&list_uids=1569655&dopt=Abstract)
89. Montgomery RC, Richardson JD, Harty JI. Posttraumatic renovascular hypertension after occult renal injury. *J Trauma* 1998;45(1):106–110.  
[http://www.ncbi.nlm.nih.gov/entrez/query.fcgi?cmd=Retrieve&db=PubMed&list\\_uids=9680021&dopt=Abstract](http://www.ncbi.nlm.nih.gov/entrez/query.fcgi?cmd=Retrieve&db=PubMed&list_uids=9680021&dopt=Abstract)
90. Lebech A, Strange-Vognsen HH. [Hypertension following blunt kidney injury.] *Ugeskr Laeger* 1990;152(14):994–997. [Danish]  
[http://www.ncbi.nlm.nih.gov/entrez/query.fcgi?cmd=Retrieve&db=PubMed&list\\_uids=2183457&dopt=Abstract](http://www.ncbi.nlm.nih.gov/entrez/query.fcgi?cmd=Retrieve&db=PubMed&list_uids=2183457&dopt=Abstract)
91. Monstrey SJ, Beerhuizen GI, vander Werken C, Debryne FM, Goris RJ. Renal trauma and hypertension. *J Trauma* 1989;29(1):65–70.  
[http://www.ncbi.nlm.nih.gov/entrez/query.fcgi?cmd=Retrieve&db=PubMed&list\\_uids=2911106&dopt=Abstract](http://www.ncbi.nlm.nih.gov/entrez/query.fcgi?cmd=Retrieve&db=PubMed&list_uids=2911106&dopt=Abstract)
92. Haas CA, Reigle MD, Selzman AA, Elder JS, Spirnak JP. Use of ureteral stents in the management of major renal trauma with urinary extravasation: is there a role? *J Endourol* 1998;12(6):545–549.  
[http://www.ncbi.nlm.nih.gov/entrez/query.fcgi?cmd=Retrieve&db=PubMed&list\\_uids=9895260&dopt=Abstract](http://www.ncbi.nlm.nih.gov/entrez/query.fcgi?cmd=Retrieve&db=PubMed&list_uids=9895260&dopt=Abstract)
93. Wang KT, Hou CJ, Hsieh JJ, Chou YS, Tsai CH. Late development of renal arteriovenous fistula following gunshot trauma — a case report. *Angiology* 1998;49(5):415–418.  
[http://www.ncbi.nlm.nih.gov/entrez/query.fcgi?cmd=Retrieve&db=PubMed&list\\_uids=9591535&dopt=Abstract](http://www.ncbi.nlm.nih.gov/entrez/query.fcgi?cmd=Retrieve&db=PubMed&list_uids=9591535&dopt=Abstract)
94. Franco de Castro A, Gibanel Garanto R, Real MI, Rodriguez Casado A, Cetina Herrando A, Gutierrez del Pozo R, Montanya X, Vazquez F, Alcover Garcia JB. [Selective embolization of post-traumatic renal pseudoaneurysm in monorenal patient.] *Actas Urol Esp* 2001;25(1):64–66. [Spanish]  
[http://www.ncbi.nlm.nih.gov/entrez/query.fcgi?cmd=Retrieve&db=PubMed&list\\_uids=11284371&dopt=Abstract](http://www.ncbi.nlm.nih.gov/entrez/query.fcgi?cmd=Retrieve&db=PubMed&list_uids=11284371&dopt=Abstract)
95. Miller DC, Forauer A, Faerber GJ. Successful angioembolization of renal artery pseudoaneurysms after blunt abdominal trauma. *Urology* 2002;59(3):444.  
[http://www.ncbi.nlm.nih.gov/entrez/query.fcgi?cmd=Retrieve&db=PubMed&list\\_uids=11880095&dopt=Abstract](http://www.ncbi.nlm.nih.gov/entrez/query.fcgi?cmd=Retrieve&db=PubMed&list_uids=11880095&dopt=Abstract)

96. Harrington TG, Kandel LB. Renal colic following a gunshot wound to the abdomen: the birdshot calculus. *J Urol* 1997;157(4):1351–1352.  
[http://www.ncbi.nlm.nih.gov/entrez/query.fcgi?cmd=Retrieve&db=PubMed&list\\_uids=9120940&dopt=Abstract](http://www.ncbi.nlm.nih.gov/entrez/query.fcgi?cmd=Retrieve&db=PubMed&list_uids=9120940&dopt=Abstract)
97. Park JK, Yang SO, Park SC. Duodenal obstruction by retroperitoneal haematoma induced by severe blunt renal trauma. *J Urol* 2001;165(6 Pt 1):1993–1994.  
[http://www.ncbi.nlm.nih.gov/entrez/query.fcgi?cmd=Retrieve&db=PubMed&list\\_uids=11371904&dopt=Abstract](http://www.ncbi.nlm.nih.gov/entrez/query.fcgi?cmd=Retrieve&db=PubMed&list_uids=11371904&dopt=Abstract)
98. Peclet MH, Newman KD, Eichelberger MR, Gotschall CS, Garcia VF, Bowman LM. Thoracic trauma in children: an indicator of increased mortality. *J Pediatr Surg* 1990;25(9):961–965; discussion 965–966.  
[http://www.ncbi.nlm.nih.gov/entrez/query.fcgi?cmd=Retrieve&db=PubMed&list\\_uids=2213448&dopt=Abstract](http://www.ncbi.nlm.nih.gov/entrez/query.fcgi?cmd=Retrieve&db=PubMed&list_uids=2213448&dopt=Abstract)
99. Morse TS. Renal injuries. *Pediatr Clin North Am* 1975;22(2):379–391.  
[http://www.ncbi.nlm.nih.gov/entrez/query.fcgi?cmd=Retrieve&db=PubMed&list\\_uids=1124221&dopt=Abstract](http://www.ncbi.nlm.nih.gov/entrez/query.fcgi?cmd=Retrieve&db=PubMed&list_uids=1124221&dopt=Abstract)
100. McAleer IM, Kaplan GW, Scherz HC, Packer MG, Lynch FP. Genitourinary trauma in the paediatric patient. *Urology* 1993;42(5):563–567; discussion 567–568.  
[http://www.ncbi.nlm.nih.gov/entrez/query.fcgi?cmd=Retrieve&db=PubMed&list\\_uids=8236601&dopt=Abstract](http://www.ncbi.nlm.nih.gov/entrez/query.fcgi?cmd=Retrieve&db=PubMed&list_uids=8236601&dopt=Abstract)
101. Elshihabi I, Elshihabi S, Arar M. An overview of renal trauma. *Curr Opin Pediatr* 1998;10(2):162–166.  
[http://www.ncbi.nlm.nih.gov/entrez/query.fcgi?cmd=Retrieve&db=PubMed&list\\_uids=9608894&dopt=Abstract](http://www.ncbi.nlm.nih.gov/entrez/query.fcgi?cmd=Retrieve&db=PubMed&list_uids=9608894&dopt=Abstract)
102. Brown SL, Elder JS, Spirnak JP. Are pediatric patients more susceptible to major renal injury from blunt trauma? A comparative study. *J Urol* 1998;160(1):138–140.  
[http://www.ncbi.nlm.nih.gov/entrez/query.fcgi?cmd=Retrieve&db=PubMed&list\\_uids=9628634&dopt=Abstract](http://www.ncbi.nlm.nih.gov/entrez/query.fcgi?cmd=Retrieve&db=PubMed&list_uids=9628634&dopt=Abstract)
103. Chopra P, St-Vil D, Yazbeck S. Blunt renal trauma — blessing in disguise? *J Pediatr Surg* 2002;37(5):779–782.  
[http://www.ncbi.nlm.nih.gov/entrez/query.fcgi?cmd=Retrieve&db=PubMed&list\\_uids=11987100&dopt=Abstract](http://www.ncbi.nlm.nih.gov/entrez/query.fcgi?cmd=Retrieve&db=PubMed&list_uids=11987100&dopt=Abstract)
104. Quinlan DM, Gearhart JP. Blunt renal trauma in childhood. Features indicating severe injury. *Br J Urol* 1990;66(5):526–531.  
[http://www.ncbi.nlm.nih.gov/entrez/query.fcgi?cmd=Retrieve&db=PubMed&list\\_uids=2249124&dopt=Abstract](http://www.ncbi.nlm.nih.gov/entrez/query.fcgi?cmd=Retrieve&db=PubMed&list_uids=2249124&dopt=Abstract)
105. Angus LD, Tachmes L, Kahn S, Gulmi F, Gintautas J, Shaftan GW. Surgical management of paediatric renal trauma: an urban experience. *Am Surg* 1993;59(6):388–394.  
[http://www.ncbi.nlm.nih.gov/entrez/query.fcgi?cmd=Retrieve&db=PubMed&list\\_uids=8507066&dopt=Abstract](http://www.ncbi.nlm.nih.gov/entrez/query.fcgi?cmd=Retrieve&db=PubMed&list_uids=8507066&dopt=Abstract)
106. Nguyen MM, Das S. Pediatric renal trauma. *Urology* 2002;59:762–766; discussion 766–767.  
[http://www.ncbi.nlm.nih.gov/entrez/query.fcgi?cmd=Retrieve&db=PubMed&list\\_uids=11992916&dopt=Abstract](http://www.ncbi.nlm.nih.gov/entrez/query.fcgi?cmd=Retrieve&db=PubMed&list_uids=11992916&dopt=Abstract)
107. Stalker HP, Kaufman RA, Stedje K. The significance of hematuria in children after blunt abdominal trauma. *AJR Am J Roentgenol* 1990;154(3):569–571.  
[http://www.ncbi.nlm.nih.gov/entrez/query.fcgi?cmd=Retrieve&db=PubMed&list\\_uids=2106223&dopt=Abstract](http://www.ncbi.nlm.nih.gov/entrez/query.fcgi?cmd=Retrieve&db=PubMed&list_uids=2106223&dopt=Abstract)
108. Stein JP, Kaji DM, Eastham J, Freeman JA, Esrig D, Hardy BE. Blunt renal trauma in the pediatric population: indications for radiographic evaluation. *Urology* 1994;44(3):406–410.  
[http://www.ncbi.nlm.nih.gov/entrez/query.fcgi?cmd=Retrieve&db=PubMed&list\\_uids=8073555&dopt=Abstract](http://www.ncbi.nlm.nih.gov/entrez/query.fcgi?cmd=Retrieve&db=PubMed&list_uids=8073555&dopt=Abstract)
109. Morey AF, Bruce JE, McAninch JW. Efficacy of radiographic imaging in pediatric blunt renal trauma. *J Urol* 1996;156(6):2014–2018.  
[http://www.ncbi.nlm.nih.gov/entrez/query.fcgi?cmd=Retrieve&db=PubMed&list\\_uids=8911380&dopt=Abstract](http://www.ncbi.nlm.nih.gov/entrez/query.fcgi?cmd=Retrieve&db=PubMed&list_uids=8911380&dopt=Abstract)
110. Santucci RA, Langenburg SE, Zachareas MJ. Traumatic hematuria in children can be evaluated as in adults. *J Urol* 2004;171(2 Pt 1):822–825.  
[http://www.ncbi.nlm.nih.gov/entrez/query.fcgi?cmd=Retrieve&db=pubmed&dopt=Abstract&list\\_uids=14713834&query\\_hl=14&itool=pubmed\\_docsum](http://www.ncbi.nlm.nih.gov/entrez/query.fcgi?cmd=Retrieve&db=pubmed&dopt=Abstract&list_uids=14713834&query_hl=14&itool=pubmed_docsum)



111. Luks FI, Lemire A, St-Vil D, Di Lorenzo M, Filiatrault D, Ouimet A. Blunt abdominal trauma in children: the practical value of ultrasonography. *J Trauma* 1993;34(5):607–610; discussion 610–611.  
[http://www.ncbi.nlm.nih.gov/entrez/query.fcgi?cmd=Retrieve&db=PubMed&list\\_uids=8496996&dopt=Abstract](http://www.ncbi.nlm.nih.gov/entrez/query.fcgi?cmd=Retrieve&db=PubMed&list_uids=8496996&dopt=Abstract)
112. Wessel LM, Jester I, Scholz S, Arnold R, Lorenz C, Wirth H, Waag KL. [Diagnostic and therapeutic consequences of kidney injuries in pediatric blunt abdominal trauma]. *Urologe A* 2000;39(5):425–431. [German]  
[http://www.ncbi.nlm.nih.gov/entrez/query.fcgi?cmd=Retrieve&db=PubMed&list\\_uids=11045043&dopt=Abstract](http://www.ncbi.nlm.nih.gov/entrez/query.fcgi?cmd=Retrieve&db=PubMed&list_uids=11045043&dopt=Abstract)
113. Perez-Brayfield MR, Gatti JM, Smith EA, Broecker B, Massad C, Scherz H, Kirsch AJ. Blunt traumatic haematuria in children. Is a simplified algorithm justified? *J Urol* 2002;167(6):2543–2546; discussion 2546–2547.  
[http://www.ncbi.nlm.nih.gov/entrez/query.fcgi?cmd=Retrieve&db=PubMed&list\\_uids=11992085&dopt=Abstract](http://www.ncbi.nlm.nih.gov/entrez/query.fcgi?cmd=Retrieve&db=PubMed&list_uids=11992085&dopt=Abstract)
114. Mayor B, Gudinchet F, Wicky S, Reinberg O, Schnyder P. Imaging evaluation of blunt renal trauma in children: diagnostic accuracy of intravenous pyelography and ultrasonography. *Pediatr Radiol* 1995;25(3):214–218.  
[http://www.ncbi.nlm.nih.gov/entrez/query.fcgi?cmd=Retrieve&db=PubMed&list\\_uids=7644308&dopt=Abstract](http://www.ncbi.nlm.nih.gov/entrez/query.fcgi?cmd=Retrieve&db=PubMed&list_uids=7644308&dopt=Abstract)
115. Turnock RR, Sprigg A, Lloyd DA. Computed tomography in the management of blunt abdominal trauma in children. *Br J Surg* 1993;80(8):982–984.  
[http://www.ncbi.nlm.nih.gov/entrez/query.fcgi?cmd=Retrieve&db=PubMed&list\\_uids=8402096&dopt=Abstract](http://www.ncbi.nlm.nih.gov/entrez/query.fcgi?cmd=Retrieve&db=PubMed&list_uids=8402096&dopt=Abstract)
116. Carpio F, Morey AF. Radiographic staging of renal injuries. *World J Urol* 1999;17(2):66–70.  
[http://www.ncbi.nlm.nih.gov/entrez/query.fcgi?cmd=Retrieve&db=PubMed&list\\_uids=10367363&dopt=Abstract](http://www.ncbi.nlm.nih.gov/entrez/query.fcgi?cmd=Retrieve&db=PubMed&list_uids=10367363&dopt=Abstract)
117. Takeda M, Katayama Y, Tsutsui T, Takahashi H, Komeyama T, Mizusawa T, Sato S. Value of dimercaptosuccinic acid single photon emission computed tomography and magnetic resonance imaging in detecting renal injury in pediatric patients with vesicoureteral reflux. Comparison with dimercaptosuccinic acid planar scintigraphy and intravenous pyelography. *Eur Urol* 1994;25(4):320–325.  
[http://www.ncbi.nlm.nih.gov/entrez/query.fcgi?cmd=Retrieve&db=PubMed&list\\_uids=8056025&dopt=Abstract](http://www.ncbi.nlm.nih.gov/entrez/query.fcgi?cmd=Retrieve&db=PubMed&list_uids=8056025&dopt=Abstract)
118. Levy JB, Baskin LS, Ewalt DH, Zderic SA. Nonoperative management of blunt pediatric major renal trauma. *Urology* 1993;42(4):418–424.  
[http://www.ncbi.nlm.nih.gov/entrez/query.fcgi?cmd=Retrieve&db=PubMed&list\\_uids=8212441&dopt=Abstract](http://www.ncbi.nlm.nih.gov/entrez/query.fcgi?cmd=Retrieve&db=PubMed&list_uids=8212441&dopt=Abstract)
119. Buckley JC, McAninch JW. Pediatric renal injuries: management guidelines from a 25-year experience. *J Urol* 2004;172(2):687–690.  
[http://www.ncbi.nlm.nih.gov/entrez/query.fcgi?cmd=Retrieve&db=pubmed&dopt=Abstract&list\\_uids=15247762&query\\_hl=20&itool=pubmed\\_docsum](http://www.ncbi.nlm.nih.gov/entrez/query.fcgi?cmd=Retrieve&db=pubmed&dopt=Abstract&list_uids=15247762&query_hl=20&itool=pubmed_docsum)
120. Baumann L, Greenfield SP, Aker J, Brody A, Karp M, Allen J, Cooney D. Nonoperative management of major blunt renal trauma in children: in-hospital morbidity and long-term followup. *J Urol* 1992;148 Pt 2):691–693.  
[http://www.ncbi.nlm.nih.gov/entrez/query.fcgi?cmd=Retrieve&db=PubMed&list\\_uids=1640547&dopt=Abstract](http://www.ncbi.nlm.nih.gov/entrez/query.fcgi?cmd=Retrieve&db=PubMed&list_uids=1640547&dopt=Abstract)
121. Moog R, Becmeur F, Dutson E, Chevalier-Kauffmann I, Sauvage P, Brunot B. Functional evaluation by quantitative dimercaptosuccinic Acid scintigraphy after kidney trauma in children. *J Urol* 2003;169(2):641–644.  
[http://www.ncbi.nlm.nih.gov/entrez/query.fcgi?cmd=Retrieve&db=pubmed&dopt=Abstract&list\\_uids=12544333&query\\_hl=24&itool=pubmed\\_docsum](http://www.ncbi.nlm.nih.gov/entrez/query.fcgi?cmd=Retrieve&db=pubmed&dopt=Abstract&list_uids=12544333&query_hl=24&itool=pubmed_docsum)
122. Nance ML, Lutz N, Carr MC, Canning DA, Stafford PW. Blunt renal injuries in children can be managed nonoperatively: outcome in a consecutive series of patients. *J Trauma* 2004;57(3):474–478.  
[http://www.ncbi.nlm.nih.gov/entrez/query.fcgi?cmd=Retrieve&db=pubmed&dopt=Abstract&list\\_uids=15454790&query\\_hl=26&itool=pubmed\\_docsum](http://www.ncbi.nlm.nih.gov/entrez/query.fcgi?cmd=Retrieve&db=pubmed&dopt=Abstract&list_uids=15454790&query_hl=26&itool=pubmed_docsum)
123. Abdalati H, Bulas DI, Sivit CJ, Majd M, Rushton HG, Eichelberger MR. Blunt renal trauma in children: healing of renal injuries and recommendations for imaging follow-up. *Pediatr Radiol* 1994;24(8):573–576.  
[http://www.ncbi.nlm.nih.gov/entrez/query.fcgi?cmd=Retrieve&db=PubMed&list\\_uids=7724279&dopt=Abstract](http://www.ncbi.nlm.nih.gov/entrez/query.fcgi?cmd=Retrieve&db=PubMed&list_uids=7724279&dopt=Abstract)

124. Surana R, Khan A, Fitzgerald RJ. Scarring following renal trauma in children. *Br J Urol* 1995;75(5):663–665.  
[http://www.ncbi.nlm.nih.gov/entrez/query.fcgi?cmd=Retrieve&db=PubMed&list\\_uids=7613804&dopt=Abstract](http://www.ncbi.nlm.nih.gov/entrez/query.fcgi?cmd=Retrieve&db=PubMed&list_uids=7613804&dopt=Abstract)
125. Carlton CE Jr, Scott R Jr, Goldman M. The management of penetrating injuries of the kidney. *J Trauma* 1968;8(6):1071–1083.  
[http://www.ncbi.nlm.nih.gov/entrez/query.fcgi?cmd=Retrieve&db=PubMed&list\\_uids=5722121&dopt=Abstract](http://www.ncbi.nlm.nih.gov/entrez/query.fcgi?cmd=Retrieve&db=PubMed&list_uids=5722121&dopt=Abstract)
126. Kansas BT, Eddy MJ, Mydlo JH, Uzzo RG. Incidence and management of penetrating renal trauma in patients with multiorgan injury: extended experience at an inner city trauma center. *J Urol* 2004;172(4 Pt 1):1355–1360.  
[http://www.ncbi.nlm.nih.gov/entrez/query.fcgi?cmd=Retrieve&db=pubmed&dopt=Abstract&list\\_uids=15371841&query\\_hl=28&itool=pubmed\\_docsum](http://www.ncbi.nlm.nih.gov/entrez/query.fcgi?cmd=Retrieve&db=pubmed&dopt=Abstract&list_uids=15371841&query_hl=28&itool=pubmed_docsum)
127. Rosen MA, McAninch JW. Management of combined renal and pancreatic trauma. *J Urol* 1994;152(1):22–25.  
[http://www.ncbi.nlm.nih.gov/entrez/query.fcgi?cmd=Retrieve&db=PubMed&list\\_uids=8201670&dopt=Abstract](http://www.ncbi.nlm.nih.gov/entrez/query.fcgi?cmd=Retrieve&db=PubMed&list_uids=8201670&dopt=Abstract)
128. Wessells H, McAninch JW. Effect of colon injury on the management of simultaneous renal trauma. *J Urol* 1996;155(6):1852–1856.  
[http://www.ncbi.nlm.nih.gov/entrez/query.fcgi?cmd=Retrieve&db=PubMed&list\\_uids=8618272&dopt=Abstract](http://www.ncbi.nlm.nih.gov/entrez/query.fcgi?cmd=Retrieve&db=PubMed&list_uids=8618272&dopt=Abstract)
129. Sartorelli KH, Frumiento C, Rogers FB, Osler TM. Nonoperative management of hepatic, splenic, and renal injuries in adults with multiple injuries. *J Trauma* 2000;49(1):56–61; discussion 61–62.  
[http://www.ncbi.nlm.nih.gov/entrez/query.fcgi?cmd=Retrieve&db=PubMed&list\\_uids=10912858&dopt=Abstract](http://www.ncbi.nlm.nih.gov/entrez/query.fcgi?cmd=Retrieve&db=PubMed&list_uids=10912858&dopt=Abstract)
130. Cass AS, Luxenberg M, Gleich P, Smith C. Deaths from urologic injury due to external trauma. *J Trauma* 1987;27(3):319–321.  
[http://www.ncbi.nlm.nih.gov/entrez/query.fcgi?cmd=Retrieve&db=pubmed&dopt=Abstract&list\\_uids=3560276&query\\_hl=30&itool=pubmed\\_docsum](http://www.ncbi.nlm.nih.gov/entrez/query.fcgi?cmd=Retrieve&db=pubmed&dopt=Abstract&list_uids=3560276&query_hl=30&itool=pubmed_docsum)

## 2. URETERAL TRAUMA

### 2.1 Introduction

The ureter is the sole conduit for urinary transport between the kidney and the bladder. Thus, any ureteral injury can threaten the function of the ipsilateral kidney. This small, mobile, worm-like, peristalsing, urothelial-lined tube runs inferiorly from the renal pelvis in the retroperitoneal space. It lies anterior to the muscles of the posterior abdominal wall and lateral to the vertebral column, before descending into the bony ring of the pelvis to enter the bladder. Any external injury to the flank or back and any calamity within the bony pelvis therefore places the ureter at risk. Perhaps because of its protected location, its small size and its mobility, trauma to the ureter is relatively rare and accounts for only 1% of all urinary tract trauma. Thus, there is a relatively small volume of published clinical experience upon which to base recommendations of management.

### 2.2 Aetiology

The largest and most contemporary review of ureteral trauma in the European literature is from Dobrowolski et al. in Poland (1). These authors retrospectively analyzed the records of patients with upper urinary tract injuries presenting to 61 urology departments between 1995 and 1999. They identified 452 ureteral injuries. Of these, 340 (75%) were iatrogenic, 81 (18%) were from blunt trauma, and 31 (7%) were from penetrating trauma. Of the 340 iatrogenic injuries, 247 (73%) were gynaecological in origin, 46 (14%) were general surgical and 47 (14%) were urological. It is therefore important to note that ureteral injury is much more likely to occur from activity within a hospital rather than from injuries sustained outside. Dobrowolski et al. estimate the frequency of ureteral injury during gynaecological pelvic surgical procedures to be 1.6 per 1000 (1). Of the total ureteral injuries identified, the injury was in the upper third in 60 cases (13%), in the middle third in 61 cases (13%), and in the lower third in 331 (74%). The median time to diagnosis was 3.3 h.

The most common diagnostic investigation was intravenous urography (IVU), which was used in 244 patients; retrograde ureteropyelography was used in 98 patients; and ureteral catheterization was used in 125. The diagnosis was also established at open surgery in 104 patients. This snapshot of ureteral trauma in a modern European setting is similar to that seen in the USA (2).

### 2.3 Diagnosis

#### 2.3.1 Clinical diagnosis

There are no classic clinical symptoms and signs associated with acute ureteral trauma caused by external injury (3). In view of this, the diagnosis must be one of suspicion. Ureteral trauma should be suspected in all cases of penetrating abdominal injury, especially gunshot wounds, and also in cases of blunt deceleration trauma, in which the kidney and renal pelvis can be torn away from the ureter. This deceleration injury is more likely to occur in children because of their hyperextensible vertebral column (4). Haematuria is also a poor indicator of injury, as it is present in only half of those with ureteral trauma (5).

It is possible for isolated ureteral injuries to be missed. Such patients tend to present with subsequent evidence of upper tract obstruction, urinary fistula formation and sepsis (6). After gynaecological pelvic surgery, any woman who complains of flank pain, develops vaginal leakage of urine or becomes septic should also be suspected of having injury to the ureter or bladder and should be investigated appropriately. At surgery, when the ureter is explored to exclude injury, the use of intravenous indigo carmine or methylene blue is to be recommended. This will help reveal the site of injury by leakage of blue-stained urine. This is especially important in partial tears.

#### 2.3.2 Radiological diagnosis

Ureteral injury may cause radiological signs of upper urinary tract obstruction but the sine qua non of ureteral injury is extravasation of radiological contrast material (3). This sign can be produced by the use of intravenous pyelography (IVP), giving 2 mg of contrast material per kilogram of body weight. However, because of the increasing use of computed tomography (CT) scanning in polytraumatized patients, the diagnosis is increasingly made with this modality.

If a high suspicion of ureteral injury exists and the CT scan is non-diagnostic, then a 'poor man's IVP' can be obtained by taking a plain kidney-ureter-bladder (KUB) film 30 minutes after intravenous injection of CT contrast medium. If this is also non-diagnostic and a suspicion of injury still exists, then retrograde pyelography should be undertaken as the gold standard investigation.

### 2.4 Classification

The American Association for the Surgery of Trauma has classified ureteral injuries as shown in Table 1 (7).

**Table 1: Classification of ureteral injury**

Grade	Description of injury
I	Haematoma only
II	Laceration < 50% of circumference
III	Laceration > 50% of circumference
IV	Complete tear < 2 cm of devascularization
V	Complete tear > 2 cm of devascularization

## 2.5 Management

### 2.5.1 Partial injuries

These can be defined as grade I to II lesions. Once recognized, they can be managed with ureteral stenting or by placement of a nephrostomy tube to divert urine (3). There is no prospective clinical trial comparing outcomes between these techniques. We believe that ureteral stenting is probably superior because a stent across the injury will allow secure drainage of the kidney, as well as providing canalization and stabilization of the injury. We believe that this will reduce the subsequent risk of stricture. The stent may be placed in an antegrade or retrograde fashion. In all cases, fluoroscopy and ureteropyelography with radio-opaque contrast should be used to guide stent placement.

The procedure should commence with the passage of a hydrophilic atraumatic guidewire across the damaged segment of ureter. Once across the site of the injury, an access catheter can be backloaded over the wire and passed across the injury. The hydrophilic wire can then be exchanged for a 0.038-inch wire, and the stent deployed. If this technique is utilized, a bladder catheter should be left in place for 2 days to limit stent reflux during voiding until mucosal healing has begun. The stent should be left in place for at least 3 weeks. The patient should have a follow-up dynamic renogram and IVP between 3 and 6 months, or sooner if lateralizing flank pain develops. If there is evidence of stricture, then this should be managed by endo-urological or open surgical techniques, as appropriate.

If a grade II or III injury is encountered during immediate surgical exploration of an iatrogenic injury, then primary closure of the ureteral ends over a stent may be recommended, with placement of an external, non suction drain adjacent to the injury.

### 2.5.2 Complete injuries

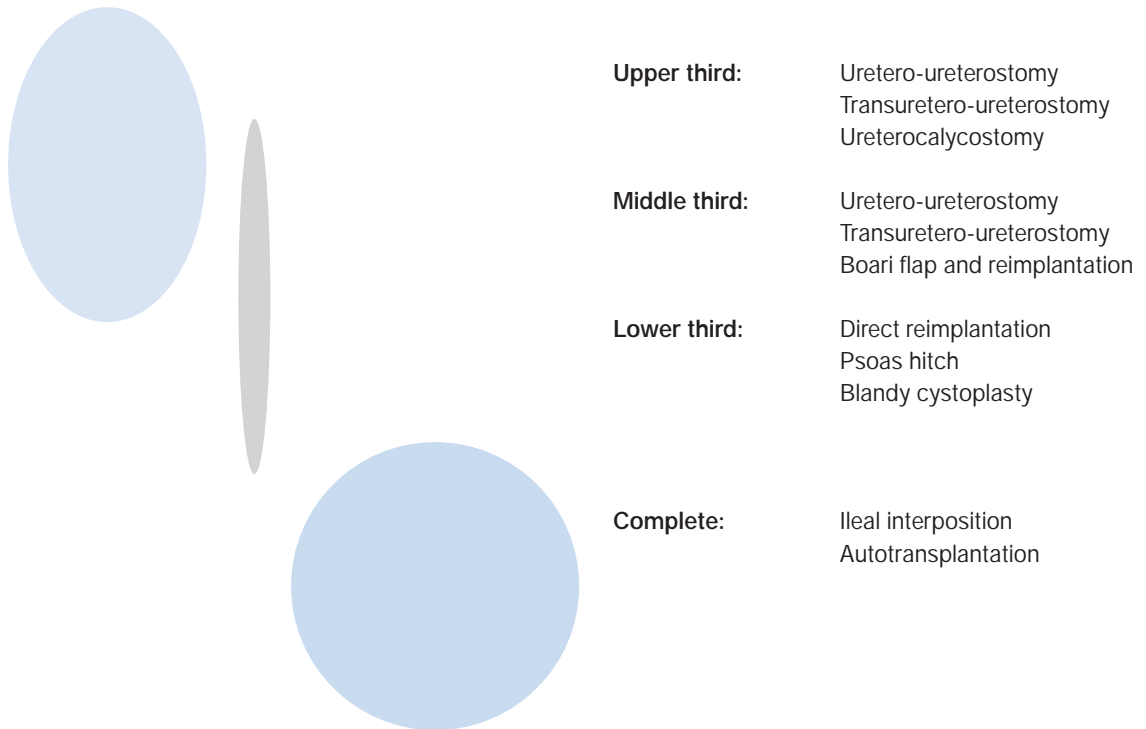
These are grade III to V injuries. Successful repair should utilize the principles outlined in Table 2.

**Table 2: Principles of repair of complete injury**

•	Debridement of ureteral ends to fresh tissue
•	Spatulation of ureteral ends
•	Placement of internal stent
•	Watertight closure of reconstructed ureter with absorbable suture
•	Placement of external, non-suction drain
•	Isolation of injury with peritoneum or omentum

The type of reconstructive repair procedure chosen by the surgeon depends on the nature and site of the injury (3). The options are depicted in Figure 1.

Figure 1: Diagram of the options for repair of complete injuries, based on the site of the injury



### 2.5.3 Sterile surgery

#### 2.5.3.1 Uretero-ureterostomy

Using the principles outlined above, the ureteral ends are debrided and freshened. The ends are spatulated. An internal JJ stent is inserted and the ends are closed over the stent using an interrupted 4/0 vicryl suture. An external, non-suction drain is placed at the site of the injury, and a catheter is left in the bladder. The bladder catheter can be removed after 2 days. The wound drain can be removed 2 days later if drainage is low. The stent should be removed after 6 weeks, and a follow-up renogram and IVP should be obtained after 3 months to assess the patency of the repair.

#### 2.5.3.2 Ureterocalycostomy

In cases where the pelvi-ureteral junction has been destroyed, the lower pole of the affected kidney can be amputated to expose the lower pole infundibulum and calyces. The distal ureteral end can then be debrided and spatulated, and anastomosed to the lower pole calyx, over an internal stent, using an interrupted 4/0 vicryl suture. An external, non-suction drain is placed at the site of the injury and a catheter is left in the bladder. The bladder catheter can be removed after 2 days. The wound drain can be removed 2 days later if drainage is low. The stent should be removed after 6 weeks and a follow-up renogram and IVP should be obtained after 3 months to assess the patency of the repair.

#### 2.5.3.3 Transuretero-ureterostomy

The distal end of the injured ureter is ligated with an absorbable suture. The proximal end is debrided and spatulated. This end is then transposed across the midline through a retroperitoneal window above the level of the inferior mesenteric artery. A 1.5 cm ureterotomy is made on the medial aspect of the contralateral ureter. A stent is placed from the ipsilateral kidney, through the anastomosis, and down the distal contralateral ureter into the bladder. A watertight anastomosis is fashioned using an interrupted 4/0 vicryl suture. An external, non-suction drain is placed at the site of the injury, and a catheter is left in the bladder. The bladder catheter can be removed after 2 days. The wound drain can be removed 2 days later if drainage is low. The stent should be removed after 6 weeks, and a follow-up renogram and IVP should be obtained after 3 months to assess the patency of the repair.

#### 2.5.3.4 Ureteroneocystostomy with Boari flap

The proximal ureteral end is debrided and spatulated. A traction suture is placed. The distal ureteral end is ligated with an absorbable suture. The bladder is filled with 200-300 ml of normal saline via a urethral catheter, and controlling stay sutures are placed on the bladder. The L-shaped flap is raised, its base being approximately four times wider than the width of the ureter to be implanted. The ureter is pulled through a

submucosal tunnel in the flap and secured to the bladder mucosa using an interrupted 4/0 vicryl suture. Anchoring sutures can be placed at the serosal aspect of the ureter to secure it to the bladder. A stent is placed across the neo-ureterocystostomy, and a suprapubic catheter is placed in the bladder. The bladder is then closed in two layers with 2/0 vicryl sutures. An external, non-suction drain should be placed at the site of the reimplant; it can be removed after 2 days. The urethral catheter can be removed at the same time. The suprapubic catheter can be removed after a cystogram at 2 weeks, and the stent can be removed after 6 weeks. An IVP and renogram should be obtained 3 months thereafter to confirm the patency of the neocystostomy.

#### *2.5.3.5 Ureterocystostomy and psoas hitch*

The proximal ureteral end is debrided and spatulated. A traction suture is placed. The distal ureteral end is ligated with an absorbable suture. The fundus of the bladder is mobilized, and the contralateral superior vesical pedicle may be divided to improve fundal mobility. The bladder is filled with 200-300 ml of normal saline via a urethral catheter, and controlling stay sutures are placed. A cystotomy (Blandy) is performed perpendicular to the line of the ureter. Two fingers are placed inside the bladder to stretch it gently towards the ipsilateral psoas tendon. Three non-absorbable 2/0 sutures are placed between the bladder wall and the tendon, with care being taken to avoid the genitofemoral nerve.

Ureteroneocystostomy is then undertaken using either the Leadbetter-Politano or Lich-Gregoire techniques. A JJ stent is placed across the reimplant, and a suprapubic catheter is placed in the bladder. The bladder is then closed in two layers with 2/0 vicryl in the line of the ureter, thus providing extra length to the hitch. The anastomosis is thus under no tension. An external, non-suction drain should be placed at the site of the reimplant, and can be removed after 2 days. The urethral catheter can be removed at the same time. The suprapubic catheter can be removed after a cystogram at 2 weeks, and the stent can be removed after 6 weeks. An IVP and renogram should be obtained 3 months thereafter to confirm the patency of the neocystostomy.

#### *2.5.3.6 Ileal interposition graft*

In cases of long segment ureteral destruction, the ureter can be totally replaced using the distal ileum. This should be avoided in patients with coincidental gastrointestinal disease, such as Crohn's disease, and in patients with impaired renal function. A 25-cm length of ileum is taken out of bowel continuity about 20 cm proximal to the ileocaecal valve. Gastrointestinal continuity is restored with an ileo-ileal anastomosis using interrupted 3/0 seromuscular vicryl. The mesenteric is repaired using 2/0 vicryl. The ileal segment is placed in the isoperistaltic orientation between the renal pelvis and the bladder. Ileo-pelvic and cysto-ileal end-to-end anastomoses are fashioned using 2/0 vicryl. A nephrostomy tube should be inserted into the ipsilateral kidney to decompress the affected upper tract. A catheter should be placed in the bladder. External, non-suction drains should cover the proximal and distal anastomoses. Lastly, the reconstruction should be wrapped in omentum.

The wound drains can be removed after 2 days. A nephrostogram should be performed after 3 weeks; if no leakage is demonstrated, the nephrostomy can be clamped and then removed. Finally, the urinary catheter can be removed. Follow-up should include IVP and renography at 3 months, together with testing for the levels of serum creatinine, chloride, bicarbonate and base excess, looking for evidence of hyperchloraemic metabolic acidosis.

#### *2.5.3.7 Autotransplantation*

If complete ureteral disruption should occur in the presence of coincidental gastrointestinal disease or impaired renal function, then autotransplantation of the affected renal unit can be undertaken. The renal artery and vein are divided long at the aorta and cava. The kidney is moved to the pelvis, and vascular continuity is restored using 5/0 prolene for the artery and 4/0 prolene for the vein. A Lich-Gregoire extravesical neo-ureterocystostomy can then be fashioned to re-establish urinary drainage. This need not be stented. A covering external, non-suction drain should be placed, and a catheter inserted in the bladder. The drain can be removed after 2 days, if dry, and the catheter removed after a cystogram at 2 weeks. Again, follow-up at 3 months with IVP and renogram is recommended.

#### *2.5.3.8 Nephrectomy*

There is one circumstance in which immediate nephrectomy should be undertaken. This is when ureteral injury complicates the repair of an abdominal aortic aneurysm or other vascular procedure in which a vascular prosthesis is to be implanted. We feel that immediate excision of the corrupted renal unit and its damaged ureter leads to less chance of urinary leak, urinoma, sepsis and graft infection.

## 2.6 REFERENCES

1. Dobrowolski Z, Kusionowicz J, Drewniak T, Habrat W, Lipczynski W, Jakubik P and Weglarz W. Renal and ureteric trauma: diagnosis and management in Poland. *BJU Int* 2002;89(7):748-751.  
[http://www.ncbi.nlm.nih.gov/entrez/query.fcgi?cmd=Retrieve&db=PubMed&list\\_uids=11966637&dopt=Abstract](http://www.ncbi.nlm.nih.gov/entrez/query.fcgi?cmd=Retrieve&db=PubMed&list_uids=11966637&dopt=Abstract)
2. Palmer LS, Rosenbaum RR, Gershbaum MD, Kreutzer ER. Penetrating ureteral trauma at an urban trauma center: 10-year experience. *Urology* 1999;54(1):34-36.  
[http://www.ncbi.nlm.nih.gov/entrez/query.fcgi?cmd=Retrieve&db=PubMed&list\\_uids=10414723&dopt=Abstract](http://www.ncbi.nlm.nih.gov/entrez/query.fcgi?cmd=Retrieve&db=PubMed&list_uids=10414723&dopt=Abstract)
3. Armenakas NA. Ureteral trauma: surgical repair. *Urol Clin North Am* 1998;6:71-84.
4. Morey AF, Bruce JE, McAninch JW. Efficacy of radiographic imaging in pediatric blunt renal trauma. *J Urol* 1996;156(6):2014-2018.  
[http://www.ncbi.nlm.nih.gov/entrez/query.fcgi?cmd=Retrieve&db=PubMed&list\\_uids=8911380&dopt=Abstract](http://www.ncbi.nlm.nih.gov/entrez/query.fcgi?cmd=Retrieve&db=PubMed&list_uids=8911380&dopt=Abstract)
5. Medina D, Lavery R, Ross SE, Livingston DH. Ureteral trauma: preoperative studies neither predict injury nor prevent missed injuries. *J Am Coll Surg* 1998;186(6):641-644.  
[http://www.ncbi.nlm.nih.gov/entrez/query.fcgi?cmd=Retrieve&db=PubMed&list\\_uids=9632150&dopt=Abstract](http://www.ncbi.nlm.nih.gov/entrez/query.fcgi?cmd=Retrieve&db=PubMed&list_uids=9632150&dopt=Abstract)
6. McGinty DM, Mendez R. Traumatic ureteral injuries with delayed recognition. *Urology* 1997;10(2):115-117.  
[http://www.ncbi.nlm.nih.gov/entrez/query.fcgi?cmd=Retrieve&db=PubMed&list\\_uids=898448&dopt=Abstract](http://www.ncbi.nlm.nih.gov/entrez/query.fcgi?cmd=Retrieve&db=PubMed&list_uids=898448&dopt=Abstract)
7. Moore EE, Cogbill TH, Jurkovitch GJ, McAninch JW, Champion HR, Gennarelli TA, Malangoni MA, Shackford SR, Trafton PG. Organ injury scaling. III: Chest wall, abdominal vascular, ureter, bladder, and urethra. *J Trauma* 1992;33(3):337-339.  
[http://www.ncbi.nlm.nih.gov/entrez/query.fcgi?cmd=Retrieve&db=PubMed&list\\_uids=1404499&dopt=Abstract](http://www.ncbi.nlm.nih.gov/entrez/query.fcgi?cmd=Retrieve&db=PubMed&list_uids=1404499&dopt=Abstract)

## 3. BLADDER TRAUMA

### 3.1 Background

Lower urinary tract injury may be caused by either blunt, penetrating, or iatrogenic trauma. About 10% of all trauma patients will manifest genitourinary tract involvement (1); among abdominal injuries that require surgical repair, 2% involve the bladder (2). Blunt trauma accounts for 67-86% of bladder ruptures, while penetrating trauma for 14-33% (3,4,5). The most common cause (90%) of bladder rupture by blunt trauma is motor vehicle accidents (6,7,8). Bladder rupture in the setting of blunt trauma may be classified as either extraperitoneal with leakage of urine limited to the perivesical space, or intraperitoneal, in which the peritoneal surface has been disrupted with concomitant urinary extravasation.

About 70-97% of patients with bladder injuries from blunt trauma have associated pelvic fractures (4,9,10). Pubic symphysis diastasis, sacroiliac diastasis, and sacral, iliac, and pubic rami fractures are significantly associated with bladder rupture, whereas isolated acetabular fractures are not (11,12). More than half of associated pelvic fractures are of the pubic ramus (13). Conversely, up to 30% of patients with pelvic fractures will have some degree of bladder injury (14). However, a major bladder injury occurs only in 5-10% of patients suffering from pelvic fracture(s) (15,16). More than 85% of patients with pelvic fractures have associated (mean of 2.9) injuries in multiple organ systems (9), with a mortality rate of 22-44% (13,14,17). Approximately 25% of intraperitoneal bladder ruptures occur in patients without pelvic fracture (16).

Traumatic forces may be transferred to the urinary bladder by the seatbelt and injuries usually occur in the patient with a full bladder. The degree of distension of the bladder with urine determines its shape and to some degree the injury it may sustain. An exceedingly light blow may rupture the fully distended bladder, but the empty bladder is seldom injured except by crushing or penetrating wounds. Pelvic scars or pre-existing pelvic pathology may modify the situation (18). Combined intra- and extraperitoneal rupture may be present in 2-20% of cases (8,19,20,21). Simultaneous bladder ruptures from external trauma occur in 10-29% of male patients with traumatic rupture of the prostatic-membranous urethra (11).

Several studies carried out in paediatric patient populations, investigating pelvic fractures and associated injuries, reported a lower incidence of urogenital injury ranging from 7.4% to 13.5% (22,23,24,25), in comparison to adult series (14,15,16). Data from seven different paediatric series identified the average rate of bladder injury as 3.6% (26/711) in patients with pelvic fractures (22,23,24,25,26,27,28). Motor vehicle accidents were the cause of the trauma in 97% of cases (28).

### 3.2 Classification

A classification scheme for bladder injury based on the degree of wall injury and anatomical location has been developed by Sandler and associates (Table 3.1) (16,29). Characteristic imaging features for each type of injury can be defined as follows:

- In bladder contusion (type 1), findings are normal.
- In intraperitoneal rupture (type 2), cystography demonstrates intraperitoneal contrast material around bowel loops, between mesenteric folds, and in the paracolic gutters.
- Manifestations of interstitial injury (type 3) include intramural haemorrhage and submucosal extravasation of contrast material without transmural extension.
- In extraperitoneal rupture (type 4), the path of extravasated contrast material is variable. Extravasation is confined to the perivesical space in simple extraperitoneal ruptures, whereas in complex extraperitoneal ruptures, contrast material extends beyond the perivesical space and may dissect into a variety of fascial planes and spaces.
- Combined intra- and extraperitoneal rupture (type 5) usually demonstrates extravasation patterns that are typical for both types of injury.

**Table 3.1: Classification of bladder injury (16,29)**

Type	Description
1	Bladder contusion
2	Intraperitoneal rupture
3	Interstitial bladder injury
4	Extraperitoneal rupture:
	A. Simple
	B. Complex
5	Combined injury

A rather simplistic classification based on the mechanism of injury has also been defined (Table 3.2) (21).

**Table 3.2: Classification of bladder injury based on the type of trauma (21)**

Classification of injury		Mechanism of injury	Associated injuries
Blunt trauma	Extraperitoneal	<ul style="list-style-type: none"> <li>• Blunt pelvic trauma with laceration by bone fragment(s)</li> <li>• Shearing at ligamentous attachment(s)</li> </ul>	<ul style="list-style-type: none"> <li>• Pelvic fractures</li> <li>• Other long bone fractures</li> </ul>
	Intraperitoneal	<ul style="list-style-type: none"> <li>• High velocity blunt lower abdominal trauma</li> <li>• High intravesical pressure with rupture at dome</li> </ul>	<ul style="list-style-type: none"> <li>• High rate of associated intra-abdominal injuries</li> <li>• High mortality</li> </ul>
Penetrating trauma		<ul style="list-style-type: none"> <li>• Direct injury to the bladder wall</li> </ul>	<ul style="list-style-type: none"> <li>• Associated injury to other organs is common</li> </ul>

In this classification, the same definitions as those for blunt trauma can be applied to penetrating injuries. However, these have very limited clinical impact since all cases of penetrating bladder injuries should undergo emergency exploration (30).

### 3.3 Risk factors

Driving under the influence of alcohol predisposes to motor vehicle accidents and to a distended bladder as well. Thus, it is a risk factor for bladder injury (21).

### 3.4 Diagnosis

The two most common signs and symptoms are gross haematuria (82%) and abdominal tenderness (62%) in patients with major bladder injuries (4). Other findings may include the inability to void, bruises over the suprapubic region and abdominal distension (7). Extravasation of urine may result in swelling in the perineum, scrotum and thighs, as well as along the anterior abdominal wall within the potential space between the transversalis fascia and the parietal peritoneum.



#### 3.4.1 *Macroscopic (gross) haematuria*

Gross haematuria indicates urological trauma. A review of the existing literature reveals that traumatic bladder rupture is strongly correlated with the combination of pelvic fracture and gross haematuria: Morey et al. reported gross haematuria in all of their patients with bladder rupture and 85% had pelvic fractures (31). Thus, the classic combination of pelvic fracture and gross haematuria constitutes an absolute indication for immediate cystography in blunt trauma victims (4,14,16,31).

The presence of gross blood at the urethral meatus is considered diagnostic of a urethral injury. A Foley catheter should not be inserted without first doing a retrograde urethrogram to ensure urethral integrity (1). While grossly clear urine in a trauma patient without a pelvic fracture virtually eliminates the possibility of a bladder rupture, between 2% and 10% of patients with bladder rupture may have only microhaematuria or no haematuria at all (1,6).

Tarman et al. reviewed 8021 paediatric trauma patients retrospectively, including 212 consecutive patients with pelvic fractures. In patients with pelvic fractures, only one patient (0.5%) had an extraperitoneal bladder rupture (28). Lower urogenital injury occurred in a total of six patients (2.8%). The absence of gross haematuria effectively ruled out serious injury in this cohort. Based on their data, Tarman and colleagues recommended no further work-up in patients with pelvic fractures without gross haematuria. It is recommended that patients, with gross haematuria, multiple associated injuries or significant abnormalities found upon physical examination, should be evaluated by further testing with retrograde urethrography and cystography.

#### 3.4.2 *Microscopic haematuria*

In the trauma patient with a pelvic ring fracture, microscopic haematuria should be considered to be a possible indicator of bladder laceration and further investigation is warranted. However, exactly how much blood in the urine necessitates investigation is a point of controversy in the literature. In their series, Morgan et al. reported that no ruptures were seen in patients with lower than 25 red blood cells/high power field (rbc/hpf) (11). Werkman et al. (32) concluded that if cystography were restricted only to patients with more than 35-50 rbc/hpf, no perforation would have been missed in their series.

Fuhrman et al. (33) believe that cystography in blunt trauma should be restricted only to those patients with gross haematuria, which they defined as greater than 200 rbc/hpf. They also thought that a retrograde urethrogram should be done first. Existing data do not support lower urinary tract imaging in all patients with either pelvic fracture or microscopic haematuria alone. Similarly, Hochberg and Stone (34) concluded that since 90% of patients in their series of 103 patients with pelvic fracture did not have a bladder rupture, cystography might be safely reserved for those patients with pelvic fracture considered to be at high risk for such an injury. They limited cystography in pelvic fracture to patients with significant pubic arch involvement, gross haematuria, and/or haemodynamic instability.

These observations do not appear to be valid for paediatric trauma patients. In paediatric patients, according to Abou-Jaoude et al. (35), a threshold for radiological evaluation of greater than or equal to 20 rbc/hpf would miss 25% of cases with bladder injury. In contrast to other reported series (28), they suggested that lower urogenital tract evaluation in paediatric trauma patients, especially in the presence of pelvic fractures, should be based as much on clinical judgment as on the presence of haematuria (35).

#### 3.4.3 *Cystography*

Retrograde cystography in the evaluation of bladder trauma is considered the standard diagnostic procedure (14,16,36,37,38). Cystography is accepted as the most accurate radiological study for diagnosing bladder rupture. When adequate bladder filling and post-void images are obtained, cystography has an accuracy rate of 85-100% (6,16,39,40). The diagnosis of bladder rupture is usually made easily on cystography when the injected contrast is identified outside the bladder.

Adequate distension of the urinary bladder is crucial to demonstrate perforation, especially in instances of penetrating trauma, since most instances of a false-negative retrograde cystography were found in this situation (37).

Cystography requires plain film, filled film, and post-drainage films (at minimum). Half-filled film and obliques are optional. For the highest diagnostic accuracy, the bladder must be distended by the instillation of at least 350 ml of contrast media with gravity. Bladder injury may be identified only on the post-drainage film in approximately 10% of cases (16). False-negative findings may result from improperly performed studies with less than 250 ml of contrast instillation or omission of a post-drainage film (41). Only a properly performed cystography should be used to exclude bladder injury (16).

#### 3.4.4 Excretory urography (intravenous pyelogram)

An intravenous pyelogram (IVP) is inadequate for evaluation of the bladder and urethra after trauma because of dilution of the contrast material within the bladder and because a resting intravesical pressure is simply too low to demonstrate a small tear (18,42). An IVP has a low accuracy in the order of 15-25% (17). Various clinical studies have indicated that an IVP has an unacceptably high false-negative rate of 64-84%, which precludes its use as a diagnostic tool in bladder injuries (32,40,43).

#### 3.4.5 Ultrasound

Although, the use of ultrasound in bladder rupture has been described (44), it has not been routinely used for evaluation of bladder injury. The presence of peritoneal fluid in the presence of normal viscera, or a failure to visualize the bladder after the transurethral introduction of saline, are considered highly suggestive of bladder rupture (44). Practically, however, ultrasound is not definitive in bladder or urethral trauma and is almost never used. In contrast, most or all, serious trauma patients are likely to be evaluated with computed tomography (CT) because of the technique's speed and accuracy of evaluation.

#### 3.4.6 Computed tomography (CT)

Computed tomography is clearly the method of choice for the evaluation of patients with blunt or penetrating abdominal and/or pelvic trauma. However, routine CT is not reliable in the diagnosis of bladder rupture even if an inserted urethral catheter is clamped. Computed tomography demonstrates intraperitoneal and extraperitoneal fluid but cannot differentiate urine from ascites. As with IVP, the bladder is usually inadequately distended to cause extravasation through a bladder laceration or perforation, during routine abdominal and pelvic studies. Thus, a negative study cannot be entirely trusted and routine CT cannot therefore exclude bladder injury (13,18,45). Horstman et al. (46) reviewed the cystograms and CT examination of 25 patients who underwent both investigations in the initial evaluation of blunt abdominal trauma. Five of the 25 patients were found to have bladder rupture, three of which were extraperitoneal and two intraperitoneal; all the injuries were detected by both studies. The authors concluded that delayed imaging or contrast instillation (CT cystography) could provide the adequate bladder distention needed to demonstrate contrast extravasation from the injury site during CT.

Similarly, in a series of 316 patients, Deck et al. diagnosed 44 cases with bladder ruptures. In patients who underwent a formal surgical repair, 82% had operative findings that exactly matched the CT cystography interpretation (39). Schneider (1) states that either retrograde cystography or CT cystography are the diagnostic procedures of choice for suspected bladder injury. CT cystography may be used in place of a conventional cystography (overall sensitivity 95% and specificity 100%), especially in patients undergoing CT scanning for other associated injuries (39). However, this procedure should be performed using retrograde filling of the bladder with a minimum of 350 ml of dilute contrast material (16,46,47).

In conclusion, CT cystographic features may lead to accurate classification of bladder injury and allow prompt, effective treatment with less radiation exposure than, and without the additional cost of, conventional cystography (48).

#### 3.4.7 Angiography

Angiography, rarely if ever is indicated. It can be useful in identifying an occult source of bleeding and can guide its subsequent therapeutic embolization (18).

#### 3.4.8 Magnetic resonance imaging (MRI)

Since it is extremely difficult to monitor a seriously injured patient in a strong magnetic field, MRI currently has little place in the evaluation of acute bladder (18). The use of MRI has been described for later evaluation of urethral injury (49,50,51).

### 3.5 Treatment

The first priority in the treatment of bladder injuries is stabilization of the patient and treatment of associated life-threatening injuries.

#### 3.5.1 Blunt trauma: extraperitoneal rupture

Most patients with extraperitoneal rupture can be managed safely by catheter drainage only, even in the presence of extensive retroperitoneal or scrotal extravasation (41). Obstruction of the catheter by clots or tissue debris must be prevented for a proper healing. Cass and Luxenberg reported 93% success rate with this approach in a series of 30 patients with extraperitoneal rupture (6). Eighty-seven per cent of the ruptures were healed in 10 days, and virtually all were healed in three weeks (38). However, bladder neck involvement (3), the presence of bone fragments in the bladder wall or entrapment of the bladder wall will necessitate surgical intervention (21).

### 3.5.2 Blunt trauma: intraperitoneal rupture

Intraperitoneal ruptures occurring after blunt trauma should always be managed by surgical exploration. This type of injury involves a high degree of force and because of the severity of associated injuries, carries a high mortality rate of 20-40% (30). Lacerations are usually large in these cases, with the potential risk of peritonitis due to urine leakage if left untreated (41). Abdominal organs should be inspected for possible associated injuries and an urinoma must be drained.

### 3.5.3 Penetrating injuries

All bladder perforations due to a penetrating trauma should undergo emergency exploration and repair (41)

## 3.6 Recommendations

### 3.6.1 General

Stabilization of the patient is always the priority in cases with associated injuries.

### 3.6.2 Diagnosis

1. Immediate cystography is required in the presence of haematuria and pelvic fracture.
2. Diagnosis should be made with retrograde cystography with a minimum of 350 ml of gravity filled contrast medium.
3. For cystography, the minimum requirement includes a plain film, filled film, and post-drainage film. Half-filled film and obliques are optional.
4. CT cystography can be used with equal efficacy if the patient is undergoing CT scanning for associated injuries.

### 3.6.3 Treatment

1. In the absence of bladder neck involvement and/or associated injuries that require surgical intervention, extraperitoneal bladder ruptures caused by blunt trauma are managed by catheter drainage only.
2. Intraperitoneal bladder ruptures by blunt trauma and any type of bladder injury by penetrating trauma must be managed by emergency surgical exploration and repair
3. The technique of surgical repair depends on the surgeon's preference but a two-layer closure with absorbable sutures achieves a safe repair of the bladder wall.

## 3.7 REFERENCES

1. Schneider RE. Genitourinary trauma. *Emerg Med Clin North Am* 1993;11(1):137-145.  
[http://www.ncbi.nlm.nih.gov/entrez/query.fcgi?cmd=Retrieve&db=PubMed&list\\_uids=8432245&dopt=Abstract](http://www.ncbi.nlm.nih.gov/entrez/query.fcgi?cmd=Retrieve&db=PubMed&list_uids=8432245&dopt=Abstract)
2. Carlin BI, Resnick MI. Indications and techniques for urologic evaluation of the trauma patient with suspected urologic injury. *Semin Urol* 1995;13(1):9-24.  
[http://www.ncbi.nlm.nih.gov/entrez/query.fcgi?cmd=Retrieve&db=PubMed&list\\_uids=7597359&dopt=Abstract](http://www.ncbi.nlm.nih.gov/entrez/query.fcgi?cmd=Retrieve&db=PubMed&list_uids=7597359&dopt=Abstract)
3. Corriere JN Jr, Sandler CM. Management of the ruptured bladder: seven years of experience with 111 cases. *J Trauma* 1986;26(9):830-833.  
[http://www.ncbi.nlm.nih.gov/entrez/query.fcgi?cmd=Retrieve&db=PubMed&list\\_uids=3746959&dopt=Abstract](http://www.ncbi.nlm.nih.gov/entrez/query.fcgi?cmd=Retrieve&db=PubMed&list_uids=3746959&dopt=Abstract)
4. Carroll PR, McAninch JW. Major bladder trauma: mechanisms of injury and a unified method of diagnosis. *J Urol* 1984;132(2):254-257.  
[http://www.ncbi.nlm.nih.gov/entrez/query.fcgi?cmd=Retrieve&db=PubMed&list\\_uids=6737572&dopt=Abstract](http://www.ncbi.nlm.nih.gov/entrez/query.fcgi?cmd=Retrieve&db=PubMed&list_uids=6737572&dopt=Abstract)
5. McConnell JD, Wilkerson MD, Peters PC. Rupture of the bladder. *Urol Clin North Am* 1982;9(2):293-296.  
[http://www.ncbi.nlm.nih.gov/entrez/query.fcgi?cmd=Retrieve&db=PubMed&list\\_uids=7101594&dopt=Abstract](http://www.ncbi.nlm.nih.gov/entrez/query.fcgi?cmd=Retrieve&db=PubMed&list_uids=7101594&dopt=Abstract)
6. Cass AS and Luxenberg M. Features of 164 bladder ruptures. *J Urol* 1987;138(4):743-745.  
[http://www.ncbi.nlm.nih.gov/entrez/query.fcgi?cmd=Retrieve&db=PubMed&list\\_uids=3656524&dopt=Abstract](http://www.ncbi.nlm.nih.gov/entrez/query.fcgi?cmd=Retrieve&db=PubMed&list_uids=3656524&dopt=Abstract)
7. Sagalowsky AI, Peters PC. Genitourinary trauma. In: *Campbell's Urology*. Walsh PC et al. (eds). WB Saunders: Philadelphia, 1998, pp. 3085-3120.
8. Sandler CM, Goldman SM, Kawashima A. Lower urinary tract trauma. *World J Urol* 1998;16(1):69-75.  
[http://www.ncbi.nlm.nih.gov/entrez/query.fcgi?cmd=Retrieve&db=PubMed&list\\_uids=9542018&dopt=Abstract](http://www.ncbi.nlm.nih.gov/entrez/query.fcgi?cmd=Retrieve&db=PubMed&list_uids=9542018&dopt=Abstract)

9. Flancbaum L, Morgan AS, Fleisher M, Cox EF. Blunt bladder trauma: manifestation of severe injury. *Urology* 1988;31(3):220-222.  
[http://www.ncbi.nlm.nih.gov/entrez/query.fcgi?cmd=Retrieve&db=PubMed&list\\_uids=3347970&dopt=Abstract](http://www.ncbi.nlm.nih.gov/entrez/query.fcgi?cmd=Retrieve&db=PubMed&list_uids=3347970&dopt=Abstract)
10. Castle WN, Richardson JR Jr, Walton BJ. Unsuspected intraperitoneal rupture of bladder presenting with abdominal free air. *Urology* 1986;28(6):521-523.  
[http://www.ncbi.nlm.nih.gov/entrez/query.fcgi?cmd=Retrieve&db=PubMed&list\\_uids=3787926&dopt=Abstract](http://www.ncbi.nlm.nih.gov/entrez/query.fcgi?cmd=Retrieve&db=PubMed&list_uids=3787926&dopt=Abstract)
11. Morgan DE, Nallamala LK, Kenney PJ, Mayo MS and Rue LW 3rd. CT cystography: radiographic and clinical predictors of bladder rupture. *AJR Am J Roentgenol* 2000;174(1):89-95.  
[http://www.ncbi.nlm.nih.gov/entrez/query.fcgi?cmd=Retrieve&db=PubMed&list\\_uids=10628460&dopt=Abstract](http://www.ncbi.nlm.nih.gov/entrez/query.fcgi?cmd=Retrieve&db=PubMed&list_uids=10628460&dopt=Abstract)
12. Aihara R, Blansfield JS, Millham FH, LaMorte WW, Hirsch EF. Fracture locations influence the likelihood of rectal and lower urinary tract injuries in patients sustaining pelvic fractures. *J Trauma* 2002;52(2):205-208; discussion 208-209.  
[http://www.ncbi.nlm.nih.gov/entrez/query.fcgi?cmd=Retrieve&db=PubMed&list\\_uids=11834976&dopt=Abstract](http://www.ncbi.nlm.nih.gov/entrez/query.fcgi?cmd=Retrieve&db=PubMed&list_uids=11834976&dopt=Abstract)
13. Cass AS. Diagnostic studies in bladder rupture. Indications and techniques. *Urol Clin North Am* 1989;16(2):267-273.  
[http://www.ncbi.nlm.nih.gov/entrez/query.fcgi?cmd=Retrieve&db=PubMed&list\\_uids=2652855&dopt=Abstract](http://www.ncbi.nlm.nih.gov/entrez/query.fcgi?cmd=Retrieve&db=PubMed&list_uids=2652855&dopt=Abstract)
14. Rehm CG, Mure AJ, O'Malley KF, Ross SE. Blunt traumatic bladder rupture: the role of retrograde cystogram. *Ann Emerg Med* 1991;20(8):845-847.  
[http://www.ncbi.nlm.nih.gov/entrez/query.fcgi?cmd=Retrieve&db=PubMed&list\\_uids=1854066&dopt=Abstract](http://www.ncbi.nlm.nih.gov/entrez/query.fcgi?cmd=Retrieve&db=PubMed&list_uids=1854066&dopt=Abstract)
15. Coppola PT, Coppola M. Emergency department evaluation and treatment of pelvic fractures. *Emerg Med Clin North Am* 2000;18(1):1-27, v. Review.  
[http://www.ncbi.nlm.nih.gov/entrez/query.fcgi?cmd=Retrieve&db=PubMed&list\\_uids=10678158&dopt=Abstract](http://www.ncbi.nlm.nih.gov/entrez/query.fcgi?cmd=Retrieve&db=PubMed&list_uids=10678158&dopt=Abstract)
16. Sandler CM, Goldman SM, Kawashima A. Lower urinary tract trauma. *World J Urol* 1998;16(1):69-75.  
[http://www.ncbi.nlm.nih.gov/entrez/query.fcgi?cmd=Retrieve&db=PubMed&list\\_uids=9542018&dopt=Abstract](http://www.ncbi.nlm.nih.gov/entrez/query.fcgi?cmd=Retrieve&db=PubMed&list_uids=9542018&dopt=Abstract)
17. Festini G, Gregorutti S, Reina G, Bellis GB. Isolated intraperitoneal bladder rupture in patients with alcohol intoxication and minor abdominal trauma. *Ann Emerg Med* 1991;20(12):1371-1372.  
[http://www.ncbi.nlm.nih.gov/entrez/query.fcgi?cmd=Retrieve&db=PubMed&list\\_uids=1746742&dopt=Abstract](http://www.ncbi.nlm.nih.gov/entrez/query.fcgi?cmd=Retrieve&db=PubMed&list_uids=1746742&dopt=Abstract)
18. Ben-Menachem Y, Coldwell DM, Young JW, Burgess AR. Hemorrhage associated with pelvic fractures: causes, diagnosis, and emergent management. *AJR Am J Roentgenol* 1991;157(5):1005-1014.  
[http://www.ncbi.nlm.nih.gov/entrez/query.fcgi?cmd=Retrieve&db=PubMed&list\\_uids=1927786&dopt=Abstract](http://www.ncbi.nlm.nih.gov/entrez/query.fcgi?cmd=Retrieve&db=PubMed&list_uids=1927786&dopt=Abstract)
19. Cass AS. The multiple injured patient with bladder trauma. *J Trauma* 1984;24(8):731-734.  
[http://www.ncbi.nlm.nih.gov/entrez/query.fcgi?cmd=Retrieve&db=PubMed&list\\_uids=6471137&dopt=Abstract](http://www.ncbi.nlm.nih.gov/entrez/query.fcgi?cmd=Retrieve&db=PubMed&list_uids=6471137&dopt=Abstract)
20. Taffet R. Management of pelvic fractures with concomitant urologic injuries. *Orthop Clin North Am* 1997;28(3):389-396.  
[http://www.ncbi.nlm.nih.gov/entrez/query.fcgi?cmd=Retrieve&db=PubMed&list\\_uids=9208831&dopt=Abstract](http://www.ncbi.nlm.nih.gov/entrez/query.fcgi?cmd=Retrieve&db=PubMed&list_uids=9208831&dopt=Abstract)
21. Dreitlein DA, Suner S, Basler J. Genitourinary trauma. *Emerg Med Clin North Am* 2001;19(3):569-590.  
[http://www.ncbi.nlm.nih.gov/entrez/query.fcgi?cmd=Retrieve&db=PubMed&list\\_uids=11554276&dopt=Abstract](http://www.ncbi.nlm.nih.gov/entrez/query.fcgi?cmd=Retrieve&db=PubMed&list_uids=11554276&dopt=Abstract)
22. Reed MH. Pelvic fractures in children. *J Can Assoc Radiol* 1976;27(4):255-261.  
[http://www.ncbi.nlm.nih.gov/entrez/query.fcgi?cmd=Retrieve&db=PubMed&list\\_uids=993239&dopt=Abstract](http://www.ncbi.nlm.nih.gov/entrez/query.fcgi?cmd=Retrieve&db=PubMed&list_uids=993239&dopt=Abstract)
23. Torode I, Zieg D. Pelvic fractures in children. *J Pediatr Orthop* 1985;5(1):76-84.  
[http://www.ncbi.nlm.nih.gov/entrez/query.fcgi?cmd=Retrieve&db=PubMed&list\\_uids=3980712&dopt=Abstract](http://www.ncbi.nlm.nih.gov/entrez/query.fcgi?cmd=Retrieve&db=PubMed&list_uids=3980712&dopt=Abstract)

24. Musemeche CA, Fischer RP, Cotler HB, Andrassy RJ. Selective management of paediatric pelvic fractures: a conservative approach. *J Pediatr Surg* 1987;22(6):538-540.  
[http://www.ncbi.nlm.nih.gov/entrez/query.fcgi?cmd=Retrieve&db=PubMed&list\\_uids=3612446&dopt=Abstract](http://www.ncbi.nlm.nih.gov/entrez/query.fcgi?cmd=Retrieve&db=PubMed&list_uids=3612446&dopt=Abstract)
25. Bond SJ, Gotschall CS, Eichelberger MR. Predictors of abdominal injury in children with pelvic fracture. *J Trauma* 1991;31(8):1169-1173.  
[http://www.ncbi.nlm.nih.gov/80/entrez/query.fcgi?cmd=Retrieve&db=PubMed&list\\_uids=1875444&dopt=Abstract](http://www.ncbi.nlm.nih.gov/80/entrez/query.fcgi?cmd=Retrieve&db=PubMed&list_uids=1875444&dopt=Abstract)
26. Reichard SA, Helikson MA, Shorter N, White RI Jr, Shemeta DW, Haller JA Jr. Pelvic fractures in children — review of 120 patients with a new look at general management. *J Pediatr Surg* 1980;15(6):727-734.  
[http://www.ncbi.nlm.nih.gov/80/entrez/query.fcgi?cmd=Retrieve&db=PubMed&list\\_uids=7463272&dopt=Abstract](http://www.ncbi.nlm.nih.gov/80/entrez/query.fcgi?cmd=Retrieve&db=PubMed&list_uids=7463272&dopt=Abstract)
27. Koraitim MM, Marzouk ME, Atta MA, Orabi SS. Risk factors and mechanism of urethral injury in pelvic fractures. *Br J Urol* 1996;77(6):876-880.  
[http://www.ncbi.nlm.nih.gov/80/entrez/query.fcgi?cmd=Retrieve&db=PubMed&list\\_uids=8705225&dopt=Abstract](http://www.ncbi.nlm.nih.gov/80/entrez/query.fcgi?cmd=Retrieve&db=PubMed&list_uids=8705225&dopt=Abstract)
28. Tarman GJ, Kaplan GW, Lerman SL, McAleer IM, Losasso BE. Lower genitourinary injury and pelvic fractures in paediatric patients. *Urology* 2002;59(1):123-126.  
[http://www.ncbi.nlm.nih.gov/entrez/query.fcgi?cmd=Retrieve&db=PubMed&list\\_uids=11796295&dopt=Abstract](http://www.ncbi.nlm.nih.gov/entrez/query.fcgi?cmd=Retrieve&db=PubMed&list_uids=11796295&dopt=Abstract)
29. Sandler CM, Hall JT, Rodriguez MB, Corriere JN Jr. Bladder injury in blunt pelvic trauma. *Radiology* 1986;158(3):633-638.  
[http://www.ncbi.nlm.nih.gov/entrez/query.fcgi?cmd=Retrieve&db=PubMed&list\\_uids=3945731&dopt=Abstract](http://www.ncbi.nlm.nih.gov/entrez/query.fcgi?cmd=Retrieve&db=PubMed&list_uids=3945731&dopt=Abstract)
30. Thomae KR, Kilambi NK, Poole G V. Method of urinary diversion in nonurethral traumatic bladder injuries: retrospective analysis of 70 cases. *Am Surg* 1998;64(1):77-80, discussion 80-81.  
[http://www.ncbi.nlm.nih.gov/entrez/query.fcgi?cmd=Retrieve&db=PubMed&list\\_uids=9457042&dopt=Abstract](http://www.ncbi.nlm.nih.gov/entrez/query.fcgi?cmd=Retrieve&db=PubMed&list_uids=9457042&dopt=Abstract)
31. Morey AF, Iverson AJ, Swan A, Harmon WJ, Spore SS, Bhayani S, Brandes SB. Bladder rupture after blunt trauma: guidelines for diagnostic imaging. *J Trauma* 2001;51(4):683-686.  
[http://www.ncbi.nlm.nih.gov/entrez/query.fcgi?cmd=Retrieve&db=PubMed&list\\_uids=11586159&dopt=Abstract](http://www.ncbi.nlm.nih.gov/entrez/query.fcgi?cmd=Retrieve&db=PubMed&list_uids=11586159&dopt=Abstract)
32. Werkman HA, Jansen C, Klein JP, Ten Duis HJ. Urinary tract injuries in multiply-injured patients: a rational guideline for the initial assessment. *Injury* 1991;22(6):471-474.  
[http://www.ncbi.nlm.nih.gov/entrez/query.fcgi?cmd=Retrieve&db=PubMed&list\\_uids=1757139&dopt=Abstract](http://www.ncbi.nlm.nih.gov/entrez/query.fcgi?cmd=Retrieve&db=PubMed&list_uids=1757139&dopt=Abstract)
33. Fuhrman GM, Simmons GT, Davidson BS, Buerk CA. The single indication for cystography in blunt trauma. *Am Surg* 1993;59(6):335-337.  
[http://www.ncbi.nlm.nih.gov/entrez/query.fcgi?cmd=Retrieve&db=PubMed&list\\_uids=8507053&dopt=Abstract](http://www.ncbi.nlm.nih.gov/entrez/query.fcgi?cmd=Retrieve&db=PubMed&list_uids=8507053&dopt=Abstract)
34. Hochberg E, Stone NN. Bladder rupture associated with pelvic fracture due to blunt trauma. *Urology* 1993;41(6):531-533.  
[http://www.ncbi.nlm.nih.gov/entrez/query.fcgi?cmd=Retrieve&db=PubMed&list\\_uids=8516988&dopt=Abstract](http://www.ncbi.nlm.nih.gov/entrez/query.fcgi?cmd=Retrieve&db=PubMed&list_uids=8516988&dopt=Abstract)
35. Abou-Jaoude WA, Sugarman JM, Fallat ME, Casale AJ. Indicators of genitourinary tract injury or anomaly in cases of paediatric blunt trauma. *J Pediatr Surg* 1996;31(1):86-89; discussion 90.  
[http://www.ncbi.nlm.nih.gov/entrez/query.fcgi?cmd=Retrieve&db=PubMed&list\\_uids=8632293&dopt=Abstract](http://www.ncbi.nlm.nih.gov/entrez/query.fcgi?cmd=Retrieve&db=PubMed&list_uids=8632293&dopt=Abstract)
36. Stine RJ, Avila JA, Lemons MF, Sickorez GJ. Diagnostic and therapeutic urologic procedures. *Emerg Med Clin North Am* 1988;6(3):547-578.  
[http://www.ncbi.nlm.nih.gov/80/entrez/query.fcgi?cmd=Retrieve&db=PubMed&list\\_uids=3292227&dopt=Abstract](http://www.ncbi.nlm.nih.gov/80/entrez/query.fcgi?cmd=Retrieve&db=PubMed&list_uids=3292227&dopt=Abstract)
37. Baniel J, Shein M. The management of penetrating trauma to the urinary tract. *J Am Coll Surg* 1994;178(4):417-425.  
[http://www.ncbi.nlm.nih.gov/entrez/query.fcgi?cmd=Retrieve&db=PubMed&list\\_uids=8149045&dopt=Abstract](http://www.ncbi.nlm.nih.gov/entrez/query.fcgi?cmd=Retrieve&db=PubMed&list_uids=8149045&dopt=Abstract)

38. Corriere JN, Sandler CM. Management of extraperitoneal bladder rupture. *Urol Clin North Am* 1989;16(2):275-277.  
[http://www.ncbi.nlm.nih.gov/entrez/query.fcgi?cmd=Retrieve&db=PubMed&list\\_uids=2711545&dopt=Abstract](http://www.ncbi.nlm.nih.gov/entrez/query.fcgi?cmd=Retrieve&db=PubMed&list_uids=2711545&dopt=Abstract)
39. Deck AJ, Shaves S, Talner L, Porter JR. Computerized tomography cystography for the diagnosis of traumatic bladder rupture. *J Urol* 2000;164(1):43-46.  
[http://www.ncbi.nlm.nih.gov/entrez/query.fcgi?cmd=Retrieve&db=PubMed&list\\_uids=10840421&dopt=Abstract](http://www.ncbi.nlm.nih.gov/entrez/query.fcgi?cmd=Retrieve&db=PubMed&list_uids=10840421&dopt=Abstract)
40. Carroll PR, McAninch JW. Major bladder trauma: the accuracy of cystography. *J Urol* 1983;Nov;130(5):887-888.  
[http://www.ncbi.nlm.nih.gov/entrez/query.fcgi?cmd=Retrieve&db=PubMed&list\\_uids=6632094&dopt=Abstract](http://www.ncbi.nlm.nih.gov/entrez/query.fcgi?cmd=Retrieve&db=PubMed&list_uids=6632094&dopt=Abstract)
41. Morey AF, Hernandez J, McAninch JW. Reconstructive surgery for trauma of the lower urinary tract. *Urol Clin North Am* 1999;26(1):49-60, viii.  
[http://www.ncbi.nlm.nih.gov/80/entrez/query.fcgi?cmd=Retrieve&db=PubMed&list\\_uids=10086050&dopt=Abstract](http://www.ncbi.nlm.nih.gov/80/entrez/query.fcgi?cmd=Retrieve&db=PubMed&list_uids=10086050&dopt=Abstract)
42. Bonavita JA, Pollack HM. Trauma of the adult bladder and urethra. *Semin Roentgenol* 1983;18(4):299-306.  
[http://www.ncbi.nlm.nih.gov/80/entrez/query.fcgi?cmd=Retrieve&db=PubMed&list\\_uids=6359436&dopt=Abstract](http://www.ncbi.nlm.nih.gov/80/entrez/query.fcgi?cmd=Retrieve&db=PubMed&list_uids=6359436&dopt=Abstract)
43. MacMahon R, Hosking D, Ramsey EW. Management of blunt injury to the lower urinary tract. *Can J Surg* 1983;26(5):415-418.  
[http://www.ncbi.nlm.nih.gov/entrez/query.fcgi?cmd=Retrieve&db=PubMed&list\\_uids=6616359&dopt=Abstract](http://www.ncbi.nlm.nih.gov/entrez/query.fcgi?cmd=Retrieve&db=PubMed&list_uids=6616359&dopt=Abstract)
44. Bigongiari LR, Zarnow H. Traumatic, inflammatory, neoplastic and miscellaneous lesions of the bladder. In: *Medical Radiology of the Lower Urinary Tract*. Land EK. (ed.) Springer Verlag: Berlin, 1994, pp. 70-147.
45. Mee SL, McAninch JW, Federle MP. Computerized tomography in bladder rupture: diagnostic limitations. *J Urol* 1987;137(2):207-209.  
[http://www.ncbi.nlm.nih.gov/entrez/query.fcgi?cmd=Retrieve&db=PubMed&list\\_uids=3806805&dopt=Abstract](http://www.ncbi.nlm.nih.gov/entrez/query.fcgi?cmd=Retrieve&db=PubMed&list_uids=3806805&dopt=Abstract)
46. Horstman WG, McClennan BL, Heiken JP. Comparison of computed tomography and conventional cystography for detection of traumatic bladder rupture. *Urol Radiol* 1991;12(4):188-193.  
[http://www.ncbi.nlm.nih.gov/entrez/query.fcgi?cmd=Retrieve&db=PubMed&list\\_uids=2042269&dopt=Abstract](http://www.ncbi.nlm.nih.gov/entrez/query.fcgi?cmd=Retrieve&db=PubMed&list_uids=2042269&dopt=Abstract)
47. Lis LE, Cohen AJ. CT cystography in the evaluation of bladder trauma. *J Comput Assist Tomogr* 1990;14(3):386-389.  
[http://www.ncbi.nlm.nih.gov/entrez/query.fcgi?cmd=Retrieve&db=PubMed&list\\_uids=2335605&dopt=Abstract](http://www.ncbi.nlm.nih.gov/entrez/query.fcgi?cmd=Retrieve&db=PubMed&list_uids=2335605&dopt=Abstract)
48. Vaccaro JP, Brody JM. CT cystography in the evaluation of major bladder trauma. *Radiographics* 2000;20(5):1373-1381.  
[http://www.ncbi.nlm.nih.gov/80/entrez/query.fcgi?cmd=Retrieve&db=PubMed&list\\_uids=10992026&dopt=Abstract](http://www.ncbi.nlm.nih.gov/80/entrez/query.fcgi?cmd=Retrieve&db=PubMed&list_uids=10992026&dopt=Abstract)
49. Dixon CM, Hricak H, McAninch JW. Magnetic resonance imaging of traumatic posterior urethral defects and pelvic crush injuries. *J Urol* 1992;148(4):1162-1165.  
[http://www.ncbi.nlm.nih.gov/80/entrez/query.fcgi?cmd=Retrieve&db=PubMed&list\\_uids=1404629&dopt=Abstract](http://www.ncbi.nlm.nih.gov/80/entrez/query.fcgi?cmd=Retrieve&db=PubMed&list_uids=1404629&dopt=Abstract)
50. Narumi Y, Hricak H, Armenakas NA, Dixon CM, McAninch JW. MR imaging of traumatic posterior urethral injury. *Radiology* 1993;188(2):439-443.  
[http://www.ncbi.nlm.nih.gov/80/entrez/query.fcgi?cmd=Retrieve&db=PubMed&list\\_uids=8327694&dopt=Abstract](http://www.ncbi.nlm.nih.gov/80/entrez/query.fcgi?cmd=Retrieve&db=PubMed&list_uids=8327694&dopt=Abstract)
51. Armenakas NA, McAninch JW, Lue TF, Dixon CM, Hricak H. Posttraumatic impotence: magnetic resonance imaging and duplex ultrasound in diagnosis and management. *J Urol* 1993;149(5 Pt 2):1272-1275.  
[http://www.ncbi.nlm.nih.gov/80/entrez/query.fcgi?cmd=Retrieve&db=PubMed&list\\_uids=8479013&dopt=Abstract](http://www.ncbi.nlm.nih.gov/80/entrez/query.fcgi?cmd=Retrieve&db=PubMed&list_uids=8479013&dopt=Abstract)

## 4. URETHRAL TRAUMA

### 4.1 Anatomical and aetiological considerations

The male urethra is divided into the anterior and posterior sections by the urogenital diaphragm. The posterior urethra consists of the prostatic and the membranous urethra. The anterior urethra consists of the bulbar and penile urethra. Only the posterior urethra exists in the female; the anterior urethra corresponds to the labia minora, which results from persistent separation of the urethral folds on the ventral surfaces of the genital tubercle.

#### 4.1.1 *Posterior urethral injuries*

Injuries to the posterior urethra occur with pelvic fractures, which are commonly caused by road traffic accidents, crush injuries or falls from height. About two-thirds (70%) of pelvic fractures occur as a result of motor vehicle accidents, with an incidence of 20% in fatal motor accidents, as a driver or passenger, and nearly 50% in fatal pedestrian accidents. Twenty-five per cent of cases present as a result of a fall from a height (1,2). Altogether blunt trauma accounts for more than 90% of urethral injuries (3). Overall the male posterior urethra is concomitantly injured in approximately 3.5-19% of, and the female urethra in 0-6% of, all pelvic fractures (2,4-12). The female urethra is rarely injured, except by contusion or laceration by bone fragments.

Specifically with a crush or deceleration impact injury, the severe shearing forces necessary to fracture the pelvis are transmitted to the prostatic-membranous junction, resulting in disruption of the prostate from its connection to the anterior urethra at the prostatic apex. Retrograde urethrography and magnetic resonance imaging have been correlated with this location of the injury (13,14). Recent cadaveric anatomic studies suggest that in most cases the membranous urethra is torn distally to the urogenital diaphragm (15). An accurate knowledge of the functional anatomy of the sphincter mechanism is essential to the success of posterior urethral surgery. The feasibility of anastomotic reconstruction of subprostatic pelvic fracture urethral distraction defects depends upon the independent function of the proximal bladder neck and of the distal urethral sphincter mechanism, each of which is competent and independently capable of maintaining continence in the absence of the other (16).

In order to diagnose and treat pelvic ring disruptions accurately, the surgeon must have a concept of pelvic stability, which should be determined in both the horizontal and vertical planes. A mechanically stable pelvis is defined as one that can withstand normal physiological forces without abnormal deformation (17). The degree of instability is best indicated by the disruption and posterior displacement at the sacroiliac area and is of extreme importance as a prognostic indicator for the general resuscitation of the patient (18). The anteroposterior and lateral compression types of fracture, while vastly different, may be associated with both stable and unstable subtypes.

The vertical shear fracture is always unstable; the latter, described by Malgaigne in 1855, consists of a fracture anteriorly through both rami of the symphysis pubis, in association with massive posterior disruption, either through the sacrum, the sacroiliac joint or the ilium.

#### 4.1.1.1 *Stable pelvic fracture*

In a stable pelvic fracture, urethral disruption can occur when the large external force, which has fractured all four pelvic rami (straddle fracture), propels the resultant butterfly fragment backwards together with the prostate which is fixed to the back of the pubic bone. The shearing force that results disrupts the membranous urethra, as it passes through the perineum and inevitably destroys the distal urethral sphincter mechanism in almost all such cases.

#### 4.1.1.2 *Unstable pelvic fractures*

Unstable fractures that involve the anterior part of the pubic ring and the sacroiliac joint, ileum or sacrum can also cause injuries to the posterior urethra, either as a result of tears by bony fractures or, more commonly, as a result of disruptions of the urethra caused by distortions of the bony pelvis during major trauma.

This distortion is thought to result in lateral shearing forces, acting on the membranous urethra, as the puboprostatic ligaments and the membranous urethral area are pulled in opposite directions (11). Unstable diametric pelvic fractures (8,11,19-21) or bilateral ischiopubic rami fractures have the highest likelihood of injuring the posterior urethra. In particular, the combination of straddle fractures with diastasis of the sacroiliac joint has the highest risk of urethral injury; the odds ratio is about 7 times higher than for straddle or Malgaigne fractures (Table 4.1) (2).

**Table 4.1: Odds ratio of suffering urethral injury with different types of pelvic fracture**

Type of fracture	Odds ratio
• Single ramus	0.64
• Ipsilateral rami	0.76
• Malgaigne's (vertical shear)	3.40
• Straddle	3.85
• Straddle plus sacroiliac	24.02

Lower urinary tract injury has been reported in about 16% of patients with unilateral rami fractures, but in 41% of patients with bilateral rami fractures (22). Anteroposterior compression injuries from frontal crushes produce more severe pelvic fractures, major retroperitoneal bleeding and more frequent injury to the lower urinary tract than do lateral crashes (23).

Prostatomembranous urethral injuries can vary from simple stretching (25%) to partial rupture (25%) or complete disruptions (50%) (2). The more severe injuries result in prostatic-urethral displacement, with progressive scar formation encompassing the rupture defect. Another type of posterior injury is the post-prostatectomy sphincter strictures, which will not be discussed further in these guidelines, and which are generally treated with dilations to avoid damage to the distal sphincteric mechanism. The incidence of double injuries involving the urethra and the bladder ranges between 10% and 20% of males, and may be intraperitoneal (17-39%) or extraperitoneal (56-78%), or both (2,7).

Urethral injuries, by themselves, are never life-threatening, except as a consequence of their close association with pelvic fractures and multiple organ injuries, which occur in about 27% of cases. Initially, the assessment and management of other associated injuries are usually far more important than the assessment and management of the urethral injury (24).

Colapinto and McCallum (13) classified posterior urethral injuries on the basis of radiographic appearance into three types, depending on the integrity of the membranous urethra and extension of the disruption into the bulbar and membranous urethra (Table 4.2).

**Table 4.2: Classification of posterior injuries according to Collapinto and McCallum (13)**

Type	Description	Radiographic appearance
1	Urethral contusion or stretch injury	Passage of contrast into the bladder, without extravasation and elongation of posterior urethra
2	Partial or complete rupture above the urogenital genital diaphragm (supra-diaphragmatic rupture)	Contrast may reach the bladder, but extravasation is present into the pelvis
3	Complete disruption of the membranous urethra and urogenital diaphragm (sub- and supra-diaphragmatic rupture)	Contrast does not reach the bladder and extravasation is seen into the perineum

The American Association for Surgery of Trauma (AAST) later proposed the classification given in Table 4.3.



**Table 4.3: Organ injury scaling III classification of urethral injuries (25)**

Type	Description	Appearance
I	Contusion	Blood at the urethral meatus; normal urethrogram
II	Stretch injury	Elongation of the urethra without extravasation on urethrography
III	Partial disruption	Extravasation of contrast at injury site with contrast visualized in the bladder
IV	Complete disruption	Extravasation of contrast at injury site without visualization in the bladder; < 2 cm of urethral separation
V	Complete disruption	Complete transection with > 2 cm urethral separation, or extension into the prostate or vagina

Recently a new system has been proposed that provides an anatomical classification and a means of comparing treatment strategies and outcomes (Table 4.4).

**Table 4.4: Classification of urethral injuries according to Goldman et al. (26)**

Type	Description
I	Posterior urethra stretched but intact
II	Tear of the prostatomembranous urethra above the urogenital diaphragm
III	Partial or complete tear of both anterior and posterior urethra, with disruption of the urogenital diaphragm
IV	Bladder injury extending into the urethra
IVa	Injury of the bladder base with periurethral extravasation simulating posterior urethral injury
V	Partial or complete pure anterior urethral injury

In 2001, Al-Rifaei et al. (27) proposed a new anatomical and functional classification for posterior urethral injuries, by adding the combined injuries to prostatic and membranous urethra (Table 4.5).

**Table 4.5: Classification of posterior urethral injuries according to Al-Rifaei et al (27)**

Classification	Description
Ia	Proximal avulsion of the prostate from the bladder neck
Ib	Incomplete or complete transverse transprostatic urethral rupture
II	Stretching of the membranous urethra
III	Incomplete or complete pure rupture of the prostatomembranous junction (classic injury)
IV	Incomplete or complete pure rupture of the bulbomembranous urethra (infradiaphragmatic)
V	Incomplete or complete, variable, combined urethral injuries, affecting more than one level of the urethra

We propose a new classification (Table 4.6) that combines the best of previous classifications and also has direct implications in clinical management .

**Table 4.6: Classification of blunt anterior and posterior urethra**

Classification	Description
I	Stretch injury. Elongation of the urethra without extravasation on urethrography
II	Contusion. Blood at the urethral meatus; no extravasation on urethrography
III	Partial disruption of anterior or posterior urethra. Extravasation of contrast at injury site with contrast visualized in the proximal urethra or bladder
IV	Complete disruption of anterior urethra. Extravasation of contrast at injury site without visualization of proximal urethral or bladder
V	Complete disruption of posterior urethra. Extravasation of contrast at injury site without visualization of bladder
VI	Complete or partial disruption of posterior urethra with associated tear of the bladder neck or vagina

Thus, clinical management can be advised accordingly:

- Type I no treatment required
- Types II and III can be managed conservatively with suprapubic cystostomy or urethral catheterisation.
- Types IV and V will require open or endoscopic treatment, primary or delayed.
- Type VI requires primary open repair.

#### 4.1.1.3 Urethral injuries in children

Urethral injuries in children tend to follow the same mechanism of injury as in adults. The only significant difference is that straddle pelvic fractures, Malgaigne's fractures or the association of straddle plus sacroiliac joint fracture are more common in children than in adults. In addition, posterior urethral injuries can involve the prostatic urethra and the bladder neck, as well as the membranous urethra. The tear is often in the prostatic urethra or at the bladder neck because of the rudimentary nature of the prostate and is more likely to be a complete rupture (69% versus 42%). Urethral stretching is less common than in adults. It has been shown that the more proximal the injury, the greater the risk of incontinence, impotence and stricture formation in the long term (2,24,28,29).

#### 4.1.1.4 Urethral injuries in women

These are rare events since the female urethra is short and mobile, without any significant attachments to the pubic bone. They usually occur in children and are accompanied by severe pelvic fractures, where bony fragments of the fractured pelvis provoke lacerations of the urethra, frequently extending into the bladder neck or vagina and disrupting the normal continence mechanism (4,12). Injury to the female urethra is usually a partial tear of the anterior wall and is rarely a complete disruption of the proximal or distal urethra (29).

#### 4.1.1.5 Penetrating injuries to the perineum

These can occur involving the urethra, as well as being iatrogenic injuries caused by endoscopic instrumentation or during surgery for vaginal repair. In developing countries, urethral and bladder neck damage occur quite often due to ischaemic injury during obstructed labour.

#### 4.1.2 Anterior urethral injuries

Anterior urethral injuries result from blunt trauma more frequently than from penetrating trauma (Table 4.7).

**Table 4.7: Aetiology of anterior urethral injuries**

Causes
<b>Blunt trauma</b>
• Vehicular accidents
• Fall astride
• Kicks in the perineum
• Blows in the perineum from bicycle handlebars, tops of fences, etc.
<b>Sexual intercourse</b>
• Penile fractures
• Urethral intraluminal stimulation
<b>Penetrating trauma</b>
• Gunshot wounds
• Stab wounds
• Dog bites
• External impalement
• Penile amputations
<b>Constriction bands</b>
• Paraplegia
<b>Iatrogenic injuries</b>
• Endoscopic instrumentations
• Urethral catheters-dilators

##### 4.1.2.1 Blunt trauma

Most anterior urethral injuries are caused by vehicular accidents, falls or blows; in contrast to posterior urethral trauma, they are rarely associated with pelvic fractures. They are usually straddle-type injuries caused by blows of blunt objects against the perineum, such as bicycle handlebars or the top of a fence. In this type of accident, the relatively immobile bulbar urethra is trapped and compressed by a direct force on it against the inferior surface of the symphysis pubis. These injuries are more common in children than adults (28).

##### 4.1.2.2 Intercourse-related trauma

Another less frequent cause of blunt anterior urethral trauma occurs in association with ruptures of the corpora cavernosa, which usually occur with an erect penis, often during intercourse. In these injuries, the urethra is involved in 20% of the cases (30). Intraluminal stimulation of the urethra with foreign objects have also been reported to cause anterior urethral trauma. Most are short and incomplete and occur in the distal penile urethra. Surgery is rarely indicated and depends on the degree and extent of injury to the urethra.

#### 4.1.2.3 Penetrating trauma

Penetrating injuries to the anterior urethra usually occur from gunshot wounds and involve the pendulous and bulbar urethral segments equally; these injuries are often found with penetrating penile or testicular trauma, depending on the missile tract. These can involve the rectum, which may result in pelvic abscesses and fistulae formation (31,32). Other less frequent causes of external anterior urethral injuries include stab wounds, penile amputation and external impalement.

#### 4.1.2.4 Constriction band-related trauma

Individuals with paraplegia, who use a constriction device for urinary incontinence and forget to release the band due to the lack of sensation, can cause severe ischaemic injuries involving the penis and urethra.

#### 4.1.2.5 Iatrogenic trauma

Iatrogenic urethral injuries caused by instrumentation are by far the most common cause of urethral trauma. Urethral ischaemic injuries related to cardiac bypass procedures are not infrequent and can result in long and fibrotic strictures.

## 4.2 Diagnosis: Initial emergency assessment

### 4.2.1 Clinical assessment

The initial management of all urethral injuries is resuscitation of the patient as a result of associated possibly life-threatening injuries. In the absence of blood at the meatus or haematoma, a urological injury is very unlikely and will be rapidly excluded by catheterization that promptly occurs in all major trauma victims as part of the process of resuscitation. Airway and respiratory function are maintained, the cervical spine secured in case of polytraumatism, and excessive haemorrhage addressed. This is particularly important in posterior urethral injuries because of their close association with pelvic fractures.

The next step includes taking a complete history and carrying out physical, laboratory and radiographic evaluations in order to identify all injuries accurately. A diagnosis of acute urethral trauma should be suspected from the history. A pelvic fracture, or any external penile or perineal trauma, can be suggestive of urethral trauma (33,34).

For penetrating injuries, the type of weapon used, including the calibre of the bullet with gunshot wounds, is helpful in assessing potential tissue damage. In a conscious patient, a thorough voiding history should be obtained to establish the time of last urination, force of urinary stream, painful urination and presence of haematuria. The following clinical indicators of acute urethral trauma warrant a complete urethral evaluation:

#### 4.2.1.1 Blood at the meatus

It is present in 37-93% of patients with posterior urethral injury and at least 75% of patients with anterior urethral trauma (35,36). Its presence should preclude any attempts at urethral instrumentation, until the entire urethra is adequately imaged. In an unstable patient, an attempt can be made to pass a urethral catheter, but if there is any difficulty a suprapubic catheter is inserted and a retrograde urethrogram performed when appropriate. It is extremely unlikely that gentle passage of a urethral catheter will do any additional damage to that caused by a fracture of the pelvis (37,38), although it has been suggested that this may convert a partial tear into one that is complete (39). There are no convincing data indicating a higher rate of infection or urethral stricture after a single attempt at catheterization (3). Indeed, if a urethral injury is suspected, urethrography prior to attempted catheterization is the most prudent approach.

#### 4.2.1.2 Blood at the vaginal introitus

It is present in more than 80% of female patients with pelvic fractures and co-existing urethral injuries (4).

#### 4.2.1.3 Haematuria

Although non-specific, haematuria on a first voided specimen may indicate urethral injury. The amount of urethral bleeding correlates poorly with the severity of injury, as a mucosal contusion or small partial tear may be accompanied by copious bleeding, while total transection of the urethra may result in little bleeding (40).

#### 4.2.1.4 Pain on urination or inability to void

The inability to void suggests urethral disruption.

#### 4.2.1.5 Haematoma or swelling

With anterior urethral trauma, the pattern of the haematoma can be useful in identifying the anatomical boundaries violated by the injury. Extravasation of blood or urine in a sleeve distribution along the penile shaft indicates that the injury is confined by Buck's fascia. Disruption of Buck's fascia results in a pattern of extravasation limited only by Colles' fascia, extending therefore up to the coracoclavicular fascia superiorly and

the fascia lata inferiorly. This results in a characteristic butterfly pattern of bruising in the perineum. In female patients with severe pelvic fractures, the presence of labial swelling may be an indicator of urethral injury. It can be caused by urinary extravasation from a urethral fistula and warrants immediate attention.

#### 4.2.1.6 High-riding prostate

This is a relatively unreliable finding in the acute phase, since the pelvic haematoma associated with pelvic fractures often precludes the adequate palpation of a small prostate, particularly in younger men (3). A boggy mass is usually palpated without recognition of a prostate gland (41). Rectal examination is more important as a tool to screen for rectal injuries, which can be associated with pelvic fractures. Blood on the examination finger is highly suggestive of such an injury. Assessment of concomitant genital injuries is mandatory in every case of external urethral trauma as well.

#### 4.2.2 Radiographic examination

Retrograde urethrography is considered the gold standard for evaluating urethral injury (5,29). A scout film should be performed first to assess the radiographic technique, and to detect pelvic fractures, as well as the presence of any foreign bodies, such as bullets or stones, which may not be delineated once the contrast material has been given. This is performed using a 12 or 14 French Foley catheter in the fossa navicularis, with the balloon inflated using 1-2 ml of saline to occlude the urethra. Then, 20-30 ml of undiluted contrast material is injected and films taken during the injection in a 30° oblique position. When severe pelvic fractures and associated patient discomfort are present, the oblique position may not always be possible. Radiographic appearance of the urethra permits classification of the injury and facilitate subsequent management.

If posterior urethral injury is suspected, a suprapubic catheter is inserted; a simultaneous cystogram and ascending urethrogram can be carried out at a later date to assess the site, severity and length of the urethral injury. This is usually done within a week of injury, if delayed primary repair is contemplated, or after 3 months if a delayed or late repair is considered. When the proximal urethra is not visualized in a simultaneous cystogram and urethrogram, either magnetic resonance imaging (MRI) of the posterior urethra (42) or endoscopy through the suprapubic tract can be used to define the anatomy of the posterior urethra. Since manipulation in the bladder can cause the bladder neck to open and give the false impression of incompetence, the endoscopic appearance of the bladder neck should be noted immediately on placing the scope into the bladder (43).

After assessing the endoscopic appearance of the bladder neck, the flexible endoscope can be advanced through the bladder neck into the posterior urethra to the level of obstruction. If there is a question regarding the length of the distraction, a simultaneous retrograde urethrogram can be performed while the endoscope is in the posterior urethra. The radiographic appearance of the bladder neck is important but not as reliable an indicator of continence as is the endoscopic appearance. Furthermore, there are patients who, despite evidence of an open bladder neck or a scar at the bladder neck will have acceptable continence after reconstruction. For this reason, concomitant bladder neck surgery at the time of urethral reconstruction is debatable (43,44).

Ultrasonography is not a routine investigation in the initial assessment of urethral injuries but can be very useful in determining the position of the pelvic haematomas and the high-riding bladder when a suprapubic catheter is indicated.

Computed tomography and MRI have no place in the initial assessment of urethral injuries. However, they are useful in defining the distorted pelvic anatomy after severe injury and assessing associated injuries of penile crura, bladder, kidneys and intra-abdominal organs (14,45).

#### 4.2.3 Endoscopic examination

Urethroscopy does not have any role in the initial diagnosis of urethral trauma in males. In females, however, where the short urethra precludes adequate retrograde urethrography, urethroscopy is an important adjunct to the physical examination for the identification and staging of urethral injuries (46).

### 4.3 Management

The management of urethral injuries remains controversial due to the variety of injury patterns, associated injuries and treatment options available. In addition, urethral injuries are relatively uncommon; hence the limited experience of most urologists worldwide and absence of randomised prospective studies.

#### 4.3.1 Anterior urethral injuries

##### 4.3.1.1 Blunt injuries

Partial tears can be managed with a suprapubic catheter or with urethral catheterization (29,37,47). Suprapubic cystostomy has the advantage that it not only diverts the urine away from the site of injury, but it avoids urethral manipulation (48). It also allows for a simultaneous study to be carried out at a later date. If the bladder is not

easily palpable suprapubically, transabdominal sonography should be used to guide the placement of the catheter. The cystostomy tube is maintained for approximately 4 weeks to allow urethral healing. Voiding cystourethrography is then performed and if normal voiding can be re-established and no contrast extravasation nor subsequent stricture is present, then the tube can be safely removed.

The potential early complications of acute urethral injuries include strictures and infections. Extravasated blood or urine from the urethral tear produces an inflammatory reaction that can progress to the formation of an abscess. Extension of the infection depends on the fascial planes violated (see above Diagnosis — initial clinical assessment). Potential sequelae of these infections include urethrocutaneous fistulae, periurethral diverticulae and, rarely, necrotizing fasciitis. Prompt urinary diversion coupled with the appropriate administration of antibiotics decreases the incidence of these complications.

After the patient has adequately recovered from any associated injuries, and the urethral injury has stabilized, the urethra can be thoroughly re-evaluated radiographically and, when necessary, the appropriate reconstructive procedure planned. Blunt anterior urethral injuries are associated with important spongiosal contusion which makes it more difficult evaluating the limits of urethral debridement in the acute phase. Thus, acute or early urethroplasty is not indicated and the best management is simply suprapubic diversion. Satisfactory urethral luminal recanalization occurs in approximately 50% of partial anterior urethral disruptions (47,49). Short and flimsy strictures can be managed with optical urethrotomy or urethral dilation. Denser strictures require formal urethral reconstruction. Anastomotic urethroplasty is indicated in strictures less than 1 cm in length.

Longer strictures of the anterior urethra should not be repaired by an end-to-end anastomosis to avoid chordee. In these cases, flap urethroplasty is indicated. Almost all complete ruptures of the anterior urethra require anastomotic or patch urethroplasty at 3-6 months. The only exception to this is urethral injury associated with penile fracture; this usually results in partial urethral disruption and can be repaired at the time of cavernosal closure.

#### 4.3.1.2 Open injuries

##### 4.3.1.2.1 Male urethral injuries

Stab wounds, gunshot wounds and dog bites to the urethra often involve the penis and testes, necessitating immediate exploration. During this procedure, the urethral injury can be surgically evaluated and repaired as needed, limiting subsequent stricture formation to less than 15% (50).

Primary urethral suturing involves direct visualization of the severed urethral ends, with creation of a water-tight, tension-free repair. The exposure is obtained using a circumferential subcoronal incision to deglove the penis with the patient in the supine position. In complete disruptions, the corpus spongiosum is mobilized at the level of the injury and the urethral ends dissected distally and proximally. Urethral ends are spatulated and end-to-end anastomosis is fashioned over a 14 French Foley catheter. Small lacerations can be sutured with fine absorbable material. Attention is directed to overclosure of the corpus spongiosum and overlying tissues to minimize subsequent fistulae formation (24). Urethral debridement should be kept to a minimum since the vascular characteristics of the corpus spongiosum will permit excellent healing with a properly performed urethrospingiosal repair.

Perioperative prophylactic antibiotics should be used to avoid infections. At 10 days to 2 weeks, a cystourethrogram should be obtained with the urethral catheter *in situ*. Provided there is no leakage at the anastomotic site, the urethral catheter can be removed. If there is leakage, then the catheter is left longer and the cystourethrogram should be repeated 1 week later.

If at the time of initial exploration, the urethra is found to be so extensively disrupted that primary anastomosis is not feasible — this occurs with defects over 1-1.5 cm length - the procedure should be aborted. The surgeon should marsupialize the urethra preparatory to a two-stage urethral repair with proximal suprapubic urinary diversion. A delayed elective procedure is usually carried out after a minimum of 3 months after injury. There is no role for urethral substitution, with either a graft or flap, in the initial management of any urethral injury, since contamination or decreased blood supply can compromise such a repair (33).

##### 4.3.1.2.2 Female urethral injuries

Most female urethral disruptions can be sutured primarily. This is because these injuries occur more frequently in association with bladder ruptures, necessitating prompt exploration. For proximal urethral injuries, urethral exposure is best obtained transvesically, permitting direct visualization of the bladder, bladder neck and proximal urethra. Distal urethral injuries can be approached via the vaginal route (29). Early repair of post-traumatic urethral fistulas can be accomplished using a transvaginal approach (4,12).

#### 4.3.2 Posterior urethral injuries

It is important to make a distinction between posterior urethral stricture and a subprostatic pelvic fracture urethral distraction defect, as the principles of their surgical management are entirely different. Urethral stricture

should be used to indicate a narrowing of the urethral continuity, such as sphincter strictures due to instrumentation or partial urethral tears. In subprostatic complete urethral fractures, a urethral distraction defects exists and there is a gap between the prostatic apex or membranous urethra and the bulbar urethral bout. The dismembered end of the urethra retract and the space between them is filled with fibrous tissue, resulting from organization and healing of the haematoma and urinary extravasation. There is no urethral wall in the scarred space and any lumen represents merely a fistulous tract between the urethral bouts. A further difference with inflammatory strictures is that urethral bouts, regardless of the length of the distraction defect, present very limited fibrosis and when re-anastomosed without tension, heal usually with a little potential for re-stricturing (51).

Erectile dysfunction occurs in 20-60% of patients after traumatic posterior urethral rupture (51-55). Available data suggest that the severity of the initial injury is the most important determining factor associated with impotence. Only 5% of complete erectile dysfunction follows as a consequence of open surgical repair (51,56). King reported an incidence of 42% in cases of pelvic fracture and urethral injury, but only 5% when the urethra was not injured (53). Barbagli reported an incidence of 60% in patients with posterior urethral injury compared with 14% in patients with bulbar injury (57).

Factors that correlate with the development of impotence are age, defect length and the type of fracture; bilateral pubic rami fracture are the most frequent cause of impotence, which is almost always of neurogenic aetiology due to bilateral damage of the cavernous nerves at the prostatomembranous urethra behind the symphysis pubis (58,59). Associated vasculogenic erectile failure may occur in up to 80% of cases (60). Dixon et al. presented evidence that impotence may be also a consequence of avulsion of the corpora cavernosa from the ischium (14). Five of six patients in this series, with avulsion of the corpora cavernosa off the inferior pubic ramus, were impotent. Spontaneous return of potency may occur up to 2 years after injury (42). Gibson reported an incidence of improved sexual function after 18 months in 21% of patients (52).

#### 4.3.2.1 *Partial urethral rupture*

Partial tears of the posterior urethra can be managed in most cases with a suprapubic or urethral catheter and repeat retrograde urethrography at 2-weekly intervals until healing has occurred (29,37). They may heal without significant scarring or obstruction if managed by diversion alone (48,61). Any residual or subsequent stricture can be managed with urethral dilation or optical urethrotomy, if short and flimsy or by anastomotic urethroplasty if denser (24,37).

#### 4.3.2.2 *Complete urethral rupture*

The treatment options available include primary realignment, immediate open urethroplasty, delayed primary urethroplasty, delayed urethroplasty and delayed endoscopic incision.

#### 4.3.2.3 *Primary realignment*

Urethral realignment can be achieved either transpubically (open realignment) or with endoscopic techniques (endoscopic realignment). In posterior urethral injuries associated with concomitant bladder neck or rectal injuries, immediate open exploration, repair and urethral realignment is advisable. Bladder neck injury risks incontinence and infection of the pelvic fractures. Rectal injury carries the obvious risk of sepsis and fistula, and early exploration is indicated to evacuate contaminated haematoma and perform colostomy. Urethral realignment over a stenting catheter is appropriate in such cases (29,40,62-64).

The overall condition of the patient and the extent of associated injuries greatly affect the decision to proceed with primary realignment. Most patients with pelvic crush injuries have multiple organ injuries. Associated lower extremity fractures can prevent placement in the lithotomy position, which is often required for primary realignment, while head injuries increase the adverse risks of anaesthesia. If these conditions are controlled, such that a haemodynamically stable patient can safely undergo a lengthier anaesthesia and can be placed in the lithotomy position, endoscopic urethral realignment may be considered during the first 2 weeks after trauma.

The proposed benefits of primary alignment follow:

1. There is a lower stricture rate than with suprapubic catheter placement alone (69% versus 10%) (6). This avoids a second operation for urethral reconstruction in about one-third of patients (3).
2. If scarring occurs, restoration of urethral continuity is simplified and may be accomplished by endoscopic procedures or dilation.
3. If a urethroplasty is required later, it is technically easier when the prostate and urethra are well-aligned.

Its disadvantage may be a higher incidence of erectile dysfunction and incontinence when compared to delayed reconstruction (6,65).

Webster studied 301 patients from 15 series in which primary realignment was used, and compared the incontinence, impotence, and stricture rates to those in 236 patients from five series, in which cystostomy

and delayed repair was performed (6). Overall, impotence occurred in 44% of patients treated with primary alignment compared with 11% of patients treated with delayed repair. Incontinence was also higher after primary alignment (20% versus 2%). Stricture rates after cystostomy tube placement approach 100%, whereas after primary realignment, strictures occurred in 64% of patients. In most cases of delayed repair, a stricture-free anastomosis can be achieved with success rates greater than 90% (6,66-69). Koraitim in an extensive review of the English literature for the last 50 years came to a similar conclusion. Primary realignment was found to double the incidence of impotence (36% versus 19%) and to have the incidence of stricture compared to suprapubic cystostomy and delayed repair (53% versus 97%) (29). The implication was that primary realignment led to higher impotence and incontinence rates because of iatrogenic factors and thus should be avoided.

However, the series of primary realignment reviewed by Webster and Koraitim encompassed a number of techniques which may explain the poor results of their analysis, compared with those reported by other authors (70). Recent publications show that the injury itself and not the type of management is probably responsible for the loss of potency and continence after urethral trauma (71-73). Elliott and Barret (69) have reported on a series of 57 patients who underwent primary endoscopic urethral realignment with a mean follow-up of 10.5 years; 21% had some degree of erectile dysfunction, 3.7% had mild stress incontinence, 68% had post alignment strictures. The effects on continence and potency with immediate realignment following urethral disruption were also reviewed by Kotkin and Koch (74) in 20 nearly case-matched patients with posterior urethral injuries treated by primary surgical realignment or catheter placement. Continence was preserved in 83% and 80% of patients, respectively, while erectile function returned in 76% and 70%, respectively. A recent series reported by Mouraviev et al. has also shown a lower incidence of impotence and incontinence in patients treated with early realignment than with delayed open reconstruction (75).

The great variation of techniques used for primary realignment procedures confuses any comparison with delayed repair procedures (76-79). Primary realignment techniques include:

- Simple passage of a catheter across the defect (78)
- Endoscopically assisted catheter realignment using flexible, rigid endoscopes and biplanar fluoroscopy (80,81)
- Use of interlocking sounds ('railroading') or magnetic catheters to place the catheter (75,79)
- Pelvic haematoma evacuation and dissection of the prostatic apex (with or without suture anastomosis) over a catheter
- Catheter traction or perineal traction sutures to pull the prostate back to its normal location (82).

Realignment, even with traction, may be insufficient to completely join the margins of the severed urethra and 1.5-4 cm defects have been observed (83). This finding agrees with experimental animal data, which show that when the urethra is transacted and apparently good urethral junction is achieved by catheter traction, there is no evidence of epithelialization of the mucosal gap but rather that the intervening area is filled with fibrous tissue (84). Moreover, sustained traction on the balloon catheter has been noted to damage the only remaining sphincter mechanism at the bladder neck from pressure necrosis (3,62). If series that use true immediate urethral realignment with minimal traction and without suture repair bolsters only are included, the results with immediate realignment are much more favourable (Table 4.8).

**Table 4.8:**  
**Results of immediate realignment in complete urethral disruption (61,70,74,77,79,81,85-98)**

Series	No. of patients	Follow-up months (range)	Erectile dysfunction	Incontinence	Restricture rate*
Gibson (1974)	35**	NA	12 (34%)	1 (3%)	26 (74.3%)
Crassweller et al. (1977)	38	24-240	19/42 (45%)	NA	12 (31.6%)
Malek et al. (1977)***	7	168 (96-264)	0	0	1 (14.3%)
Gelbard et al. (1989)	7	10.2 (2-24)	1/6 (16.7%)	0	2 (33)
Cohen et al. (1991)	4	28 (17-35)	2 (50%)	0	2 (50%)
Melekos et al. (1992)	4	NA	0	0	4 (100%)
Follis et al. (1992)	20	42 (1-360)	4 (20%)	2 (10%)	12 (60%)
El-Abd (1995)	44	NA	35 (79.5%)	0	44 (100%)
Gheiler and Frontera (1997)	3	6 (5-9)	0	0	1 (33.3%)
Londergan et al. (1997)	4	20.2 (12-35)	1 (25%)	0	3 (75%)
Elliott and Barret (1997)	53	126 (1->120)	11 (21%)	2 (3.8%)	36 (68%)
Porter et al. (1997)	10	10.9 (2-31)	1/7 (14%)	0	5 (50%)
Rehman et al. (1998)	3	(11-26)	1 (16.7%)	0	2 (66.7%)
Sahin et al. (1998)	5	31 (21-53)	1 (20%)	1 (20%)	4 (80%)
Tahan et al. (1999)	13	29	3 (23%)	0	5 (38.5%)
Jepson et al. (1999)	8	50.4 (35-85)	3 (37.5%)	1 (12.5%)	5 (62.5%)
Asci et al. (1999)	20	39 (19-78)	4 (20%)	2 (10%)	9 (45%)
Ying-Hao et al. (2000)	4	56 (39-85)	0	0	1 (25%)
Moudouni et al. (2001)	23	68 (18-155)	4/29 (14%)	0	16 (69.5%)
Mouraviev et al. 2005	57	< 24 (2-15)	19/57 (34%)	10/57 (10%)	28/57 (49%)
<b>TOTALS</b>	<b>362</b>		<b>130/368 (35.3%)****</b>	<b>19/362 (5.2%)</b>	<b>218/362 (60.2%)</b>

\*Stricture that requires internal urethrotomy or open urethroplasty or more than 1 dilation;

\*\*5 patients with partial rupture;

\*\*\*children;

\*\*\*\* some partial ruptures included.

This type of summary of the literature suggest that immediate realignment is associated with an impotence rate of approximately 35%, an incontinence rate of 5% and a restricture rate of 60%.

#### 4.3.2.4 Immediate open urethroplasty

Immediate open urethroplasty of posterior injuries is not indicated because of poor visualization and the inability to assess accurately the degree of urethral disruption during the acute phase, characterized by extensive swelling and ecchymosis. The difficulty in identifying structures and planes hamper adequate mobilization and subsequent surgical apposition (24). Incontinence and impotence rates are higher than with the other techniques described in these guidelines (impotence 56%, incontinence 21%, restricture 49%) (6,29,48,65,99,100).

#### 4.3.2.5 Delayed primary urethroplasty

The management of complete posterior rupture of the urethra has changed in recent years. There is now more active orthopaedic management of pelvic fractures with immediate external and internal fixation and this has led to an option for early repairs of urethral injuries (37).

In the absence of indications for immediate exploration, the management of posterior urethral disruption can be in a delayed primary fashion. The delayed primary approach requires placement of a suprapubic tube at the time of initial injury, with repair undertaken when the patient is stable, usually within 10-14 days. It is at a time when patients are stable and most pelvic bleeding has resolved. The aim of the delayed primary repair is to correct severe distraction injuries rather than to prevent a stricture occurring; however, it will also ensure that if it does occur it is easily treatable (99). Haematomas preventing adequate pelvic descent can be evacuated at this point. Repair at this time can be performed endoscopically, as well as through an abdominal or perineal approach (88,99). Urethral repairs using one-stage perineal anastomotic urethroplasty offer a stricture-free rate of 80% (38). The progressive perineal technique usually employed in a delayed fashion after 3 or more months of suprapubic drainage is equally useful in the immediate post-injury period for delayed primary repair if the patient is able to tolerate lithotomy position.

In female urethral disruption, delayed primary urethroplasty is probably the best approach, though no large experience exists. Less than 50 cases have been reported so far, with most reports being simple case



reports (12). Delayed primary repair tries to preserve as much urethral length as possible and to avoid the urethra being embedded in dense scar, thus trying to avoid subsequent incontinence. Surgical exploration should be attempted via the retropubic route for proximal injuries and the vaginal route for distal injuries (29).

#### 4.3.2.6 *Delayed urethroplasty*

The most common end-result of a subprostatic urethral injury managed by delayed repair is the development of a relatively short prostatobulbar urethral gap. Such a simple short gap defect can generally be resolved by a relatively simple perineal approach anastomotic repair, provided that it is not associated with extensive haematoma-fibrosis and the bladder neck mechanism is occlusive and competent.

After division of the bulbar urethra at the distal point of obliteration, mobilization of a normal bulbar urethra to the base of the penis generally achieves 4-5 cm of elastic lengthening. This is usually sufficient to achieve a tension-free, 2 cm, spatulated overlap anastomosis with the apical prostatic urethra, after bridging a gap of 2-2.5 cm without rerouting (24).

This technique has the advantage that most associated injuries and damaged skin and tissues, in addition to the pelvic haematoma, have resolved by the time it is performed. The only problem with this approach would be the length of period that the patient must have a suprapubic catheter before definitive treatment.

When the prostatobulbar gap is longer than 2-3 cm as a result of a high dislocation of the prostate, or when the available elongation of the mobilized urethra has been foreshortened by damage caused by previous surgical procedure, the following manoeuvres are carried out sequentially to gain sufficient anterior urethral mobility to bridge up to 8 cm of separation (101,102): midline separation of the proximal corporal bodies, inferior pubectomy and supracorporal urethral rerouting.

In addition to its use as initial therapy for posterior urethral distraction injuries, the progressive perineal approach can be applied successfully to salvage procedures following failed repair. There are a number of circumstances that may preclude successful perineal anastomotic repair as either initial or salvage therapy. This group probably represents less than 5% of cases and includes the following (101,103,104):

Distraction defects longer than 7-8 cm: A tubed interposition flap of penile or perineoscrotal skin can be used for reconstruction.

Fistulae: These may require a combined abdomino-perineal approach to secure adequate closure.

Synchronous anterior urethral stricture: The presence of associated spongiofibrosis in the anterior urethra may compromise the blood supply to the bulbar urethra following division of the bulbar arteries.

Urinary incontinence: As the distal urethral sphincter mechanism is usually defunctionalized by urethral distraction, urinary continence must be maintained primarily by the proximal bladder neck sphincter. Concomitant bladder neck injury with the likelihood of incontinence may warrant a combined abdominoperineal procedure to enable simultaneous bladder neck and urethral reconstruction. The most common cause of bladder neck incompetence is the circumferential tethering of an uninjured mechanism by the natural shrinkage-replacement of an extensive pelvic floor haematoma by fibrosis. In such cases, it is usually possible to restore functional competence of the bladder neck by mobilizing it meticulously. This can be accomplished by removal of the dense haematoma-fibrosis anchoring the bladder neck to the pubis, anteriorly and laterally, and prevention of secondary fibrotic re-immobilization by occluding the consequent paraprostatic dead-space cavity with a supple omental pedicle graft, so preserving the functional mobility of the liberated sphincter mechanism (44,105).

The results of various techniques are reviewed by Koraitim (65) in a personal series of 100 patients combined with a review of 771 patients from published reports. Immediate and early realignment (n=326) was associated with 53% stricture rate, 5% incontinence rate and 36% impotence rate. Of the patients successfully managed with immediate realignment, 42% needed subsequent instrumentation to attempt stabilization of stricture. Urethroplasty was ultimately necessary in 33%. Primary suturing (n=37) was associated with 49% stricture rate, 21% incontinence rate and 56% impotence rate. In comparison, inserting a suprapubic catheter before delayed repair (n=508) was associated with 97% stricture rate, 4% incontinence rate and 19% impotence rate. The resticture rate after delayed anastomotic urethroplasty was less than 10% (28,38,43,51,55,106-109) and the risk of impotence caused by delayed urethroplasty was about 5% (37,51,55,56,65, 110-112). On the basis of such results, it is evident that the gold standard remains delayed urethral repair at a minimum of 3 months after trauma, using a one-stage perineal approach.

In children similar results are obtained as in adults; the higher incidence of abdominal surgery simply reflects the greater propensity to damage of the bladder neck in children (112-113).

#### 4.3.2.7 *Reconstruction of failed repair of posterior urethral rupture*

When restenosis occurs after delayed urethral repair, it is identified usually within 6 months. If the anastomosis has a normal calibre at 6 months, then it is extremely unlikely that the patient will develop further stricturing (38).

The principles of a salvage repair are similar to those of the initial procedure. Progressive perineal anastomotic repair alone can be successful in 95% of salvage urethroplasties. If an anastomotic repair cannot be performed, a one-stage substitution urethroplasty using a pedicle island of penile skin may be possible and may be more desirable than the final alternative, a two-stage scrotourethral inlay procedure or mesh split-thickness skin graft urethroplasty (101,114,115). The presence of fistulous tracts to the bladder base, abdominal wall, or rectum; periurethral epithelialized cavities; and an ability to achieve the lithotomy position are the leading indications for a combined abdominoperineal surgical approach (104).

Restenosis to a luminal calibre of 12 French Foley catheter or less is required before a reduction in the urinary flow is perceived as abnormal (116). A wide calibre stricture may be followed expectantly or gently dilated. Optical urethrotomy is an alternative, particularly for a short, narrow stricture.

#### 4.3.2.8 Delayed endoscopic optical incision

The principles of the procedure were described by Sachse in 1974 (116). A curved metal sound was passed through the suprapubic cystostomy into the blindly ending proximal urethra, the direct vision urethrotome was inserted into the urethra, and cuts were made toward the sound. Blandy subsequently described the suprapubic passage of a cystoscope for transillumination of the thin perineal membrane associated with short urethral defects and transurethral 'cutting-to-the-light' with an electrode (117). Today, the cut-to-the-light technique is performed more effectively using c-arm fluoroscopy for stereotactic guidance. The urethral catheter is left in place for between 1 and 3 weeks, and the suprapubic drainage for 2 additional weeks to confirm consistent voiding (118).

Results of several small series have been reported and are summarized in Table 4.9.

**Table 4.9:**  
**Results of optical urethrotomy for traumatically obliterated pelvic urethra (97,119-131)**

Series	n	Follow-up months (range)	No. (%) requiring repeat urethrotomy	Erectile dysfunction
Gupta & Gill (1986)	10	15.1 (6-24)	10 (100%)	0
Chiou et al. (1988)	8	43 (12-79)	7 (87.5%)	0
Marshall (1989)	10	NA	10 (100%)	0
Barry (1989)	12	22 (1.5-85)	6 (50%)	0
DeVries & Anderson (1990)	4	< 4	1 (25%)	0
Leonard et al. (1990)	3	31 (13-51)	1 (33.3%)	0
Kernohan et al. (1991)	7	35 (21-84)	7 (100%)	0
Yasuda et al. (1991)	17	44 (12-96)	7 (41.2%)	0
Quint & Stanisic (1993)	10	43 (7-108)	6 (60%)	0
El-Abd (1995)	284	NA	272 (95.8%)	0
Goel et al. (1997)	13	17.7 (11-24)	10 (76.9%)	NA
Levine and Wessells (2001)	6	60	6 (100%)	NA
Dogra & Nabi (2002)*	61	30 (9-44)	11 (18%)	NA
<b>TOTALS</b>	<b>445</b>		<b>354 (79.5%)</b>	

\*Laser urethrotomy

The procedure is only indicated if the urethral defect is short, the bladder neck is competent and there is minimal displacement of the prostate and proximal bulbous urethra (123). Although restoration of urethral continuity is common, and potency is not affected by the procedure, urethral dilation, repeat optical urethrotomy and transurethral resection of stricture are common and will be required in about 80% of patients. Most repeat urethrotomies are performed in the first year of follow-up. It should be noted that after failure of the initial urethrotomy, alternative treatments should be considered as repeat urethrotomy achieves only temporary improvement (131).

Urethral false passage and rectal perforation have been reported (119,123,126). Stents are not currently recommended for patients with strictures following pelvic trauma, as fibrotic tissue tends to grow through into the lumen of the stent (43,132-134).

## 4.4 Recommendations for treatment: Algorithms

The optimal management of patients with prostatomembranous disruptions should not be thought of as delayed repair versus other type of treatment modalities. Each patient should be assessed and managed according to the initial clinical circumstances. It is impractical to suggest that all patients be managed by one single method, due to the variability of each case and the severity of associated injuries. The intervention

should be guided by the clinical circumstances. The following algorithms are suggested for the treatment of urethral injuries in males and females (Figures 4.1-4.3).

#### **4.5 Suggestion for future prospective study**

Study population: Patients with rupture of the membranous urethra but no indications for acute surgery nor 'pie-in-the-sky' bladder.

Material and methods: After a cystostomy tube has been placed and the patient has been stabilized, they are randomized to receive either:

- Delayed primary end-to-end urethroplasty (day 7-14)
- Endoscopic realignment (day < 14)
- Delayed urethroplasty (3-6 months).

Comment: The study could only be carried out in patients able to tolerate the lithotomy position and general anaesthesia. The aim of this hypothetical multicentre study would be to provide accurate data about incontinence, impotence and stricture rate after different types of management for traumatic urethral injuries.

Figure 4.1: Management of posterior urethral injuries in men

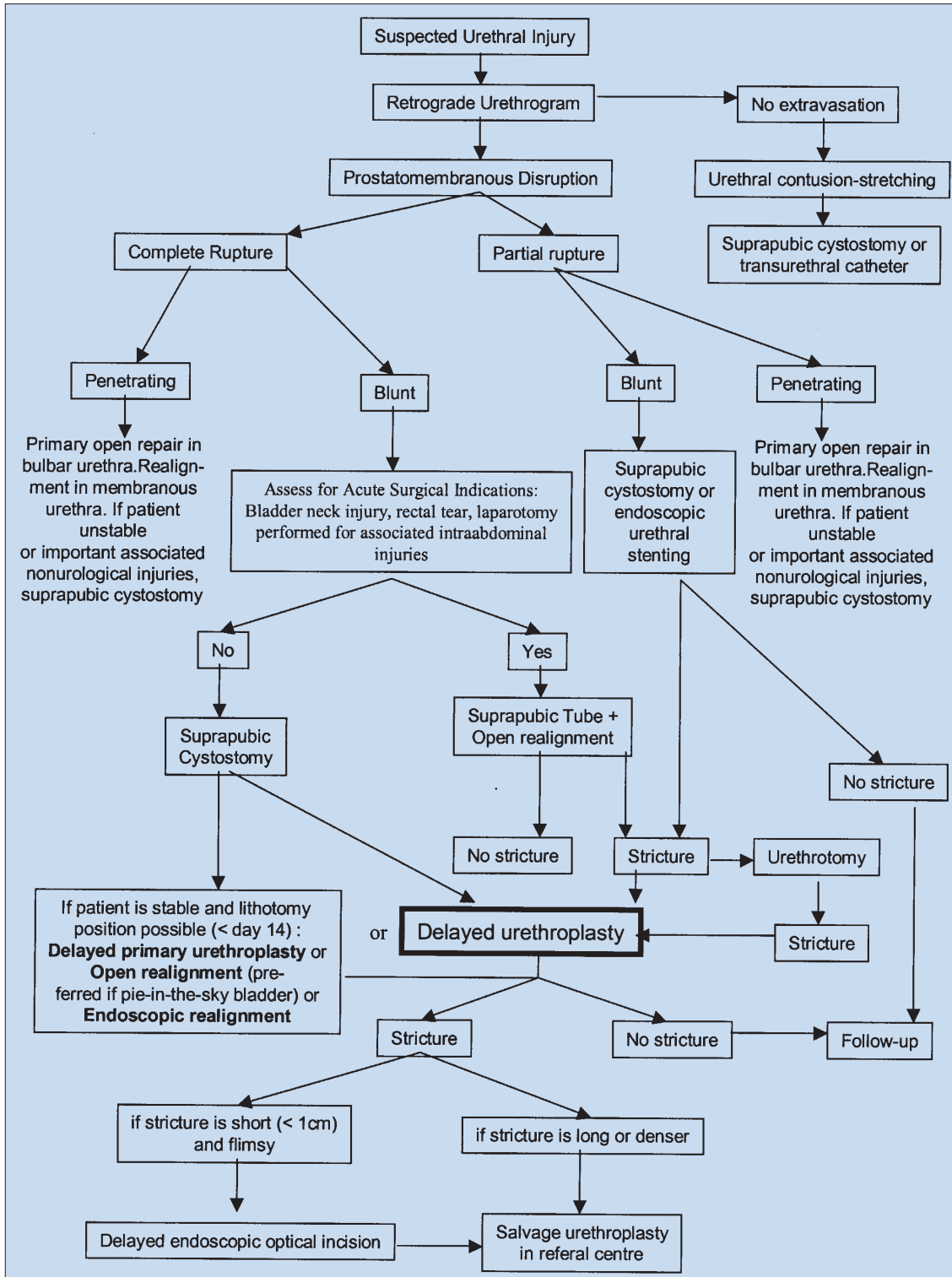


Figure 4.2: Management of anterior urethral injuries in men

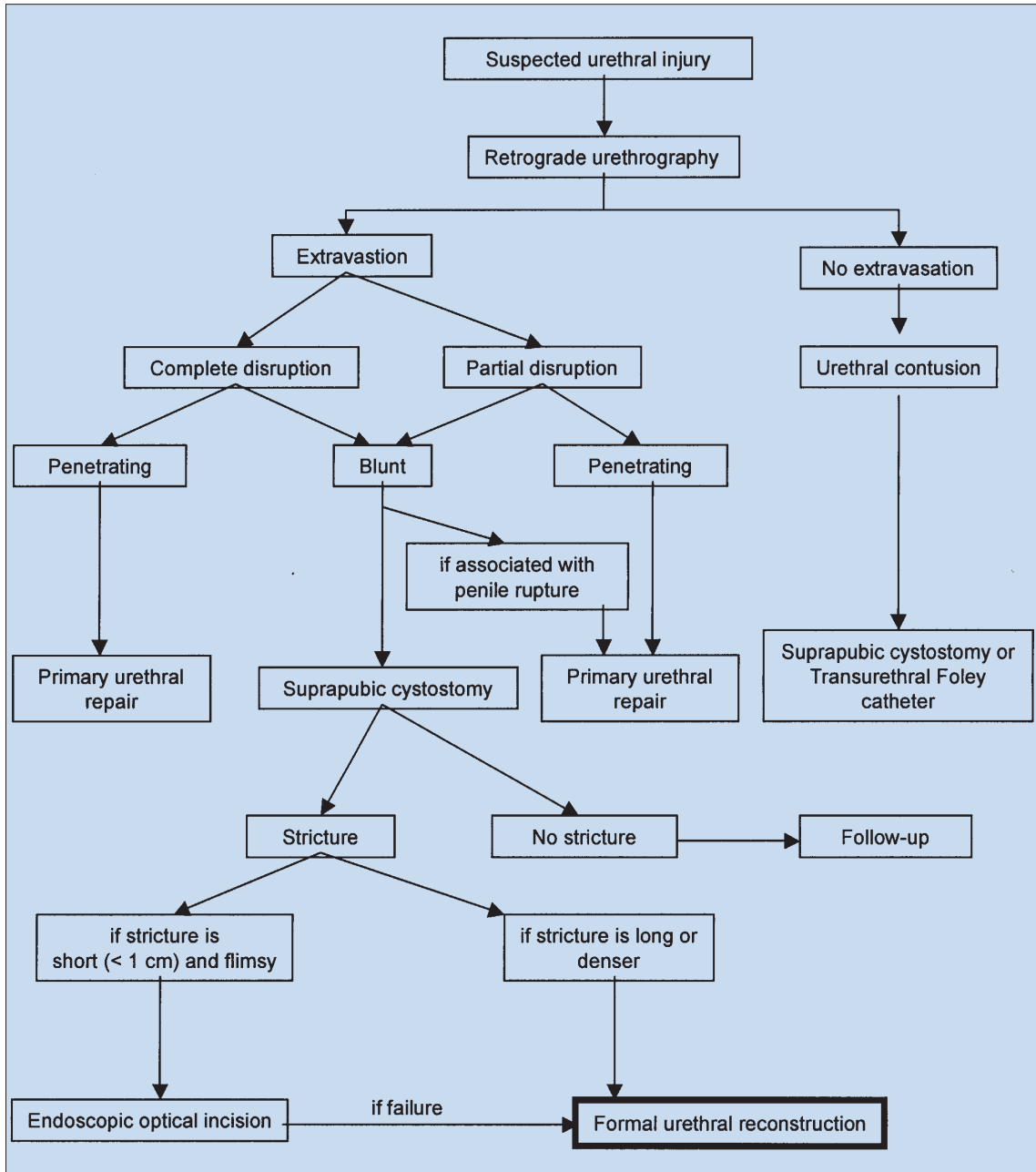
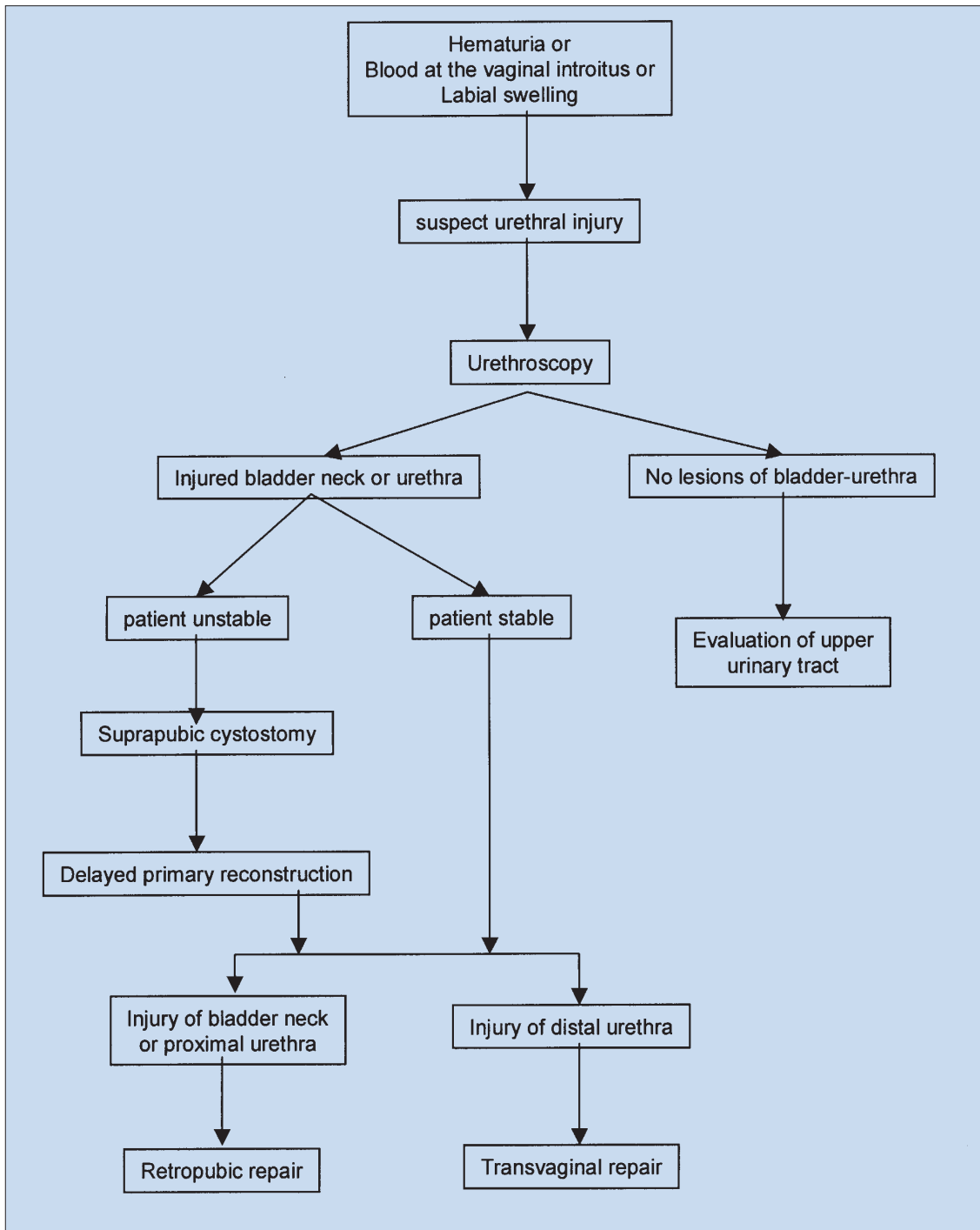


Figure 4.3: Management of urethral injuries in women



#### 4.6 REFERENCES

1. Sevitt S. Fatal road accidents. Injuries, complications, and causes of death in 250 subjects. *Br J Surg* 1968;55(7):481-505.  
[http://www.ncbi.nlm.nih.gov:80/entrez/query.fcgi?cmd=Retrieve&db=PubMed&list\\_uids=5663432&dopt=Abstract](http://www.ncbi.nlm.nih.gov:80/entrez/query.fcgi?cmd=Retrieve&db=PubMed&list_uids=5663432&dopt=Abstract)
2. Koraitim MM, Marzouk ME, Atta MA, Orabi SS. Risk factors and mechanism of urethral injury in pelvic fractures. *Br J Urol* 1996;77(6):876-880 (level of evidence: 2b).  
[http://www.ncbi.nlm.nih.gov:80/entrez/query.fcgi?cmd=Retrieve&db=PubMed&list\\_uids=8705225&dopt=Abstract](http://www.ncbi.nlm.nih.gov:80/entrez/query.fcgi?cmd=Retrieve&db=PubMed&list_uids=8705225&dopt=Abstract)
3. Dixon CM. Diagnosis and acute management of posterior urethral disruptions. In: McAninch JW, ed. *Traumatic and reconstructive urology*. Philadelphia: WB Saunders, 1996, pp. 347-355 (level of evidence: 4).

4. Perry MO, Husmann DA. Urethral injuries in female subjects following pelvic fractures. *J Urol* 1992;147(1):139-143.  
[http://www.ncbi.nlm.nih.gov/entrez/query.fcgi?cmd=Retrieve&db=PubMed&list\\_uids=1729508&dopt=Abstract](http://www.ncbi.nlm.nih.gov/entrez/query.fcgi?cmd=Retrieve&db=PubMed&list_uids=1729508&dopt=Abstract)
5. Colapinto V. Trauma to the pelvis: urethral injury. *Clin Ortho Rel Res* 1980 Sep; (151):46-55.  
[http://www.ncbi.nlm.nih.gov/entrez/query.fcgi?cmd=Retrieve&db=PubMed&list\\_uids=7418323&dopt=Abstract](http://www.ncbi.nlm.nih.gov/entrez/query.fcgi?cmd=Retrieve&db=PubMed&list_uids=7418323&dopt=Abstract)
6. Webster GD, Mathes GL, Selli C. Prostatomembranous urethral injuries: A review of the literature and a rational approach to their management. *J Urol* 1983;130(5):898-902 (level of evidence: 4).  
[http://www.ncbi.nlm.nih.gov/entrez/query.fcgi?cmd=Retrieve&db=PubMed&list\\_uids=6355512&dopt=Abstract](http://www.ncbi.nlm.nih.gov/entrez/query.fcgi?cmd=Retrieve&db=PubMed&list_uids=6355512&dopt=Abstract)
7. Carlin BI, Resnick MI. Indications and techniques for urologic evaluation of the trauma patient with suspected urologic injury. *Semin Urol* 1995;13(1):9-24 (level of evidence: 4).  
[http://www.ncbi.nlm.nih.gov/entrez/query.fcgi?cmd=Retrieve&db=PubMed&list\\_uids=7597359&dopt=Abstract](http://www.ncbi.nlm.nih.gov/entrez/query.fcgi?cmd=Retrieve&db=PubMed&list_uids=7597359&dopt=Abstract)
8. Palmer KJ, Benson GS, Corriere JN Jr. Diagnosis and initial management of urological injuries associated with 200 consecutive pelvic fractures. *J Urol* 1983;130(4):712-714 (level of evidence: 2b).  
[http://www.ncbi.nlm.nih.gov/entrez/query.fcgi?cmd=Retrieve&db=PubMed&list\\_uids=6887403&dopt=Abstract](http://www.ncbi.nlm.nih.gov/entrez/query.fcgi?cmd=Retrieve&db=PubMed&list_uids=6887403&dopt=Abstract)
9. Lowe MA, Mason JT, Luna GK, Maier RV, Copass MK, Berger RE. Risk factors for urethral injuries in men with traumatic pelvic fractures. *J Urol* 1988;140(3):506-507.  
[http://www.ncbi.nlm.nih.gov/entrez/query.fcgi?cmd=Retrieve&db=PubMed&list\\_uids=3411661&dopt=Abstract](http://www.ncbi.nlm.nih.gov/entrez/query.fcgi?cmd=Retrieve&db=PubMed&list_uids=3411661&dopt=Abstract)
10. Clark SS, Prudencio RF. Lower urinary tract injuries associated with pelvic fractures. Diagnosis and management. *Surg Clin North Amer* 1972;52(1):183-201.  
<http://www.ncbi.nlm.nih.gov/entrez/query.fcgi?cmd=Retrieve&db=PubMed&listuids=5013219&dopt=Abstract>
11. Pokorny M, Pontes JE, Pierce JM Jr. Urological injuries associated with pelvic trauma. *J Urol* 1979;121(4):455-457.  
[http://www.ncbi.nlm.nih.gov/entrez/query.fcgi?cmd=Retrieve&db=PubMed&list\\_uids=439217&dopt=Abstract](http://www.ncbi.nlm.nih.gov/entrez/query.fcgi?cmd=Retrieve&db=PubMed&list_uids=439217&dopt=Abstract)
12. Hemal AK, Dorairajan LN, Gupta NP. Posttraumatic complete and partial loss of urethra with pelvic fracture in girls: an appraisal of management. *J Urol* 2000;163(1):282-287.  
[http://www.ncbi.nlm.nih.gov/entrez/query.fcgi?cmd=Retrieve&db=PubMed&list\\_uids=10604377&dopt=Abstract](http://www.ncbi.nlm.nih.gov/entrez/query.fcgi?cmd=Retrieve&db=PubMed&list_uids=10604377&dopt=Abstract)
13. Colapinto V, McCallum RW. Injury to the male posterior urethra in fractured pelvis: a new classification. *J Urol* 1977;118(4):575-580.  
[http://www.ncbi.nlm.nih.gov/entrez/query.fcgi?cmd=Retrieve&db=PubMed&list\\_uids=916052&dopt=Abstract](http://www.ncbi.nlm.nih.gov/entrez/query.fcgi?cmd=Retrieve&db=PubMed&list_uids=916052&dopt=Abstract)
14. Dixon CM, Hricak H, McAninch JW. Magnetic resonance imaging of traumatic posterior urethral defects and pelvic crush injuries. *J Urol* 1992;148(4):1162-1165.  
[http://www.ncbi.nlm.nih.gov/entrez/query.fcgi?cmd=Retrieve&db=PubMed&list\\_uids=1404629&dopt=Abstract](http://www.ncbi.nlm.nih.gov/entrez/query.fcgi?cmd=Retrieve&db=PubMed&list_uids=1404629&dopt=Abstract)
15. Mouraviev VB, Santucci RA. Cadaveric anatomy of pelvic fracture urethral distraction injury: most injuries are distal to the external urinary sphincter. *J Urol* 2005 ;173(3):869-72.  
[http://www.ncbi.nlm.nih.gov/entrez/query.fcgi?cmd=Retrieve&db=pubmed&dopt=Abstract&list\\_uids=15711300&query\\_hl=4&itool=pubmed\\_docsum](http://www.ncbi.nlm.nih.gov/entrez/query.fcgi?cmd=Retrieve&db=pubmed&dopt=Abstract&list_uids=15711300&query_hl=4&itool=pubmed_docsum)
16. Turner-Warwick R. Observations on the treatment of traumatic urethral injuries and the value of the fenestrated urethral catheter. *Br J Surg* 1973;60(10):775-781.  
[http://www.ncbi.nlm.nih.gov/entrez/query.fcgi?cmd=Retrieve&db=PubMed&list\\_uids=4748381&dopt=Abstract](http://www.ncbi.nlm.nih.gov/entrez/query.fcgi?cmd=Retrieve&db=PubMed&list_uids=4748381&dopt=Abstract)
17. Tile M, Pennal GF. Pelvic disruption: principles of management. *Clin Orthop* 1980;(151):56-64 (level of evidence: 4).  
[http://www.ncbi.nlm.nih.gov/entrez/query.fcgi?cmd=Retrieve&db=PubMed&list\\_uids=7418324&dopt=Abstract](http://www.ncbi.nlm.nih.gov/entrez/query.fcgi?cmd=Retrieve&db=PubMed&list_uids=7418324&dopt=Abstract)
18. Pennal GF, Tile M, Waddell JP, Garside H. Pelvic disruption: assessment and classification. *Clin Orthop* 1980;(151):12-21 (level of evidence: 4).  
[http://www.ncbi.nlm.nih.gov/entrez/query.fcgi?cmd=Retrieve&db=PubMed&list\\_uids=7418295&dopt=Abstract](http://www.ncbi.nlm.nih.gov/entrez/query.fcgi?cmd=Retrieve&db=PubMed&list_uids=7418295&dopt=Abstract)

19. Conolly WB, Hedberg EA. Observations on fractures of the pelvis. *J Trauma* 1969;9(2):104-111.  
[http://www.ncbi.nlm.nih.gov/entrez/query.fcgi?cmd=Retrieve&db=PubMed&list\\_uids=5763326&dopt=Abstract](http://www.ncbi.nlm.nih.gov/entrez/query.fcgi?cmd=Retrieve&db=PubMed&list_uids=5763326&dopt=Abstract)
20. Flaherty JJ, Kelley R, Burnett B, Bucy J, Surian M, Schildkraut D, Clarke BG. Relationship of pelvic bone fracture patterns to injuries of urethra and bladder. *J Urol* 1968;99(3):297-300.  
[http://www.ncbi.nlm.nih.gov/entrez/query.fcgi?cmd=Retrieve&db=PubMed&list\\_uids=5689611&dopt=Abstract](http://www.ncbi.nlm.nih.gov/entrez/query.fcgi?cmd=Retrieve&db=PubMed&list_uids=5689611&dopt=Abstract)
21. Devine PC, Devine CJ Jr. Posterior urethral injuries associated with pelvic fractures. *Urology* 1982;20(5):467-470 (level of evidence: 4).  
[http://www.ncbi.nlm.nih.gov/80/entrez/query.fcgi?cmd=Retrieve&db=PubMed&list\\_uids=7147524&dopt=Abstract](http://www.ncbi.nlm.nih.gov/80/entrez/query.fcgi?cmd=Retrieve&db=PubMed&list_uids=7147524&dopt=Abstract)
22. Zorn G. [Fractures of the pelvis with urethral injuries, their treatment and results.] *Bruns Beitr Klin Chir* 1960;201:147-155. [German]  
[http://www.ncbi.nlm.nih.gov/entrez/query.fcgi?cmd=Retrieve&db=PubMed&list\\_uids=13788802&dopt=Abstract](http://www.ncbi.nlm.nih.gov/entrez/query.fcgi?cmd=Retrieve&db=PubMed&list_uids=13788802&dopt=Abstract)
23. Siegel JH, Dalal SA, Burgess AR, Young JW. Pattern of organ injuries in pelvic fracture: impact force implications for survival and death in motor vehicle injuries. *Accid Anal Prev* 1990;22(5):457-466.  
[http://www.ncbi.nlm.nih.gov/entrez/query.fcgi?cmd=Retrieve&db=PubMed&list\\_uids=2222708&dopt=Abstract](http://www.ncbi.nlm.nih.gov/entrez/query.fcgi?cmd=Retrieve&db=PubMed&list_uids=2222708&dopt=Abstract)
24. Chapple CR, Png D. Contemporary management of urethral trauma and the post-traumatic stricture. *Curr Opin Urol* 1999;9(3):253-260 (level of evidence: 4).  
[http://www.ncbi.nlm.nih.gov/entrez/query.fcgi?cmd=Retrieve&db=PubMed&list\\_uids=10726100&dopt=Abstract](http://www.ncbi.nlm.nih.gov/entrez/query.fcgi?cmd=Retrieve&db=PubMed&list_uids=10726100&dopt=Abstract)
25. Moore EE, Cogbill TH, Jurkovich GJ, McAninch JW, Champion HR, Gennarelli TA, Malangoni MA, Shackford SR, Trafton PG. Organ injury scaling. III: Chest wall, abdominal vascular, ureter, bladder, and urethra. *J Trauma* 1992;33(3):337-339 (level of evidence: 4).  
[http://www.ncbi.nlm.nih.gov/entrez/query.fcgi?cmd=Retrieve&db=PubMed&list\\_uids=1404499&dopt=Abstract](http://www.ncbi.nlm.nih.gov/entrez/query.fcgi?cmd=Retrieve&db=PubMed&list_uids=1404499&dopt=Abstract)
26. Goldman SM, Sandler CM, Corriere JN Jr, McGuire EJ. Blunt urethral trauma: a unified, Anatomical mechanical classification. *J Urol* 1997;157(1):85-89.  
[http://www.ncbi.nlm.nih.gov/entrez/query.fcgi?cmd=Retrieve&db=PubMed&list\\_uids=8976222&dopt=Abstract](http://www.ncbi.nlm.nih.gov/entrez/query.fcgi?cmd=Retrieve&db=PubMed&list_uids=8976222&dopt=Abstract)
27. Al-Rifaei M, Eid NI, Al-Rifaei A. Urethral injury secondary to pelvic fracture: anatomical and functional classification. *Scand J Urol Nephrol* 2001;35(3):205-211.  
[http://www.ncbi.nlm.nih.gov/entrez/query.fcgi?cmd=Retrieve&db=PubMed&list\\_uids=11487073&dopt=Abstract](http://www.ncbi.nlm.nih.gov/entrez/query.fcgi?cmd=Retrieve&db=PubMed&list_uids=11487073&dopt=Abstract)
28. Koraitim MM. Posttraumatic posterior urethral strictures in children: a 20-year experience. *J Urol* 1997;157(2):641-645.  
[http://www.ncbi.nlm.nih.gov/entrez/query.fcgi?cmd=Retrieve&db=PubMed&list\\_uids=8996388&dopt=Abstract](http://www.ncbi.nlm.nih.gov/entrez/query.fcgi?cmd=Retrieve&db=PubMed&list_uids=8996388&dopt=Abstract)
29. Koraitim MM. Pelvic fracture urethral injuries: the unresolved controversy. *J Urol* 1999;161(5):1433-1441 (level of evidence: 4).  
[http://www.ncbi.nlm.nih.gov/entrez/query.fcgi?cmd=Retrieve&db=PubMed&list\\_uids=10210368&dopt=Abstract](http://www.ncbi.nlm.nih.gov/entrez/query.fcgi?cmd=Retrieve&db=PubMed&list_uids=10210368&dopt=Abstract)
30. Nicolaisen GS, Melamud A, Williams RD, McAninch JW. Rupture of the corpus cavernosum: surgical management. *J Urol* 1983;130(5):917-919.  
[http://www.ncbi.nlm.nih.gov/entrez/query.fcgi?cmd=Retrieve&db=PubMed&list\\_uids=6632099&dopt=Abstract](http://www.ncbi.nlm.nih.gov/entrez/query.fcgi?cmd=Retrieve&db=PubMed&list_uids=6632099&dopt=Abstract)
31. Gomez RG, Castanheira ACC, McAninch JW. Gunshot wounds to the male external genitalia. *J Urol* 1993;150(4):1147-1149.  
[http://www.ncbi.nlm.nih.gov/entrez/query.fcgi?cmd=Retrieve&db=PubMed&list\\_uids=8371375&dopt=Abstract](http://www.ncbi.nlm.nih.gov/entrez/query.fcgi?cmd=Retrieve&db=PubMed&list_uids=8371375&dopt=Abstract)
32. Pontes JE, Pierce JM Jr. Anterior urethral injuries: four years of experience at the Detroit General Hospital. *J Urol* 1978;120(5):563-564.  
[http://www.ncbi.nlm.nih.gov/entrez/query.fcgi?cmd=Retrieve&db=PubMed&list\\_uids=568672&dopt=Abstract](http://www.ncbi.nlm.nih.gov/entrez/query.fcgi?cmd=Retrieve&db=PubMed&list_uids=568672&dopt=Abstract)
33. Armenakas NA, McAninch JW. Acute anterior urethral injuries: diagnosis and initial management. In: McAninch JW, ed. *Traumatic and reconstructive urology*. Philadelphia: WB Saunders, 1996: 543-550 (level of evidence: 4).



34. Armenakas NA, McAninch JW. A uniform approach to urethroplasty. *Probl Urol* 1994;8(2):254-268 (level of evidence: 4).
35. Lim PH, Chng HC. Initial management of acute urethral injuries. *Br J Urol* 1989;64(2):165-168.  
[http://www.ncbi.nlm.nih.gov/entrez/query.fcgi?cmd=Retrieve&db=PubMed&list\\_uids=2765784&dopt=Abstract](http://www.ncbi.nlm.nih.gov/entrez/query.fcgi?cmd=Retrieve&db=PubMed&list_uids=2765784&dopt=Abstract)
36. McAninch JW. Traumatic injuries to the urethra. *J Trauma* 1981;21(4):291-297.  
[http://www.ncbi.nlm.nih.gov/entrez/query.fcgi?cmd=Retrieve&db=PubMed&list\\_uids=7218395&dopt=Abstract](http://www.ncbi.nlm.nih.gov/entrez/query.fcgi?cmd=Retrieve&db=PubMed&list_uids=7218395&dopt=Abstract)
37. Venn SN, Mundy AR. Immediate management of major trauma to the urinary tract. *Eur Urol* 1998;33(Curric Urol 3.1):1-8. (level of evidence: 4).
38. Mundy AR. Urethroplasty for posterior urethral strictures. *Br J Urol* 1996;78(2):243-247. (Evidence level 2b).  
[http://www.ncbi.nlm.nih.gov/entrez/query.fcgi?cmd=Retrieve&db=PubMed&list\\_uids=8813921&dopt=Abstract](http://www.ncbi.nlm.nih.gov/entrez/query.fcgi?cmd=Retrieve&db=PubMed&list_uids=8813921&dopt=Abstract)
39. Corriere JN Jr, Harris JD. The management of urological injuries in blunt pelvic trauma. *Radiol Clin North Am* 1981;19(1):187-193. (level of evidence: 4).
40. Antoci JP, Schiff MJ Jr. Bladder and urethral injuries in patients with pelvic fractures. *J Urol* 1982;128(1):25-26.  
[http://www.ncbi.nlm.nih.gov/entrez/query.fcgi?cmd=Retrieve&db=PubMed&list\\_uids=7109063&dopt=Abstract](http://www.ncbi.nlm.nih.gov/entrez/query.fcgi?cmd=Retrieve&db=PubMed&list_uids=7109063&dopt=Abstract)
41. Fallon B, Wendt JC, Hawtrey CE. Urological injury and assessment in patients with fractured pelvis. *J Urol* 1984;131(4):712-714.  
[http://www.ncbi.nlm.nih.gov/entrez/query.fcgi?cmd=Retrieve&db=PubMed&list\\_uids=6708187&dopt=Abstract](http://www.ncbi.nlm.nih.gov/entrez/query.fcgi?cmd=Retrieve&db=PubMed&list_uids=6708187&dopt=Abstract)
42. McAninch JW. Pubectomy in repair of membranous urethral strictures. In: McAninch JW, ed. *Traumatic and reconstructive urology*. Philadelphia: WB Saunders, 1996, pp. 411-415.
43. Jordan GH. Management of membranous urethral distraction injuries via the perineal approach. In: McAninch JW, ed. *Traumatic and reconstructive urology*. Philadelphia: WB Saunders, 1996, pp. 393-409 (level of evidence: 4).
44. Iselin CE, Webster GD. The significance of the open bladder neck associated with pelvic fracture urethral distraction defects. *J Urol* 1999;162(2):347-351.  
[http://www.ncbi.nlm.nih.gov/80/entrez/query.fcgi?cmd=Retrieve&db=PubMed&list\\_uids=10411036&dopt=Abstract](http://www.ncbi.nlm.nih.gov/80/entrez/query.fcgi?cmd=Retrieve&db=PubMed&list_uids=10411036&dopt=Abstract)
45. Kane NM, Francis IR, Ellis JH. The value of CT in the detection of bladder and posterior urethral injuries. *AJR Am J Roentgenol* 1989;153(6):1243-1246.  
[http://www.ncbi.nlm.nih.gov/entrez/query.fcgi?cmd=Retrieve&db=PubMed&list\\_uids=2816642&dopt=Abstract](http://www.ncbi.nlm.nih.gov/entrez/query.fcgi?cmd=Retrieve&db=PubMed&list_uids=2816642&dopt=Abstract)
46. McAninch JW. Urethral injuries in female subjects following pelvic fractures.(Editorial Comment). *J Urol* 1992;147(1):143 (level of evidence: 4).
47. Jackson DH, Williams JL. Urethral injury: a retrospective study. *Br J Urol* 1974;46(6):665-676.  
[http://www.ncbi.nlm.nih.gov/entrez/query.fcgi?cmd=Retrieve&db=PubMed&list\\_uids=4451833&dopt=Abstract](http://www.ncbi.nlm.nih.gov/entrez/query.fcgi?cmd=Retrieve&db=PubMed&list_uids=4451833&dopt=Abstract)
48. Glassberg KI, Tolete-Velcek F, Ashley R, Waterhouse K. Partial tears of prostatomembranous urethra in children. *Urology* 1979;13(5):500-504.  
[http://www.ncbi.nlm.nih.gov/entrez/query.fcgi?cmd=Retrieve&db=PubMed&list\\_uids=442372&dopt=Abstract](http://www.ncbi.nlm.nih.gov/entrez/query.fcgi?cmd=Retrieve&db=PubMed&list_uids=442372&dopt=Abstract)
49. Cass AS, Godec CJ. Urethral injury due to external trauma. *Urology* 1978;11(6):607-611.  
[http://www.ncbi.nlm.nih.gov/entrez/query.fcgi?cmd=Retrieve&db=PubMed&list\\_uids=675928&dopt=Abstract](http://www.ncbi.nlm.nih.gov/entrez/query.fcgi?cmd=Retrieve&db=PubMed&list_uids=675928&dopt=Abstract)
50. Husmann DA, Boone TB, Wilson WT. Management of low velocity gunshot wounds to the anterior urethra: the role of primary repair versus urinary diversion alone. *J Urol* 1993;150(1):70-72.  
[http://www.ncbi.nlm.nih.gov/entrez/query.fcgi?cmd=Retrieve&db=PubMed&list\\_uids=8510278&dopt=Abstract](http://www.ncbi.nlm.nih.gov/entrez/query.fcgi?cmd=Retrieve&db=PubMed&list_uids=8510278&dopt=Abstract)
51. Martínez Piñeiro JA, Carcamo P, García Matres MJ, Martínez Piñeiro L, Iglesias JR, Rodríguez-Ledesma JM. Excision and anastomotic repair for urethral stricture disease: experience with 150 cases. *Eur Urol* 1997;32(4):433-441.  
[http://www.ncbi.nlm.nih.gov/entrez/query.fcgi?cmd=Retrieve&db=PubMed&list\\_uids=9412802&dopt=Abstract](http://www.ncbi.nlm.nih.gov/entrez/query.fcgi?cmd=Retrieve&db=PubMed&list_uids=9412802&dopt=Abstract)

52. Gibson GR. Impotence following fractured pelvis and ruptured urethra. *Br J Urol* 1970;42(1):86-88.  
[http://www.ncbi.nlm.nih.gov/entrez/query.fcgi?cmd=Retrieve&db=PubMed&list\\_uids=5435706&dopt=Abstract](http://www.ncbi.nlm.nih.gov/entrez/query.fcgi?cmd=Retrieve&db=PubMed&list_uids=5435706&dopt=Abstract)
53. King J. Impotence after fractures of the pelvis. *J Bone Joint Surg Am* 1975;57(8):1107-1109.  
[http://www.ncbi.nlm.nih.gov/entrez/query.fcgi?cmd=Retrieve&db=PubMed&list\\_uids=1201996&dopt=Abstract](http://www.ncbi.nlm.nih.gov/entrez/query.fcgi?cmd=Retrieve&db=PubMed&list_uids=1201996&dopt=Abstract)
54. Dhabuwala CB, Hamid S, Katsikas DM, Pierce JM Jr. Impotence following delayed repair of prostatomembranous urethral disruption. *J Urol* 1990;144(3):677-678.  
[http://www.ncbi.nlm.nih.gov/entrez/query.fcgi?cmd=Retrieve&db=PubMed&list\\_uids=2388326&dopt=Abstract](http://www.ncbi.nlm.nih.gov/entrez/query.fcgi?cmd=Retrieve&db=PubMed&list_uids=2388326&dopt=Abstract)
55. Corriere JN. 1-Stage delayed bulboprostatic anastomotic repair of posterior urethral rupture: 60 patients with 1-year followup. *J Urol* 2001;165(2):404-407.  
[http://www.ncbi.nlm.nih.gov/entrez/query.fcgi?cmd=Retrieve&db=PubMed&list\\_uids=11176383&dopt=Abstract](http://www.ncbi.nlm.nih.gov/entrez/query.fcgi?cmd=Retrieve&db=PubMed&list_uids=11176383&dopt=Abstract)
56. Webster GD. Impotence following delayed repair of prostatomembranous urethral disruption. Editorial comment. *J Urol* 1990;144(3):678.
57. Barbagli G, Selli C, Stomaci N, Delle Rose A, Trippitelli A, Lenzi R. Urethral trauma: radiological aspects and treatment options. *J Trauma* 1987;27(3):256-261.  
[http://www.ncbi.nlm.nih.gov/80/entrez/query.fcgi?cmd=Retrieve&db=PubMed&list\\_uids=3560267&dopt=Abstract](http://www.ncbi.nlm.nih.gov/80/entrez/query.fcgi?cmd=Retrieve&db=PubMed&list_uids=3560267&dopt=Abstract)
58. Mark SD, Keane TE, Vandemark RM, Webster GD. Impotence following pelvic fracture urethral injury: incidence, aetiology and management. *Br J Urol* 1995;75(1):62-64.  
[http://www.ncbi.nlm.nih.gov/80/entrez/query.fcgi?cmd=Retrieve&db=PubMed&list\\_uids=7850299&dopt=Abstract](http://www.ncbi.nlm.nih.gov/80/entrez/query.fcgi?cmd=Retrieve&db=PubMed&list_uids=7850299&dopt=Abstract)
59. Shenfeld OZ, Kiselgorf D, Gofrit ON, Verstandig AG, Landau EH, Pode D, Jordan GH, McAninch JW. The incidence and causes of erectile dysfunction after pelvic fractures associated with posterior urethral disruption. *J Urol*. 2003;169(6):2173-2176.  
[http://www.ncbi.nlm.nih.gov/entrez/query.fcgi?cmd=Retrieve&db=pubmed&dopt=Abstract&list\\_uids=12771742&query\\_hl=6&itool=pubmed\\_docsum](http://www.ncbi.nlm.nih.gov/entrez/query.fcgi?cmd=Retrieve&db=pubmed&dopt=Abstract&list_uids=12771742&query_hl=6&itool=pubmed_docsum)
60. Armenakas NA, McAninch JW, Lue TF, Dixon CM, Hricak H. Posttraumatic impotence: magnetic resonance imaging and duplex ultrasound in diagnosis and management. *J Urol* 1993;149(5 Pt 2):1272-1275.  
[http://www.ncbi.nlm.nih.gov/80/entrez/query.fcgi?cmd=Retrieve&db=PubMed&list\\_uids=8479013&dopt=Abstract](http://www.ncbi.nlm.nih.gov/80/entrez/query.fcgi?cmd=Retrieve&db=PubMed&list_uids=8479013&dopt=Abstract)
61. Turner-Warwick R. Prevention of complications resulting from pelvic fracture urethral injuries — and from their surgical management. *Urol Clin North Am* 1989;16(2):335-358 (level of evidence: 4).  
[http://www.ncbi.nlm.nih.gov/80/entrez/query.fcgi?cmd=Retrieve&db=PubMed&list\\_uids=2652859&dopt=Abstract](http://www.ncbi.nlm.nih.gov/80/entrez/query.fcgi?cmd=Retrieve&db=PubMed&list_uids=2652859&dopt=Abstract)
62. Berman AT, Tom L. Traumatic separation of the pubic symphysis with associated fatal rectal tear: a case report and analysis of mechanism of injury. *J Trauma* 1974;14(12):1060-1067.  
[http://www.ncbi.nlm.nih.gov/80/entrez/query.fcgi?cmd=Retrieve&db=PubMed&list\\_uids=4431071&dopt=Abstract](http://www.ncbi.nlm.nih.gov/80/entrez/query.fcgi?cmd=Retrieve&db=PubMed&list_uids=4431071&dopt=Abstract)
63. Muhlbauer S, Bard RH. Early definitive urologic management of patient with crush pelvic trauma and deep perineal laceration. *Urology* 1980;15(1):56-59.  
[http://www.ncbi.nlm.nih.gov/80/entrez/query.fcgi?cmd=Retrieve&db=PubMed&list\\_uids=7352346&dopt=Abstract](http://www.ncbi.nlm.nih.gov/80/entrez/query.fcgi?cmd=Retrieve&db=PubMed&list_uids=7352346&dopt=Abstract)
64. Koraitim MM. Pelvic fracture urethral injuries: evaluation of various methods of management. *J Urol* 1996;156(4):1288-1291.  
[http://www.ncbi.nlm.nih.gov/80/entrez/query.fcgi?cmd=Retrieve&db=PubMed&list\\_uids=8808856&dopt=Abstract](http://www.ncbi.nlm.nih.gov/80/entrez/query.fcgi?cmd=Retrieve&db=PubMed&list_uids=8808856&dopt=Abstract)
65. Coffield KS, Weems WL. Experience with management of posterior urethral injury associated with pelvic fracture. *J Urol* 1977;117(6):722-724.  
[http://www.ncbi.nlm.nih.gov/80/entrez/query.fcgi?cmd=Retrieve&db=PubMed&list\\_uids=559782&dopt=Abstract](http://www.ncbi.nlm.nih.gov/80/entrez/query.fcgi?cmd=Retrieve&db=PubMed&list_uids=559782&dopt=Abstract)
66. Morehouse DD, Mackinnon KJ. Management of prostatomembranous urethral disruption: a 13-year experience. *J Urol* 1980;123(2):173-174.  
[http://www.ncbi.nlm.nih.gov/80/entrez/query.fcgi?cmd=Retrieve&db=PubMed&list\\_uids=7354510&dopt=Abstract](http://www.ncbi.nlm.nih.gov/80/entrez/query.fcgi?cmd=Retrieve&db=PubMed&list_uids=7354510&dopt=Abstract)

67. McAninch JW. Pubectomy in repair of membranous urethral stricture. *Urol Clin North Am* 1989;16(2):297-302 (level of evidence: 4).  
[http://www.ncbi.nlm.nih.gov:80/entrez/query.fcgi?cmd=Retrieve&db=PubMed&list\\_uids=2711548&dopt=Abstract](http://www.ncbi.nlm.nih.gov:80/entrez/query.fcgi?cmd=Retrieve&db=PubMed&list_uids=2711548&dopt=Abstract)
68. Webster GD. Perineal repair of membranous urethral stricture. *Urol Clin North Am* 1989;16(2):303-312 (level of evidence: 4).  
[http://www.ncbi.nlm.nih.gov:80/entrez/query.fcgi?cmd=Retrieve&db=PubMed&list\\_uids=2652857&dopt=Abstract](http://www.ncbi.nlm.nih.gov:80/entrez/query.fcgi?cmd=Retrieve&db=PubMed&list_uids=2652857&dopt=Abstract)
69. Elliott DS, Barrett DM. Long-term follow-up and evaluation of primary realignment of posterior urethral disruptions. *J Urol* 1997;157(3):814-816.  
[http://www.ncbi.nlm.nih.gov:80/entrez/query.fcgi?cmd=Retrieve&db=PubMed&list\\_uids=9072573&dopt=Abstract](http://www.ncbi.nlm.nih.gov:80/entrez/query.fcgi?cmd=Retrieve&db=PubMed&list_uids=9072573&dopt=Abstract)
70. McAninch JW. Editorial: Scars in the urinary system. *J Urol* 1997;157(3):817 (level of evidence: 4).  
[http://www.ncbi.nlm.nih.gov/entrez/query.fcgi?cmd=Retrieve&db=pubmed&dopt=Abstract&list\\_uids=9072574&query\\_hl=24&itool=pubmed\\_docsum](http://www.ncbi.nlm.nih.gov/entrez/query.fcgi?cmd=Retrieve&db=pubmed&dopt=Abstract&list_uids=9072574&query_hl=24&itool=pubmed_docsum)
71. Husmann DA, Wilson WT, Boone TB, Allen TD. Prostatomembranous urethral disruptions: management by suprapubic cystostomy and delayed urethroplasty. *J Urol* 1990;144(1):76-78.  
[http://www.ncbi.nlm.nih.gov:80/entrez/query.fcgi?cmd=Retrieve&db=PubMed&list\\_uids=2359183&dopt=Abstract](http://www.ncbi.nlm.nih.gov:80/entrez/query.fcgi?cmd=Retrieve&db=PubMed&list_uids=2359183&dopt=Abstract)
72. Morey AF, McAninch JW. Reconstruction of posterior urethral disruption injuries: outcome analysis in 82 patients. *J Urol* 1997;157(2):506-510.  
[http://www.ncbi.nlm.nih.gov:80/entrez/query.fcgi?cmd=Retrieve&db=PubMed&list\\_uids=8996343&dopt=Abstract](http://www.ncbi.nlm.nih.gov:80/entrez/query.fcgi?cmd=Retrieve&db=PubMed&list_uids=8996343&dopt=Abstract)
73. Asci R, Sarikaya S, Buyukalpelli R, Saylik A, Yilmaz AF, Yildiz S. Voiding and sexual dysfunctions after pelvic fracture urethral injuries treated with either initial cystostomy and delayed urethroplasty or immediate primary urethral realignment. *Scand J Urol Nephrol* 1999;33(4):228-233.  
[http://www.ncbi.nlm.nih.gov:80/entrez/query.fcgi?cmd=Retrieve&db=PubMed&list\\_uids=10515084&dopt=Abstract](http://www.ncbi.nlm.nih.gov:80/entrez/query.fcgi?cmd=Retrieve&db=PubMed&list_uids=10515084&dopt=Abstract)
74. Kotkin L, Koch MO. Impotence and incontinence after immediate realignment of posterior urethral trauma: results of injury or management? *J Urol* 1996;155(5):1600-1603 (level of evidence: 2b).  
[http://www.ncbi.nlm.nih.gov:80/entrez/query.fcgi?cmd=Retrieve&db=PubMed&list\\_uids=8627832&dopt=Abstract](http://www.ncbi.nlm.nih.gov:80/entrez/query.fcgi?cmd=Retrieve&db=PubMed&list_uids=8627832&dopt=Abstract)
75. Mouraviev VB, Coburn M, Santucci RA. The treatment of posterior urethral disruption associated with pelvic fractures: comparative experience of early realignment versus delayed urethroplasty. *J Urol* 2005;173(3):873-876.  
[http://www.ncbi.nlm.nih.gov/entrez/query.fcgi?cmd=Retrieve&db=pubmed&dopt=Abstract&list\\_uids=15711301&query\\_hl=8&itool=pubmed\\_docsum](http://www.ncbi.nlm.nih.gov/entrez/query.fcgi?cmd=Retrieve&db=pubmed&dopt=Abstract&list_uids=15711301&query_hl=8&itool=pubmed_docsum)
76. Follis HW, Koch MO, McDougal WS. Immediate management of prostatomembranous urethral disruptions. *J Urol* 1992;147(5):1259-1262 (level of evidence: 2b).  
[http://www.ncbi.nlm.nih.gov:80/entrez/query.fcgi?cmd=Retrieve&db=PubMed&list\\_uids=1569663&dopt=Abstract](http://www.ncbi.nlm.nih.gov:80/entrez/query.fcgi?cmd=Retrieve&db=PubMed&list_uids=1569663&dopt=Abstract)
77. Herschorn S, Thijssen A, Radomski SB. The value of immediate or early catheterization of the traumatized posterior urethra. *J Urol* 1992;148(5):1428-1431.  
[http://www.ncbi.nlm.nih.gov:80/entrez/query.fcgi?cmd=Retrieve&db=PubMed&list\\_uids=1433542&dopt=Abstract](http://www.ncbi.nlm.nih.gov:80/entrez/query.fcgi?cmd=Retrieve&db=PubMed&list_uids=1433542&dopt=Abstract)
78. Porter JR, Takayama TK, Defalco AJ. Traumatic posterior urethral injury and early realignment using magnetic urethral catheters. *J Urol* 1997;158(2):425-430.  
[http://www.ncbi.nlm.nih.gov:80/entrez/query.fcgi?cmd=Retrieve&db=PubMed&list\\_uids=9224316&dopt=Abstract](http://www.ncbi.nlm.nih.gov:80/entrez/query.fcgi?cmd=Retrieve&db=PubMed&list_uids=9224316&dopt=Abstract)
79. Guille F, Cipolla B, Leveque JM, Guirassy S, Olivo JF, Lobel B. Early endoscopic realignment of complete traumatic rupture of the posterior urethra. *Br J Urol* 1991;68(2):178-180.  
[http://www.ncbi.nlm.nih.gov:80/entrez/query.fcgi?cmd=Retrieve&db=PubMed&list\\_uids=1884146&dopt=Abstract](http://www.ncbi.nlm.nih.gov:80/entrez/query.fcgi?cmd=Retrieve&db=PubMed&list_uids=1884146&dopt=Abstract)
80. Gelbard MK, Heyman AM, Weintraub P. A technique for immediate realignment and catheterization of the disrupted prostatomembranous urethra. *J Urol* 1989;142(1):52-55.  
[http://www.ncbi.nlm.nih.gov:80/entrez/query.fcgi?cmd=Retrieve&db=PubMed&list\\_uids=2733109&dopt=Abstract](http://www.ncbi.nlm.nih.gov:80/entrez/query.fcgi?cmd=Retrieve&db=PubMed&list_uids=2733109&dopt=Abstract)
81. Turner-Warwick R. Complex traumatic posterior urethral strictures. *J Urol* 1977;118(4):564-574.  
[http://www.ncbi.nlm.nih.gov:80/entrez/query.fcgi?cmd=Retrieve&db=PubMed&list\\_uids=916051&dopt=Abstract](http://www.ncbi.nlm.nih.gov:80/entrez/query.fcgi?cmd=Retrieve&db=PubMed&list_uids=916051&dopt=Abstract)

82. Ragde H, McInnes GF. Transpubic repair of the severed prostatomembranous urethra. *J Urol* 1969;101(3):335-337.  
[http://www.ncbi.nlm.nih.gov:80/entrez/query.fcgi?cmd=Retrieve&db=PubMed&list\\_uids=5765881&dopt=Abstract](http://www.ncbi.nlm.nih.gov:80/entrez/query.fcgi?cmd=Retrieve&db=PubMed&list_uids=5765881&dopt=Abstract)
83. McRoberts JW, Ragde H. The severed canine posterior urethra: a study of two distinct methods of repair. *J Urol* 1970;104(5):724-729 (level of evidence: 2a).  
[http://www.ncbi.nlm.nih.gov:80/entrez/query.fcgi?cmd=Retrieve&db=PubMed&list\\_uids=4922399&dopt=Abstract](http://www.ncbi.nlm.nih.gov:80/entrez/query.fcgi?cmd=Retrieve&db=PubMed&list_uids=4922399&dopt=Abstract)
84. Gibson GR. Urological management and complications of fractured pelvis and rupture urethra. *J Urol* 1974;111(3):353-355.  
[http://www.ncbi.nlm.nih.gov:80/entrez/query.fcgi?cmd=Retrieve&db=PubMed&list\\_uids=4813576&dopt=Abstract](http://www.ncbi.nlm.nih.gov:80/entrez/query.fcgi?cmd=Retrieve&db=PubMed&list_uids=4813576&dopt=Abstract)
85. Crassweller PO, Farrow GA, Robson CJ, Russell JL, Colapinto V. Traumatic rupture of the supramembranous urethra. *J Urol* 1977;118(5):770-771.  
[http://www.ncbi.nlm.nih.gov:80/entrez/query.fcgi?cmd=Retrieve&db=PubMed&list\\_uids=562426&dopt=Abstract](http://www.ncbi.nlm.nih.gov:80/entrez/query.fcgi?cmd=Retrieve&db=PubMed&list_uids=562426&dopt=Abstract)
86. Malek RS, O'Dea MJ, Kelalis PP. Management of ruptured posterior urethra in childhood. *J Urol* 1977;117(1):105-109.  
[http://www.ncbi.nlm.nih.gov:80/entrez/query.fcgi?cmd=Retrieve&db=PubMed&list\\_uids=830957&dopt=Abstract](http://www.ncbi.nlm.nih.gov:80/entrez/query.fcgi?cmd=Retrieve&db=PubMed&list_uids=830957&dopt=Abstract)
87. Cohen JK, Berg G, Carl GH, Diamond DD. Primary endoscopic realignment following posterior urethral disruption. *J Urol* 1991;146(6):1548-1550.  
[http://www.ncbi.nlm.nih.gov:80/entrez/query.fcgi?cmd=Retrieve&db=PubMed&list\\_uids=1942338&dopt=Abstract](http://www.ncbi.nlm.nih.gov:80/entrez/query.fcgi?cmd=Retrieve&db=PubMed&list_uids=1942338&dopt=Abstract)
88. Melekos MD, Pantazakos A, Daouaher H, Papatsoris G. Primary endourologic re-establishment of urethral continuity after disruption of prostatomembranous urethra. *Urology* 1992;39(2):135-138.  
[http://www.ncbi.nlm.nih.gov:80/entrez/query.fcgi?cmd=Retrieve&db=PubMed&list\\_uids=1736505&dopt=Abstract](http://www.ncbi.nlm.nih.gov:80/entrez/query.fcgi?cmd=Retrieve&db=PubMed&list_uids=1736505&dopt=Abstract)
89. Ying-Hao S, Chuan-Liang X, Xu G, Guo-Qiang L, Jian-Guo H. Urethroscopic realignment of ruptured bulbar urethra. *J Urol* 2000;164(5):1543-1545.  
[http://www.ncbi.nlm.nih.gov:80/entrez/query.fcgi?cmd=Retrieve&db=PubMed&list\\_uids=11025700&dopt=Abstract](http://www.ncbi.nlm.nih.gov:80/entrez/query.fcgi?cmd=Retrieve&db=PubMed&list_uids=11025700&dopt=Abstract)
90. Moudouni SM, Patard JJ, Manuta A, Guiraud P, Lobel B, Guille F. Early endoscopic realignment of post-traumatic posterior urethral disruption. *Urology* 2001;57(4):628-632.  
[http://www.ncbi.nlm.nih.gov:80/entrez/query.fcgi?cmd=Retrieve&db=PubMed&list\\_uids=11306365&dopt=Abstract](http://www.ncbi.nlm.nih.gov:80/entrez/query.fcgi?cmd=Retrieve&db=PubMed&list_uids=11306365&dopt=Abstract)
91. Gheller EL, Frontera JR. Immediate primary realignment of prostatomembranous urethral disruptions using endourologic techniques. *Urology* 1997;49(4):596-599.  
[http://www.ncbi.nlm.nih.gov:80/entrez/query.fcgi?cmd=Retrieve&db=PubMed&list\\_uids=9111631&dopt=Abstract](http://www.ncbi.nlm.nih.gov:80/entrez/query.fcgi?cmd=Retrieve&db=PubMed&list_uids=9111631&dopt=Abstract)
92. Londergan TA, Gundersen LH, van Every MJ. Early fluoroscopic realignment for traumatic urethral injuries. *Urology* 1997;49(1):101-103.  
[http://www.ncbi.nlm.nih.gov:80/entrez/query.fcgi?cmd=Retrieve&db=PubMed&list\\_uids=9000194&dopt=Abstract](http://www.ncbi.nlm.nih.gov:80/entrez/query.fcgi?cmd=Retrieve&db=PubMed&list_uids=9000194&dopt=Abstract)
93. Jepson BR, Boullier JA, Moore RG, Parra RO. Traumatic posterior urethral injury and early primary endoscopic realignment: evaluation of long-term follow-up. *Urology* 1999;53(6):1205-1210.  
[http://www.ncbi.nlm.nih.gov:80/entrez/query.fcgi?cmd=Retrieve&db=PubMed&list\\_uids=10367853&dopt=Abstract](http://www.ncbi.nlm.nih.gov:80/entrez/query.fcgi?cmd=Retrieve&db=PubMed&list_uids=10367853&dopt=Abstract)
94. Sahin H, Bircan MK, Akay AF, Gocmen M, Bilici A. Endoscopic treatment of complete posterior urethral obliteration. *Acta Urol Belg* 1998;66(4):21-24.  
[http://www.ncbi.nlm.nih.gov:80/entrez/query.fcgi?cmd=Retrieve&db=PubMed&list\\_uids=10083629&dopt=Abstract](http://www.ncbi.nlm.nih.gov:80/entrez/query.fcgi?cmd=Retrieve&db=PubMed&list_uids=10083629&dopt=Abstract)
95. Tahan H, Randrianantenaina A, Michel F. [Treatment of complete rupture of the posterior urethra by endoscopic treatment.] *Prog Urol* 1999;9(3):489-495. [French]  
[http://www.ncbi.nlm.nih.gov:80/entrez/query.fcgi?cmd=Retrieve&db=PubMed&list\\_uids=10434323&dopt=Abstract](http://www.ncbi.nlm.nih.gov:80/entrez/query.fcgi?cmd=Retrieve&db=PubMed&list_uids=10434323&dopt=Abstract)
96. el-Abd SA. Endoscopic treatment of posttraumatic urethral obliteration: experience in 396 patients. *J Urol* 1995;153(1):67-71.  
[http://www.ncbi.nlm.nih.gov:80/entrez/query.fcgi?cmd=Retrieve&db=PubMed&list\\_uids=7966794&dopt=Abstract](http://www.ncbi.nlm.nih.gov:80/entrez/query.fcgi?cmd=Retrieve&db=PubMed&list_uids=7966794&dopt=Abstract)

97. Rehman J, Samadi D, Ricciardi R Jr, Kreutzer E. Early endoscopic realignment as primary therapy for complete posterior urethral disruptions. *J Endourol* 1998;12(3):283-289.  
[http://www.ncbi.nlm.nih.gov:80/entrez/query.fcgi?cmd=Retrieve&db=PubMed&list\\_uids=9658304&dopt=Abstract](http://www.ncbi.nlm.nih.gov:80/entrez/query.fcgi?cmd=Retrieve&db=PubMed&list_uids=9658304&dopt=Abstract)
98. Mundy AR. The role of delayed primary repair in the acute management of pelvic fracture injuries of the urethra. *Br J Urol* 1991;68(3):273-276 (level of evidence: 4).  
[http://www.ncbi.nlm.nih.gov:80/entrez/query.fcgi?cmd=Retrieve&db=PubMed&list\\_uids=1913069&dopt=Abstract](http://www.ncbi.nlm.nih.gov:80/entrez/query.fcgi?cmd=Retrieve&db=PubMed&list_uids=1913069&dopt=Abstract)
99. Weems WL. Management of genitourinary injuries in patients with pelvic fractures. *Ann Surg* 1979;189(6):717-723.  
[http://www.ncbi.nlm.nih.gov:80/entrez/query.fcgi?cmd=Retrieve&db=PubMed&list\\_uids=453943&dopt=Abstract](http://www.ncbi.nlm.nih.gov:80/entrez/query.fcgi?cmd=Retrieve&db=PubMed&list_uids=453943&dopt=Abstract)
100. Mark SD, Webster GD. Reconstruction of the failed repair of posterior urethral rupture. In: McAninch JW, ed. *Traumatic and reconstructive urology*. Philadelphia: WB Saunders, 1996: 439-451 (level of evidence: 4).
101. Webster GD, Ramon J. Repair of pelvic fracture posterior urethral defects using an elaborated perineal approach: experience with 74 cases. *J Urol* 1991;145(4):744-748.  
[http://www.ncbi.nlm.nih.gov:80/entrez/query.fcgi?cmd=Retrieve&db=PubMed&list\\_uids=2005693&dopt=Abstract](http://www.ncbi.nlm.nih.gov:80/entrez/query.fcgi?cmd=Retrieve&db=PubMed&list_uids=2005693&dopt=Abstract)
102. Webster GD. The management of complex posterior urethral strictures. *Prob Uro* 1987;1:226-247.
103. Webster GD, Ramon J, Kreder KJ. Salvage posterior urethroplasty after failed initial repair of pelvic fracture membranous urethral defects. *J Urol* 1990;144(6):1370-1372.  
[http://www.ncbi.nlm.nih.gov:80/entrez/query.fcgi?cmd=Retrieve&db=PubMed&list\\_uids=2231930&dopt=Abstract](http://www.ncbi.nlm.nih.gov:80/entrez/query.fcgi?cmd=Retrieve&db=PubMed&list_uids=2231930&dopt=Abstract)
104. MacDiarmid S, Rosario D, Chapple CR. The importance of accurate assessment and conservative management of the open bladder neck in patients with post-pelvic fracture membranous urethral distraction defects. *Br J Urol* 1995;75(1):65-67.  
[http://www.ncbi.nlm.nih.gov:80/entrez/query.fcgi?cmd=Retrieve&db=PubMed&list\\_uids=7850300&dopt=Abstract](http://www.ncbi.nlm.nih.gov:80/entrez/query.fcgi?cmd=Retrieve&db=PubMed&list_uids=7850300&dopt=Abstract)
105. Mundy AR. Results and complications of urethroplasty and its future. *Br J Urol* 1993;71(3):322-325.  
[http://www.ncbi.nlm.nih.gov/entrez/query.fcgi?cmd=Retrieve&db=PubMed&list\\_uids=8477319&dopt=Abstract](http://www.ncbi.nlm.nih.gov/entrez/query.fcgi?cmd=Retrieve&db=PubMed&list_uids=8477319&dopt=Abstract)
106. Santucci RA, Mario LA, McAninch JW. Anastomotic urethroplasty for bulbar urethral stricture: analysis of 168 patients. *J Urol* 2002;167(4):1715-1719.  
[http://www.ncbi.nlm.nih.gov/entrez/query.fcgi?cmd=Retrieve&db=PubMed&list\\_uids=11912394&dopt=Abstract](http://www.ncbi.nlm.nih.gov/entrez/query.fcgi?cmd=Retrieve&db=PubMed&list_uids=11912394&dopt=Abstract)
107. Zinman LM. The management of traumatic posterior urethral distraction defects. Editorial. *J Urol* 1997;157(2):511-512 (level of evidence: 4).  
[http://www.ncbi.nlm.nih.gov/entrez/query.fcgi?cmd=Retrieve&db=PubMed&list\\_uids=8996344&dopt=Abstract](http://www.ncbi.nlm.nih.gov/entrez/query.fcgi?cmd=Retrieve&db=PubMed&list_uids=8996344&dopt=Abstract)
108. Corriere JN Jr, Rudy DC, Benson GS. Voiding and erectile function after delayed one-stage repair of posterior urethral disruption in 50 men with fractured pelvis. *J Trauma* 1994;37(4):587-590.  
[http://www.ncbi.nlm.nih.gov/entrez/query.fcgi?cmd=Retrieve&db=PubMed&list\\_uids=7932889&dopt=Abstract](http://www.ncbi.nlm.nih.gov/entrez/query.fcgi?cmd=Retrieve&db=PubMed&list_uids=7932889&dopt=Abstract)
109. Flynn BJ, Delvecchio FC, Webster GD. Perineal repair of pelvic fracture urethral distraction defects: experience in 120 patients during the last 10 years. *J Urol*. 2003;170(5):1877-80.  
[http://www.ncbi.nlm.nih.gov/entrez/query.fcgi?cmd=Retrieve&db=pubmed&dopt=Abstract&list\\_uids=14532797&query\\_hl=15&itool=pubmed\\_docsum](http://www.ncbi.nlm.nih.gov/entrez/query.fcgi?cmd=Retrieve&db=pubmed&dopt=Abstract&list_uids=14532797&query_hl=15&itool=pubmed_docsum)
110. Fiala R, Zatura F, Vrtal R. [Personal experience with treatment of posttraumatic urethral distraction defects.] *Acta Chir Orthop Traumatol Cech* 2001;68(2):99-104. [Czech]  
[http://www.ncbi.nlm.nih.gov/entrez/query.fcgi?cmd=Retrieve&db=PubMed&list\\_uids=11706724&dopt=Abstract](http://www.ncbi.nlm.nih.gov/entrez/query.fcgi?cmd=Retrieve&db=PubMed&list_uids=11706724&dopt=Abstract)
111. Koraitim MM. The lessons of 145 posttraumatic posterior urethral strictures treated in 17 years. *J Urol* 1995;153(1):63-66.  
[http://www.ncbi.nlm.nih.gov/entrez/query.fcgi?cmd=Retrieve&db=PubMed&list\\_uids=7966793&dopt=Abstract](http://www.ncbi.nlm.nih.gov/entrez/query.fcgi?cmd=Retrieve&db=PubMed&list_uids=7966793&dopt=Abstract)

112. Podesta ML. Use of the perineal and perineal-abdominal (transpubic) approach for delayed management of pelvic fracture urethral obliterative strictures in children: long-term outcome. *J Urol* 1998;160(1):160-164.  
[http://www.ncbi.nlm.nih.gov/entrez/query.fcgi?cmd=Retrieve&db=PubMed&list\\_uids=9628640&dopt=Abstract](http://www.ncbi.nlm.nih.gov/entrez/query.fcgi?cmd=Retrieve&db=PubMed&list_uids=9628640&dopt=Abstract)
113. Hafez AT, El-Assmy A, Sarhan O, El-Hefnawy AS, Ghoneim MA. Perineal anastomotic urethroplasty for managing post-traumatic urethral strictures in children: the long-term outcome. *BJU Int*. 2005;95(3):403-406.  
[http://www.ncbi.nlm.nih.gov/entrez/query.fcgi?cmd=Retrieve&db=pubmed&dopt=Abstract&list\\_uids=15679803&query\\_hl=10&itool=pubmed\\_docsum](http://www.ncbi.nlm.nih.gov/entrez/query.fcgi?cmd=Retrieve&db=pubmed&dopt=Abstract&list_uids=15679803&query_hl=10&itool=pubmed_docsum)
114. Wadhwa SN, Chahal R, Hemal AK, Gupta NP, Dogra PN, Seth A. Management of obliterative posttraumatic posterior urethral strictures after failed initial urethroplasty. *J Urol* 1998;159(6):1898-1902.  
[http://www.ncbi.nlm.nih.gov/entrez/query.fcgi?cmd=Retrieve&db=PubMed&list\\_uids=9598483&dopt=Abstract](http://www.ncbi.nlm.nih.gov/entrez/query.fcgi?cmd=Retrieve&db=PubMed&list_uids=9598483&dopt=Abstract)
115. Smith JC. The measurement and significance of the urinary flow rate. *Br J Urol* 1966;38(6):701-706.  
[http://www.ncbi.nlm.nih.gov/entrez/query.fcgi?cmd=Retrieve&db=PubMed&list\\_uids=4163385&dopt=Abstract](http://www.ncbi.nlm.nih.gov/entrez/query.fcgi?cmd=Retrieve&db=PubMed&list_uids=4163385&dopt=Abstract)
116. Sachse H. Zur behandlung der Harnrohrenstriktur: Die transuretrale schlitzung unter Sicht mit scharfem Schnitt. *Fortschr Med* 1974;92:12-15 [German].
117. Blandy JP. Urethral stricture. *Postgrad Med J* 1980;56(656):383-418 (level of evidence: 4).  
[http://www.ncbi.nlm.nih.gov/entrez/query.fcgi?cmd=Retrieve&db=PubMed&list\\_uids=6997851&dopt=Abstract](http://www.ncbi.nlm.nih.gov/entrez/query.fcgi?cmd=Retrieve&db=PubMed&list_uids=6997851&dopt=Abstract)
118. Lieberman SF, Barry JM. Retreat from transpubic urethroplasty for obliterated membranous urethral strictures. *J Urol* 1982;128(2):379-381.  
[http://www.ncbi.nlm.nih.gov/entrez/query.fcgi?cmd=Retrieve&db=PubMed&list\\_uids=7109114&dopt=Abstract](http://www.ncbi.nlm.nih.gov/entrez/query.fcgi?cmd=Retrieve&db=PubMed&list_uids=7109114&dopt=Abstract)
119. Gupta NP, Gill IS. Core-through optical internal urethrotomy in management of impassable traumatic posterior urethral strictures. *J Urol* 1986;136(5):1018-1021.  
[http://www.ncbi.nlm.nih.gov/entrez/query.fcgi?cmd=Retrieve&db=PubMed&list\\_uids=3773060&dopt=Abstract](http://www.ncbi.nlm.nih.gov/entrez/query.fcgi?cmd=Retrieve&db=PubMed&list_uids=3773060&dopt=Abstract)
120. Chiou RK, Gonzalez R, Ortlip S, Fraley EE. Endoscopic treatment of posterior urethral obliteration: long-term follow-up and comparison with transpubic urethroplasty. *J Urol* 1988;140(3):508-511.  
[http://www.ncbi.nlm.nih.gov/entrez/query.fcgi?cmd=Retrieve&db=PubMed&list\\_uids=3411662&dopt=Abstract](http://www.ncbi.nlm.nih.gov/entrez/query.fcgi?cmd=Retrieve&db=PubMed&list_uids=3411662&dopt=Abstract)
121. Marshall FF. Endoscopic reconstruction of traumatic urethral transections. *Urol Clin North Am* 1989;16(2):313-318 (level of evidence: 4).  
[http://www.ncbi.nlm.nih.gov/entrez/query.fcgi?cmd=Retrieve&db=PubMed&list\\_uids=2711549&dopt=Abstract](http://www.ncbi.nlm.nih.gov/entrez/query.fcgi?cmd=Retrieve&db=PubMed&list_uids=2711549&dopt=Abstract)
122. Barry JM. Visual urethrotomy in the management of the obliterated membranous urethra. *Urol Clin North Am* 1989;16(2):319-324 (level of evidence: 4).  
[http://www.ncbi.nlm.nih.gov/entrez/query.fcgi?cmd=Retrieve&db=PubMed&list\\_uids=2711550&dopt=Abstract](http://www.ncbi.nlm.nih.gov/entrez/query.fcgi?cmd=Retrieve&db=PubMed&list_uids=2711550&dopt=Abstract)
123. deVries CR, Anderson RU. Endoscopic urethroplasty: an improved technique. *J Urol* 1990;143(6):1225-1226.  
[http://www.ncbi.nlm.nih.gov/entrez/query.fcgi?cmd=Retrieve&db=PubMed&list\\_uids=2342187&dopt=Abstract](http://www.ncbi.nlm.nih.gov/entrez/query.fcgi?cmd=Retrieve&db=PubMed&list_uids=2342187&dopt=Abstract)
124. Leonard MP, Emtage J, Perez R, Morales A. Endoscopic management of urethral stricture: "cut to the light" procedure. *Urology* 1990;35(2):117-120.  
[http://www.ncbi.nlm.nih.gov/entrez/query.fcgi?cmd=Retrieve&db=PubMed&list\\_uids=2305533&dopt=Abstract](http://www.ncbi.nlm.nih.gov/entrez/query.fcgi?cmd=Retrieve&db=PubMed&list_uids=2305533&dopt=Abstract)
125. Kernohan RM, Anwar KK, Johnston SR. Complete urethral stricture of the membranous urethra: a different perspective. *Br J Urol* 1990;65(1):51-54.  
[http://www.ncbi.nlm.nih.gov/entrez/query.fcgi?cmd=Retrieve&db=PubMed&list\\_uids=2310932&dopt=Abstract](http://www.ncbi.nlm.nih.gov/entrez/query.fcgi?cmd=Retrieve&db=PubMed&list_uids=2310932&dopt=Abstract)
126. Yasuda T, Yamanishi T, Isaka S, Okano T, Masai M, Shimazaki J. Endoscopic re-establishment of membranous urethral disruption. *J Urol* 1991;145(5):977-979.  
[http://www.ncbi.nlm.nih.gov/entrez/query.fcgi?cmd=Retrieve&db=PubMed&list\\_uids=2016813&dopt=Abstract](http://www.ncbi.nlm.nih.gov/entrez/query.fcgi?cmd=Retrieve&db=PubMed&list_uids=2016813&dopt=Abstract)

127. Quint HJ, Stanisis TH. Above and below delayed endoscopic treatment of traumatic posterior urethral disruptions. *J Urol* 1993;149(3):484-487.  
[http://www.ncbi.nlm.nih.gov/entrez/query.fcgi?cmd=Retrieve&db=PubMed&list\\_uids=8437251&dopt=Abstract](http://www.ncbi.nlm.nih.gov/entrez/query.fcgi?cmd=Retrieve&db=PubMed&list_uids=8437251&dopt=Abstract)
128. Goel MC, Kumar M, Kapoor R. Endoscopic management of traumatic posterior urethral stricture: early results and followup. *J Urol* 1997;157(1):95-97.  
[http://www.ncbi.nlm.nih.gov/entrez/query.fcgi?cmd=Retrieve&db=PubMed&list\\_uids=8976224&dopt=Abstract](http://www.ncbi.nlm.nih.gov/entrez/query.fcgi?cmd=Retrieve&db=PubMed&list_uids=8976224&dopt=Abstract)
129. Dogra PN, Nabi G. Core-through urethrotomy using the neodymium : YAG laser for obliterative urethral strictures after traumatic urethral disruption and/or distraction defects: long-term outcome. *J Urol* 2002;167(2 Pt 1):543-546.  
[http://www.ncbi.nlm.nih.gov/entrez/query.fcgi?cmd=Retrieve&db=PubMed&list\\_uids=11792915&dopt=Abstract](http://www.ncbi.nlm.nih.gov/entrez/query.fcgi?cmd=Retrieve&db=PubMed&list_uids=11792915&dopt=Abstract)
130. Levine J, Wessells H. Comparison of open and endoscopic treatment of posttraumatic posterior urethral strictures. *World J Surg* 2001;25(12):1597-1601 (level of evidence: 2b).  
[http://www.ncbi.nlm.nih.gov/entrez/query.fcgi?cmd=Retrieve&db=PubMed&list\\_uids=11775198&dopt=Abstract](http://www.ncbi.nlm.nih.gov/entrez/query.fcgi?cmd=Retrieve&db=PubMed&list_uids=11775198&dopt=Abstract)
131. Pansadoro V, Emiliozzi P. Internal urethrotomy in the management of anterior urethral strictures: long-term follow-up. *J Urol* 1996;156(1):73-75.  
[http://www.ncbi.nlm.nih.gov/entrez/query.fcgi?cmd=Retrieve&db=PubMed&list\\_uids=8648841&dopt=Abstract](http://www.ncbi.nlm.nih.gov/entrez/query.fcgi?cmd=Retrieve&db=PubMed&list_uids=8648841&dopt=Abstract)
132. Williams G. Stents in the lower urinary tract. *Am Urol Assoc Update Ser* 1993;12:26.
133. Milroy EJ, Chapple CR, Eldin A, Wallsten N. A new treatment for urethral strictures - a permanently implanted urethral stent. *J Urol* 1989;141(5):1120-1122.  
[http://www.ncbi.nlm.nih.gov/entrez/query.fcgi?cmd=Retrieve&db=PubMed&list\\_uids=2709498&dopt=Abstract](http://www.ncbi.nlm.nih.gov/entrez/query.fcgi?cmd=Retrieve&db=PubMed&list_uids=2709498&dopt=Abstract)
134. Baert L, Verhamme L, Van Poppel H, Vandeursen H, Baert J. Long-term consequences of urethral stents. *J Urol* 1993;150(3):853-855.  
[http://www.ncbi.nlm.nih.gov/entrez/query.fcgi?cmd=Retrieve&db=PubMed&list\\_uids=8345599&dopt=Abstract](http://www.ncbi.nlm.nih.gov/entrez/query.fcgi?cmd=Retrieve&db=PubMed&list_uids=8345599&dopt=Abstract)

## 5. GENITAL TRAUMA

### 5.1 Background

Traumatic injuries to the genitourinary tract are seen in 2.2-10.3% of patients admitted to hospitals (1-5). Of these injuries, between one-third and two-thirds of cases are associated with injuries to the external genitalia (1). The incidence of genital trauma is higher in men than in women, not only because of anatomical differences but also due to increased exposure to violence, performance of aggressive sports and motor vehicle accidents. In addition, an increase in domestic violence has led to an increase in gunshot and stab wounds over the last several years (6-9). Approximately 35% of all gunshot wounds are affiliated with genital injuries (10).

Genitourinary trauma is seen in all age groups, most frequently in males between 15-40 years. However, 5% of patients are less than 10 years old (10). Genitourinary trauma is commonly caused by blunt injuries (80%), whereas 20% concern penetrating lesions. Again, blunt injuries to the external genitalia occur more frequently in men than women. However, the risk of associated injuries to neighbouring organs (bladder, urethra, vagina, rectum, bowel) after blunt genital trauma is higher in females than in males.

In men, blunt genital trauma frequently occurs unilaterally with only 1% of cases presenting as bilateral scrotal and/or testicular injuries (10). However, penetrating scrotal injuries affect both testes in 30% of cases (10,11). Besides locally extended lesions associated with penetrating trauma, there is 70% risk of additional injuries in both genders.

The accurate diagnosis and treatment of patients with penetrating injuries are of utmost importance. However, it is essential that physicians and nurses treating trauma patients are aware of an increased risk of hepatitis B and/or C infection (7). A recent investigation in males with penetrating gunshot or stab wounds to the external genitalia reported a 38% infection rate with hepatitis B and/or C (7). The percentage was significantly higher than the incidence of hepatitis infection in the normal population, thus exposing emergency staff to an increased risk.

## 5.2 Pathophysiology

Proper management of genital trauma requires information about the accident, possibly involved other persons, animals, vehicles and weapons (stab, knife, gun, etc.) in order to estimate the injury and potential risk of associated lesions.

### 5.2.1 Blunt trauma

In males, a direct blow to the erect penis may cause penile fracture, frequently occurring during consensual intercourse, which accounts for approximately 60% of penile fractures (12). Penile fracture is caused by rupturing of the cavernosal tunica albuginea and may be associated with lesions of the corpus spongiosum and urethra in 10-22% (13,14). Usually the penis slips out of the vagina and strikes against the symphysis pubis or perineum.

Due to the thickness of the tunica albuginea in the flaccid state (approximately 2 mm), blunt trauma to the penis does not usually cause tearing of the tunica when there is no tumescence and rigidity. In these cases, only subcutaneous haematoma may be seen.

Blunt trauma to the scrotum can cause testicular dislocation, testicular rupture and/or subcutaneous scrotal haematoma. Overall, traumatic dislocation of the testicle occurs rarely, in victims of car or motor cycle accidents, or in pedestrians run over by a vehicle (15-18). Bilateral dislocation of the testes has been reported in up to 25% the cases (18). It can be classified as:

1. Subcutaneous dislocation with epifascial displacement of the testis
2. Internal dislocation; in these cases, the testis is positioned in the superficial external inguinal ring, inguinal canal or abdominal cavity.

Testicular rupture is found in approximately 50% of blunt traumas to the scrotum (19). It can occur under intense, traumatic compression of the testis against the inferior pubic ramus or symphysis, resulting in a rupture of the tunica albuginea of the testis. Wasko and Goldstein estimated that a force of approximately 50 kg is necessary to cause testicular rupture (20).

In females, blunt trauma to the vulva is rarely reported. The incidence of traumatic vulvar haematomas after vaginal deliveries was reported as 1 in 310 deliveries (21). The frequency in non-obstetric vulvar haematomas is even lower with only several cases reported (22). Although blunt trauma to the female external genital is rarely reported, the presence of vulvar haematoma is closely related to an increased risk of associated vaginal, pelvic or abdominal injuries. Goldman et al. reported on blunt injuries of the vulva and vagina associated with pelvic trauma in 30%, consensual intercourse in 25%, sexual assault in 20% and other blunt trauma in 15% (23).

### 5.2.2 Penetrating trauma

Penetrating trauma to the external genitalia is frequently associated with complex injuries of other organs. In children, penetrating injuries are most frequently seen after straddle-type falls or laceration of genital skin due to falls on sharp objects (10,24).

Increasing domestic violence has led to the incidence of stab and/or gunshot injuries associated with injuries of the genitourinary tract. The extent of injuries associated with guns is related to the calibre and velocity of the missile (8). Handguns or pistols range from 0.22 to 0.45 calibre with a velocity of 200-300 m/s. In addition, magnum handguns transmit 20-60% more energy than standard handgun to the tissue due to the higher velocity of the missile. Injuries by rifles cause even more extensive lesions. Rifles have a calibre ranging from 0.17 to 0.460 with a kinetic energy transmission of up to 1000 m/s.

Missiles with a velocity of approximately 200-300 m/s are considered as low velocity inducing a 'permanent cavity'. The energy along the projectile path transmitted to the tissue is much less than in high-velocity missiles, so that tissue destruction in low-velocity guns is less extensive (8). On the contrary, high-velocity missiles (velocity of 800-1000 m/s) have an explosive effect with high-energy transmission to the tissue causing a 'temporary cavity'. Due to the high-energy released, gaseous tissue vaporization induces extensive damage often associated with life-threatening injuries.

In relation to the weapon, calibre and configuration of the missile, gunshot wounds are classified as penetrating, perforating and avulsive. Penetrating injuries are caused by low-velocity missiles, with bullets often retained in the tissue and a small, ragged entry wound. Perforating gunshot wounds are frequently seen in low- to high-velocity missiles. In these cases, the missile passes through the tissue with a small entry wound, but larger, exit one. Serious injuries are associated with avulsive gunshot wounds caused by high-velocity missiles, with a small entry wound comparable to the calibre but a large tissue defect at the exit wound.

In any penetrating trauma, tetanus vaccination is mandatory and should be performed by active (tetanus toxoid booster) and passive immunization (250 IE human tetanus immunoglobulin) if the patient's last immunization was given more than 5 years ago (25). For current recommendations for tetanus vaccination, see information from the Robert Koch Institute, Germany (<http://www.rki.de/INFEKT/INFEKT.HTM>). Although animal bites are common, bites involving injury to the external genital are rare. Wounds are usually minor but there is a



potential risk of serious wound infection. The most common bacterial infection by a dog bite is *Pasturella multocida* which accounts for up to 50% of infections (25). Other micro-organisms commonly involved are *Escherichia coli*, *Streptococcus viridans*, *Staphylococcus aureus*, *Bacteroides* and *Fusobacterium spp.* (25,26). The first choice of antibiotics is penicillin followed by cephalosporin or erythromycin.

In any case of animal bites, one has to consider the possibility of rabies infection. In the case of domestic presence of rabies, vaccination must be given to prevent life-threatening infection (27). Besides vaccination, local wound management is an essential part of post-exposure rabies prophylaxis. If rabies infection is suspected, vaccination should be considered in relation to the animal involved, specific nature of the wound and attack (provoked/unprovoked) and the appearance of the animal (aggressive, foam at the mouth). Presently, vaccination with human rabies immunoglobulin and human diploid cell vaccine is recommended (27,28).

### 5.3 Risk factors

There are certain sports gaining in popularity which are associated with an increase in genital trauma. Off-road bicycling and motorbike riding, especially on bikes with a dominant petrol tank, accidents from in-line hockey skating and rugby footballers have been associated with blunt testicular trauma (29-32). Any kind of full-contact sports, without the use of necessary protective aids, may be associated with genital trauma. Besides these risk groups, self-mutilation of the external genitalia have also been reported in psychotic patients and transsexuals (26).

### 5.4 Diagnosis

Investigating genital trauma requires information concerning the accident and a thorough clinical examination. Since an abusive assault may be related with genital injury, investigation must consider the intimacy of the patient. In suspicious cases, swabs or vaginal smears should be taken for detection of spermatozoa (24). In penetrating injuries or gunshot wounds, it is important to obtain information concerning the penetrating object or involved guns, distance of entrance of the missile, calibre and size of the bullet.

An urinalysis is required; the presence of macro- and or microhaematuria in genital trauma indicate the performance of a retrograde urethrography in males (see above 4. Urethral trauma). In females, the performance of flexible or rigid cystoscopy has been recommended to exclude urethral and bladder injury (23,33).

In women with genital injuries and blood at the vaginal introitus, it has been repeatedly emphasized that this may not only be due to menstrual bleeding, but necessitates further investigation to exclude vaginal injuries (33). Complete vaginal inspection with specula is mandatory which, because of pain, should be carried out under sedation or general anaesthesia in most cases.

#### 5.4.1 Blunt penile trauma

##### 5.4.1.1 Penile fracture

These patients report a sudden cracking or popping sound associated with local pain and immediate detumescence. As a result, local swelling of the penile shaft develops with progressive haematoma that may occur along fascial layers of the penile shaft extending to the lower abdominal wall in case of rupture of Buck's fascia.

Depending on the extent of the haematoma, rupturing of the tunica may be palpated. Besides the history and clinical examination, imaging may be performed by cavernosography and magnetic resonance imaging (MRI) (34,35). Both techniques can identify laceration of the tunica albuginea. Recent reports have supported the role of MRI as being particularly helpful in determining the need for surgical intervention, which is based on the integrity of the tunica albuginea (36). Associated injuries to adjacent structures (e.g. corpus spongiosum, urethra) can also be demonstrated. In the case of tunical laceration, surgical correction with suturing of the ruptured area is indicated. In patients without penile fracture, MRI can demonstrate an intact tunica albuginea and the presence of intracavernosal or extratunical haematoma. It remains uncertain whether the routine use of contrast material-enhanced MRI is justified (37). Presently, cavernosography and/or MRI are the most accurate imaging procedures in cases where penile fracture is suspected but the clinical findings are unclear (38).

#### 5.4.2 Blunt testicular trauma

Patients report immediate scrotal pain, nausea, vomiting and sometimes they faint. They often present with a tender, swollen scrotum and a palpatory, indistinguishable testis. High-resolution, real-time ultrasonography with a 7.5-10 MHz probe should be performed to determine intra- and/or extratesticular bleeding, testicular contusion or rupture (39-46). However, contradictory results have been presented regarding the usefulness of ultrasonography in testicular trauma. Some studies have reported convincing results with high accuracy of 94% (26,39,44,45), whereas results by others have been disappointing regarding specificity and sensitivity for determination of testicular rupture - as low as 78% and 28%, respectively (42). Some found that the overall

accuracy of scrotal ultrasound for determination of testicular rupture was only 56%, irrespective of the investigator (42). However, grayscale ultrasonography has been recommended by various groups with good reliability.

Although accuracy has been satisfactory, results must be interpreted carefully to avoid misinterpretation of the imaging obtained. Information may be increased by colour doppler-duplex ultrasonography to evaluate testicular perfusion. In the case of inconclusive scrotal sonography, testicular computed tomography (CT) or MRI may be helpful in elucidating scrotal dilemmas (47). However, these techniques did not specifically increase the detection of testicular rupture. The time-delay associated with imaging studies has to be weighed against the reliability of information in order to decide whether or not surgical exploration is indicated.

If imaging studies cannot exclude testicular rupture, surgical exploration should be initiated.

#### 5.4.3 *Blunt female trauma*

In females with blunt trauma to the external genitalia, imaging studies of the pelvis with CT or MRI should be performed since additional injuries and extensive intrapelvic haematoma are frequently seen (24,33).

#### 5.4.4 *Penetrating trauma*

In penetrating trauma of the external genital in men, urethrography should be performed in any case, irrespective of urinalysis. Additionally, abdominal CT, with or without cystography, should be performed in both men and women.

In females, the use of laparoscopy for identification of intraperitoneal injuries has been reported prior to explorative laparotomy (24). This approach is only reasonable in haemodynamic stable patients, in whom CT cannot exclude the presence of associated bowel injuries or intra-abdominal bleeding.

### 5.5 **Treatment**

#### 5.5.1 *Penile trauma*

##### 5.5.1.1 *Blunt trauma*

The presence of subcutaneous haematoma, without rupturing of the cavernosal tunica albuginea and no immediate detumescence of the erect penis, does not require surgical intervention. In these cases, non-steroidal analgesics and ice-packs are recommended.

This can be easily distinguished from penile fracture with post-traumatic flaccidity. In the case of penile fracture, immediate surgical intervention with closure of the tunica albuginea is recommended. Closure can be obtained by using either absorbable or non-absorbable sutures, with good long-term outcome and protection of potency. Post-operative complications were seen in 9%, including superficial wound infection and impotence in 1.3% (12,48). Conservative management of penile fractures are not recommended due to reported complications, including penile abscess, missed partial urethral disruption, penile curvature and persistent haematoma requiring delayed surgical intervention (48). Late complications after conservative management were fibrosis and angulations in 35% (12,48).

##### 5.5.1.2 *Penetrating trauma*

In penetrating penile trauma, surgical exploration and conservative debridement of necrotic tissue is recommended with primary closure in most cases. Even in extended injuries of the penis or complete dissection, primary realignment should be obtained by the aid of a skilled microsurgeon because of the excellent blood supply of penile tissues (26). In extended loss of penile shaft skin, split-thickness grafts can be utilized after infectious control. McAnich et al. recommended the use of a skin graft thickness of at least 0.001 mm in order to reduce the risk of skin contractions that may restrict the penile enlargement during erection (26). Additionally, grafts should be placed circumferentially to the artificially erected penis for avoidance of contracture and penile shortening. Placement of suprapubic cystostomy for bladder drainage may be considered in most cases for prevention of wound infection in addition to antibiotics.

#### 5.5.2 *Testicular trauma*

##### 5.5.2.1 *Blunt trauma*

Blunt trauma to the scrotum can cause significant haematocele without testicular rupture. Conservative management can be performed in haematoceles smaller than three times the size of the contralateral testis (6). Several studies have shown that conservative management requires delayed interventions (> 3 days) in many cases with a significantly higher rate of orchiectomy even in non-ruptured testis (10,19,26,49,50). Complications indicating surgery were infections and pain. It has been clearly shown that early surgical intervention resulted in > 90% preservation of the testis whereas delayed surgery necessitated orchiectomy in 45-55% (19). Additionally, duration of hospital stay is markedly reduced emphasising early surgical intervention

even in large haematoceles. Therefore, generous indication of surgical exploration is advocated in haematocele, irrespective of testicle contusion or rupture. At the very least, the blood-clot should be evacuated from the tunica vaginalis sac to relieve disability and hasten recovery.

In cases of testicular rupture, surgical exploration with excision of necrotic testicular tubules and closure of the tunica albuginea is mandatory. This guarantees a high rate of testicular preservation and normal endocrine function. The additional use of antibiotics and antiphlogistics has been recommended.

Traumatic dislocation of the testis can be manually replaced but secondary surgical subcutaneous fixation of the entrance into the scrotum from the spermatic cord is recommended. If manual reposition cannot be performed, orchidopexy should be carried out.

#### 5.5.2.2 Penetrating trauma

Penetrating injuries to the scrotum need surgical exploration with conservative debridement of non-viable tissue. Again, depending on the extent of the injury, primary reconstruction for both the testis and scrotum should be carried out in most cases. In case of complete disruption of the spermatic cord, realignment without vaso-vasostomy can be performed in the haemodynamic stable patient if surgically feasible (51). If there is extensive destruction of the tunica albuginea, mobilization of a free tunica vaginalis flap can be obtained for testicular closure. If the patient is unstable or reconstruction cannot be achieved, orchiectomy should be performed. Staged secondary microsurgical vaso-vasostomy can be performed after rehabilitation, though there are only a few data reported (51). The application of antibiotics is recommended in any case of penetrating trauma in addition to tetanus prophylaxis.

Extended laceration of scrotal skin requires surgical intervention for skin closure. Due to the elasticity of the scrotum, most defects can be primarily closed, even if the lacerated skin is only minimally attached to the body (26). Recreation of scrotal skin is usually high, indicating conservative debridement and primary realignment in most cases. However, local wound management with extensive rinsing of the wound is an important fact for scrotal convalescence. Even in cases of complete disruption of scrotal skin, it can be realigned after debridement and washing. Extensive resection of fatty skin is not indicated due to the lack of subcutaneous fatty tissue in the scrotum (26). In addition, it has an associated risk of harming the vascular plexus in the stratum reticulare. Partial necrosis of full-thickness skin grafts may occur, indicating resection and staged closure with split-thickness grafts or, depending upon the extent of the defect, secondary granulation of the wound.

#### 5.5.3 Vulvar injuries

Blunt trauma to the vulva are rare and commonly present as extended haematomas. However, in contrast to men, blunt trauma may be associated with voiding problems. In case of absent bladder trauma, transurethral catheterization is indicated. In associated bladder trauma, suprapubic cystostomy may be required after cystography or CT-cystography (see Guidelines for Bladder Trauma). Vulvar haematomas do not require surgical intervention in most cases, though they can cause significant blood loss requiring red blood cell transfusions. The reported data are scarce, making recommendations for local wound management difficult (22-24,33). In haemodynamically stable women, non-steroidal antirheumatics and cold packs relieve pain, requiring no surgical intervention in the majority of the cases. In extended vulvar haematoma or haemodynamic unstable patients, surgical intervention may be indicated. The additional use of antibiotics is recommended in major vulvar trauma. Again, it is important to emphasize that vulvar haematoma and/or blood at the vaginal introitus are an indication for vaginal exploration in order to identify possible associated vaginal and/or rectal injuries under sedation or general anaesthesia (33). In case of vulvar laceration, realignment after conservative debridement is indicated. If there are associated injuries to the vagina, these can be repaired immediately by primary suturing. Additional injuries to the bladder, rectum or bowel may require laparotomy for closure and, in case of rectal injuries, may necessitate transient colostomy.

## 5.6 REFERENCES

1. Brandes SB, Buckman RF, Chelsky MJ, Hanno PM. External genitalia gunshot wounds: a ten-year experience with fifty-six cases. *J Trauma* 1995;39(2):266-271 (level of evidence: 3).  
[http://www.ncbi.nlm.nih.gov/entrez/query.fcgi?cmd=Retrieve&db=PubMed&list\\_uids=7674395&dopt=Abstract](http://www.ncbi.nlm.nih.gov/entrez/query.fcgi?cmd=Retrieve&db=PubMed&list_uids=7674395&dopt=Abstract)
2. Marekovic Z, Derežic D, Krhen I, Kastelan Z. Urogenital war injuries. *Mil Med* 1997;162(5):346-348 (level of evidence: 3).  
[http://www.ncbi.nlm.nih.gov/entrez/query.fcgi?cmd=Retrieve&db=PubMed&list\\_uids=9155106&dopt=Abstract](http://www.ncbi.nlm.nih.gov/entrez/query.fcgi?cmd=Retrieve&db=PubMed&list_uids=9155106&dopt=Abstract)

3. Salvatierra O Jr, Rigdon WO, Norris DM, Brady TW. Vietnam experience with 252 urological war injuries. *J Urol* 1969;101(4):615-620 (level of evidence: 3).  
[http://www.ncbi.nlm.nih.gov/entrez/query.fcgi?cmd=Retrieve&db=PubMed&list\\_uids=5776049&dopt=Abstract](http://www.ncbi.nlm.nih.gov/entrez/query.fcgi?cmd=Retrieve&db=PubMed&list_uids=5776049&dopt=Abstract)
4. Tucak A, Lukacevic T, Kuvezdic H, Petek Z, Novak R. Urogenital wounds during the war in Croatia in 1991/1992. *J Urol* 1995;153(1):121-122 (level of evidence: 3).  
[http://www.ncbi.nlm.nih.gov/entrez/query.fcgi?cmd=Retrieve&db=PubMed&list\\_uids=7966742&dopt=Abstract](http://www.ncbi.nlm.nih.gov/entrez/query.fcgi?cmd=Retrieve&db=PubMed&list_uids=7966742&dopt=Abstract)
5. Archbold JA, Barros d'sa AA, Morrison E. Genito-urinary tract injuries of civil hostilities. *Br J Surg* 1981;68(9):625-631 (level of evidence: 3).  
[http://www.ncbi.nlm.nih.gov/entrez/query.fcgi?cmd=Retrieve&db=PubMed&list\\_uids=7272689&dopt=Abstract](http://www.ncbi.nlm.nih.gov/entrez/query.fcgi?cmd=Retrieve&db=PubMed&list_uids=7272689&dopt=Abstract)
6. Tiguert R, Harb JF, Hurley PM, Gomes De Oliveira J, Castillo-Frontera RJ, Triest JA, Gheiler EL. Management of shotgun injuries to the pelvis and lower genitourinary system. *Urology* 2000;55(2):193-197 (level of evidence: 3).  
[http://www.ncbi.nlm.nih.gov/entrez/query.fcgi?cmd=Retrieve&db=PubMed&list\\_uids=10688077&dopt=Abstract](http://www.ncbi.nlm.nih.gov/entrez/query.fcgi?cmd=Retrieve&db=PubMed&list_uids=10688077&dopt=Abstract)
7. Cline KJ, Mata JA, Venable DD, Eastham JA. Penetrating trauma to the male external genitalia. *J Trauma* 1998;44(3):492-494 (level of evidence: 3).  
[http://www.ncbi.nlm.nih.gov/entrez/query.fcgi?cmd=Retrieve&db=PubMed&list\\_uids=9529176&dopt=Abstract](http://www.ncbi.nlm.nih.gov/entrez/query.fcgi?cmd=Retrieve&db=PubMed&list_uids=9529176&dopt=Abstract)
8. Jolly BB, Sharma SK, Vaidyanathan S, Mandal AK. Gunshot wounds of the male external genitalia. *Urol Int* 1994;53(2):92-96 (level of evidence: 3).  
[http://www.ncbi.nlm.nih.gov/entrez/query.fcgi?cmd=Retrieve&db=PubMed&list\\_uids=7801424&dopt=Abstract](http://www.ncbi.nlm.nih.gov/entrez/query.fcgi?cmd=Retrieve&db=PubMed&list_uids=7801424&dopt=Abstract)
9. Bertini JE Jr, Corriere JN Jr. The etiology and management of genital injuries. *J Trauma* 1988;28(8):1278-1281 (level of evidence: 3).  
[http://www.ncbi.nlm.nih.gov/entrez/query.fcgi?cmd=Retrieve&db=PubMed&list\\_uids=3411650&dopt=Abstract](http://www.ncbi.nlm.nih.gov/entrez/query.fcgi?cmd=Retrieve&db=PubMed&list_uids=3411650&dopt=Abstract)
10. Monga M, Hellstrom WJ. Testicular trauma. *Adolesc Med* 1996;7(1):141-148 (level of evidence: 4).  
[http://www.ncbi.nlm.nih.gov/entrez/query.fcgi?cmd=Retrieve&db=PubMed&list\\_uids=10359963&dopt=Abstract](http://www.ncbi.nlm.nih.gov/entrez/query.fcgi?cmd=Retrieve&db=PubMed&list_uids=10359963&dopt=Abstract)
11. Cass AS, Ferrara L, Wolpert J, Lee J. Bilateral testicular injury from external trauma. *J Urol* 1988;140(6):1435-1436 (level of evidence: 3).  
[http://www.ncbi.nlm.nih.gov/entrez/query.fcgi?cmd=Retrieve&db=pubmed&dopt=Abstract&list\\_uids=3193512&query\\_hl=34&itool=pubmed\\_docsum](http://www.ncbi.nlm.nih.gov/entrez/query.fcgi?cmd=Retrieve&db=pubmed&dopt=Abstract&list_uids=3193512&query_hl=34&itool=pubmed_docsum)
12. Haas CA, Brown SL, Spirnak JP. Penile fracture and testicular rupture. *World J Urol* 1999;17(2):101-106 (level of evidence: 4).  
[http://www.ncbi.nlm.nih.gov/entrez/query.fcgi?cmd=Retrieve&db=PubMed&list\\_uids=10367369&dopt=Abstract](http://www.ncbi.nlm.nih.gov/entrez/query.fcgi?cmd=Retrieve&db=PubMed&list_uids=10367369&dopt=Abstract)
13. Nicolaisen GS, Melamud A, Williams RD, McAninch JW. Rupture of the corpus cavernosum: surgical management. *J Urol* 1983;130(5):917-919 (level of evidence: 3).  
[http://www.ncbi.nlm.nih.gov/entrez/query.fcgi?cmd=Retrieve&db=pubmed&dopt=Abstract&list\\_uids=6632099&query\\_hl=36&itool=pubmed\\_docsum](http://www.ncbi.nlm.nih.gov/entrez/query.fcgi?cmd=Retrieve&db=pubmed&dopt=Abstract&list_uids=6632099&query_hl=36&itool=pubmed_docsum)
14. Tsang T, Demby AM. Penile fracture with urethral injury. *J Urol* 1992;147(2):466-468 (level of evidence: 3).  
[http://www.ncbi.nlm.nih.gov/entrez/query.fcgi?cmd=Retrieve&db=PubMed&list\\_uids=1732623&dopt=Abstract](http://www.ncbi.nlm.nih.gov/entrez/query.fcgi?cmd=Retrieve&db=PubMed&list_uids=1732623&dopt=Abstract)
15. Lee JY, Cass AS, Streitz JM. Traumatic dislocation of testes and bladder rupture. *Urology* 1992;40(6):506-508 (level of evidence: 3).  
[http://www.ncbi.nlm.nih.gov/entrez/query.fcgi?cmd=Retrieve&db=PubMed&list\\_uids=1466102&dopt=Abstract](http://www.ncbi.nlm.nih.gov/entrez/query.fcgi?cmd=Retrieve&db=PubMed&list_uids=1466102&dopt=Abstract)
16. Shefi S, Mor Y, Dotan ZA, Ramon J. Traumatic testicular dislocation: a case report and review of published reports. *Urology* 1999;54(4):744 (level of evidence: 3).  
[http://www.ncbi.nlm.nih.gov/entrez/query.fcgi?cmd=Retrieve&db=PubMed&list\\_uids=10754145&dopt=Abstract](http://www.ncbi.nlm.nih.gov/entrez/query.fcgi?cmd=Retrieve&db=PubMed&list_uids=10754145&dopt=Abstract)
17. Pollen JJ, Funckes C. Traumatic dislocation of the testes. *J Trauma* 1982;22(3):247-249 (level of evidence: 3).  
[http://www.ncbi.nlm.nih.gov/entrez/query.fcgi?cmd=Retrieve&db=pubmed&dopt=Abstract&list\\_uids=7069812&query\\_hl=40&itool=pubmed\\_docsum](http://www.ncbi.nlm.nih.gov/entrez/query.fcgi?cmd=Retrieve&db=pubmed&dopt=Abstract&list_uids=7069812&query_hl=40&itool=pubmed_docsum)

18. Nagarajan VP, Pranikoff K, Imahori SC, Rabinowitz R. Traumatic dislocation of testis. *Urology* 1983;22(5):521-524 (level of evidence: 3).  
[http://www.ncbi.nlm.nih.gov/entrez/query.fcgi?cmd=Retrieve&db=pubmed&dopt=Abstract&list\\_uids=6649208&query\\_hl=42&itool=pubmed\\_docsum](http://www.ncbi.nlm.nih.gov/entrez/query.fcgi?cmd=Retrieve&db=pubmed&dopt=Abstract&list_uids=6649208&query_hl=42&itool=pubmed_docsum)
19. Cass AS, Luxenberg M. Testicular injuries. *Urology* 1991;37(6):528-530 (level of evidence: 3).  
[http://www.ncbi.nlm.nih.gov/entrez/query.fcgi?cmd=Retrieve&db=pubmed&dopt=Abstract&list\\_uids=2038785&query\\_hl=45&itool=pubmed\\_docsum](http://www.ncbi.nlm.nih.gov/entrez/query.fcgi?cmd=Retrieve&db=pubmed&dopt=Abstract&list_uids=2038785&query_hl=45&itool=pubmed_docsum)
20. Wasko R, Goldstein AG. Traumatic rupture of the testicle. *J Urol* 1966;95(5):721-723 (level of evidence: 3).  
[http://www.ncbi.nlm.nih.gov/entrez/query.fcgi?cmd=Retrieve&db=pubmed&dopt=Abstract&list\\_uids=5935538&query\\_hl=47&itool=pubmed\\_docsum](http://www.ncbi.nlm.nih.gov/entrez/query.fcgi?cmd=Retrieve&db=pubmed&dopt=Abstract&list_uids=5935538&query_hl=47&itool=pubmed_docsum)
21. Sotto LSJ, Collins RJ. Perigenital Hematomas. *Obstet Gynecol* 1958;12:259-263 (level of evidence: 3).
22. Propst AM, Thorp JM Jr. Traumatic vulvar hematomas: conservative versus surgical management. *South Med J* 1998;91(2):144-146 (level of evidence: 3).  
[http://www.ncbi.nlm.nih.gov/entrez/query.fcgi?cmd=Retrieve&db=PubMed&list\\_uids=9496865&dopt=Abstract](http://www.ncbi.nlm.nih.gov/entrez/query.fcgi?cmd=Retrieve&db=PubMed&list_uids=9496865&dopt=Abstract)
23. Goldman HB, Idom CB Jr, Dmochowski RR. Traumatic injuries of the female external genitalia and their association with urological injuries. *J Urol* 1998;159(3):956-959 (level of evidence: 3).  
[http://www.ncbi.nlm.nih.gov/entrez/query.fcgi?cmd=Retrieve&db=PubMed&list\\_uids=9496865&dopt=Abstract](http://www.ncbi.nlm.nih.gov/entrez/query.fcgi?cmd=Retrieve&db=PubMed&list_uids=9496865&dopt=Abstract)
24. Okur H, Kucikaydin M, Kazez A, Turan C, Bozkurt A. Genitourinary tract injuries in girls. *Br J Urol* 1996;78(3):446-449 (level of evidence: 3).  
[http://www.ncbi.nlm.nih.gov/entrez/query.fcgi?cmd=Retrieve&db=PubMed&list\\_uids=8881959&dopt=Abstract](http://www.ncbi.nlm.nih.gov/entrez/query.fcgi?cmd=Retrieve&db=PubMed&list_uids=8881959&dopt=Abstract)
25. Donovan JF, Kaplan WE. The therapy of genital trauma by dog bite. *J Urol* 1989;141(5):1163-1165 (level of evidence: 3).  
[http://www.ncbi.nlm.nih.gov/entrez/query.fcgi?cmd=Retrieve&db=PubMed&list\\_uids=2651716&dopt=Abstract](http://www.ncbi.nlm.nih.gov/entrez/query.fcgi?cmd=Retrieve&db=PubMed&list_uids=2651716&dopt=Abstract)
26. McAninch JW, Kahn RI, Jeffrey RB, Laing FC, Krieger MJ. Major traumatic and septic genital injuries. *J Trauma* 1984;24(4):291-298 (level of evidence: 3-4).  
[http://www.ncbi.nlm.nih.gov/entrez/query.fcgi?cmd=Retrieve&db=PubMed&list\\_uids=6368854&dopt=Abstract](http://www.ncbi.nlm.nih.gov/entrez/query.fcgi?cmd=Retrieve&db=PubMed&list_uids=6368854&dopt=Abstract)
27. Dreesen DW, Hanlon CA. Current recommendations for the prophylaxis and treatment of rabies. *Drugs* 1998;56(5):801-809 (level of evidence: 4).  
[http://www.ncbi.nlm.nih.gov/entrez/query.fcgi?cmd=Retrieve&db=PubMed&list\\_uids=9829154&dopt=Abstract](http://www.ncbi.nlm.nih.gov/entrez/query.fcgi?cmd=Retrieve&db=PubMed&list_uids=9829154&dopt=Abstract)
28. Anderson CR. Animal bites. Guidelines to current management. *Postgrad Med* 1992;92(1):134-136, 139-146,149 (level of evidence: 4).  
[http://www.ncbi.nlm.nih.gov/entrez/query.fcgi?cmd=Retrieve&db=PubMed&list\\_uids=1614928&dopt=Abstract](http://www.ncbi.nlm.nih.gov/entrez/query.fcgi?cmd=Retrieve&db=PubMed&list_uids=1614928&dopt=Abstract)
29. Frauscher F, Klauser A, Stenzl A, Helweg G, Amort B, zur Nedden D. US findings in the scrotum of extreme mountain bikers. *Radiology* 2001;219(2):427-431 (level of evidence: 3).  
[http://www.ncbi.nlm.nih.gov/entrez/query.fcgi?cmd=Retrieve&db=PubMed&list\\_uids=11323467&dopt=Abstract](http://www.ncbi.nlm.nih.gov/entrez/query.fcgi?cmd=Retrieve&db=PubMed&list_uids=11323467&dopt=Abstract)
30. de Peretti F, Cambas PM, Veneau B, Argenson C. [Fuel tanks of motorcycles. Role in severe trauma of the pelvis.] *Presse Med* 1993;22(2):61-63 [French] (level of evidence: 4).  
[http://www.ncbi.nlm.nih.gov/entrez/query.fcgi?cmd=Retrieve&db=PubMed&list\\_uids=8493205&dopt=Abstract](http://www.ncbi.nlm.nih.gov/entrez/query.fcgi?cmd=Retrieve&db=PubMed&list_uids=8493205&dopt=Abstract)
31. Herrmann B, Crawford J. Genital injuries in prepubertal girls from inline skating accidents. *Pediatrics* 2002;110(2 Pt 1):e16 (level of evidence: 3).  
[http://www.ncbi.nlm.nih.gov/entrez/query.fcgi?cmd=Retrieve&db=PubMed&list\\_uids=12165615&dopt=Abstract](http://www.ncbi.nlm.nih.gov/entrez/query.fcgi?cmd=Retrieve&db=PubMed&list_uids=12165615&dopt=Abstract)
32. Lawson JS, Rotem T, Wilson SF. Catastrophic injuries to the eyes and testicles in footballers. *Med J Aust* 1995;163(5):242-244 (level of evidence: 3).  
[http://www.ncbi.nlm.nih.gov/entrez/query.fcgi?cmd=Retrieve&db=PubMed&list\\_uids=7565208&dopt=Abstract](http://www.ncbi.nlm.nih.gov/entrez/query.fcgi?cmd=Retrieve&db=PubMed&list_uids=7565208&dopt=Abstract)
33. Husmann DA. Editorial Comment. *J Urol* 1998;159:959 (level of evidence: 4).

34. Karadeniz T, Topsakal M, Ariman A, Erton H, Basak D. Penile fracture: differential diagnosis, management and outcome. *Br J Urol* 1996;77(2):279-281 (level of evidence: 3).  
[http://www.ncbi.nlm.nih.gov/entrez/query.fcgi?cmd=Retrieve&db=PubMed&list\\_uids=8800899&dopt=Abstract](http://www.ncbi.nlm.nih.gov/entrez/query.fcgi?cmd=Retrieve&db=PubMed&list_uids=8800899&dopt=Abstract)
35. Pretorius ES, Siegelman ES, Ramchandani P, Banner MP. MR imaging of the penis. *Radiographics* 2001;21 Spec No:S283-S298, discussion S2988-299 (level of evidence: 3).  
[http://www.ncbi.nlm.nih.gov/entrez/query.fcgi?cmd=Retrieve&db=PubMed&list\\_uids=11598264&dopt=Abstract](http://www.ncbi.nlm.nih.gov/entrez/query.fcgi?cmd=Retrieve&db=PubMed&list_uids=11598264&dopt=Abstract)
36. Uder M, Gohl D, Takahashi M, Derouet H, Defreyne L, Kramann B, Schneider G. MRI of penile fracture: diagnosis and therapeutic follow-up. *Eur Radiol* 2002;12(1):113-120 (level of evidence: 3).  
[http://www.ncbi.nlm.nih.gov/entrez/query.fcgi?cmd=Retrieve&db=PubMed&list\\_uids=11868085&dopt=Abstract](http://www.ncbi.nlm.nih.gov/entrez/query.fcgi?cmd=Retrieve&db=PubMed&list_uids=11868085&dopt=Abstract)
37. Choi MH, Kim B, Ryu JA, Lee SW, Lee KS. MR imaging of acute penile fracture. *Radiographics* 2000;20(5):1397-1405 (level of evidence: 3).  
[http://www.ncbi.nlm.nih.gov/entrez/query.fcgi?cmd=Retrieve&db=PubMed&list\\_uids=10992029&dopt=Abstract](http://www.ncbi.nlm.nih.gov/entrez/query.fcgi?cmd=Retrieve&db=PubMed&list_uids=10992029&dopt=Abstract)
38. Fedel M, Venz S, Andreessen R, Sudhoff F, Loening SA. The value of magnetic resonance imaging in the diagnosis of suspected penile fracture with atypical clinical findings. *J Urol* 1996;155(6):1924-1927 (level of evidence: 3).  
[http://www.ncbi.nlm.nih.gov/entrez/query.fcgi?cmd=Retrieve&db=PubMed&list\\_uids=8618289&dopt=Abstract](http://www.ncbi.nlm.nih.gov/entrez/query.fcgi?cmd=Retrieve&db=PubMed&list_uids=8618289&dopt=Abstract)
39. Pavlica P, Barozzi L. Imaging of the acute scrotum. *Eur Radiol* 2001;11(2):220-228 (level of evidence: 3).  
[http://www.ncbi.nlm.nih.gov/entrez/query.fcgi?cmd=Retrieve&db=PubMed&list\\_uids=11218018&dopt=Abstract](http://www.ncbi.nlm.nih.gov/entrez/query.fcgi?cmd=Retrieve&db=PubMed&list_uids=11218018&dopt=Abstract)
40. Micallef M, Ahmad I, Ramesh N, Hurley M, McInerney D. Ultrasound features of blunt testicular injury. *Injury* 2001;32(1):23-26 (level of evidence: 3).  
[http://www.ncbi.nlm.nih.gov/entrez/query.fcgi?cmd=Retrieve&db=PubMed&list\\_uids=11164397&dopt=Abstract](http://www.ncbi.nlm.nih.gov/entrez/query.fcgi?cmd=Retrieve&db=PubMed&list_uids=11164397&dopt=Abstract)
41. Patil MG, Onuora VC. The value of ultrasound in the evaluation of patients with blunt scrotal trauma. *Injury* 1994;25(3):177-178 (level of evidence: 3).  
[http://www.ncbi.nlm.nih.gov/entrez/query.fcgi?cmd=Retrieve&db=PubMed&list\\_uids=8168890&dopt=Abstract](http://www.ncbi.nlm.nih.gov/entrez/query.fcgi?cmd=Retrieve&db=PubMed&list_uids=8168890&dopt=Abstract)
42. Corrales JG, Corbel L, Cipolla B, Staerman F, Darnault P, Guille F, Lobel B. Accuracy of ultrasound diagnosis after blunt testicular trauma. *J Urol* 1993;150(6):1834-1836 (level of evidence: 3).  
[http://www.ncbi.nlm.nih.gov/entrez/query.fcgi?cmd=Retrieve&db=PubMed&list\\_uids=8080482&dopt=Abstract](http://www.ncbi.nlm.nih.gov/entrez/query.fcgi?cmd=Retrieve&db=PubMed&list_uids=8080482&dopt=Abstract)
43. Mulhall JP, Gabram SG, Jacobs LM. Emergency management of blunt testicular trauma. *Acad Emerg Med* 1995;2(7):639-643 (level of evidence: 4).  
[http://www.ncbi.nlm.nih.gov/entrez/query.fcgi?cmd=Retrieve&db=PubMed&list\\_uids=8521212&dopt=Abstract](http://www.ncbi.nlm.nih.gov/entrez/query.fcgi?cmd=Retrieve&db=PubMed&list_uids=8521212&dopt=Abstract)
44. Martinez-Pineiro L Jr, Cerezo E, Cozar JM, Avellana JA, Moreno JA, Martinez-Pineiro JA. Value of testicular ultrasound in the evaluation of blunt scrotal trauma without haematocele. *Br J Urol* 1992;69(3):286-290 (level of evidence: 3).  
[http://www.ncbi.nlm.nih.gov/entrez/query.fcgi?cmd=Retrieve&db=PubMed&list\\_uids=1568102&dopt=Abstract](http://www.ncbi.nlm.nih.gov/entrez/query.fcgi?cmd=Retrieve&db=PubMed&list_uids=1568102&dopt=Abstract)
45. Fournier GR Jr, Laing FC, McAninch JW. Scrotal ultrasonography and the management of testicular trauma. *Urol Clin North Am* 1989;16(2):377-385 (level of evidence: 3).  
[http://www.ncbi.nlm.nih.gov/entrez/query.fcgi?cmd=Retrieve&db=PubMed&list\\_uids=2652862&dopt=Abstract](http://www.ncbi.nlm.nih.gov/entrez/query.fcgi?cmd=Retrieve&db=PubMed&list_uids=2652862&dopt=Abstract)
46. Kratzik C, Hainz A, Kuber W, Donner G, Lunglmayr G, Frick J, Schmoller HJ. Has ultrasound influenced the therapy concept of blunt scrotal trauma? *J Urol* 1989;142(5):1243-1246 (level of evidence: 3).  
[http://www.ncbi.nlm.nih.gov/entrez/query.fcgi?cmd=Retrieve&db=PubMed&list\\_uids=2652862&dopt=Abstract](http://www.ncbi.nlm.nih.gov/entrez/query.fcgi?cmd=Retrieve&db=PubMed&list_uids=2652862&dopt=Abstract)
47. Muglia V, Tucci S Jr, Elias J Jr, Trad CS, Billbey J, Cooperberg PL. Magnetic resonance imaging of scrotal diseases: when it makes the difference. *Urology* 2002;59(3):419-423 (level of evidence: 3).  
[http://www.ncbi.nlm.nih.gov/entrez/query.fcgi?cmd=Retrieve&db=PubMed&list\\_uids=11880084&dopt=Abstract](http://www.ncbi.nlm.nih.gov/entrez/query.fcgi?cmd=Retrieve&db=PubMed&list_uids=11880084&dopt=Abstract)

48. Orvis BR, McAninch JW. Penile rupture. *Urol Clin North Am* 1989;16(2):369-375 (level of evidence: 4). [http://www.ncbi.nlm.nih.gov/entrez/query.fcgi?cmd=Retrieve&db=PubMed&list\\_uids=2652861&dopt=Abstract](http://www.ncbi.nlm.nih.gov/entrez/query.fcgi?cmd=Retrieve&db=PubMed&list_uids=2652861&dopt=Abstract)
49. Altarac S. Management of 53 cases of testicular trauma. *Eur Urol* 1994;25(2):119-123 (level of evidence: 3). [http://www.ncbi.nlm.nih.gov/entrez/query.fcgi?cmd=Retrieve&db=PubMed&list\\_uids=8137851&dopt=Abstract](http://www.ncbi.nlm.nih.gov/entrez/query.fcgi?cmd=Retrieve&db=PubMed&list_uids=8137851&dopt=Abstract)
50. Cass AS, Luxenberg M. Value of early operation in blunt testicular contusion with hematocele. *J Urol* 1988;139(4):746-747 (level of evidence: 3). [http://www.ncbi.nlm.nih.gov/entrez/query.fcgi?cmd=Retrieve&db=pubmed&dopt=Abstract&list\\_uids=3352037&query\\_hl=51&itool=pubmed\\_docsum](http://www.ncbi.nlm.nih.gov/entrez/query.fcgi?cmd=Retrieve&db=pubmed&dopt=Abstract&list_uids=3352037&query_hl=51&itool=pubmed_docsum)
51. Altarac S. A case of testicle replantation. *J Urol* 1993;150(5 Pt 1):1507-1508 (level of evidence: 3). [http://www.ncbi.nlm.nih.gov/entrez/query.fcgi?cmd=Retrieve&db=PubMed&list\\_uids=8411440&dopt=Abstract](http://www.ncbi.nlm.nih.gov/entrez/query.fcgi?cmd=Retrieve&db=PubMed&list_uids=8411440&dopt=Abstract)

## 5.7 Recommendations (1)

Level	Type of evidence
1a	Evidence obtained from meta-analysis of randomized trials
1b	Evidence obtained from at least one randomized trial
2a	Evidence obtained from one well-designed controlled study without randomization
2b	Evidence obtained from at least one other type of well-designed quasi-experimental study
3	Evidence obtained from well-designed non-experimental studies, such as comparative studies, correlation studies and case reports
4	Evidence obtained from expert committee reports or opinions or clinical experience of respected authorities

## Grades of guideline recommendations (1)

Grade	Nature of recommendations
A	Based on clinical studies of good quality and consistency addressing the specific recommendations and including at least one randomized trial
B	Based on well-conducted clinical studies, but without randomized clinical trials
C	Made despite the absence of directly applicable clinical studies of good quality

1. **Agency for Health Care Policy and Research.** Clinical Practice Guidelines Development, Methodological Perspectives. US Department of Health and Human Services, Public Health Service, Washington DC, 1992, pp. 115-127.

## 6. ABBREVIATIONS

*This list is not comprehensive for the most common abbreviations*

AAST	American Association for the Surgery of Trauma
CT	computed tomography
DMSA	dimercaptosuccinic acid
IVP	intravenous pyelography
IVU	intravenous urography
KUB	kidney-ureter-bladder
MRI	magnetic resonance imaging
Rbc/hpf	red blood cells per high power field