Guidelines on Urological Trauma

N. Djakovic, E. Plas, L. Martínez-Piñeiro, Th. Lynch, Y. Mor, R.A. Santucci, E. Serafetinidis, L.N. Turkeri, M. Hohenfellner

European Association of Urology

© European Association of Urology 2010

TABLE OF CONTENTS PAGE

1. INTRODUCTION 6
   1.1 Reference 6

2. RENAL TRAUMA 6
   2.1 Background 6
   2.2 Mode of injury 7
      2.2.1 Injury classification 7
   2.3 Diagnosis: initial emergency assessment 7
      2.3.1 History and physical examination 8
      2.3.2 Recommendations 8
      2.3.3 Laboratory evaluation 8
      2.3.4 Recommendations 9
      2.3.5 Imaging: criteria for radiographic assessment in adults 9
         2.3.5.1 Ultrasonography 9
         2.3.5.2 Standard IVP 10
         2.3.5.3 One-shot intraoperative IVP 10
         2.3.5.4 Computed tomography (CT) 10
         2.3.5.5 Magnetic resonance imaging (MRI) 11
         2.3.5.6 Angiography 11
         2.3.5.7 Radionuclide scans 11
      2.3.6 Recommendations 12
   2.4 Treatment 12
      2.4.1 Indications for renal exploration 12
      2.4.2 Operative findings and reconstruction 12
      2.4.3 Non-operative management of renal injuries 13
      2.4.4 Recommendations 14
      2.4.5 Post-operative care and follow-up 14
      2.4.6 Recommendations 14
      2.4.7 Complications 15
      2.4.8 Recommendations 15
      2.4.9 Paediatric renal trauma 15
      2.4.10 Recommendations 17
      2.4.11 Renal injury in the polytrauma patient 17
      2.4.12 Recommendations 17
   2.5 Iatrogenic renal injuries 17
      2.5.1 Iatrogenic vascular injuries 17
      2.5.2 Renal transplantation 18
      2.5.3 Percutaneous renal procedures 18
      2.5.4 Recommendations 20
   2.6 Suggestions for future research studies 20
   2.7 Algorithms 20
   2.8 References 23

3. URETERAL TRAUMA 31
   3.1 Introduction 31
   3.2 Aetiology 32
   3.3 Diagnosis 32
      3.3.1 Clinical diagnosis 32
      3.3.2 Radiological diagnosis 32
   3.4 Classification 32
   3.5 Management 32
      3.5.1 Partial injuries 32
      3.5.2 Complete injuries 33
      3.5.3 Sterile surgery 33
         3.5.3.1 Uretero-ureterostomy 33
         3.5.3.2 Ureterocalycostomy 34
         3.5.3.3 Transuretero-ureterostomy 34

3.5.3.4 Ureteroneocystostomy with Boari flap 34
3.5.3.5 Ureterocystostomy and psoas hitch 34
3.5.3.6 Ileal interposition graft 34
3.5.3.7 Autotransplantation 35
3.5.3.8 Nephrectomy 35
3.6 References 35

4. BLADDER TRAUMA 35
4.1 Background 35
4.1.1 Iatrogenic trauma 36
4.2 Classification 37
4.3 Risk factors 37
4.4 Diagnosis 37
4.4.1 Macroscopic (gross) haematuria 37
4.4.2 Microscopic haematuria 38
4.4.3 Cystography 38
4.4.4 Excretory urography (intravenous pyelogram [IVP]) 38
4.4.5 Ultrasound (US) 38
4.4.6 Computed tomography (CT) 38
4.4.7 Angiography 39
4.4.8 Magnetic resonance imaging (MRI) 39
4.4.9 Cystoscopy 39
4.5 Treatment 39
4.5.1 Blunt trauma: extraperitoneal rupture 39
4.5.2 Blunt trauma: intraperitoneal rupture 39
4.5.3 Penetrating injuries 39
4.5.4 Iatrogenic injuries 39
4.6 Recommendations 40
4.6.1 General 40
4.6.2 Diagnosis 40
4.6.3 Treatment 40
4.7 References 40

5. URETHRAL TRAUMA 44
5.1 Anatomical and aetiological considerations 44
5.1.1 Posterior urethral injuries 44
5.1.1.1 Urethral injuries in children 46
5.1.1.2 Urethral injuries in women 46
5.1.1.3 Penetrating injuries to the perineum 46
5.1.2 Anterior urethral injuries 46
5.1.2.1 Blunt trauma 46
5.1.2.2 Intercourse-related trauma 47
5.1.2.3 Penetrating trauma 47
5.1.2.4 Constriction band-related trauma 47
5.1.2.5 Iatrogenic trauma 47
5.2. Diagnosis: initial emergency assessment 47
5.2.1 Clinical assessment 47
5.2.1.1 Blood at the meatus 47
5.2.1.2 Blood at the vaginal introitus 47
5.2.1.3 Haematuria 47
5.2.1.4 Pain on urination or inability to void 48
5.2.1.5 Haematoma or swelling 48
5.2.1.6 High-riding prostate 48
5.2.2 Radiographic examination 48
5.2.3 Endoscopic examination 49
5.3. Management 49
5.3.1 Anterior urethral injuries 49
5.3.1.1 Blunt injuries 49
5.3.1.2 Open injuries 49
5.3.1.2.1 Male urethral injuries 49

5.3.1.2.2 Female urethral injuries 50
5.3.2 Posterior urethral injuries 50
5.3.2.1 Partial urethral rupture 50
5.3.2.2 Complete urethral rupture 50
5.3.2.3 Primary realignment 51
5.3.2.4 Immediate open urethroplasty 53
5.3.2.5 Delayed primary urethroplasty 53
5.3.2.6 Delayed urethroplasty 53
5.3.2.7 Reconstruction of failed repair of posterior urethral rupture 54
5.3.2.8 Delayed endoscopic optical incision 55
5.4 Recommendations for treatment: algorithms 56
5.5 Iatrogenic urethral trauma 58
5.5.1 Introduction 58
5.5.2 Iatrogenic urethral trauma caused by catheterisation 58
5.5.3 Iatrogenic urethral trauma caused by transurethral surgery 59
5.5.4 Iatrogenic urethral trauma related to surgical prostate cancer treatment 59
5.5.5 Iatrogenic urethral trauma related to radiotherapy for prostate cancer treatment 59
5.5.6 Iatrogenic urethral trauma related to major abdominal surgery 59
5.5.7 Symptoms of iatrogenic urethral injury 59
5.5.8 Diagnosis 60
5.5.9 Treatment 60
5.5.10 Recommendations for treatment: algorithms 60
5.5.11 Recommendations 61
5.6 References 61

6. GENITAL TRAUMA 69
6.1 Background 69
6.2 Pathophysiology 69
6.2.1 Blunt trauma 69
6.2.2 Penetrating trauma 70
6.3 Risk factors 71
6.4 Diagnosis 71
6.4.1 Blunt renal trauma 71
6.4.1.1 Penile fracture 71
6.4.2 Blunt testicular trauma 71
6.4.3 Blunt female trauma 72
6.4.4 Penetrating trauma 72
6.5 Treatment 72
6.5.1 Penile trauma 72
6.5.1.1 Blunt trauma 72
6.5.1.2 Penetrating trauma 72
6.5.2 Testicular trauma 72
6.5.2.1 Blunt trauma 72
6.5.2.2 Penetrating trauma 73
6.5.3 Vulvar injuries 73
6.6. References 73

7. MASS CASUALTY EVENTS, TRIAGE AND DAMAGE CONTROL 76
7.1 Definition 76
7.2 Causes of mass casualty events 76
7.3 Mechanisms of explosive injury 77
7.4 Triage 77
7.4.1 Primary triage 77
7.4.2 Secondary triage 77
7.4.3 Re-triage 77
7.5 Principles of ‘damage control’ 78
7.6 Urological aspects of ‘damage control’ 78
7.6.1 The urological consultation in the emergency room during mass casualty events 78
7.6.1.1 Responsibility and primary overall assessment 78
7.6.1.2 Imaging 78

7.6.1.3 Primary management 78
7.6.2 The urological consultation in the operating room during mass casualty events 79
7.6.2.1 Renal trauma 79
7.6.2.2 Ureteral injuries 80
7.6.2.3 Bladder injury 81
7.6.2.3.1 Auxiliary damage control measures 81
7.6.2.4 Urethral injury 81
7.6.2.5 Injury of the external genitalia 81
7.6.2.5.1 Temporary damage control measures 81
7.7 Summary 81
7.8 References 81

8. ABBREVIATIONS USED IN THE TEXT 84

1. INTRODUCTION

1.1 Background

The European Association of Urology (EAU) Guidelines Group for Urological Trauma prepared this guidelines document to assist medical professionals in the management of urological trauma.

The Urological Trauma guidelines are based on a review of the literature, using on-line searches of MEDLINE and other source documents published between 2005 and 2008. A critical assessment of the findings was made, not involving a formal appraisal of the data. There is a paucity of high-powered randomized controlled trials in this area and considerable available data are based on retrospective studies. The panel recognise this limitation.

A level of evidence (LE) and/or grade of recommendation (GR) have been assigned where possible (1).
The aim of grading recommendations is to provide transparency between the underlying evidence and the recommendation given.

Publication history information: The Urological Trauma Guidelines were first published in 2003, with a partial update in 2006 followed by this full text update in 2009. Additionally, a quick reference guide is available.
All texts can be viewed and downloaded for personal use at the society website: http://www.uroweb.org/professional-resources/guidelines/.

Levels of evidence and grade of guideline recommendations*

Table 1: Level of evidence

Level	Type of evidence
1a	Evidence obtained from meta-analysis of randomised trials
1b	Evidence obtained from at least one randomised trial
2a	Evidence obtained from one well-designed controlled study without randomisation
2b	Evidence obtained from at least one other type of well-designed quasi-experimental study
3	Evidence obtained from well-designed non-experimental studies, such as comparative studies, correlation studies and case reports
4	Evidence obtained from expert committee reports or opinions or clinical experience of respected authorities

Table 2: Grade of recommendation

Grade	Nature of recommendations
A	Based on clinical studies of good quality and consistency addressing the specific recommendations and including at least one randomised trial
B	Based on well-conducted clinical studies, but without randomised clinical trials
C	Made despite the absence of directly applicable clinical studies of good quality

**modified from Sackett et al. (1)*

1.1 REFERENCE

1. Oxford Centre for Evidence-based Medicine Levels of Evidence (May 2001). Produced by Bob Phillips, Chris Ball, Dave Sackett, Doug Badenoch, Sharon Straus, Brian Haynes, Martin Dawes since November 1998. http://www.cebm.net/index.aspx?o=1025 [accessed February 2009].

2. RENAL TRAUMA

2.1 Background

Renal trauma occurs in approximately 1-5% of all trauma cases (1, 2). The kidney is the most commonly injured genitourinary and abdominal organ. There is a 3:1 male to female ratio in kidney trauma patients (3-5). Renal trauma can be acutely life-threatening, but the majority of renal injuries can be managed conservatively. Advances in imaging and treatment strategies during the past 20 years have decreased the need for surgical intervention and increased renal preservation (6-8).

2.2 Mode of injury

Renal injuries are classified by their mechanism: blunt or penetrating. In rural settings, blunt trauma can account for the largest percentage (90-95%) (9), while in urban settings, the percentage of penetrating injuries can increase to 20% (6) or higher.

Blunt trauma is usually caused by motor vehicle accidents, falls, vehicle-associated pedestrian accidents, contact sports and assault. Traffic accidents are the major cause of almost half the blunt renal injuries (10). Renal injury in frontal and side-impact collisions appears to occur after direct impact from objects in the vehicle compartment. For frontal crashes, occupant acceleration into the seat belt or steering wheel seems to result in renal injuries. Side impact injuries occur when the vehicle side panel intrudes into the compartment, striking the occupant (11). A 20-year review of renal injuries following free falls found a rate of 16% (12).

Renal lacerations and renal vascular injuries make up only 10-15% of all blunt renal injuries. Isolated renal artery injury following blunt abdominal trauma is extremely rare, and accounts for less than 0.1% of all trauma patients (13).

Renal artery occlusion is associated with rapid deceleration injuries. In theory, the kidney is displaced causing renal artery traction; the resulting tear in the inelastic intima and subsequent haemorrhage into the vessel wall leads to thrombosis. Compression of the renal artery between the anterior abdominal wall and the vertebral bodies may result in thrombosis of the renal artery.

Gunshot and stab wounds represent the most common causes of penetrating injuries. Renal injuries from penetrating trauma tend to be more severe and less predictable than those from blunt trauma. Bullets, because of their higher kinetic energy, have the potential for greater parenchymal destruction and are most often associated with multiple-organ injuries (14).

In wartime, the kidney is the most commonly injured urogenital organ. Most are found to be associated with major abdominal injuries, and the rate of wartime nephrectomies is relatively high (25-33%) (15-17).

2.2.1 Injury classification

Classifying renal injuries helps to standardise different groups of patients, select appropriate therapy and predict results. A total of 26 classifications for renal injuries have been presented in the literature in the past 50 years (18), but the committee on organ injury scaling of the American Association for the Surgery of Trauma (AAST) has developed a renal-injury scaling system that is now widely used (19). Renal injuries are classified as grade 1 to 5 (Table 3). Abdominal computed tomography (CT) or direct renal exploration is used to classify injuries. Most recent publications in the field of renal trauma have adopted this classification. In a retrospective review, the AAST scaling system was determined as the most important variable predicting the need for kidney repair or removal (20, 21). It also predicts for morbidity after blunt or penetrating injury, and for mortality after blunt injury (22).

Table 3: AAST renal injury grading scale (17)

Grade*	Description of injury
1	• Contusion or non-expanding subcapsular haematoma
	• No laceration
2	• Non-expanding peri-renal haematoma
	• Cortical laceration < 1 cm deep without extravasation
3	• Cortical laceration > 1 cm without urinary extravasation
4	• Laceration: through corticomedullary junction into collecting system
	or
	• Vascular: segmental renal artery or vein injury with contained haematoma, or partial vessel laceration, or vessel thrombosis
5	• Laceration: shattered kidney
	or
	• Vascular: renal pedicle or avulsion

**Advance one grade for bilateral injuries up to grade III.*

2.3 Diagnosis: initial emergency assessment

Initial assessment of the trauma patient should include securing the airway, controlling external bleeding and resuscitation of shock, as required. In many cases, physical examination is carried out during the stabilisation

of the patient. When renal injury is suspected, further evaluation (CT scan, laparotomy) is required for a prompt diagnosis.

2.3.1 History and physical examination

A direct history is obtained from conscious patients. Witnesses and emergency personnel can provide valuable information about unconscious or seriously injured patients. Possible indicators of major renal injury include a rapid deceleration event (fall, high-speed motor vehicle accidents) or a direct blow to the flank. In assessing trauma patients after motor vehicle accidents, the history should include the vehicle's speed and whether the patient was a passenger or pedestrian.

In penetrating injuries, important information includes the size of the weapon in stabbings, and the type and calibre of weapon used in gunshot wounds, as high-velocity projectiles have the potential to cause more extensive damage.

The medical history should be as detailed as possible, as pre-existing organ dysfunction can have a negative effect on trauma patient outcome (23). In the early resuscitation phase, special consideration should be given to pre-existing renal disease (24). Another point of interest is the functioning renal mass of the trauma patient, as there are numerous case reports in the literature about complicated renal trauma in solitary kidneys (25).

Pre-existing renal abnormality makes renal injury more likely following trauma. Pre-existing renal pathology should be noted. Hydronephrosis due to ureteropelvic junction abnormality, renal calculi, cysts and tumours are the most commonly reported entities that may complicate a minor renal injury (26). The overall percentage of these cases varies from 4% to 22% (27, 28).

Haemodynamic stability is the primary criterion for the management of all renal injuries. Shock is defined as a systolic blood pressure of less than 90 mmHg found at any time during an adult patient's evaluation. Vital signs should be recorded throughout diagnostic evaluation.

Physical examination may reveal an obvious penetrating trauma from a stab wound to the lower thoracic back, flanks and upper abdomen, or bullet entry or exit wounds in this area. In stab wounds, the extent of the entrance wound may not accurately reflect the depth of penetration. Blunt trauma to the back, flank, lower thorax or upper abdomen may result in renal injury. The following findings on physical examination could indicate possible renal involvement:

- haematuria
- flank pain
- flank ecchymoses
- flank abrasions
- fractured ribs
- abdominal distension
- abdominal mass
- abdominal tenderness.

2.3.2 Recommendations

Recommendations	GR
• Haemodynamic stability should be decided upon admission	B
• History should be taken from conscious patients, witnesses and rescue team personnel with regard to the time and setting of the incident	C
• Past renal surgery, and known pre-existing renal abnormalities (ureteropelvic junction obstruction, large cysts, lithiasis) should be recorded	B
• A thorough examination should be made of the thorax, abdomen, flanks and back for penetrating wounds	B
• Findings on physical examination such as haematuria, flank pain, flank abrasions and ecchymoses, fractured ribs, abdominal tenderness, distension or mass, could indicate possible renal involvement	B

GR = grade of recommendation

2.3.3 Laboratory evaluation

The trauma patient is evaluated by a series of laboratory tests. Urinalysis, haematocrit and baseline creatinine are the most important tests for evaluating renal trauma.

Urinalysis is considered the basic test in the evaluation of patients with suspected renal trauma. Haematuria is the presence of an abnormal quantity of red blood cells in the urine and is usually the first indicator of renal injury. Microscopic haematuria in the trauma setting may be defined as greater than 5 red blood cells per high-power field (rbc/hpf), while gross haematuria is demonstrated by urine in which blood is readily visible.

Haematuria is a hallmark sign of renal injury, but is neither sensitive nor specific enough for differentiating minor and major injuries. It does not necessarily correlate with the degree of injury (29). Major renal injury, such as disruption of the ureteropelvic junction, renal pedicle injuries or segmental arterial thrombosis may occur without haematuria (30). In a study by Eastham et al., 9% of patients with stab wounds and resultant proven renal injury did not manifest haematuria (31). Haematuria that is out of proportion to the history of trauma may suggest pre-existing renal pathology (32). A urine dipstick is an acceptably reliable and rapid test to evaluate haematuria. However, some studies have shown false-negative result rates ranging from 3-10% using the dipstick test for haematuria (33).

Serial haematocrit determination is a method of continuous evaluation of the trauma patient. Initial haematocrit in association with vital signs implies the need for emergency resuscitation. The decrease in haematocrit and the requirement for blood transfusions is an indirect sign of the rate of blood loss and, along with the patient's response to resuscitation, is valuable in the decision-making process.

As most trauma patients are evaluated within 1 hour of injury, creatinine measurement reflects renal function prior to the injury. An increased creatinine usually reflects pre-existing renal pathology.

2.3.4 Recommendations

Recommendations	GR
• Urine from a patient with suspected renal injury should be inspected grossly and then by dipstick analysis	B
• Serial haematocrit measurement indicates blood loss. However, until evaluation is complete, it will not be clear whether it is due to renal trauma and/or associated injuries	B
• Creatinine measurement could highlight patients who had impaired renal function prior to injury	C

GR = grade of recommendation

2.3.5 Imaging: criteria for radiographic assessment in adults

Decisions about radiographic imaging in cases of suspected renal trauma are based on the clinical findings and the mechanism of injury. Since the majority of renal injuries are not significant and resolve without any intervention, many attempts have been made to identify which patients could be spared the discomfort, radiation exposure, possible allergic reaction, time and expense of a radiographic evaluation (34).

Some patients do not require radiographic evaluation following blunt renal trauma. Patients with microscopic haematuria and no shock after blunt trauma have a low likelihood of concealing significant renal injury (35). The indications for radiographic evaluation are gross haematuria, microscopic haematuria and shock, or the presence of major associated injuries (36). However, patients with a history of rapid deceleration injury with clinical indicators of renal trauma or associated injuries also need immediate imaging to rule out ureteral avulsion or renal pedicle injury (12).

Patients with penetrating trauma to the torso have a high incidence of significant renal injuries. If renal injury is clinically suspected on the basis of an entry or exit wound, renal imaging should be performed, regardless of the degree of haematuria (37).

2.3.5.1 Ultrasonography

Ultrasonography is a popular imaging modality in the initial evaluation of abdominal trauma. It provides a quick, non-invasive, low-cost means of detecting peritoneal fluid collections without exposure to radiation (38). However, the usefulness of conventional ultrasound in the radiographic evaluation of renal trauma has been widely questioned. Its limitations stem from the difficulty in obtaining good acoustic windows on trauma patients who have sustained numerous associated injuries. The results are also highly dependent on the operator.

Ultrasound scans can detect renal lacerations but cannot definitely assess their depth and extent and do not provide functional information about renal excretion or urine leakage. Despite the drawbacks of the method, ultrasound scans can be conveniently used during the primary assessment of renal injuries. During

the evaluation of blunt trauma patients, ultrasound scans were more sensitive and specific than standard intravenous pyelography (IVP) in minor renal trauma (39). In another study comparing the results of ultrasound scans and IVP, the sensitivity of ultrasound decreased as the severity of the trauma increased, while that of IVP remained high for all degrees of severity (40).

Another possible role for ultrasound may be for serially evaluating stable renal injuries for the resolution of urinomas and retroperitoneal haematomas (41). Ultrasound might be considered suitable for the routine follow-up of renal parenchymal lesions or haematomas in the intensive care unit. Contrast-enhanced sonography is more sensitive than conventional ultrasound in the detection of renal injuries. In haemodynamically stable patients, it is a useful tool in the assessment of blunt injuries (42).

In conclusion, since ultrasound scans are used in the triage of patients with blunt abdominal trauma in many centres, they can be helpful in identifying which patients require a more aggressive radiological exploration to obtain a certain diagnosis (43, 44). Ultrasound findings do not provide sufficient evidence for a definite answer on the severity of renal injuries.

2.3.5.2 Standard IVP

Standard IVP is no longer the study of choice for the evaluation of renal trauma. In some centres it may be the only study available, in which case IVP should establish the presence or absence of one or both of the kidneys, clearly define the renal parenchyma, and outline the collecting system. In order to stage renal trauma, the IVP should include nephrotomograms, delineate the renal contour, and visualise the excretion of contrast material from both kidneys into the renal pelvis and ureter. Non-visualisation, contour deformity, or extravasation of contrast implies a major renal injury and should prompt further radiological evaluation with CT or, less commonly, angiography if available.

The most significant findings on IVP are non-function and extravasation. Non-function is usually a sign of extensive trauma to the kidney, pedicle injury (vascular avulsion or thrombosis), or a severely shattered kidney. Extravasation of the contrast medium also implies a severe degree of trauma, involving the capsule, parenchyma and collecting system. Other less reliable signs are delayed excretion, incomplete filling, calyceal distortion and obscuring of the renal shadow. The sensitivity of IVP is high (> 92%) for all degrees of trauma severity (45).

2.3.5.3 One-shot intraoperative IVP

Unstable patients selected for immediate operative intervention (and thus unable to have a CT scan) should undergo one-shot IVP in the operating theatre. The technique consists of a bolus intravenous injection of 2 mL/kg of radiographic contrast followed by a single plain film taken after 10 minutes. The study is safe, efficient, and of high quality in the majority of cases. It provides important information for decision-making in the critical time of urgent laparotomy concerning the injured kidney, as well as the presence of a normal functioning kidney on the contralateral side (46).

While the majority of experts advocate its use, not all studies have shown one-shot IVP to be necessary. In cases of penetrating abdominal trauma, the positive predictive value of one-shot IVP was only 20% (80% of patients with normal one-shot IVP findings had renal injuries not detected by the IVP) (47). One-shot IVP is of no significant value in assessing penetrating abdominal trauma patients who undergo exploratory laparotomy for associated intra-abdominal injuries, and should be reserved only for patients with a flank wound or gross haematuria following penetrating trauma (48).

2.3.5.4 Computed tomography (CT)

CT is the gold standard method for the radiographic assessment of stable patients with renal trauma. CT is more sensitive and specific than IVP, ultrasonography or angiography. In a retrospective study, the positive rate during evaluation of 298 patients was 96% by CT, 91% by double-dose intravenous IVP and 79% by ultrasound (45).

CT more accurately defines the location of injuries, easily detects contusions and devitalised segments, visualises the entire retroperitoneum and any associated haematomas, and simultaneously provides a view of both the abdomen and pelvis. It demonstrates superior anatomical detail, including the depth and location of renal laceration and presence of associated abdominal injuries, and establishes the presence and location of the contralateral kidney (49). CT is particularly useful in evaluating traumatic injuries to kidneys with pre-existing abnormalities (50).

Intravenous contrast should be administered for renal evaluation. A lack of contrast enhancement of the injured

kidney is a hallmark of renal pedicle injury. In cases where this typical finding is not demonstrated, central parahilar haematoma increases the possibility of renal pedicle injury. This sign should be considered even if the renal parenchyma is well enhanced (51).

Renal vein injury remains difficult to diagnose with any type of radiographic study. However, the presence on CT of a large haematoma, medial to the kidney and displacing the renal vasculature, should raise the suspicion of venous injury. Newer 'spiral' CT provides shorter scanning time and thus fewer artefacts in the examinations of patients who cannot co-operate adequately (52). Three-dimensional post-processing modalities allow assessment of the renal vascular pedicle by CT angiography and improve the demonstration of complex lacerations of the renal parenchyma. However, injury to the renal collecting system may be missed during routine spiral CT. In all cases of suspected renal trauma evaluated with spiral CT, repeat scans of the kidneys should be performed 10-15 minutes after contrast injection (53). Most blunt ureteral and ureteropelvic junction injuries can be identified if delayed excretory CT scans are performed (54). CT scanning is also safe as part of the diagnostic procedure for patients with gunshot wounds who are being considered for non-operative management (55).

2.3.5.5 Magnetic resonance imaging (MRI)

Although MRI is not used in the majority of renal trauma patients, Leppäniemi et al. investigated the use of high-field strength MRI (1.0 T) in the evaluation of blunt renal trauma (56). MRI scans were accurate in finding peri-renal haematomas, assessing the viability of renal fragments, and detecting pre-existing renal abnormalities, but failed to visualise urinary extravasation on initial examination. The authors concluded that MRI could replace CT in patients with iodine allergy and could be used for initial staging if CT were not available (56).

In a recent study comparing CT and MRI findings, the latter clearly revealed renal fracture with non-viable fragment, and was able to detect focal renal laceration not detected on CT due to peri-renal haematoma (57).

However, MRI is not the first choice in managing patients with trauma because it requires a longer imaging time, increases the cost, and limits access to patients when they are in the magnet during the examination. MRI is therefore useful in renal trauma only if CT is not available, in patients with iodine allergy, or in the very few cases where the findings on CT are equivocal.

2.3.5.6 Angiography

CT has largely replaced the use of angiography for staging renal injuries, as angiography is less specific, more time-consuming and more invasive. Angiography is, however, more specific for defining the exact location and degree of vascular injuries and may be preferable when planning selective embolisation for the management of persistent or delayed haemorrhage from branching renal vessels (50).

Angiography can define renal lacerations, extravasation and pedicle injury. Additionally, it is the test of choice for evaluating renal venous injuries. The most common indication for arteriography is non-visualisation of a kidney on IVP after major blunt renal trauma when a CT is not available. Common causes for non-visualisation are:

- total avulsion of the renal vessels (usually presents with life-threatening bleeding)
- renal artery thrombosis
- severe contusion causing major vascular spasm.

Angiography is also indicated in stable patients to assess pedicle injury if the findings on CT are unclear, and for those who are candidates for radiological control of haemorrhage (31).

2.3.5.7 Radionuclide scans

Radionuclide scans might be helpful for documenting renal blood flow in trauma patients with severe allergy to iodinated contrast material (50), but are not generally used or required.

2.3.6 Recommendations

Recommendations	GR
• Blunt trauma patients with macroscopic or microscopic haematuria (at least 5 rbc/hpf) with hypotension (systolic blood pressure < 90 mmHg) should undergo radiographic evaluation	B
• Radiographic evaluation is also recommended for all patients with a history of rapid deceleration injury and/or significant associated injuries	B
• All patients with any degree of haematuria after penetrating abdominal or thoracic injury require urgent renal imaging	B
• Ultrasonography can be informative during the primary evaluation of polytrauma patients and for the follow-up of recuperating patients, although more data is required to suggest this modality universally	C
• A CT scan with enhancement of intravenous contrast material is the best imaging study for the diagnosis and staging of renal injuries in haemodynamically stable patients	B
• Unstable patients who require emergency surgical exploration should undergo a one-shot IVP with bolus intravenous injection of 2 mL/kg contrast	C
• Formal IVP, MRI and radiographic scintigraphy are acceptable second-line alternatives for imaging renal trauma when CT is not available	C
• Angiography can be used for diagnosis and simultaneous selective embolisation of bleeding vessels	B

GR = grade of recommendation

2.4 Treatment

2.4.1 Indications for renal exploration

The goal in managing patients with renal injuries is to minimise morbidity and to preserve renal function. The need for renal exploration can be predicted with accuracy with a nomogram, which uses the type of injury, transfusion requirements, blood urea nitrogen (BUN), creatinine and injury grade (58). However, the management of renal injury is usually influenced by the decision to explore or observe associated abdominal injuries (59).

A life-threatening haemodynamic instability due to renal haemorrhage is an absolute indication for renal exploration, irrespective of the mode of injury (60, 61). Other indications include an expanding or pulsatile peri-renal haematoma identified at exploratory laparotomy performed for associated injuries (this finding heralds a grade 5 vascular injury and is quite rare). A one-shot intraoperative IVP can provide valuable information. Poor visualisation or any other abnormality of the injured kidney is an indication for exploration.

Grade 5 vascular renal injuries are, by definition, regarded as an absolute indication for exploration, although a single report has suggested that patients who are haemodynamically stable at presentation but with a grade 5 parenchymal injury (shattered kidney) after blunt trauma might be safely treated conservatively (62).

The management of major renal injuries with urinary extravasation and devitalised fragments is controversial. Since these injuries are very uncommon, published series report on small numbers of patients. In recent years, it seems to have been recognised that most major injuries heal with non-operative treatment (63). Moudouni et al. suggest that an initially conservative approach is feasible in stable patients with devitalised fragments (64). These injuries are, however, associated with an increased rate of complications and late surgery (65).

Persistent extravasation or urinoma are usually managed successfully with endourological techniques. Inconclusive renal imaging and a pre-existing renal abnormality or an incidentally diagnosed tumour could require surgery even after relatively minor renal injury (32).

2.4.2 Operative findings and reconstruction

The overall exploration rate for blunt trauma is less than 10% (60), and may be even lower as more centres adopt a very conservative approach to the management of these patients (66). The goal of renal exploration following renal trauma is control of haemorrhage and renal salvage. Most experienced authors suggest the transperitoneal approach for surgery (67, 68). Access to the renal vascular pedicle is then obtained through the posterior parietal peritoneum, which is incised over the aorta, just medial to the inferior mesenteric vein.

Temporary vascular occlusion before opening Gerota's fascia is a safe and effective method during exploration and renal reconstruction (69). It tends to lower blood loss and the nephrectomy rate, and appears not to increase post-operative azotaemia or mortality (70). Renal reconstruction is feasible in most cases. The overall

rate of patients who have a nephrectomy during exploration is around 13%, usually in patients with penetrating injury, and higher rates of transfusion requirements, haemodynamic instability, injury severity scores and mortality (71). Other intra-abdominal injuries also slightly increase the need for nephrectomy (72). Mortality is associated with the overall severity of the injury and is not often a consequence of the renal injury itself (73). In gunshot injuries caused by a high-velocity bullet, reconstruction can be difficult and nephrectomy is often required (14).

Renorrhaphy is the most common reconstructive technique. Partial nephrectomy is required when non-viable tissue is detected. Watertight closure of the collecting system, if open, might be desirable, although some experts merely close the parenchyma over the injured collecting system with good results. If the renal capsule is not preserved, an omental pedicle flap or peri-renal fat bolster may be used for coverage (74). In a review by Shekarriz and Stoller, the use of fibrin sealant in traumatic renal reconstruction proved to be helpful (75). Newly developed haemostatic agents such as FLOSEAL (Baxter International Inc.) that have proven useful in open and laparoscopic partial nephrectomy, might also be helpful, but are largely unproven in the trauma setting. In all cases, drainage of the ipsilateral retroperitoneum is recommended to provide an outlet for any temporary leakage of urine.

Renovascular injuries are uncommon. They are associated with extensive associated trauma and increased peri- and post-operative mortality and morbidity. Blunt renal artery injury is rare. Non-operative management should be considered as an acceptable therapeutic option (76).

Following blunt trauma, repair of grade 5 vascular injury is seldom if ever effective (77). Repair could be attempted in those very rare cases in which there is a solitary kidney or the patient has sustained bilateral injuries (78). In all other cases, nephrectomy appears to be the treatment of choice (79). In a recent review, it appears that nephrectomy for main renal artery injury has outcomes similar to those of vascular repair, and it does not worsen post-treatment renal function in the short term. Non-operative management for segmental renal artery injury results in excellent outcomes (80).

Angiography with selective renal embolisation for haemorrhage control is a reasonable alternative to laparotomy provided that no other indication for immediate surgery exists (81). Cure of haematuria after superselective transarterial embolisation is reported as high as 98% (82). Successful haemostasis by embolisation is reported to be identical in blunt and penetrating injuries (83, 84). The complication rate is minimal, and it has been proven effective for grade 4 injuries where conservative therapy failed (85). In our series, embolisation failed when applied to grade 5 injuries (85).

2.4.3 Non-operative management of renal injuries

As the indications for renal exploration become clearer, non-operative management has become the treatment of choice for the majority of renal injuries. In stable patients, supportive care with bed-rest, hydration and antibiotics is the preferred initial approach (7). Primary conservative management is associated with a lower rate of nephrectomy without any increase in the immediate or long-term morbidity (86). The failure of conservative therapy is low (1.1%) (6).

All grade 1 and 2 renal injuries can be managed non-operatively, whether due to blunt or penetrating trauma. Therapy of grade 3 injuries has been controversial, but recent studies support expectant treatment (87-89). Patients diagnosed with urinary extravasation in solitary injuries can be managed without major intervention and a resolution rate of > 90% (90). Persistent bleeding is the main indication for a reconstruction attempt (91).

The majority of patients with grade 4 and 5 renal injuries present with major associated injuries, and consequently experience high exploration and nephrectomy rates (92), although emerging data indicate that many of these patients can be managed safely with an expectant approach. Although almost all grade 4 patients with penetrating injury require renal exploration, only 20% of those with blunt trauma do (93). Isolated grade 4 renal injuries represent a unique situation to treat the patient based solely on the extent of the renal injury, thus non-operative management is used more frequently. Persistent bleeding represents the main indication for renal exploration and reconstruction. In all cases of severe renal injury, non-operative management should occur only after complete renal staging in haemodynamically stable patients (91).

Penetrating wounds have traditionally been approached surgically. However, stable patients should undergo complete staging to define the full extent of the injury. Renal gunshot injuries should be explored only if they involve the hilum or are accompanied by signs of continued bleeding, ureteral injuries, or renal pelvis lacerations (94).

Low-velocity gunshot and stab wounds of minor degree may be managed conservatively with an acceptably good outcome (95). Tissue damage from high-velocity gunshot injuries, on the other hand, might be more extensive and nephrectomy could be required. Non-operative management of renal gunshot wounds in selected stable patients is associated with a high rate of success (96-98).

If the site of penetration by stab wound is posterior to the anterior axillary line, 88% of such renal injuries can be managed non-operatively (99). Injuries to the flank are more likely to be grade 3, while injuries to the abdomen are more likely to be grade 1. A systematic approach based on clinical, laboratory and radiological evaluation might minimise negative exploration without increasing morbidity from missed injury (61). Renal stab wounds producing major renal injuries (grade 3 or higher) are more unpredictable and are associated with a higher rate of delayed complications if treated expectantly (100).

2.4.4 Recommendations

Recommendations	GR
• Following grade 1-4 blunt renal trauma, stable patients should be managed conservatively with bed-rest, prophylactic antibiotics and continuous monitoring of vital signs until haematuria resolves	B
• Following grade 1-3 stab and low-velocity gunshot wounds, stable patients, after complete staging, should be selected for expectant management	B
• Indications for surgical management include: • haemodynamic instability • exploration for associated injuries • expanding or pulsatile peri-renal haematoma identified during laparotomy • grade 5 injury	
• incidental finding of pre-existing renal pathology requiring surgical therapy	B
• Renal reconstruction should be attempted in cases where the primary goal of controlling haemorrhage is achieved and a sufficient amount of renal parenchyma is viable	B

GR = grade of recommendation

2.4.5 Post-operative care and follow-up

Patients who are successfully treated conservatively carry some risk of complications. This risk correlates with increasing grade. Repeat imaging 2-4 days after trauma minimises the risk of missed complications, especially in grade 3-5 blunt renal injuries (101). However, the utility of frequent CT scanning after injury has never been satisfactorily proven. CT scans should always be performed on patients with fever, unexplained decreasing haematocrit, or significant flank pain.

Nuclear renal scans are useful for documenting and tracking functional recovery in patients following renal reconstruction before discharge from hospital (97). To detect many of the delayed complications, an excretory urogram is recommended within 3 months of major renal injury, although benefit to the patient has not yet been proven in the literature. Follow-up should involve physical examination, urinalysis, individualised radiological investigation, serial blood pressure measurement and serum determination of renal function (60, 64). Follow-up examinations should continue until healing is documented and laboratory findings have stabilised, although checking for latent renovascular hypertension may need to continue for years (102).

The literature is generally inadequate on the subject of the long-term consequences of trauma on renal tissue. It appears that on histopathological evaluation, renal tissue may appear dystrophic following some cases of conservative management of minor renal injuries (103).

2.4.6 Recommendations

Recommendations	GR
• Repeat imaging is recommended for all hospitalised patients within 2-4 days of significant renal trauma (although no specific data exists). Repeat imaging is always recommended in cases of fever, flank pain, or falling haematocrit	B
• Nuclear scintigraphy before discharge from the hospital is useful for documenting functional recovery	C
• Within 3 months of major renal injury, patients' follow-up should involve: 1. physical examination	C

	2. urinalysis 3. individualised radiological investigation 4. serial blood pressure measurement 5. serum determination of renal function	
•	Long-term follow-up should be decided on a case-by-case basis but should at the very least involve monitoring for renovascular hypertension	C

GR = grade of recommendation

2.4.7 Complications

Early complications occur within the first month after injury and can be bleeding, infection, peri-nephric abscess, sepsis, urinary fistula, hypertension, urinary extravasation and urinoma. Delayed complications include bleeding, hydronephrosis, calculus formation, chronic pyelonephritis, hypertension, arteriovenous fistula, hydronephrosis and pseudoaneurysms.

Delayed retroperitoneal bleeding usually occurs within several weeks of an injury or procedure and may be life-threatening. Selective angiographic embolisation is the preferred treatment (104). Peri-nephric abscess formation is usually best managed by percutaneous drainage, although open drainage may sometimes be required (60). Percutaneous management of complications may pose less risk of renal loss than re-operation, which may lead to nephrectomy when infected tissues make reconstruction difficult.

Renal trauma is a rare cause of hypertension, mostly in young men. The frequency of post-traumatic hypertension is estimated to be less than 5% in all published series (105, 106). Hypertension may occur acutely as a result of external compression from peri-renal haematoma (Page kidney), or chronically because of compressive scar formation (Goldblatt kidney). Hypertension is usually renin-dependent and associated with parenchymal injury. Renin-mediated hypertension may occur as a long-term complication; aetiologies include renal artery thrombosis, segmental arterial thrombosis, renal artery stenosis (Goldblatt kidney), devitalised fragments and arteriovenous fistulae. Arteriography is informative in cases of post-traumatic hypertension (107). Treatment is required if the hypertension persists, and could include medical management, excision of the ischaemic parenchymal segment, vascular reconstruction, or total nephrectomy (108).

Urinary extravasation after renal reconstruction often subsides without intervention as long as ureteral obstruction and infection are not present. Ureteral retrograde stenting may improve drainage and allow healing (109). Persistent urinary extravasation from an otherwise viable kidney after blunt trauma often responds to stent placement and/or percutaneous drainage as necessary (63).

Arteriovenous fistulae usually present with delayed onset of significant haematuria, most often after penetrating trauma. Percutaneous embolisation is often effective for symptomatic arteriovenous fistulae, but larger ones may require surgery (110).

The development of pseudoaneurysm is a rare complication following blunt renal trauma. In numerous case reports, transcatheter embolisation appears to be a reliable minimally invasive solution (111, 112).

Acute renal colic from a retained missile has been reported, and can be managed endoscopically if possible (113). Other unusual late complications, such as duodenal obstruction, may result from retroperitoneal haematoma following blunt renal trauma (114).

2.4.8 Recommendations

Recommendations		GR
•	Complications following renal trauma require a thorough radiographic evaluation	B
•	Medical management and minimally invasive techniques should be the first choice for the management of complications	C
•	Renal salvage should be the surgeon's aim for patients in whom surgical intervention is necessary	C

GR = grade of recommendation

2.4.9 Paediatric renal trauma

Blunt renal trauma is the most common injury seen in children and accounts for more than 90% of renal injuries in the paediatric population (115, 116). Children are more susceptible to renal trauma than adults. Differences in anatomy and physiology, as well as the higher incidence of pre-existing renal disease, make children

more likely to sustain injury. The kidneys are lower in the abdomen, less well-protected by the lower ribs and muscles of the flank and abdomen, more mobile, have less protective peri-renal fat and are proportionately larger in the abdomen than in adults (117-119).

History and physical examination are very important factors in the evaluation of the paediatric patient with suspected renal trauma. Unlike adults, hypotension is an unreliable sign in children, as an outpouring of catecholamines can maintain blood pressure despite a significant volume of blood loss. Hypotension is less common in children, and significant injury can be present despite stable blood pressures (120). Another important difference from adults is that children with microscopic haematuria or normal urinalyses and stable vital signs may have sustained significant renal injury (121). Haematuria is an important clinical sign of paediatric renal injury and is directly related to the severity of that renal injury and the presence of associated injuries (122).

The radiographic evaluation of children with suspected renal trauma is still controversial. Stein *et al*. proposed that all paediatric patients with any degree of haematuria should be evaluated for renal trauma (123). In contrast, Morey et al. concluded that significant injuries are unlikely in the absence of gross or significant microscopic haematuria (> 50 rbc/hpf) (124). Nguyen and Das proposed a low threshold for renal imaging following renal trauma. The instances of its use should include patients with blunt abdominal trauma with any level of haematuria, patients with associated abdominal injury regardless of the findings of urinalysis, and patients with normal urinalyses but in whom the mechanism of injury has a high index of suspicion for renal trauma (i.e. rapid deceleration event, direct flank trauma, falls from a height) (125). After studying 720 paediatric trauma cases, Santucci et al. concluded that the decision for imaging based on the adult criteria of gross haematuria, shock and significant deceleration injury is appropriate (126).

Ultrasound is considered a reliable method of screening and following the course of renal injury in paediatric patients with blunt renal trauma in Europe, although it is used much less frequently in the USA (127, 128). Ultrasound is used in some centres, mostly in stable cases with abnormal urinalyses and/or findings suggestive of a major injury (129). The diagnostic accuracy of IVP is superior to that of ultrasound, and should be performed as an emergency procedure if CT scan is not available (130).

CT is the best imaging modality, however, and those with multiple injuries or suspected renal trauma should be evaluated by contrast-enhanced CT if possible (131, 132). The use of MRI in paediatric patients with vesicoureteral reflux found that MRI at 1.5 T was better than dimercaptosuccinic acid (DMSA) scans in detecting small renal parenchymal lesions (133), although MRI has little proven use in the acute management of the trauma patient.

Conservative treatment for grade 1-2 renal injuries is clearly defined, and these injuries should be managed expectantly (134). Non-operative management results in an excellent long-term outcome in the majority of cases (135). Non-operative management of high grade renal injuries is effective and is recommended for stable children, but requires close clinical observation, serial CT, and frequent reassessment of the patient's overall condition (136).

The length of hospital stay does not increase with worsening severity of renal injury, but is determined by the severity of non-renal injuries (137). Haemodynamic instability and a diagnosed grade 5 injury are the strongest indications for operative management (59, 120, 136). Stable patients with urinary extravasation can also be managed expectantly since most urinomas resolve spontaneously. In cases where there is persistent leakage, the placement of a ureteral stent or percutaneous drainage is feasible and curative in most cases. Early placement of a ureteral stent can be considered for paediatric patients with blunt renal trauma who demonstrate an absence of contrast material in the ipsilateral ureter, as clinical indications for stent placement will likely develop (138).

Major kidney trauma has significant consequences on the opposite side. Post-traumatic functional evaluation by DMSA scintigraphy 8 days after major injury is a valid prognostic indicator of later function, but its clinical utility has never been established.
Children with renal injuries that fail with non-surgical therapy appear to do so in a median time of 4 hours, but the majority of patients fail within the first 24 hours (139). The failure rate of non-surgical management for renal injuries is 3% (140). Buckley and McAninch presented an algorithm for the management of paediatric renal injuries based on the 25 year experience of the San Francisco General Hospital, which is highly recommended (135) (Figure 1).

Mild renal injuries do not require follow-up imaging. Follow-up is only recommended for patients with major injuries as there is an increased risk of delayed complications and loss of renal function (139).

The majority of patients with severe renal injuries develop parenchymal scars. Radionuclide scans such as DMSA can be useful in the early diagnosis of scars and consequent hypertension (141).

2.4.10 Recommendations

Recommendations		GR
•	Indications for radiographic evaluation of children suspected of renal trauma include:	
1.	blunt and penetrating trauma patients with any level of haematuria	
2.	patients with associated abdominal injury regardless of the findings of urinalysis	
3.	patients with normal urinalyses who sustained a rapid deceleration event, direct flank trauma, or a fall from a height	B
•	Ultrasonography is considered a reliable method of screening and monitoring blunt renal injuries by some researchers, but is not universally accepted	B
•	CT scanning is the imaging study of choice for staging renal injuries	B
•	Haemodynamic instability and a diagnosed grade 5 injury are absolute indications for surgical exploration	B

GR = grade of recommendation

2.4.11 Renal injury in the polytrauma patient

Approximately 8-10% of blunt and penetrating abdominal injuries involve the kidneys. The incidence of associated injury in penetrating renal trauma ranges from 77-100%. Gunshot wounds are associated with organ injury more often than are stab wounds. The majority of patients with penetrating renal trauma have associated adjacent organ injuries that may complicate treatment. In the absence of an expanding haematoma with haemodynamic instability, associated multiorgan injuries do not increase the risk of nephrectomy (142).

Blunt and penetrating trauma equally contributed to combined renal and pancreatic injury, as reported by Rosen and McAninch (143). Renal preservation was achieved in most patients, and the complication rate of the series was 15% (143). A similar rate of complications (16%) was reported in patients with simultaneous colon and renal injury. In a report reviewing this combination of injuries over a period of 17 years, 58% of patients underwent an exploration, with nephrectomies performed in 16% of explorations (144).

Renal injuries seem to be rather rare in patients with blunt chest trauma. In a recent study of polytrauma patients, conservative management was safely attempted without increasing morbidity (145). In polytrauma patients undergoing partial or total nephrectomy, there is no increased mortality or renal failure rate (146).

2.4.12 Recommendations

Recommendations		GR
•	Polytrauma patients with associated renal injuries should be evaluated on the basis of the most threatening injury	C
•	In cases where surgical intervention is chosen, all associated injuries should be evaluated simultaneously	C
•	The decision for conservative management should consider all injuries independently	C

GR = grade of recommendation

2.5 Iatrogenic renal injuries

2.5.1 Iatrogenic vascular injuries

Iatrogenic main renal artery injuries with perforation or rupture are rare. They are usually reported after renal artery angioplasty or stenting, and have an incidence of 1.6% (147). One case of an iatrogenic renal artery perforation as a complication of cardiac catheterisation has also been reported (148). Since most iatrogenic renal artery lesions occur during endovascular procedures, there are no reports on the clinical symptoms, but only on the angiographic findings. Arteriovenous fistulae, pseudoaneurysms, arterial dissection or contrast extravasation are the possible radiological findings in these traumatic vascular lesions.

Traditional therapy for renal perforation has been renal artery ligation followed by bypass grafting or nephrectomy, but nowadays the treatment for acute iatrogenic rupture of the main renal artery is balloon tamponade. However, in case of failure, the immediate availability of a stent graft is vital.

Patients with iatrogenic operative injuries are strikingly different from those with penetrating, blunt or catheter-related vascular trauma. Renal vessels are vulnerable during oncological procedures. Factors that increase technical difficulty are previous operation, tumour recurrence, radiation exposure and chronic inflammatory changes.

Renal vein injuries during elective abdominal operations represent a serious complication with significant morbidity. Most patients with operative venous injuries have partial lacerations that can be managed with relatively simple techniques, such as venorrhaphy. Patch angioplasty with autologous vein or polytetrafluoroethylene (ePTFE) graft may be required if venorrhaphy is not possible (149).

Some renal vascular injuries, such as pseudoaneurysms following nephron-sparing surgery, can be managed by transcatheter embolisation (150).

2.5.2 Renal transplantation

The orthotopic kidney is protected from external force by muscles, Gerota's fascia and peri-nephric fat. A renal graft is located in the lower pelvis in the iliac fossa and is therefore more susceptible to injury, especially from direct blows to the abdomen. The transplanted kidney, unlike the native kidney, is fixed in position by a thick fibrotic capsule that develops post-transplant. Also, the transplant kidney is not suspended by the renal vessels, so deceleration events that cause pedicle injury to a native kidney are less likely to affect a transplanted kidney (151). As transplant recipients return to more active lifestyles, including a significant risk of becoming a trauma victim, a renal graft is liable to be severely affected by trauma that might not cause any injury to a native kidney.

In transplant recipients it is very important to know patients' baseline renal function (152). The knowledge of an abnormal renal baseline may prevent unnecessary extensive diagnostic evaluation. Radiographic evaluation should proceed as for the native kidney. The increased risk for contrast nephrotoxicity can be minimised with adequate hydration.

A CT scan is the test of choice for a stable injured transplant recipient, as it will identify renal and associated intra-abdominal injuries and will also indirectly assess renal blood flow and function. A renal duplex examination can be also very helpful for identifying isolated trauma to the transplanted kidney and for identifying renal blood flow. Radionuclide scans might reveal urine leaks and are good for assessing overall blood flow and renal function, while angiography can assess blood flow and identify specific arterial injuries.

The surgical management of an injured transplanted kidney is complex. A very short vascular pedicle and ureter, dense scarring, and a fibrous capsule may prevent any attempt at the direct repair of the parenchymal, collecting system and vascular pedicle injuries. Grade 1-3 injuries can be managed non-operatively. Grade 4-5 injuries might require exploration with debridement and drainage. Major injuries could require a subcapsular nephrectomy. Renovascular injuries have a poor prognosis. Renal arteriography may be helpful with embolisation of the main artery to stop bleeding, or with more selective embolisation to salvage part of the kidney. When renal graft injury occurs, saving the patient's life is the first priority, but saving the graft is also very important to maintain renal function.

Iatrogenic vascular injuries of renal transplants can be managed by embolisation. Angiographic embolisation often fails, and is associated with a high complication rate and high eventual nephrectomy rate (153). On the other hand, transcatheter embolisation is highly effective for biopsy-related vascular injury in the transplanted kidney.

2.5.3 Percutaneous renal procedures

Percutaneous nephrostomy is achieved in nearly all patients without major complications. Haematuria is common for a few days, but massive retroperitoneal haemorrhage is rare. Small subcapsular renal haematomas resolve spontaneously, while arteriovenous-calyceal fistulae are best managed by angiographic embolisation.

If a nephrostomy catheter is seen to transfix the renal pelvis, the possibility of injury to a large renal artery must be considered. The misplaced nephrostomy catheter should be withdrawn over a guidewire, and renal artery embolisation might enable rapid arrest of a life-threatening haemorrhage (154). In more complex cases, CT could be used to detect possible catheter malposition and successfully guide catheter repositioning into the renal collecting system (155).

Renal pelvis injuries can occur during percutaneous nephrostomy placement. Haemorrhage can be prevented

by avoiding puncture in anticoagulated or coagulopathic patients, careful puncture on to target calyceals, and avoidance of medial punctures. A pelvic injury is less likely to happen if the dilator is not advanced further than the calyx, the peelaway sheaths are handled with care, especially when advanced around the pelviureteric junction, and kinking of the guidewires is avoided (156).

Percutaneous renal biopsy is a relatively safe procedure. Haemorrhage, arteriovenous fistula and renal capsular artery pseudoaneurysm might occur. Arteriovenous fistula might present with severe hypertension and is managed by embolisation (157). A pseudoaneurysm should be suspected if the patient presents with flank pain and decreasing haematocrit without haematuria. Arteriography and transarterial embolisation is the appropriate therapy (158).

Percutaneous nephrolithotomy (PCNL) is a popular procedure in which stones in the renal pelvis are removed via a nephroscope, often after ultrasonic or electrohydraulic disruption. The complications include haemorrhage, extravasation and absorption of large volumes of irrigation fluid, fever, infection, colonic perforation, arteriovenous fistulae, and pneumothorax.

Extravasation of fluid is often due to a tear in the pelvicalyceal system. A close watch on irrigation fluid input and output is required for early recognition of the complication. Termination of the procedure if the renal pelvis is torn or ruptured is a safe choice. Apart from intraoperative evaluation of serum electrolytes, acid-base status and oxygenation, the monitoring of airway pressure is a good indicator of this complication. Metabolic acidosis, hyponatraemia, hypokalaemia, peritonism and ileus are due to absorption of large volumes of irrigation fluids. Management of this complication requires close monitoring, placement of an abdominal or retroperitoneal drain, correction of acidosis and supportive measures (159).

The diagnosis of a colon injury during or after percutaneous renal surgery can be elusive because symptoms are often variable. An unrecognised or untreated colon injury can result in abscess formation, septicaemia, and/or nephrocolic or colocutaneous fistula. Surgical exploration is inevitable when the patient experiences haemorrhage, pneumoperitoneum and peritonitis.

The majority of these cases can be successfully managed conservatively. The consistent application of proper techniques, avoidance of puncturing the kidney lateral to the posterior axillary line, and puncture of the upper pole calyx when feasible, will help prevent the injuries.

Vascular injuries with renal bleeding are quite frequent and can occur at any stage of the percutaneous procedure, requiring transfusion in 1-11% of cases. A high number of punctures and incorrect choice of puncture site (access that is too medial or direct puncture of the renal pelvis) have been suggested as the cause of vascular lesions after percutaneous procedures. Renal bleeding can arise from both venous and arterial lesions. Bleeding from venous vessels could be profuse at the end of a procedure, but is generally controlled by simple measures, such as placing the patient supine to reduce abdominal compression, positioning a nephrostomy catheter, and forcing diuresis through hydration and parenteral administration of mannitol after clamping of the nephrostomy catheter. In the case of major venous trauma with massive haemorrhage, patients with concomitant renal insufficiency can be treated without open exploration or angiographic embolisation using a Council balloon catheter (160).

Arterial lesions may induce acute or late post-operative bleeding. Severe acute bleeding usually arises from injury to the anterior or posterior segmental arteries. Delayed bleeding is usually caused by interlobar and lower pole artery lesions, often arteriovenous fistulae and post-traumatic aneurysms. Duplex ultrasound and CT angiography can diagnose vascular injuries.

Hyperselective renal embolisation is considered the most appropriate technique for the treatment of iatrogenic vascular lesions. It is essential to identify the precise site of the lesion so as to be as selective as possible and reduce the risk of renal dysfunction. Hyperselective catheterisation of the renal artery branches is achieved by means of either hydrophilic 5 French catheters or coaxial systems with low profile microcatheters (2.6 French). The use of an embolic agent helps in performing a distal and irreversible occlusion with complete haemostasis. A variety of embolic materials have been used; microcoils, homologous clots, detachable balloons, polyvinyl alcohol particles, gelfoam, silicone rubber, cotton pellets and silk filaments. The choice of the embolic agent is dependent mainly on the blood flow entity at the level of the lesion, the vessel size and the operator's experience.

Finally, complications of endopyelotomy can be classified as major (vascular injury), and minor (infection,

urinoma) (161). Preventive steps, along with proper patient selection, minimise the risk for these complications.

2.5.4 RECOMMENDATIONS

Recommendations	GR
• Iatrogenic rupture of the main renal artery should be treated with balloon tamponade, and, in case of failure, with a stent graft	C
• Surgical venous injuries should be managed with venorrhaphy or patch angioplasty	C
• The transplanted kidney should be evaluated on the basis of renal function, type of injury and the patients' condition	C
• Hyperselective embolisation may control arterial bleeding during percutaneous procedures	C

GR = grade of recommendation

2.6 Suggestions for future research studies

Among the topics that would be useful subjects for future research studies are:

- blunt trauma grade 5 patients, as it appears that some of them may benefit from non-surgical management
- the necessity and nature of follow-up imaging
- the value of the administration of antibiotics in low-grade renal injuries selected for conservative management.

2.7 Algorithms

Figure 1 is an algorithm for the management of renal trauma in children. Figures 2 and 3 show the suggested treatment of blunt and penetrating renal injuries in adults.

Figure 1: Algorithm for the management of paediatric renal trauma (119)

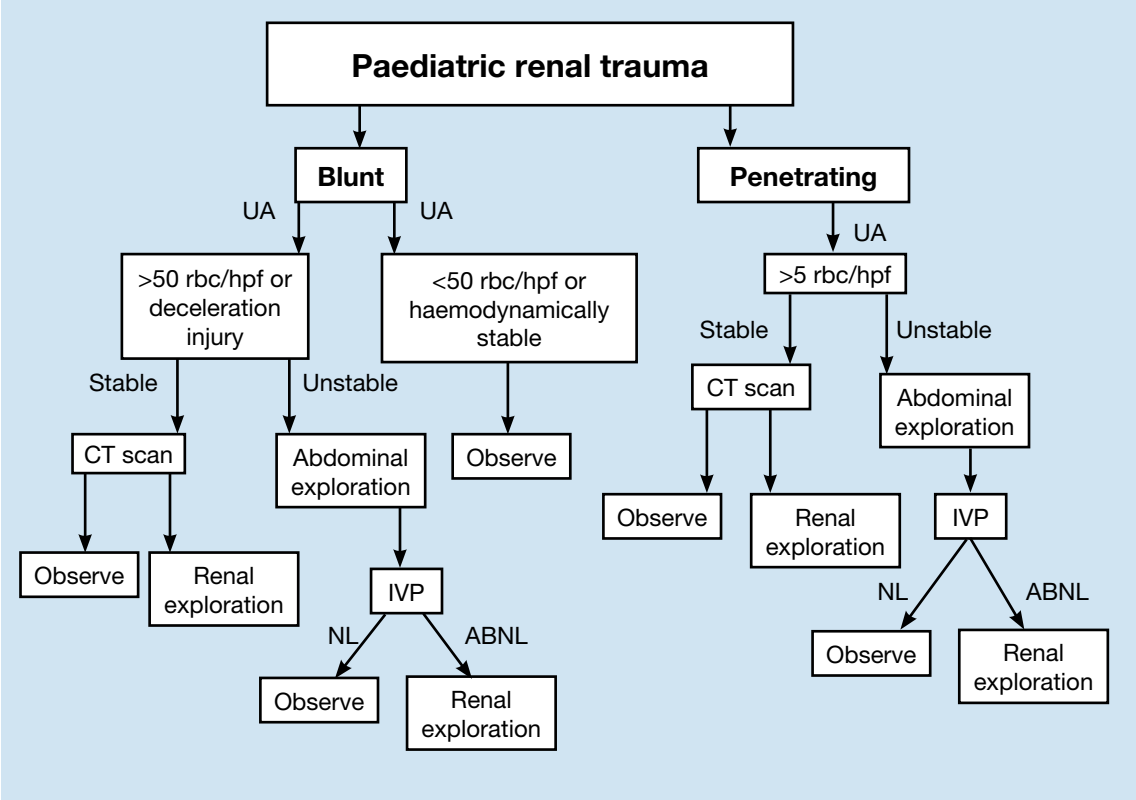

Figure 2: Evaluation of blunt renal trauma in adults

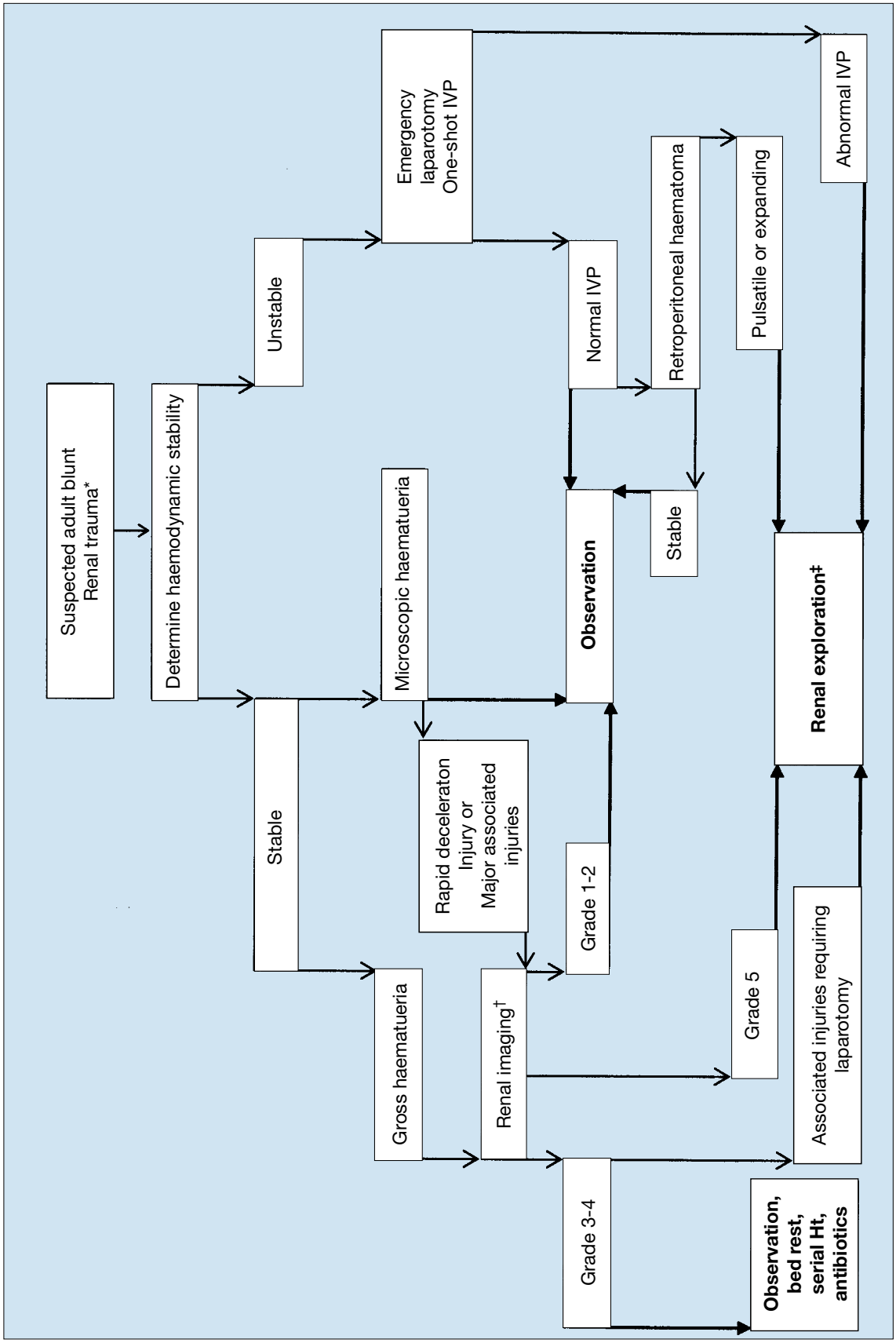

**Suspected renal trauma results from reported mechanism of injury and physical examination.*

† Renal imaging: CT scans are the gold standard for evaluating blunt and penetrating renal injuries in stable patients. In settings where the method is not available, the urologist should rely on other imaging modalities (IVP, angiography, radiographic scintigraphy, MRI).

‡ Renal exploration: Although renal salvage is a primary goal for the urologist, decisions concerning the viability of the organ and the type of reconstruction are made during the operation.

Figure 3: Evaluation of penetrating renal trauma in adults

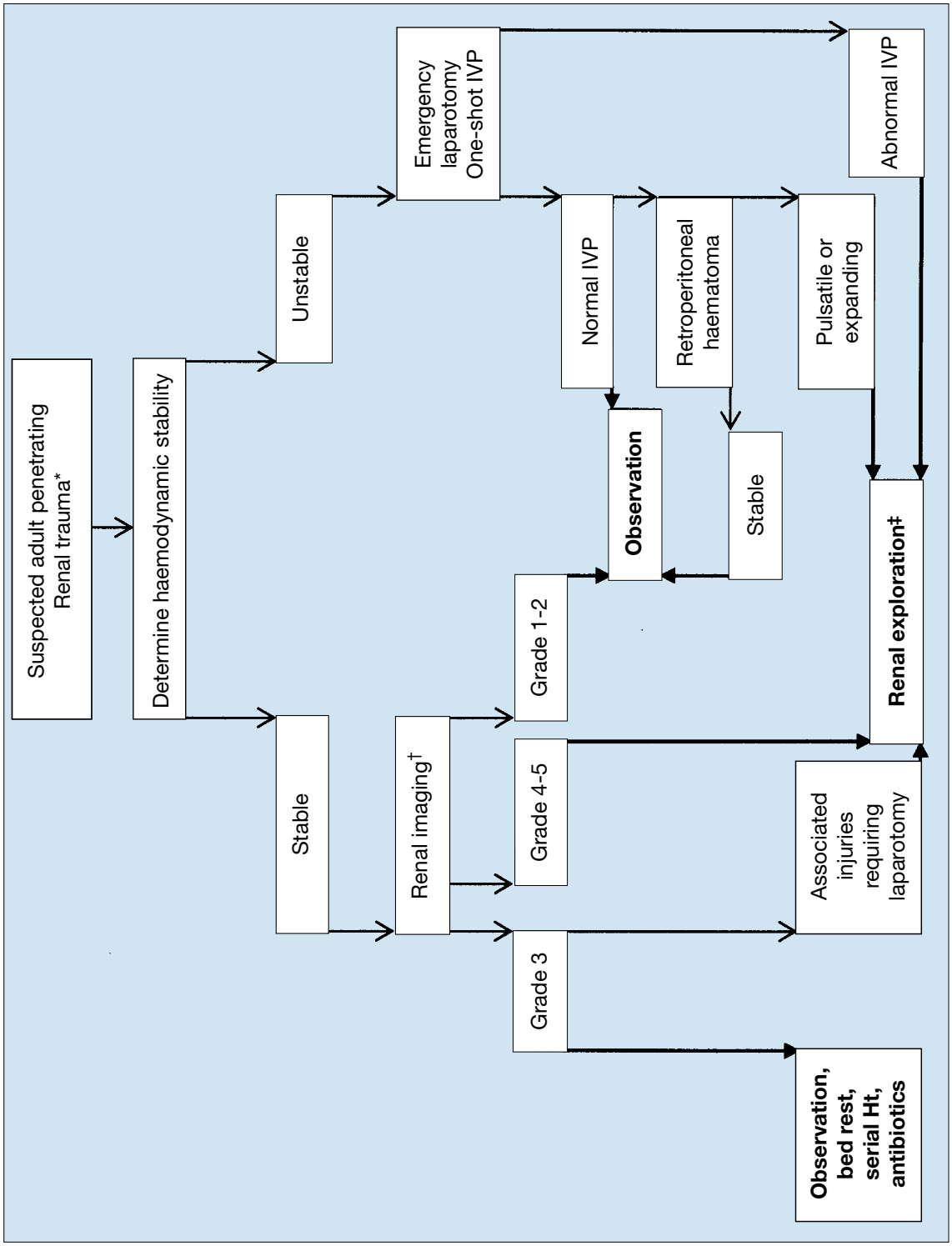

**Suspected renal trauma results from reported mechanism of injury and physical examination.*

† Renal imaging: CT scans are the gold standard for evaluating blunt and penetrating renal injuries in stable patients. In settings where the method is not available, the urologist should rely on other imaging modalities (IVP, angiography, radiographic scintigraphy, MRI).

‡ Renal exploration: Although renal salvage is a primary goal for the urologist, decisions concerning the viability of the organ and the type of reconstruction are made during the operation.

2.8 REFERENCES

1. Baverstock, R, Simons, R, McLoughlin, M. Severe blunt renal trauma: a 7-year retrospective review from a provincial trauma centre. Can J Urol 2001 Oct;8(5):1372-6. http://www.ncbi.nlm.nih.gov/pubmed/11718633
2. Meng MV, Brandes SB, McAninch JW. Renal trauma: indications and techniques for surgical exploration. World J Urol 1999 Apr;17(2):71-7. http://www.ncbi.nlm.nih.gov/pubmed/10367364
3. Paparel P, N'Diaye A, Laumon B, Caillot JL, Perrin P, Ruffion A. The epidemiology of trauma of the genitourinary system after traffic accidents: analysis of a register of over 43,000 victims. BJU Int 2006 Feb;97(2):338-41. http://www.ncbi.nlm.nih.gov/pubmed/16430642
4. Kristjánsson A, Pedersen J. Management of blunt renal trauma. Br J Urol 1993 Nov;72(5Pt2):692-6. http://www.ncbi.nlm.nih.gov/pubmed/8281396
5. Danuser H, Wille S, Zöscher G, Studer U. How to treat blunt kidney ruptures: primary open surgery or conservative treatment with deferred surgery when necessary? Eur Urol 2001 Jan;39(1):9-14. http://www.ncbi.nlm.nih.gov/pubmed/11173932
6. Hurtuk M, Reed RL 2nd, Esposito TJ, Davis KA, Luchette FA. Trauma surgeons practice what they preach. The NTDB story on solid organ injury management. J Trauma 2006 Aug;61(2):243-54; discussion 254-5. http://www.ncbi.nlm.nih.gov/pubmed/16917435
7. Santucci RA, Fisher MB. The literature increasingly supports expectant (conservative) management of renal trauma – a systematic review. J Trauma 2005 Aug;59(2):493-503. http://www.ncbi.nlm.nih.gov/pubmed/16294101
8. Santucci RA, McAninch JW. Diagnosis and management of renal trauma: past, present, and future. J Am Coll Surg 2000 Oct;191(4):443-51. http://www.ncbi.nlm.nih.gov/pubmed/11030250
9. Krieger JN, Algood CB, Mason JT, Copass MK, Ansell JS. Urological trauma in the Pacific Northwest: etiology, distribution, management and outcome. J Urol 1984 Jul;132(1):70-3. http://www.ncbi.nlm.nih.gov/pubmed/6726964
10. Brophy RH, Gamradt SC, Barnes RP, Powell JW, DelPizzo JJ, Rodeo SA, Warren RF. Kidney injuries in professional American football: implications for management of an athlete with 1 functioning kidney. Am J Sports Med 2008 Jan;36(1):85-90. http://www.ncbi.nlm.nih.gov/pubmed/17986635
11. Kuan JK, Kaufman R, Wright JL, Mock C, Nathens AB, Wessells H, Bulger E. Renal injury mechanisms of motor vehicle collisions: analysis of the crash injury research and engineering network data set. J Urol 2007 Sep;178(3Pt1):935-40; discussion 940. http://www.ncbi.nlm.nih.gov/pubmed/17632156
12. Brandes SB, McAninch JW. Urban free falls and patterns of renal injury: a 20-year experience with 396 cases. J Trauma 1999 Oct;47(4):643-9; discussion 649-50. http://www.ncbi.nlm.nih.gov/pubmed/10528597
13. Bruce LM, Croce MA, Santaniello JM, Miller PR, Lyden SP, Fabian TC. Blunt renal artery injury: incidence, diagnosis, and management. Am Surg 2001 Jun;67(6):550-4; discussion 555-6. http://www.ncbi.nlm.nih.gov/pubmed/11409803
14. Ersay A, Akgün Y: Experience with renal gunshot injuries in a rural setting. Urology 1999 Dec;54(6): 972-5. http://www.ncbi.nlm.nih.gov/pubmed/10604692
15. Abu-Zidan FM, Al-Tawheed A, Ali YM. Urologic injuries in the Gulf War. Int Urol Nephrol 1999;31(5):577-83. http://www.ncbi.nlm.nih.gov/pubmed/10755347
16. Tucak A, Lukacevic T, Kuvezdic H, Petek Z, Novak R. Urogenital wounds during the war in Croatia in 1991/1992. J Urol 1995 Jan;153(1):121-2. http://www.ncbi.nlm.nih.gov/pubmed/7966742
17. Paquette EL. Genitourinary trauma at a combat support hospital during Operation Iraqi Freedom: the impact of body armor. J Urol 2007 Jun;177(6):2196-9; discussion 2199. http://www.ncbi.nlm.nih.gov/pubmed/17509316
18. Lent V. What classification is appropriate in renal trauma? Eur Urol 1996;30(3):327-34. http://www.ncbi.nlm.nih.gov/pubmed/8931965

19. Moore EE, Shackford SR, Pachter HL, McAninch JW, Browner BD, Champion HR, Flint LM, Gennarelli TA, Malangoni MA, Ramenofsky ML. Organ injury scaling: spleen, liver, and kidney. J Trauma 1989 Dec;29(12):1664-6.
http://www.ncbi.nlm.nih.gov/pubmed/2593197
20. Shariat SF, Roehrborn CG, Karakiewicz PI, Dhami G, Stage KH. Evidence-based validation of the predictive value of the American Association for the Surgery of Trauma kidney injury scale. J Trauma 2007 Apr;62(4):933-9.
http://www.ncbi.nlm.nih.gov/pubmed/17426551
21. Santucci RA, McAninch JW, Safir M, Mario LA, Service S, Segal MR. Validation of the American Association for the Surgery of Trauma organ injury severity scale for the kidney. J Trauma 2001 Feb;50(2):195-200.
http://www.ncbi.nlm.nih.gov/pubmed/11242281
22. Kuan JK, Wright JL, Nathens AB, Rivara FP, Wessells H; American Association for the Surgery of Trauma. American Association for the Surgery of Trauma Organ Injury Scale for kidney injuries predicts nephrectomy, dialysis, and death in patients with blunt injury and nephrectomy for penetrating injuries. J Trauma 2006 Feb;60(2):351-6.
http://www.ncbi.nlm.nih.gov/pubmed/16508495
23. Sacco WJ, Copes WS, Bain LW Jr, MacKenzie EJ, Frey CF, Hoyt DB, Weigelt JA, Champion HR. Effect of preinjury illness on trauma patient survival outcome. J Trauma 1993 Oct;35(4):538-42; discussion 542-3.
http://www.ncbi.nlm.nih.gov/pubmed/8411276
24. Cachecho R, Millham FH, Wedel SK. Management of the trauma patient with pre-existing renal disease. Crit Care Clin 1994 Jul;10(3):523-36.
http://www.ncbi.nlm.nih.gov/pubmed/7922736
25. Cózar JM, Cárcamo P, Hidalgo L, Navarro J, García-Matres MJ, Ortín M, Martínez-Piñeiro JA. [Management of injury of the solitary kidney]. Arch Esp Urol 1990 Jan-Feb;43(1):15-18. [article in Spanish]
http://www.ncbi.nlm.nih.gov/pubmed/2331159
26. Sebastià MC, Rodriguez-Dobao M, Quiroga S, Pallisa E, Martinez-Rodriguez M, Alvarez-Castells A. Renal trauma in occult ureteropelvic junction obstruction: CT findings. Eur Radiol 1999;9(4):611-15.
http://www.ncbi.nlm.nih.gov/pubmed/10354870
27. Bahloul A, Krid M, Trifa M, Mosbah AT, Mhiri MN. [Contusions to the pathologic kidney. A retrospective study, apropos of 34 cases]. Ann Urol (Paris) 1997;31(5):253-8. [article in French]
http://www.ncbi.nlm.nih.gov/pubmed/9480628
28. Giannopoulos A, Serafetinides E, Alamanis C, Constantinides C, Anastasiou I, Dimopoulos C. [Urogenital lesions diagnosed incidentally during evaluation for blunt renal injuries]. Prog Urol 1999 Jun;9(3):464-9. [article in French]
http://www.ncbi.nlm.nih.gov/pubmed/10434318
29. Buchberger W, Penz T, Wicke K, Eberle J. [Diagnosis and staging of blunt kidney trauma. A comparison of urinalysis, i.v. urography, sonography and computed tomography]. Rofo 1993 Jun;158(6):507-12. [article in German]
http://www.ncbi.nlm.nih.gov/pubmed/8507839
30. Carroll PR, McAninch JW, Klosterman P, Greenblatt M. Renovascular trauma: risk assessment, surgical management, and outcome. J Trauma 1990 May;30(5):547-52; discussion 553-4.
http://www.ncbi.nlm.nih.gov/pubmed/2342137
31. Eastham JA, Wilson TG, Larsen DW, Ahlering TE. Angiographic embolization of renal stab wounds. J Urol 1992 Aug;148(2Pt1):268-70.
http://www.ncbi.nlm.nih.gov/pubmed/1635114
32. Schmidlin FR, Iselin CE, Naimi A, Rohner S, Borst F, Farshad M, Niederer P, Graber P. The higher injury risk of abnormal kidneys in blunt renal trauma. Scand J Urol Nephrol 1998 Dec;32(6):388-92.
http://www.ncbi.nlm.nih.gov/pubmed/9925001
33. Chandhoke PS, McAninch JW. Detection and significance of microscopic hematuria in patients with blunt renal trauma. J Urol 1988 Jul;140(1):16-18.
http://www.ncbi.nlm.nih.gov/pubmed/3379684
34. Miller KS, McAninch JW. Radiographic assessment of renal trauma: our 15-year experience. J Urol 1995 Aug;154(2Pt1):352-5.
http://www.ncbi.nlm.nih.gov/pubmed/7609096
35. Hardeman SW, Husmann DA, Chinn HK, Peters PC. Blunt urinary tract trauma: identifying those patients who require radiological diagnostic studies. J Urol 1987 Jul;138(1):99-101.
http://www.ncbi.nlm.nih.gov/pubmed/3599230

36. McAndrew JD, Corriere JN Jr. Radiographic evaluation of renal trauma: evaluation of 1103 consecutive patients. Br J Urol 1994 Apr;73(4):352-4.
http://www.ncbi.nlm.nih.gov/pubmed/8199819
37. Mee SL, McAninch JW. Indications for radiographic assessment in suspected renal trauma. Urol Clin North Am 1989 May;16(2):187-92.
http://www.ncbi.nlm.nih.gov/pubmed/2652848
38. Brown DF, Rosen CL, Wolfe RE. Renal ultrasonography. Emerg Med Clin North Am 1997 Nov;15(4): 877-93.
http://www.ncbi.nlm.nih.gov/pubmed/9391497
39. Arena F, Peracchia G, di Stefano C, Sebastio N, Cortellini P. [The role of echotomography in minor renal traumatology]. Acta Biomed Ateneo Parmense 1997;68(3-4):53-7. [article in Italian]
http://www.ncbi.nlm.nih.gov/pubmed/10068351
40. Qin R, Shao G, Yu M. [The diagnosis and treatment of blunt renal trauma]. Zhonghua Wai Ke Za Zhi 1996 Aug;34(8):505-7. [article in Chinese]
http://www.ncbi.nlm.nih.gov/pubmed/9594202
41. Pollack HM, Wein AJ. Imaging of renal trauma. Radiology 1989 Aug;172(2):297-308.
http://www.ncbi.nlm.nih.gov/pubmed/2664858
42. Valentino M, Serra C, Zironi G, De Luca C, Pavlica P, Barozzi L. Blunt abdominal trauma: emergency contrast-enhanced sonography for detection of solid organ injuries. AJR Am J Roentgenol 2006 May;186(5):1361-7.
http://www.ncbi.nlm.nih.gov/pubmed/16632732
43. McGahan JP, Richards JR, Jones CD, Gerscovich EO. Use of ultrasonography in the patient with acute renal trauma. J Ultrasound Med 1999 Mar;18(3):207-13; quiz 215-6.
http://www.ncbi.nlm.nih.gov/pubmed/10082355
44. Rosales A, Arango O, Coronado J, Vesa J, Maristany J, Gelabert A. The use of ultrasonography as the initial diagnostic exploration in blunt renal trauma. Urol Int 1992;48(2):134-7.
http://www.ncbi.nlm.nih.gov/pubmed/1585506
45. Qin R, Wang P, Qin W, Wang H, Chen B. Diagnosis and treatment of renal trauma in 298 patients. Chin J Traumatol 2002 Feb;5(1):21-3.
http://www.ncbi.nlm.nih.gov/pubmed/11835751
46. Morey AF, McAninch JW, Tiller BK, Duckett CP, Carroll PR. Single shot intraoperative excretory urography for the immediate evaluation of renal trauma. J Urol 1999 Apr;161(4):1088-92.
http://www.ncbi.nlm.nih.gov/pubmed/10081844
47. Patel VG, Walker ML. The role of 'one-shot' intravenous pyelogram in evaluation of penetrating abdominal trauma. Am Surg 1997 Apr;63(4):350-3.
http://www.ncbi.nlm.nih.gov/pubmed/9124757
48. Nagy KK, Brenneman FD, Krosner SM, Fildes JJ, Roberts RR, Joseph KT, Smith RF, Barrett J. Routine preoperative 'one-shot' intravenous pyelography is not indicated in all patients with penetrating abdominal trauma. J Am Coll Surg 1997 Dec;185(6):530-3.
http://www.ncbi.nlm.nih.gov/pubmed/9404875
49. Steinberg DL, Jeffrey RB, Federle MP, McAninch JW. The computerized tomography appearance of renal pedicle injury. J Urol 1984 Dec;132(6):1163-4.
http://www.ncbi.nlm.nih.gov/pubmed/6502811
50. Kawashima A, Sandler CM, Corl FM, West OC, Tamm EP, Fishman EK, Goldman SM. Imaging of renal trauma: a comprehensive review. Radiographics 2001 May-Jun;21(3):557-74.
http://www.ncbi.nlm.nih.gov/pubmed/11353106
51. Shima H, Nosaka S, Hayakawa M, Kawaguchi H, Wakabayashi M, Saeki M, Yamaguchi T, Nakajima Y, Ishikawa T. [Diagnostic imaging of renal pedicle injury]. Nippon Igaku Hoshasen Gakkai Zasshi 1997 Jan;57(1):5-11. [article in Japanese]
http://www.ncbi.nlm.nih.gov/pubmed/9038056
52. Vasile M, Bellin MF, Hélénon O, Mourey I, Cluzel P. Imaging evaluation of renal trauma. Abdom Imaging 2000 Jul-Aug;25(4):424-30.
http://www.ncbi.nlm.nih.gov/pubmed/10926198
53. Brown SL, Hoffman DM, Spirnak JP. Limitations of routine spiral computerized tomography in the evaluation of blunt renal trauma. J Urol 1998 Dec;160(6Pt1):1979-81.
http://www.ncbi.nlm.nih.gov/pubmed/9817304
54. Ortega SJ, Netto FS, Hamilton P, Chu P, Tien HC. CT scanning for diagnosing blunt ureteral and ureteropelvic junction injuries. BMC Urol 2008 Feb;8:3.
http://www.ncbi.nlm.nih.gov/pubmed/18257927

55. Velmahos GC, Constantinou C, Tillou A, Brown CV, Salim A, Demetriades D. Abdominal computed tomographic scan for patients with gunshot wounds to the abdomen selected for nonoperative management. J Trauma 2005 Nov;59(5):1155-60; discussion 1160-1.
http://www.ncbi.nlm.nih.gov/pubmed/16385294
56. Leppäniemi A, Lamminen A, Tervahartiala P, Salo J, Haapiainen R, Lehtonen T. MRI and CT in blunt renal trauma: an update. Semin Ultrasound CT MR 1997 Apr;18(2):129-35.
http://www.ncbi.nlm.nih.gov/pubmed/9163832
57. Ku JH, Jeon YS, Kim ME, Lee NK, Park YH. Is there a role for magnetic resonance imaging in renal trauma? Int J Urol 2001 Jun;8(6):261-7.
http://www.ncbi.nlm.nih.gov/pubmed/11389740
58. Shariat SF, Trinh QD, Morey AF, Stage KH, Roehrborn CG, Valiquette L, Karakiewicz PI. Development of a highly accurate nomogram for prediction of the need for exploration in patients with renal trauma. J Trauma 2008 Jun;64(6):1451-8.
http://www.ncbi.nlm.nih.gov/pubmed/18545108
59. Husmann DA, Gilling PJ, Perry MO, Morris JS, Boone TB. Major renal lacerations with a devitalized fragment following blunt abdominal trauma: a comparison between nonoperative (expectant) versus surgical management. J Urol 1993 Dec;150(6):1774-7.
http://www.ncbi.nlm.nih.gov/pubmed/8230501
60. McAninch JW, Carroll PR, Klosterman PW, Dixon CM, Greenblatt MN. Renal reconstruction after injury. J Urol 1991 May;145(5):932-7.
http://www.ncbi.nlm.nih.gov/pubmed/2016804
61. Armenakas NA, Duckett CP, McAninch JW. Indications for nonoperative management of renal stab wounds. J Urol 1999 Mar;161(3):768-71.
http://www.ncbi.nlm.nih.gov/pubmed/10022681
62. Altman AL, Haas C, Dinchman KH, Spirnak JP. Selective nonoperative management of blunt grade 5 renal injury. J Urol 2000 Jul;164(1):27-30;discussion 30-1.
http://www.ncbi.nlm.nih.gov/pubmed/10840417
63. Matthews LA, Smith EM, Spirnak JP. Nonoperative treatment of major blunt renal lacerations with urinary extravasation. J Urol 1997 Jun;157(6):2056-8.
http://www.ncbi.nlm.nih.gov/pubmed/9146579
64. Moudouni SM, Hadj Slimen M, Manunta A, Patard JJ, Guiraud PH, Guillé F, Bouchot O, Lobel B. Management of major blunt renal lacerations: is a nonoperative approach indicated? Eur Urol 2001 Oct;40(4):409-14.
http://www.ncbi.nlm.nih.gov/pubmed/11713395
65. Husmann DA, Morris JS. Attempted nonoperative management of blunt renal lacerations extending through the corticomedullary junction: the short-term and long-term sequelae. J Urol 1990 Apr;143(4): 682-4.
http://www.ncbi.nlm.nih.gov/pubmed/2313792
66. Hammer CC, Santucci RA. Effect of an institutional policy of nonoperative treatment of grades I to IV renal injuries. J Urol 2003 May;169(5):1751-3.
http://www.ncbi.nlm.nih.gov/pubmed/12686825
67. Robert M, Drianno N, Muir G, Delbos O, Guiter J. Management of major blunt renal lacerations: surgical or nonoperative approach? Eur Urol 1996;30(3):335-9.
http://www.ncbi.nlm.nih.gov/pubmed/8931966
68. Nash PA, Bruce JE, McAninch JW. Nephrectomy for traumatic renal injuries. J Urol 1995 Mar; 153(3 Pt 1):609-11.
http://www.ncbi.nlm.nih.gov/pubmed/7861494
69. Gonzalez RP, Falimirski M, Holevar MR, Evankovich C. Surgical management of renal trauma: is vascular control necessary? J Trauma 1999 Dec;47(6):1039-42; discussion 1042-4.
http://www.ncbi.nlm.nih.gov/pubmed/10608530
70. Atala A, Miller FB, Richardson JD, Bauer B, Harty J, Amin M. Preliminary vascular control for renal trauma. Surg Gynecol Obstet 1991 May;172(5):386-90.
http://www.ncbi.nlm.nih.gov/pubmed/2028374
71. Davis KA, Reed RL 2nd, Santaniello J, Abodeely A, Esposito TJ, Poulakidas SJ, Luchette FA. Predictors of the need for nephrectomy after renal trauma. J Trauma 2006 Jan;60(1):164-9; discussion 169-70.
http://www.ncbi.nlm.nih.gov/pubmed/16456451
72. Wright JL, Nathens AB, Rivara FP, Wessells H. Renal and extrarenal predictors of nephrectomy from the national trauma data bank. J Urol 2006 Mar;175(3Pt1):970-5; discussion 975.
http://www.ncbi.nlm.nih.gov/pubmed/16469594

73. DiGiacomo JC, Rotondo MF, Kauder DR, Schwab CW. The role of nephrectomy in the acutely injured. Arch Surg 2001 Sep;136(9):1045-9.
http://www.ncbi.nlm.nih.gov/pubmed/11529828
74. McAninch JW, Dixon CM, Carroll PR. [The surgical treatment of renal trauma]. Vestn Khir Im I I Grek 1990 Nov;145(11):64-72. [article in Russian]
http://www.ncbi.nlm.nih.gov/pubmed/1966179
75. Shekarriz B, Stoller ML. The use of fibrin sealant in urology. J Urol 2002 Mar;167(3):1218-25.
http://www.ncbi.nlm.nih.gov/pubmed/11832701
76. Sangthong B, Demetriades D, Martin M, Salim A, Brown C, Inaba K, Rhee P, Chan L. Management and hospital outcomes of blunt renal artery injuries: analysis of 517 patients from the National Trauma Data Bank. J Am Coll Surg 2006 Nov;203(5):612-7.
http://www.ncbi.nlm.nih.gov/pubmed/17084321
77. Knudson MM, Harrison PB, Hoyt DB, Shatz DV, Zietlow SP, Bergstein JM, Mario LA, McAninch JW. Outcome after major renovascular injuries: a Western trauma association multicenter report. J Trauma 2000 Dec;49(6):1116-22.
http://www.ncbi.nlm.nih.gov/pubmed/11130498
78. Tillou A, Romero J, Asensio JA, Best CD, Petrone P, Roldan G, Rojo E. Renal vascular injuries. Surg Clin North Am 2001 Dec;81(6):1417-30.
http://www.ncbi.nlm.nih.gov/pubmed/11766183
79. el Khader K, Bouchot O, Mhidia A, Guillé F, Lobel B, Buzelin JM. [Injuries of the renal pedicle: is renal revascularization justified?]. Prog Urol 1998 Dec;8(6):995-1000. [article in French]
http://www.ncbi.nlm.nih.gov/pubmed/9894257
80. Elliott SP, Olweny EO, McAninch JW. Renal arterial injuries: a single center analysis of management strategies and outcomes. J Urol 2007 Dec;178(6):2451-5.
http://www.ncbi.nlm.nih.gov/pubmed/17937955
81. Hagiwara A, Sakaki S, Goto H, Takenega K, Fukushima H, Matuda H, Shimazaki S. The role of interventional radiology in the management of blunt renal injury: a practical protocol. J Trauma 2001 Sep;51(3):526-31.
http://www.ncbi.nlm.nih.gov/pubmed/11535904
82. Mohsen T, El-Assmy A, El-Diasty T. Long-term functional and morphological effects of transcatheter arterial embolization of traumatic renal vascular injury. BJU Int 2008 Feb;101(4):473-7.
http://www.ncbi.nlm.nih.gov/pubmed/17941919
83. Velmahos GC, Chahwan S, Falabella A, Hanks SE, Demetriades D. Angiographic embolization for intraperitoneal and retroperitoneal injuries. World J Surg 2000 May;24(5):539-45.
http://www.ncbi.nlm.nih.gov/pubmed/10787073
84. Sofocleous CT, Hinrichs C, Hubbi B, Brountzos E, Kaul S, Kannarkat G, Bahramipour P, Barone A, Contractor DG, Shah T. Angiographic findings and embolotherapy in renal arterial trauma. Cardiovasc Intervent Radiol 2005 Jan-Feb;28(1):39-47.
http://www.ncbi.nlm.nih.gov/pubmed/15602636
85. Breyer BN, McAninch JW, Elliott SP, Master VA. Minimally invasive endovascular techniques to treat acute renal hemorrhage. J Urol 2008 Jun;179(6):2248-52; discussion 2253.
http://www.ncbi.nlm.nih.gov/pubmed/18423679
86. Schmidlin FR, Rohner S, Hadaya K, Iselin CE, Vermeulen B, Khan H, Farshad M, Niederer P, Graber P. [The conservative treatment of major kidney injuries]. Ann Urol (Paris) 1997;31(5):246-52. [article in French]
http://www.ncbi.nlm.nih.gov/pubmed/9480627
87. el Khader K, Mhidia A, Ziade J, Patard JJ, Guillé F, Lobel B. [Conservative treatment of stage III kidney injuries]. Acta Urol Belg 1998 Dec;66(4):25-8. [article in French]
http://www.ncbi.nlm.nih.gov/pubmed/10083630
88. Thall EH, Stone NN, Cheng DL, Cohen EL, Fine EM, Leventhal I, Aldoroty RA. Conservative management of penetrating and blunt Type III renal injuries. Br J Urol 1996 Apr;77(4):512-7.
http://www.ncbi.nlm.nih.gov/pubmed/8777609
89. Cheng DL, Lazan D, Stone N. Conservative treatment of type III renal trauma. J Trauma 1994 Apr;36(4):491-4.
http://www.ncbi.nlm.nih.gov/pubmed/8158708
90. Alsikafi NF, McAninch JW, Elliott SP, Garcia M. Nonoperative management outcomes of isolated urinary extravasation following renal lacerations due to external trauma. J Urol 2006 Dec;176(6Pt1):2494-7.
http://www.ncbi.nlm.nih.gov/pubmed/17085140

91. Buckley JC, McAninch JW. Selective management of isolated and nonisolated grade IV renal injuries. J Urol 2006 Dec;176(6Pt1):2498-502; discussion 2502.
http://www.ncbi.nlm.nih.gov/pubmed/17085141
92. Santucci RA, McAninch JM. Grade IV renal injuries: evaluation, treatment, and outcome. World J Surg 2001 Dec;25(12):1565-72.
http://www.ncbi.nlm.nih.gov/pubmed/11775193
93. Shariat SF, Jenkins A, Roehrborn CG, Karam JA, Stage KH, Karakiewicz PI. Features and outcomes of patients with grade IV renal injury. BJU Int 2008 Sep;102(6):728-33; discussion 733.
http://www.ncbi.nlm.nih.gov/pubmed/18435808
94. Velmahos GC, Demetriades D, Cornwell EE 3rd, Belzberg H, Murray J, Asensio J, Berne TV. Selective management of renal gunshot wounds. Br J Surg 1998 Aug;85(8):1121-4.
http://www.ncbi.nlm.nih.gov/pubmed/9718011
95. Baniel J, Schein M. The management of penetrating trauma to the urinary tract. J Am Coll Surg 1994 Apr;178(4):417-25.
http://www.ncbi.nlm.nih.gov/pubmed/8149045
96. DuBose J, Inaba K, Teixeira PG, Pepe A, Dunham MB, McKenney M. Selective non-operative management of solid organ injury following abdominal gunshot wounds. Injury 2007 Sep;38(9): 1084-90.
http://www.ncbi.nlm.nih.gov/pubmed/17544428
97. Wessells H, Deirmenjian J, McAninch JW. Preservation of renal function after reconstruction for trauma: quantitative assessment with radionuclide scintigraphy. J Urol 1997 May;157(5):1583-6.
http://www.ncbi.nlm.nih.gov/pubmed/9112481
98. Shefler A, Gremitzky A, Vainrib M, Tykochinsky G, Shalev M, Richter S, Erlich N, Schiwartz I, Leibovitch I. [The role of nonoperative management of penetrating renal trauma]. Harefuah 2007 May;146(5):345-8, 406-7. [article in Hebrew.]
http://www.ncbi.nlm.nih.gov/pubmed/17674549
99. Bernath AS, Schutte H, Fernandez RR, Addonizio JC. Stab wounds of the kidney: conservative management in flank penetration. J Urol 1983 Mar;129(3):468-70.
http://www.ncbi.nlm.nih.gov/pubmed/6834529
100. Wessells H, McAninch JW, Meyer A, Bruce J. Criteria for nonoperative treatment of significant penetrating renal lacerations. J Urol 1997 Jan;157(1):24-7.
http://www.ncbi.nlm.nih.gov/pubmed/8976207
101. Blankenship JC, Gavant ML, Cox CE, Chauhan RD, Gingrich JR. Importance of delayed imaging for blunt renal trauma. World J Surg 2001 Dec;25(12):1561-4.
http://www.ncbi.nlm.nih.gov/pubmed/11775192
102. Dunfee BL, Lucey BC, Soto JA. Development of renal scars on CT after abdominal trauma: does grade of injury matter? AJR Am J Roentgenol 2008 May;190(5):1174-9.
http://www.ncbi.nlm.nih.gov/pubmed/18430828
103. Pruthi RS, Issa MM, Kabalin JN, Terris MK. Renal masses presenting 25 and 50 years following blunt renal trauma. Urol Int 1998 Oct;61(1):43-6.
http://www.ncbi.nlm.nih.gov/pubmed/9792983
104. Heyns CF, van Vollenhoven P. Increasing role of angiography and segmental artery embolization in the management of renal stab wounds. J Urol 1992 May;147(5):1231-4.
http://www.ncbi.nlm.nih.gov/pubmed/1569655
105. Monstrey SJ, Beerthuizen GI, vander Werken C, Debruyne FM, Goris RJ. Renal trauma and hypertension. J Trauma 1989 Jan;29(1):65-70.
http://www.ncbi.nlm.nih.gov/pubmed/2911106
106. Lebech A, Strange-Vognsen HH. [Hypertension following blunt kidney injury]. Ugeskr Laeger 1990 Apr;152(14):994-7. [article in Danish]
http://www.ncbi.nlm.nih.gov/pubmed/2183457
107. Montgomery RC, Richardson JD, Harty JI. Posttraumatic renovascular hypertension after occult renal injury. J Trauma 1998 Jul;45(1):106-10.
http://www.ncbi.nlm.nih.gov/pubmed/9680021
108. Chedid A, Le Coz S, Rossignol P, Bobrie G, Herpin D, Plouin PF. Blunt renal trauma-induced hypertension: prevalence, presentation, and outcome. Am J Hypertens 2006 May;19(5):500-4.
http://www.ncbi.nlm.nih.gov/pubmed/16647623
109. Haas CA, Reigle MD, Selzman AA, Elder JS, Spirnak JP. Use of ureteral stents in the management of major renal trauma with urinary extravasation: is there a role? J Endourol 1998 Dec;12(6):545-9.
http://www.ncbi.nlm.nih.gov/pubmed/9895260

110. Wang KT, Hou CJ, Hsieh JJ, Chou YS, Tsai CH. Late development of renal arteriovenous fistula following gunshot trauma – a case report. Angiology 1998 May;49(5):415-18.
http://www.ncbi.nlm.nih.gov/pubmed/9591535
111. Franco de Castro A, Gibanel Garanto R, Real MI, Rodríguez Casado A, Cetina Herrando A, Gutiérrez del Pozo R, Montanyà X, Vázquez F, Alcover García JB. [Selective embolization of post-traumatic renal pseudoaneurysm in monorenal patient]. Actas Urol Esp 2001 Jan;25(1):64-6. [article in Spanish]
http://www.ncbi.nlm.nih.gov/pubmed/11284371
112. Miller DC, Forauer A, Faerber GJ. Successful angioembolization of renal artery pseudoaneurysms after blunt abdominal trauma. Urology 2002 Mar;59(3):444.
http://www.ncbi.nlm.nih.gov/pubmed/11880095
113. Harrington TG, Kandel LB. Renal colic following a gunshot wound to the abdomen: the birdshot calculus. J Urol 1997 Apr;157(4):1351-2.
http://www.ncbi.nlm.nih.gov/pubmed/9120940
114. Park JK, Yang SO, Park SC. Duodenal obstruction by retroperitoneal hematoma induced by severe blunt renal trauma. J Urol 2001 Jun;165(6Pt1):1993-4.
http://www.ncbi.nlm.nih.gov/pubmed/11371904
115. McAleer IM, Kaplan GW, Scherz HC, Packer MG, Lynch FP. Genitourinary trauma in the pediatric patient. Urology 1993 Nov;42(5):563-7; discussion 567-8.
http://www.ncbi.nlm.nih.gov/pubmed/8236601
116. Morse TS: Renal injuries. Pediatr Clin North Am 1975 May;22(2):379-91.
http://www.ncbi.nlm.nih.gov/pubmed/1124221
117. Elshihabi I, Elshihabi S, Arar M. An overview of renal trauma. Curr Opin Pediatr 1998 Apr;10(2):162-6.
http://www.ncbi.nlm.nih.gov/pubmed/9608894
118. Brown SL, Elder JS, Spirnak JP. Are pediatric patients more susceptible to major renal injury from blunt trauma? A comparative study. J Urol 1998 Jul;160(1):138-40.
http://www.ncbi.nlm.nih.gov/pubmed/9628634
119. Chopra P, St-Vil D, Yazbeck S. Blunt renal trauma-blessing in disguise? J Pediatr Surg 2002 May;37(5):779-82.
http://www.ncbi.nlm.nih.gov/pubmed/11987100
120. Quinlan DM, Gearhart JP. Blunt renal trauma in childhood. Features indicating severe injury. Br J Urol 1990 Nov;66(5):526-31.
http://www.ncbi.nlm.nih.gov/pubmed/2249124
121. Angus LD, Tachmes L, Kahn S, Gulmi F, Gintautas J, Shaftan GW. Surgical management of pediatric renal trauma: an urban experience. Am Surg 1993 Jun;59(6):388-94.
http://www.ncbi.nlm.nih.gov/pubmed/8507066
122. Stalker HP, Kaufman RA, Stedje K. The significance of hematuria in children after blunt abdominal trauma. AJR Am J Roentgenol 1990 Mar;154(3):569-71.
http://www.ncbi.nlm.nih.gov/pubmed/2106223
123. Stein JP, Kaji DM, Eastham J, Freeman JA, Esrig D, Hardy BE. Blunt renal trauma in the pediatric population: indications for radiographic evaluation. Urology 1994 Sep;44(3):406-10.
http://www.ncbi.nlm.nih.gov/pubmed/8073555
124. Morey AF, Bruce JE, McAninch JW. Efficacy of radiographic imaging in pediatric blunt renal trauma. J Urol 1996 Dec;156(6):2014-18.
http://www.ncbi.nlm.nih.gov/pubmed/8911380
125. Nguyen MM, Das S. Pediatric renal trauma. Urology 2002 May;59(5):762-6; discussion 766-767.
http://www.ncbi.nlm.nih.gov/pubmed/11992916
126. Santucci RA, Langenburg SE, Zachareas MJ. Traumatic hematuria in children can be evaluated as in adults. J Urol 2004 Feb;171(2Pt1):822-5.
http://www.ncbi.nlm.nih.gov/pubmed/14713834
127. Luks FI, Lemire A, St-Vil D, Di Lorenzo M, Filiatrault D, Ouimet A. Blunt abdominal trauma in children: the practical value of ultrasonography. J Trauma 1993 May;34(5):607-10; discussion 610-1.
http://www.ncbi.nlm.nih.gov/pubmed/8496996
128. Wessel LM, Jester I, Scholz S, Arnold R, Lorenz C, Wirth H, Waag KL. [Diagnostic and therapeutic consequences of kidney injuries in pediatric blunt abdominal trauma]. Urologe A 2000 Sep;39(5): 425-31. [article in German]
http://www.ncbi.nlm.nih.gov/pubmed/11045043
129. Perez-Brayfield MR, Gatti JM, Smith EA, Broecker B, Massad C, Scherz H, Kirsch AJ. Blunt traumatic hematuria in children. Is a simplified algorithm justified? J Urol 2002 Jun;167(6):2543-6; discussion 2546-7.
http://www.ncbi.nlm.nih.gov/pubmed/11992085

130. Mayor B, Gudinchet F, Wicky S, Reinberg O, Schnyder P. Imaging evaluation of blunt renal trauma in children: diagnostic accuracy of intravenous pyelography and ultrasonography. Pediatr Radiol 1995;25(3):214-8.
http://www.ncbi.nlm.nih.gov/pubmed/7644308
131. Turnock RR, Sprigg A, Lloyd DA. Computed tomography in the management of blunt abdominal trauma in children. Br J Surg 1993 Aug;80(8):982-4.
http://www.ncbi.nlm.nih.gov/pubmed/8402096
132. Carpio F, Morey AF. Radiographic staging of renal injuries. World J Urol 1999 Apr;17(2):66-70.
http://www.ncbi.nlm.nih.gov/pubmed/10367363
133. Takeda M, Katayama Y, Tsutsui T, Takahashi H, Komeyama T, Mizusawa T, Sato S. Value of dimercaptosuccinic acid single photon emission computed tomography and magnetic resonance imaging in detecting renal injury in pediatric patients with vesicoureteral reflux. Comparison with dimercaptosuccinic acid planar scintigraphy and intravenous pyelography. Eur Urol 1994;25(4):320-5.
http://www.ncbi.nlm.nih.gov/pubmed/8056025
134. Levy JB, Baskin LS, Ewalt DH, Zderic SA, Bellah R, Snyder HM 3rd, Templeton J, Duckett JW. Nonoperative management of blunt pediatric major renal trauma. Urology 1993 Oct;42(4):418-24.
http://www.ncbi.nlm.nih.gov/pubmed/8212441
135. Buckley JC, McAninch JW. Pediatric renal injuries: management guidelines from a 25-year experience. J Urol 2004 Aug;172(2):687-90; discussion 690.
http://www.ncbi.nlm.nih.gov/pubmed/15247762
136. Henderson CG, Sedberry-Ross S, Pickard R, Bulas DI, Duffy BJ, Tsung D, Eichelberger MR, Belman AB, Rushton HG. Management of high grade renal trauma: 20-year experience at a pediatric level I trauma center. J Urol 2007 Jul;178(1):246-50; discussion 250.
http://www.ncbi.nlm.nih.gov/pubmed/17499798
137. Broghammer JA, Langenburg SE, Smith SJ, Santucci RA. Pediatric blunt renal trauma: its conservative management and patterns of associated injuries. Urology 2006 Apr;67(4):823-7.
http://www.ncbi.nlm.nih.gov/pubmed/16566992
138. Cannon GM Jr, Polsky EG, Smaldone MC, Gaines BA, Schneck FX, Bellinger MF, Docimo SG, Wu HY. Computerized tomography findings in pediatric renal trauma – indications for early intervention? J Urol 2008 Apr;179(4):1529-32; discussion 1532-3.
http://www.ncbi.nlm.nih.gov/pubmed/18295268
139. Nance ML, Holmes JH 4th, Wiebe DJ. Timeline to operative intervention for solid organ injuries in children. J Trauma 2006 Dec;61(6):1389-92.
http://www.ncbi.nlm.nih.gov/pubmed/17159681
140. Holmes JH 4th, Wiebe DJ, Tataria M, Mattix KD, Mooney DP, Scaife ER, Brown RL, Groner JI, Brundage SI, Tres Scherer LR 3rd, Nance ML. The failure of nonoperative management in pediatric solid organ injury: a multi-institutional experience. J Trauma 2005 Dec;59(6):1309-13.
http://www.ncbi.nlm.nih.gov/pubmed/16394902
141. Surana R, Khan A, Fitzgerald RJ. Scarring following renal trauma in children. Br J Urol 1995 May;75(5): 663-5.
http://www.ncbi.nlm.nih.gov/pubmed/7613804
142. Kansas BT, Eddy MJ, Mydlo JH, Uzzo RG. Incidence and management of penetrating renal trauma in patients with multiorgan injury: extended experience at an inner city trauma center. J Urol 2004 Oct;172(4Pt1):1355-60.
http://www.ncbi.nlm.nih.gov/pubmed/15371841
143. Rosen MA, McAninch JW. Management of combined renal and pancreatic trauma. J Urol 1994 Jul;152(1):22-5.
http://www.ncbi.nlm.nih.gov/pubmed/8201670
144. Wessells H, McAninch JW. Effect of colon injury on the management of simultaneous renal trauma. J Urol 1996 Jun;155(6):1852-6.
http://www.ncbi.nlm.nih.gov/pubmed/8618272
145. Sartorelli KH, Frumiento C, Rogers FB, Osler TM. Nonoperative management of hepatic, splenic, and renal injuries in adults with multiple injuries. J Trauma. 2000 Jul;49(1):56-61; discussion 61-2.
http://www.ncbi.nlm.nih.gov/pubmed/10912858
146. Cass AS, Luxenberg M, Gleich P, Smith C. Deaths from urologic injury due to external trauma. J Trauma 1987 Mar;27(3):319-21.
http://www.ncbi.nlm.nih.gov/pubmed/3560276
147. Morris CS, Bonnevie GJ, Najarian KE. Nonsurgical treatment of acute iatrogenic renal artery injuries occurring after renal artery angioplasty and stenting. AJR Am J Roentgenol 2001 Dec;177(6):1353-7.
http://www.ncbi.nlm.nih.gov/pubmed/11717082

148. Bates MC, Shamsham FM, Faulknier B, Crotty B. Successful treatment of iatrogenic renal artery perforation with an autologous vein-covered stent. Catheter Cardiovasc Interv 2002 Sep;57(1):39-43. http://www.ncbi.nlm.nih.gov/pubmed/12203925
149. Oderich GS, Panneton JM, Hofer J, Bower TC, Cherry KJ Jr, Sullivan T, Noel AA, Kalra M, Gloviczki P. Iatrogenic operative injuries of abdominal and pelvic veins: a potentially lethal complication. J Vasc Surg 2004 May;39(5):931-6. http://www.ncbi.nlm.nih.gov/pubmed/15111840
150. Taneja M, Tan KT. Renal vascular injuries following nephron-sparing surgery and their endovascular management. Singapore Med J 2008 Jan;49(1):63-6. http://www.ncbi.nlm.nih.gov/pubmed/18204772
151. Barone GW, Sailors DM, Hudec WA, Ketel BL. Trauma management in solid organ transplant recipients. J Emerg Med 1997 Mar-Apr;15(2):169-76. http://www.ncbi.nlm.nih.gov/pubmed/9144057
152. Del Pizzo JJ, Jacobs SC, Sklar GN. Ureteroscopic evaluation in renal transplant recipients. J Endourol 1998 Apr;12(2):135-8. http://www.ncbi.nlm.nih.gov/pubmed/9607439
153. Dorffner R, Thurnher S, Prokesch R, Bankier A, Turetschek K, Schmidt A, Lammer J. Embolization of iatrogenic vascular injuries of renal transplants: immediate and follow-up results. Cardiovasc Intervent Radiol 1998 Mar-Apr;21(2):129-34. http://www.ncbi.nlm.nih.gov/pubmed/9502679
154. Cowan NC, Traill ZC, Phillips AJ, Gleeson FV. Direct percutaneous transrenal embolization for renal artery injury following percutaneous nephrostomy. Br J Radiol 1998 Nov;71(851):1199-201. http://www.ncbi.nlm.nih.gov/pubmed/10434916
155. Jones CD, McGahan JP. Computed tomographic evaluation and guided correction of malpositioned nephrostomy catheters. Abdom Imaging 1999 Jul-Aug;24(4):422-5. http://www.ncbi.nlm.nih.gov/pubmed/10390572
156. Lewis S, Patel U. Major complications after percutaneous nephrostomy – lessons from a department audit. Clin Radiol 2004 Feb;59(2):171-9. http://www.ncbi.nlm.nih.gov/pubmed/14746788
157. Ozdemir S, Cekirge S, Kara A, Bakkaloglu A. A rare complication of renal biopsy in a child with membranoproliferative glomerulonephritis. Int Urol Nephrol 1998;30(6):689-92. http://www.ncbi.nlm.nih.gov/pubmed/10195861
158. Silberzweig JE, Tey S, Winston JA, Mitty HA. Percutaneous renal biopsy complicated by renal capsular artery pseudoaneurysm. Am J Kidney Dis 1998 Mar;31(3):533-5. http://www.ncbi.nlm.nih.gov/pubmed/9506693
159. Ghai B, Dureja GP, Arvind P. Massive intraabdominal extravasation of fluid: a life threatening complication following percutaneous nephrolithotomy. Int Urol Nephrol 2003;35(3):315-18. http://www.ncbi.nlm.nih.gov/pubmed/15160530
160. Gupta M, Bellman GC, Smith AD. Massive hemorrhage from renal vein injury during percutaneous renal surgery: endourological management. J Urol 1997 Mar;157(3):795-7. http://www.ncbi.nlm.nih.gov/pubmed/9072568
161. Bellman GC. Complications of endopyelotomy. J Endourol 1996 Apr;10(2):177-81. http://www.ncbi.nlm.nih.gov/pubmed/8728685

3. URETERAL TRAUMA

3.1 Introduction

The ureter is the sole conduit for urinary transport between the kidney and the bladder. Thus, any ureteral injury can threaten the function of the ipsilateral kidney. This small, mobile, worm-like, peristalsing, urothelial-lined tube runs inferiorly from the renal pelvis in the retroperitoneal space. It lies anterior to the muscles of the posterior abdominal wall and lateral to the vertebral column, before descending into the bony ring of the pelvis to enter the bladder. Any external injury to the flank or back and any calamity within the bony pelvis therefore places the ureter at risk. Perhaps because of its protected location, its small size and its mobility, trauma to the ureter is relatively rare and accounts for only 1% of all urinary tract trauma. Thus, there is a relatively small volume of published clinical experience upon which to base recommendations of management.

3.2 Aetiology

The largest and most contemporary review of ureteral trauma in the European literature is from Dobrowolski et al. in Poland (1). These authors retrospectively analyzed the records of patients with upper urinary tract injuries presenting to 61 urology departments between 1995 and 1999. They identified 452 ureteral injuries. Of these, 340 (75%) were iatrogenic, 81 (18%) were from blunt trauma, and 31 (7%) were from penetrating trauma. Of the 340 iatrogenic injuries, 247 (73%) were gynaecological in origin, 46 (14%) were general surgical and 47 (14%) were urological. It is therefore important to note that ureteral injury is much more likely to occur from activity within a hospital rather than from injuries sustained outside. Dobrowolski et al. estimate the frequency of ureteral injury during gynaecological pelvic surgical procedures to be 1.6 per 1000 (1). Of the total ureteral injuries identified, the injury was in the upper third in 60 cases (13%), in the middle third in 61 cases (13%), and in the lower third in 331 (74%). The median time to diagnosis was 3.3 h.

The most common diagnostic investigation was intravenous urography (IVU), which was used in 244 patients; retrograde ureteropyelography was used in 98 patients; and ureteral catheterization was used in 125. The diagnosis was also established at open surgery in 104 patients. This snapshot of ureteral trauma in a modern European setting is similar to that seen in the USA (2).

3.3 Diagnosis

3.3.1 Clinical diagnosis

There are no classic clinical symptoms and signs associated with acute ureteral trauma caused by external injury (3). In view of this, the diagnosis must be one of suspicion. Ureteral trauma should be suspected in all cases of penetrating abdominal injury, especially gunshot wounds, and also in cases of blunt deceleration trauma, in which the kidney and renal pelvis can be torn away from the ureter. This deceleration injury is more likely to occur in children because of their hyperextensible vertebral column (4). Haematuria is also a poor indicator of injury, as it is present in only half of those with ureteral trauma (5).

It is possible for isolated ureteral injuries to be missed. Such patients tend to present with subsequent evidence of upper tract obstruction, urinary fistula formation and sepsis (6). After gynaecological pelvic surgery, any woman who complains of flank pain, develops vaginal leakage of urine or becomes septic should also be suspected of having injury to the ureter or bladder and should be investigated appropriately. At surgery, when the ureter is explored to exclude injury, the use of intravenous indigo carmine or methylene blue is to be recommended. This will help reveal the site of injury by leakage of blue-stained urine. This is especially important in partial tears.

3.3.2 Radiological diagnosis

Ureteral injury may cause radiological signs of upper urinary tract obstruction but the sine qua non of ureteral injury is extravasation of radiological contrast material (3). This sign can be produced by the use of intravenous pyelography (IVP), giving 2 mg of contrast material per kilogram of body weight. However, because of the increasing use of computed tomography (CT) scanning in polytraumatized patients, the diagnosis is increasingly made with this modality.

If a high suspicion of ureteral injury exists and the CT scan is non-diagnostic, then a ‘poor man’s IVP’can be obtained by taking a plain kidney-ureter-bladder (KUB) film 30 minutes after intravenous injection of CT contrast medium. If this is also non-diagnostic and a suspicion of injury still exists, then retrograde pyelography should be undertaken as the gold standard investigation.

3.4 Classification

The American Association for the Surgery of Trauma has classified ureteral injuries as shown in Table 4 (7).

Table 4: Classification of ureteral injury

Grade	Description of injury
I	Haematoma only
II	Laceration < 50% of circumference
III	Laceration > 50% of circumference
IV	Complete tear < 2 cm of devascularization
V	Complete tear > 2 cm of devascularization

3.5 Management

3.5.1 Partial injuries

These can be defined as grade I to II lesions. Once recognized, they can be managed with ureteral stenting or by placement of a nephrostomy tube to divert urine (3). There is no prospective clinical trial comparing outcomes between these techniques. We believe that ureteral stenting is probably superior because a stent

across the injury will allow secure drainage of the kidney, as well as providing canalization and stabilization of the injury. We believe that this will reduce the subsequent risk of stricture. The stent may be placed in an antegrade or retrograde fashion. In all cases, fluoroscopy and ureteropyelography with radio-opaque contrast should be used to guide stent placement.

The procedure should commence with the passage of a hydrophilic atraumatic guidewire across the damaged segment of ureter. Once across the site of the injury, an access catheter can be backloaded over the wire and passed across the injury. The hydrophilic wire can then be exchanged for a 0.038-inch wire, and the stent deployed. If this technique is utilized, a bladder catheter should be left in place for 2 days to limit stent reflux during voiding until mucosal healing has begun. The stent should be left in place for at least 3 weeks. The patient should have a follow-up dynamic renogram and IVP between 3 and 6 months, or sooner if lateralizing flank pain develops. If there is evidence of stricture, then this should be managed by endo-urological or open surgical techniques, as appropriate.

If a grade II or III injury is encountered during immediate surgical exploration of an iatrogenic injury, then primary closure of the ureteral ends over a stent may be recommended, with placement of an external, non suction drain adjacent to the injury.

3.5.2 Complete injuries

These are grade III to V injuries. Successful repair should utilize the principles outlined in Table 5.

Table 5: Principles of repair of complete injury

•	Debridement of ureteral ends to fresh tissue
•	Spatulation of ureteral ends
•	Placement of internal stent
•	Watertight closure of reconstructed ureter with absorbable suture
•	Placement of external, non-suction drain
•	Isolation of injury with peritoneum or omentum

The type of reconstructive repair procedure chosen by the surgeon depends on the nature and site of the injury (3). The options are depicted in Figure 4.

Figure 4: Diagram of the options for repair of complete injuries, based on the site of the injury

Upper third: Uretero-ureterostomy
Transuretero-ureterostomy
Ureterocalycostomy

Middle third: Uretero-ureterostomy
Transuretero-ureterostomy
Boari flap and reimplantation

Lower third: Direct reimplantation
Psoas hitch
Blandy cystoplasty

Complete: Ileal interposition
Autotransplantation

3.5.3 Sterile surgery

3.5.3.1 Uretero-ureterostomy

Using the principles outlined above, the ureteral ends are debrided and freshened. The ends are spatulated.

An internal JJ stent is inserted and the ends are closed over the stent using an interrupted 4/0 vicryl suture. An external, non-suction drain is placed at the site of the injury, and a catheter is left in the bladder. The bladder catheter can be removed after 2 days. The wound drain can be removed 2 days later if drainage is low. The stent should be removed after 6 weeks, and a follow-up renogram and IVP should be obtained after 3 months to assess the patency of the repair.

3.5.3.2 Ureterocalycostomy

In cases were the pelvi-ureteral junction has been destroyed, the lower pole of the affected kidney can be amputated to expose the lower pole infundibulum and calyces. The distal ureteral end can then be debrided and spatulated, and anastomosed to the lower pole calyx, over an internal stent, using an interrupted 4/0 vicryl suture. An external, non-suction drain is placed at the site of the injury and a catheter is left in the bladder. The bladder catheter can be removed after 2 days. The wound drain can be removed 2 days later if drainage is low. The stent should be removed after 6 weeks and a follow-up renogram and IVP should be obtained after 3 months to assess the patency of the repair.

3.5.3.3 Transuretero-ureterostomy

The distal end of the injured ureter is ligated with an absorbable suture. The proximal end is debrided and spatulated. This end is then transposed across the midline through a retroperitoneal window above the level of the inferior mesenteric artery. A 1.5 cm ureterotomy is made on the medial aspect of the contralateral ureter. A stent is placed from the ipsilateral kidney, through the anastomosis, and down the distal contralateral ureter into the bladder. A watertight anastomosis is fashioned using an interrupted 4/0 vicryl suture. An external, nonsuction drain is placed at the site of the injury, and a catheter is left in the bladder. The bladder catheter can be removed after 2 days. The wound drain can be removed 2 days later if drainage is low. The stent should be removed after 6 weeks, and a follow-up renogram and IVP should be obtained after 3 months to assess the patency of the repair.

3.5.3.4 Ureteroneocystostomy with Boari flap

The proximal ureteral end is debrided and spatulated. A traction suture is placed. The distal ureteral end is ligated with an absorbable suture. The bladder is filled with 200-300 ml of normal saline via a urethral catheter, and controlling stay sutures are placed on the bladder. The L-shaped flap is raised, its base being approximately four times wider than the width of the ureter to be implanted. The ureter is pulled through a submucosal tunnel in the flap and secured to the bladder mucosa using an interrupted 4/0 vicryl suture. Anchoring sutures can be placed at the serosal aspect of the ureter to secure it to the bladder. A stent is placed across the neo-ureterocystostomy, and a suprapubic catheter is placed in the bladder. The bladder is then closed in two layers with 2/0 vicryl sutures. An external, non-suction drain should be placed at the site of the reimplant; it can be removed after 2 days. The urethral catheter can be removed at the same time. The suprapubic catheter can be removed after a cystogram at 2 weeks, and the stent can be removed after 6 weeks. An IVP and renogram should be obtained 3 months thereafter to confirm the patency of the neocystostomy.

3.5.3.5 Ureterocystostomy and psoas hitch

The proximal ureteral end is debrided and spatulated. A traction suture is placed. The distal ureteral end is ligated with an absorbable suture. The fundus of the bladder is mobilized, and the contralateral superior vesical pedicle may be divided to improve fundal mobility. The bladder is filled with 200-300 ml of normal saline via a urethral catheter, and controlling stay sutures are placed. A cystotomy (Blandy) is performed perpendicular to the line of the ureter. Two fingers are placed inside the bladder to stretch it gently towards the ipsilateral psoas tendon. Three non-absorbable 2/0 sutures are placed between the bladder wall and the tendon, with care being taken to avoid the genitofemoral nerve.

Ureteroneocystostomy is then undertaken using either the Leadbetter-Politano or Lich-Gregoire techniques. A JJ stent is placed across the reimplant, and a suprapubic catheter is placed in the bladder. The bladder is then closed in two layers with 2/0 vicryl in the line of the ureter, thus providing extra length to the hitch. The anastomosis is thus under no tension. An external, non-suction drain should be placed at the site of the reimplant, and can be removed after 2 days. The urethral catheter can be removed at the same time. The suprapubic catheter can be removed after a cystogram at 2 weeks, and the stent can be removed after 6 weeks. An IVP and renogram should be obtained 3 months thereafter to confirm the patency of the neocystostomy.

3.5.3.6 Ileal interposition graft

In cases of long segment ureteral destruction, the ureter can be totally replaced using the distal ileum. This should be avoided in patients with coincidental gastrointestinal disease, such as Crohn's disease, and in

patients with impaired renal function. A 25-cm length of ileum is taken out of bowel continuity about 20 cm proximal to the ileocaecal valve. Gastrointestinal continuity is restored with an ileo-ileal anastomosis using interrupted 3/0 seromuscular vicryl. The mesenteric is repaired using 2/0 vicryl. The ileal segment is placed in the isoperistaltic orientation between the renal pelvis and the bladder. Ileo-pelvic and cysto-ileal end-to-end anastomoses are fashioned using 2/0 vicryl. A nephrostomy tube should be inserted into the ipsilateral kidney to decompress the affected upper tract. A catheter should be placed in the bladder. External, non-suction drains should cover the proximal and distal anastomoses. Lastly, the reconstruction should be wrapped in omentum.

The wound drains can be removed after 2 days. A nephrostogram should be performed after 3 weeks; if no leakage is demonstrated, the nephrostomy can be clamped and then removed. Finally, the urinary catheter can be removed. Follow-up should include IVP and renography at 3 months, together with testing for the levels of serum creatinine, chloride, bicarbonate and base excess, looking for evidence of hyperchloraemic metabolic acidosis.

3.5.3.7 Autotransplantation

If complete ureteral disruption should occur in the presence of coincidental gastrointestinal disease or impaired renal function, then autotransplantation of the affected renal unit can be undertaken. The renal artery and vein are divided long at the aorta and cava. The kidney is moved to the pelvis, and vascular continuity is restored using 5/0 prolene for the artery and 4/0 prolene for the vein. A Lich-Gregoire extravesical neoureterocystostomy can then be fashioned to re-establish urinary drainage. This need not be stented. A covering external, non-suction drain should be placed, and a catheter inserted in the bladder. The drain can be removed after 2 days, if dry, and the catheter removed after a cystogram at 2 weeks. Again, follow-up at 3 months with IVP and renogram is recommended.

3.5.3.8 Nephrectomy

There is one circumstance in which immediate nephrectomy should be undertaken. This is when ureteral injury complicates the repair of an abdominal aortic aneurysm or other vascular procedure in which a vascular prosthesis is to be implanted. We feel that immediate excision of the corrupted renal unit and its damaged ureter leads to less chance of urinary leak, urinoma, sepsis and graft infection.

3.6 REFERENCES

1. Dobrowolski Z, Kusionowicz J, Drewniak T, Habrat W, Lipczyñski W, Jakubik P and Wêglarz W. Renal and ureteric trauma: diagnosis and management in Poland. BJU Int 2002 May;89(7):748-51. http://www.ncbi.nlm.nih.gov/pubmed/11966637
2. Palmer LS, Rosenbaum RR, Gershbaum MD, Kreutzer ER. Penetrating ureteral trauma at an urban trauma center: 10-year experience. Urology 1999 Jul;54(1):34-6. http://www.ncbi.nlm.nih.gov/pubmed/10414723
3. Armenakas NA. Ureteral trauma: surgical repair. Atlas Urol Clin North Am 1998;6:71-84.
4. Morey AF, Bruce JE, McAninch JW. Efficacy of radiographic imaging in pediatric blunt renal trauma. J Urol 1996 Dec;156(6):2014-8. http://www.ncbi.nlm.nih.gov/pubmed/8911380
5. Medina D, Lavery R, Ross SE, Livingston DH. Ureteral trauma: preoperative studies neither predict injury nor prevent missed injuries. J Am Coll Surg 1998 Jun;186(6):641-4. http://www.ncbi.nlm.nih.gov/pubmed/9632150
6. McGinty DM, Mendez R. Traumatic ureteral injuries with delayed recognition. Urology 1997 Aug;10(2): 115-7. http://www.ncbi.nlm.nih.gov/pubmed/898448
7. Moore EE, Cogbill TH, Jurkovitch GJ, McAninch JW, Champion HR, Gennarelli TA, Malangoni MA, Shackford SR, Trafton PG. Organ injury scaling. III: Chest wall, abdominal vascular, ureter, bladder, and urethra. J Trauma 1992 Sep;33(3):337-9. http://www.ncbi.nlm.nih.gov/pubmed/1404499

4. BLADDER TRAUMA

4.1 Background

Among abdominal injuries that require surgical repair, 2% involve the bladder (1). Blunt or penetrating trauma account for 67-86% and 14-33% of bladder ruptures, respectively (2-4). Motor vehicle accidents are the

most common cause (90%) of bladder rupture by blunt trauma is (5-7). In the setting of blunt trauma, bladder rupture may be classified as either extraperitoneal with leakage of urine limited to the perivesical space, or intraperitoneal, in which the peritoneal surface has been disrupted, with concomitant urinary extravasation.

Bladder trauma: facts and figures

- 70-97% of patients with bladder injuries caused by blunt trauma have associated pelvic fractures (3, 8, 9).
- Pubic symphysis diastasis, sacroiliac diastasis, and sacral, iliac, and pubic rami fractures are significantly associated with bladder rupture, whereas isolated acetabular fractures are not (10, 11).
- > 50% of the associated pelvic fractures are of the pubic ramus (12).
- Up to 30% of patients with pelvic fractures will have some degree of bladder injury (13).
- Major bladder injury occurs in only 5-10% of patients who have pelvic fracture(s) (7, 14).
- > 85% of patients with pelvic fractures have associated injuries in other organ systems (8), with a mortality rate of 22-44% (12, 13, 15).
- Approximately 25% of intraperitoneal bladder ruptures occur in patients who do not have pelvic fracture(s) (7).

During a motor vehicle accident, traumatic forces can be transferred to the bladder by the seatbelt; injuries usually occur in patients with a full bladder. The degree of distension of the bladder with urine determines its shape and, to some degree, the injury it sustains. A fully distended bladder can be ruptured by a light blow; however, an empty bladder is seldom injured, except by crushing or penetrating wounds. Pelvic scars or pre-existing pelvic pathology can influence susceptibility to injury (16).

Combined intra- and extraperitoneal rupture may occur in 2-20% of cases (7, 17-19). Simultaneous bladder and prostate-membranous urethra ruptures occur in 10-29% of male patients (10). Several studies investigating pelvic fractures and associated injuries in paediatric patients reported a lower incidence of urogenital injury (7-14%) (20-23), than in comparative adult series (7, 13, 14). In seven paediatric series (20-26), the average rate of bladder injury in patients with pelvic fractures was 4%. Motor vehicle accidents were the cause of the trauma in 97% of cases (26).

4.1.1 Iatrogenic trauma

During lower abdominal operations, the bladder is the most frequently injured genitourinary organ (27). Most iatrogenic injuries occur during:

- open abdominal or pelvic surgery (85%)
- anterior vaginal surgery (9%)
- laparoscopy (6%).

The majority (92%) of these injuries are graded as III-IV, using the American Association for the Surgery of Trauma (AAST) scale (27). Most injuries occur during obstetric and gynaecological procedures (52-61%), followed by urological (12-39%) and general surgical (9-26%) interventions (27, 28). Of the general surgical operations that result in iatrogenic injury to the bladder, most involve resection of bowel as a result of malignancy, diverticulitis or inflammatory diseases (27, 28).

Bladder injury occurs during gynaecological operations in 0.3-8.3% of cases (29-34). Concurrent anti-incontinence surgery significantly increases the risk of injury to the bladder (13% vs 3%; P= 0.049) (34). Most cases of urological iatrogenic trauma occur during vaginal operations and laparoscopy (27, 28). The incidence of bladder wall perforation is generally low (1%) during transurethral resection of bladder tumours, and most (88%) can be managed by catheter drainage (35, 36). Transurethral resection of the prostate is also associated with low injury rates (37).

Routine cystoscopy is an important adjunct to the major gynaecological procedures, and its omission may result in underestimation of iatrogenic bladder injury. An extensive review of the literature indicated that in studies not involving routine cystoscopy, the frequency of bladder injury varied from 0.2/1000 to 19.5/1000, with an overall frequency of 2.6/1000. Only 52% of bladder injuries were identified and managed intraoperatively (31). In studies involving routine cystoscopy, the frequency of bladder injury varied from 0.0/1000 to 29.2/1000, with an overall frequency of 10.4/1000. Up to 85% of unsuspected bladder injuries were identified with the use of cystoscopy and were managed successfully intraoperatively (31). Routine cystoscopy is recommended after any type of incontinence surgery as it enables identification of unsuspected bladder injury in 85% of patients (31, 32, 34, 38).

Surgical procedures for the correction of stress urinary incontinence can also result in bladder trauma. The

rate of bladder injury is below 3% in Burch colposuspension (39-41). Bladder injury is the most common complication of the tension-free vaginal tape (TVT) procedure, with an incidence of 2.0-11.5% (42-47) and up to 19% in patients with prior failed incontinence surgery (48).

The transobturator tape (TOT) procedure minimizes the retropubic needle passage, and the incidence of bladder injury is expected to be low. Although during early experience with this technique rates of injury were similar to those associated with the TVT procedure (39), a recent meta-analysis indicated a lower incidence of bladder injuries (odds ratio: 0.12; 95% confidence interval: 0.05-0.33) with TOT procedures (49).

4.2 Classification

Table 6: Bladder injury scale[1]

Grade*	Description	
I	Hematoma	Contusion, intramural hematoma
	Laceration	Partial thickness
II	Laceration	Extraperitoneal bladder wall laceration <2 cm
III	Laceration	Extraperitoneal (>2 cm) or intraperitoneal (<2 cm) bladder wall laceration
IV	Laceration	Intraperitoneal bladder wall laceration >2 cm
V	Laceration	Intraperitoneal or extraperitoneal bladder wall laceration extending into the bladder neck or ureteral orifice (trigone)

**Advance one grade for multiple injuries up to grade III*
[1] Adapted from the AAST.

4.3 Risk factors

Individuals who driving under the influence of alcohol are likely to have a distended bladder and a motor vehicle accident. Driving after drinking alcohol is therefore a risk factor for bladder injury (19) (level of evidence: 3).

Concurrent anti-incontinence surgery during gynaecological procedures results in a fourfold increased risk of bladder injury, and is therefore a risk factor for iatrogenic bladder trauma (34) (level of evidence: 3).

4.4 Diagnosis

The most common signs and symptoms in patients with major bladder injuries are gross haematuria (82%) and abdominal tenderness (62%) (3). Other findings may include inability to void, bruises over the suprapubic region and abdominal distension (6). Extravasation of urine may result in swelling in the perineum, scrotum and thighs, as well as along the anterior abdominal wall within the potential space between the transversalis fascia and the parietal peritoneum.

4.4.1 Macroscopic (gross) haematuria

Gross haematuria indicates urological trauma (level of evidence: 3). Traumatic bladder rupture is strongly correlated with the combination of pelvic fracture and gross haematuria; Morey et al. reported gross haematuria in all their patients with bladder rupture, and 85% had pelvic fractures (50). Thus, the classic combination of pelvic fracture and gross haematuria constitutes an absolute indication for immediate cystography in patients who have blunt trauma (3, 7, 13, 50) (level of evidence: 3).

The presence of gross blood at the urethral meatus is diagnostic of a urethral injury (level of evidence: 3). A Foley catheter should not be inserted before a retrograde urethrogram has been carried out to ensure urethral integrity (51). Although grossly clear urine in a trauma patient without a pelvic fracture virtually eliminates the possibility of bladder rupture, 2-10% of patients with bladder rupture may have only microhaematuria or no haematuria at all (5, 51).

In a retrospective review of more than 8000 paediatric trauma patients, of those cases with pelvic fractures, only one patient (0.5%) had an extraperitoneal bladder rupture (26). Lower urogenital injury occurred in six patients (2.8%). The absence of gross haematuria ruled out serious injury in this cohort.

Based on this data, no further work-up was recommended in paediatric patients with pelvic fractures without gross haematuria. It is recommended that patients with gross haematuria, multiple associated injuries or significant abnormalities found on physical examination should be further evaluated with retrograde urethrography and cystography (level of evidence: 3).

4.4.2 Microscopic haematuria

In the trauma patient with a pelvic ring fracture, microscopic haematuria might indicate bladder laceration, and further investigation is warranted (level of evidence: 3). However, the exact quantity of blood in the urine that should trigger investigation is controversial.

- Morgan et al. reported that no ruptures were seen in patients with <25 red blood cells/high-power field (rbc/hpf) (10).
- Werkman et al. (52) concluded that if cystography had been restricted to patients with > 35-50 rbc/hpf, no perforation would have been missed in their series.
- Fuhrman et al. (53) believe that cystography in blunt trauma should be restricted to patients with gross haematuria, which they defined as > 200 rbc/hpf. They also thought that a retrograde urethrogram should be carried out first.

Existing data do not support lower urinary tract imaging in all patients with pelvic fracture or microscopic haematuria alone. Hochberg and Stone (54) concluded that cystography might be safely reserved for those patients with pelvic fracture considered to be high risk for bladder injury (significant pubic arch involvement, gross haematuria and/or haemodynamic instability), as 90% of patients in their series with pelvic fracture did not have a bladder rupture.

These observations do not appear to be valid for paediatric trauma patients. Abou-Jaoude et al. (55) reported a threshold for radiological evaluation of ≥ 20 rbc/hpf would miss 25% of cases with bladder injury. In contrast with other reported series (26), they suggested that lower urogenital tract evaluation in paediatric trauma patients, especially in the presence of pelvic fractures, should be based as much on clinical judgment as on the presence of haematuria (55) (level of evidence: 3).

4.4.3 Cystography

Retrograde cystography is the standard diagnostic procedure in the evaluation of bladder trauma (7, 13, 56-58) (level of evidence: 3). This is the most accurate radiological study to identify bladder rupture. When adequate bladder filling and post-void images are obtained, cystography has an accuracy rate of 85-100% (5, 7, 59, 60). Bladder rupture is usually diagnosed when the contrast is identified outside the bladder. Adequate distension of the urinary bladder is crucial to demonstrating perforation, especially in cases of penetrating trauma, as most instances of a false-negative retrograde cystography were found in this situation (56).

Cystography requires plain film, filled film, and post-drainage films (as a minimum) (level of evidence: 3); half-filled film and obliques are optional. For the highest diagnostic accuracy, the bladder must be distended using instillation of at least 350 mL of contrast medium by gravity. Bladder injury may be identified only on the post-drainage film in approximately 10% of cases (7). False-negative findings may result from incorrectly performed studies with less than 250 mL of contrast instillation or omission of a post-drainage film (61) (level of evidence: 3). Only a correctly performed cystography should be used to exclude bladder injury (7).

4.4.4 Excretory urography (intravenous pyelogram)

An intravenous pyelogram (IVP) is inadequate for evaluation of the bladder and urethra after trauma, not only because of dilution of the contrast material within the bladder, but also because resting intravesical pressure is simply too low to demonstrate a small tear (16, 62). An IVP has a low accuracy (15-25%) (15) , and clinical studies have indicated that IVP has an unacceptably high false-negative rate (64-84%), which precludes its use as a diagnostic tool in bladder injuries (52, 59, 63) (level of evidence: 3).

4.4.5 Ultrasound (US)

Although, the use of US in bladder rupture has been described (64), it is not routine for evaluation of bladder injury. Free peritoneal fluid in the presence of normal viscera, or failure to visualize the bladder after transurethral saline instillation, are highly suggestive of bladder rupture (66) (level of evidence: 3). Practically, however, US is not definitive in bladder or urethral trauma and is almost never used.

4.4.6 Computed tomography (CT)

CT is clearly the method of choice for the evaluation of patients with blunt or penetrating abdominal and/or pelvic trauma (level of evidence: 3). However, routine CT is not reliable in the diagnosis of bladder rupture, even if an inserted urethral catheter is clamped. CT demonstrates intraperitoneal and extraperitoneal fluid, but cannot differentiate urine from ascites.

As with IVP, the bladder is usually inadequately distended to reveal extravasation through a bladder laceration or perforation during routine abdominal and pelvic studies. Thus, a negative study cannot be entirely trusted,

and routine CT cannot exclude bladder injury (12, 16, 65).

In a review of the cystograms and CT scans (CT cystography) of 25 patients who underwent both investigations during the initial evaluation of blunt abdominal trauma, five patients were found to have bladder rupture, three of which were extraperitoneal and two intraperitoneal (66); all of the injuries were detected by both studies. It was concluded that delayed imaging or contrast instillation could provide the adequate bladder distention needed to demonstrate contrast extravasation from the injury site. Similarly, in a series of 316 patients, 44 cases were diagnosed with bladder ruptures (60). In patients who underwent a formal surgical repair, 82% had operative findings that exactly matched the CT cystography interpretation. Either retrograde cystography or CT cystography are diagnostic procedures of choice for suspected bladder injury (51).

CT cystography can be used in place of conventional cystography (overall sensitivity 95% and specificity 100%) (level of evidence: 3), especially in patients undergoing CT scanning for other associated injuries (60). However, this procedure should be performed using retrograde filling of the bladder with a minimum of 350 mL of dilute contrast material (7, 66, 67).

In conclusion, CT cystographic features may lead to accurate classification of bladder injury and allow prompt, effective treatment without further radiation exposure and the additional cost of conventional cystography (70) (level of evidence: 3).

4.4.7 Angiography

Angiography is seldom, if ever, indicated. It can be useful in identifying an occult source of bleeding and can guide its subsequent therapeutic embolization (16).

4.4.8 Magnetic resonance imaging (MRI)

It is extremely difficult to monitor a seriously injured patient in a strong magnetic field; MRI therefore has little place in the evaluation of acute bladder (16). The use of MRI has been described for later evaluation of urethral injury (69-71).

4.4.9 Cystoscopy

Mainly useful in iatrogenic trauma, routine cystoscopy identifies 85% of the unsuspected injuries to the bladder that would otherwise go unnoticed (31, 34, 39). Thus, it must be use as an adjunct to major gynaecological operations as well as surgical interventions for incontinence (level of evidence: 3).

4.5 Treatment

The first priority in the treatment of bladder injuries is stabilization of the patient and treatment of associated life-threatening injuries (level of evidence: 3).

4.5.1 Blunt trauma: extraperitoneal rupture

Most patients with extraperitoneal rupture can be managed safely by catheter drainage alone, even in the presence of extensive retroperitoneal or scrotal extravasation (61) (level of evidence: 3). Obstruction of the catheter by clots or tissue debris must be prevented for healing to occur. A success rate of >90% was reported with this approach in extraperitoneal rupture (5): 87% of the ruptures were healed in 10 days, and virtually all were healed in 3 weeks (57). However, bladder neck involvement (2), the presence of bone fragments in the bladder wall, or entrapment of the bladder wall will necessitate surgical intervention (19) (level of evidence: 3).

4.5.2 Blunt trauma: intraperitoneal rupture

Intraperitoneal ruptures occurring after blunt trauma should always be managed by surgical exploration (level of evidence: 3). This type of injury involves a high degree of force and, because of the severity of associated injuries, carries a high mortality (20-40%) ((72). Lacerations are usually large in these cases, with the potential risk of peritonitis due to urine leakage if left untreated (61). Abdominal organs should be inspected for possible associated injuries, and urinoma must be drained, if present.

4.5.3 Penetrating injuries

All bladder perforations resulting from penetrating trauma should undergo emergency exploration and repair (61) (level of evidence: 3).

4.5.4. Iatrogenic injuries

Iatrogenic bladder perforations can occur during any pelvic, abdominal, or vaginal procedure (27). Prompt intraoperative recognition is extremely important to ensure a successful repair. Generally, suture repair is

satisfactory, limiting unnecessary extravesical dissection (level of evidence: 3). Most (> 95%) of urinary bladder injuries sustained during gynaecological operations are detected and can be managed during surgery (73). Repair can be performed either transvaginally or abdominally. Simple catheter drainage is sufficient in most cases of bladder perforation during transurethral resection of prostate or bladder tumours (36-38) (level of evidence: 3).

4.6 Recommendations

4.6.1 General

Recommendation	GR
Stabilization of the patient is always the priority in cases with associated injuries	B

GR = grade of recommendation

4.6.2 Diagnosis

Recommendation	GR
• Immediate cystography is required in the presence of haematuria and pelvic fracture	B
• Diagnosis should be made with retrograde cystography with a minimum of 350 mL of gravity-filled contrast medium	B
• For cystography, the minimum requirement includes a plain film, filled film, and post-drainage film. Half-filled film and obliques are optional	B
• CT cystography can be used with equal efficacy if the patient is undergoing CT scanning for associated injuries	B
• Routine cystoscopy is recommended after major gynaecological operations and/or incontinence surgery	B

GR= grade of recommendation

4.6.3 Treatment

Recommendation	GR
• In the absence of bladder neck involvement and/or associated injuries that require surgical intervention, extraperitoneal bladder ruptures caused by blunt trauma are managed by catheter drainage alone	B
• Intraperitoneal bladder ruptures by blunt trauma, and any type of bladder injury by penetrating trauma, must be managed by emergency surgical exploration and repair	B
• The technique of surgical repair used depends on the surgeon's preference, but a two-layer closure with absorbable sutures achieves a safe repair of the bladder wall	B

GR = grade of recommendation

4.7 REFERENCES

1. Carlin BI, Resnick MI. Indications and techniques for urologic evaluation of the trauma patient with suspected urologic injury. Semin Urol 1995 Feb;13(1):9-24. http://www.ncbi.nlm.nih.gov/pubmed/7597359
2. Corriere JN Jr, Sandler CM. Management of the ruptured bladder: seven years of experience with 111 cases. J Trauma 1986 Sep;26(9):830-3. http://www.ncbi.nlm.nih.gov/pubmed/3746959
3. Carroll PR, McAninch JW. Major bladder trauma: mechanisms of injury and a unified method of diagnosis and repair. J Urol 1984 Aug;132(2):254-7. http://www.ncbi.nlm.nih.gov/pubmed/6737572
4. McConnell JD, Wilkerson MD, Peters PC. Rupture of the bladder. Urol Clin North Am 1982 Jun;9(2): 293-6. http://www.ncbi.nlm.nih.gov/pubmed/7101594
5. Cass AS and Luxenberg M. Features of 164 bladder ruptures. J Urol 1987 Oct;138(4):743-5. http://www.ncbi.nlm.nih.gov/pubmed/3656524
6. Sagalowsky AI, Peters PC. Genitourinary trauma. In: Walsh PC, Retik AB, Vaughan ED Jr, Wein AJ (eds). *Campbell's Urology*, 7th ed. 1998, WB Saunders: Philadelphia, pp. 3085-3120.
7. Sandler CM, Goldman SM, Kawashima A. Lower urinary tract trauma. World J Urol 1998;16(1):69-75. http://www.ncbi.nlm.nih.gov/pubmed/9542018
8. Flancbaum L, Morgan AS, Fleisher M, Cox EF. Blunt bladder trauma: manifestation of severe injury. Urology 1988 Mar;31(3):220-2. http://www.ncbi.nlm.nih.gov/pubmed/3347970

9. Castle WN, Richardson JR Jr, Walton BJ. Unsuspected intraperitoneal rupture of bladder presenting with abdominal free air. Urology 1986 Dec;28(6):521-3.
http://www.ncbi.nlm.nih.gov/pubmed/3787926
10. Morgan DE, Nallamala LK, Kenney PJ, Mayo MS and Rue LW 3rd. CT cystography: radiographic and clinical predictors of bladder rupture. Am J Roentgenol 2000 Jan;174(1):89-95.
http://www.ncbi.nlm.nih.gov/pubmed/10628460
11. Aihara R, Blansfield JS, Millham FH, LaMorte WW, Hirsch EF. Fracture locations influence the likelihood of rectal and lower urinary tract injuries in patients sustaining pelvic fractures. J Trauma 2002 Feb;52(2):205-8;discussion 208-9.
http://www.ncbi.nlm.nih.gov/pubmed/11834976
12. Cass AS. Diagnostic studies in bladder rupture. Indications and techniques. Urol Clin North Am 1989 May;16(2):267-73.
http://www.ncbi.nlm.nih.gov/pubmed/2652855
13. Rehm CG, Mure AJ, O'Malley KF, Ross SE. Blunt traumatic bladder rupture: the role of retrograde cystogram. Ann Emerg Med 1991 Aug;20(8):845-7.
http://www.ncbi.nlm.nih.gov/pubmed/1854066
14. Coppola PT, Coppola M. Emergency department evaluation and treatment of pelvic fractures. Emerg Med Clin North Am 2000 Feb;18(1):1-27, v.
http://www.ncbi.nlm.nih.gov/pubmed/10678158
15. Festini G, Gregorutti S, Reina G, Bellis GB. Isolated intraperitoneal bladder rupture in patients with alcohol intoxication and minor abdominal trauma. Ann Emerg Med 1991 Dec;20(12):1371-2.
http://www.ncbi.nlm.nih.gov/pubmed/1746742
16. Ben-Menachem Y, Coldwell DM, Young JW, Burgess AR. Hemorrhage associated with pelvic fractures: causes, diagnosis, and emergent management. Am J Roentgenol 1991 Nov;157(5):1005-14.
http://www.ncbi.nlm.nih.gov/pubmed/1927786
17. Cass AS. The multiple injured patient with bladder trauma. J Trauma 1984 Aug;24(8):731-4.
http://www.ncbi.nlm.nih.gov/pubmed/6471137
18. Taffet R. Management of pelvic fractures with concomitant urologic injuries. Orthop Clin North Am 1997 Jul;28(3):389-96.
http://www.ncbi.nlm.nih.gov/pubmed/9208831
19. Dreitlein DA, Suner S, Basler J. Genitourinary trauma. Emerg Med Clin North Am 2001 Aug;19(3): 569-90.
http://www.ncbi.nlm.nih.gov/pubmed/11554276
20. Reed MH. Pelvic fractures in children. J Can Assoc Radiol 1976 Dec;27(4):255-61.
http://www.ncbi.nlm.nih.gov/pubmed/993239
21. Torode I, Zieg D. Pelvic fractures in children. J Pediatr Orthop 1985 Jan-Feb;5(1):76-84.
http://www.ncbi.nlm.nih.gov/pubmed/3980712
22. Musemeche CA, Fischer RP, Cotler HB, Andrassy RJ. Selective management of paediatric pelvic fractures: a conservative approach. J Pediatr Surg 1987 Jun;22(6):538-40.
http://www.ncbi.nlm.nih.gov/pubmed/3612446
23. Bond SJ, Gotschall CS, Eichelberger MR. Predictors of abdominal injury in children with pelvic fracture. J Trauma 1991 Aug;31(8):1169-73.
http://www.ncbi.nlm.nih.gov/pubmed/1875444
24. Reichard SA, Helikson MA, Shorter N, White RI Jr, Shemeta DW, Haller JA Jr. Pelvic fractures in children – review of 120 patients with a new look at general management. J Pediatr Surg 1980 Dec;15(6):727-34.
http://www.ncbi.nlm.nih.gov/pubmed/7463272
25. Koraitim MM, Marzouk ME, Atta MA, Orabi SS. Risk factors and mechanism of urethral injury in pelvic fractures. Br J Urol 1996 Jun;77(6):876-80.
http://www.ncbi.nlm.nih.gov/pubmed/8705225
26. Tarman GJ, Kaplan GW, Lerman SL, McAleer IM, Losasso BE. Lower genitourinary injury and pelvic fractures in paediatric patients. Urology 2002 Jan;59(1):123-6; discussion 126.
http://www.ncbi.nlm.nih.gov/pubmed/11796295
27. Armenakas NA, Pareek G, Fracchia JA. Iatrogenic bladder perforations: longterm followup of 65 patients. J Am Coll Surg 2004 Jan;198(1):78-82.
http://www.ncbi.nlm.nih.gov/pubmed/14698314
28. Dobrowolski ZF, Lipczyñski W, Drewniak T, Jakubik P, Kusionowicz J. External and iatrogenic trauma of the urinary bladder: a survey in Poland. BJU Int 2002 May;89(7):755-6.
http://www.ncbi.nlm.nih.gov/pubmed/11966639

29. Ostrzenski A, Ostrzenska KM. Bladder injury during laparoscopic surgery. Obstet Gynecol Surv 1998 Mar;53(3):175-80.
http://www.ncbi.nlm.nih.gov/pubmed/9513988
30. Härkki-Sirén P, Sjöberg J, Tiitinen A. Urinary tract injuries after hysterectomy. Obstet Gynecol 1998 Jul;92(1):113-8.
http://www.ncbi.nlm.nih.gov/pubmed/9649105
31. Gilmour DT, Dwyer PL, Carey MP. Lower urinary tract injury during gynecologic surgery and its detection by intraoperative cystoscopy. Obstet Gynecol 1999 Nov;94(5Pt2):883-9.
http://www.ncbi.nlm.nih.gov/pubmed/10546778
32. Mendez LE. Iatrogenic injuries in gynecologic cancer surgery. Surg Clin North Am 2001 Aug;81(4): 897-923.
http://www.ncbi.nlm.nih.gov/pubmed/11551133
33. Mäkinen J, Johansson J, Tomas C, Tomás E, Heinonen PK, Laatikainen T, Kauko M, Heikkinen AM, Sjöberg J. Morbidity of 10 110 hysterectomies by type of approach. Hum Reprod 2001 Jul;16(7): 1473-8.
http://www.ncbi.nlm.nih.gov/pubmed/11425832
34. Vakili B, Chesson RR, Kyle BL, Shobeiri SA, Echols KT, Gist R, Zheng YT, Nolan TE. The incidence of urinary tract injury during hysterectomy: a prospective analysis based on universal cystoscopy. Am J Obstet Gynecol 2005 May;192(5):1599-604.
http://www.ncbi.nlm.nih.gov/pubmed/15902164
35. Skolarikos A, Chrisofos M, Ferakis N, Papatsoris A, Dellis A, Deliveliotis C. Does the management of bladder perforation during transurethral resection of superficial bladder tumors predispose to extravesical tumor recurrence? J Urol 2005 Jun;173(6):1908-11.
http://www.ncbi.nlm.nih.gov/pubmed/15879773
36. Murshidi MS. Intraperitoneal rupture of the urinary bladder during transurethral resection of transitional cell carcinoma. Acta Urol Belg 1988;56(1):68-73.
http://www.ncbi.nlm.nih.gov/pubmed/3364323
37. Donovan JL, Peters TJ, Neal DE, Brookes ST, Gujral S, Chacko KN, Wright M, Kennedy LG, Abrams P. A randomized trial comparing transurethral resection of the prostate, laser therapy and conservative treatment of men with symptoms associated with benign prostatic enlargement: The CLasP study. J Urol 2000 Jul;164(1):65-70.
http://www.ncbi.nlm.nih.gov/pubmed/10840426
38. Minaglia S, Ozel B, Klutke C, Ballard C, Klutke J. Bladder injury during transobturator sling. Urology 2004 Aug;64(2):376-7.
http://www.ncbi.nlm.nih.gov/pubmed/15302505
39. Dwyer PL, Carey MP, Rosamilia A. Suture injury to the urinary tract in urethral suspension procedures for stress incontinence. Int Urogynecol J Pelvic Floor Dysfunct 1999;10(1):15-21.
http://www.ncbi.nlm.nih.gov/pubmed/10207762
40. Gill EJ, Elser DM, Bonidie MJ, Roberts KM, Hurt WG. The routine use of cystoscopy with the Burch procedure. Am J Obstet Gynecol 2001 Aug;185(2):345-8.
http://www.ncbi.nlm.nih.gov/pubmed/11518889
41. Kenton K, Oldham L, Brubaker L. Open Burch urethropexy has a low rate of perioperative complications. Am J Obstet Gynecol 2002 Jul;187(1):107-10.
http://www.ncbi.nlm.nih.gov/pubmed/12114897
42. Olsson I, Kroon U. A three-year postoperative evaluation of tension-free vaginal tape. Gynecol Obstet Invest 1999;48(4):267-9.
http://www.ncbi.nlm.nih.gov/pubmed/10592431
43. Soulié M, Cuvillier X, Benaïssa A, Mouly P, Larroque JM, Bernstein J, Soulié R, Tollon C, Brucher P, Vazzoler N, Seguin P, Pontonnier F, Plante P. The tension-free transvaginal tape procedure in the treatment of female urinary stress incontinence: a French prospective multicentre study. Eur Urol 2001 Jun;39(6):709-14; discussion 715.
http://www.ncbi.nlm.nih.gov/pubmed/11464062
44. Tamussino KF, Hanzal E, Kölle D, Ralph G, Riss PA. Tension-free vaginal tape operation: results of the Austrian registry. Obstet Gynecol 2001 Nov;98(5Pt1):732-6.
http://www.ncbi.nlm.nih.gov/pubmed/11704161
45. Meschia M, Pifarotti P, Bernasconi F, Guercio E, Maffiolini M, Magatti F, Spreafico L. Tension-Free vaginal tape: analysis of outcomes and complications in 404 stress incontinent women. Int Urogynecol J Pelvic Floor Dysfunct 2001;12 Suppl 2:S24-27.
http://www.ncbi.nlm.nih.gov/pubmed/11450976

46. Agostini A, Bretelle F, Franchi F, Roger V, Cravello L, Blanc B. Immediate complications of tension-free vaginal tape (TVT): results of a French survey. Eur J Obstet Gynecol Reprod Biol 2006 Feb;124(2):237-9. Epub 2005.
http://www.ncbi.nlm.nih.gov/pubmed/16095800
47. Kuuva N, Nilsson CG. A nationwide analysis of complications associated with the tension-free vaginal tape (TVT) procedure. Acta Obstet Gynecol Scand 2002 Jan;81(1):72-7.
http://www.ncbi.nlm.nih.gov/pubmed/11942891
48. Azam U, Frazer MI, Kozman EL, Ward K, Hilton P, Rane A. The tension-free vaginal tape procedure in women with previous failed stress incontinence surgery. J Urol 2001 Aug;166(2):554-6.
http://www.ncbi.nlm.nih.gov/pubmed/11458067
49. Latthe PM. Review of transobturator and retropubic tape procedures for stress urinary incontinence. Curr Opin Obstet Gynecol 2008 Aug;20(4):331-6.
http://www.ncbi.nlm.nih.gov/pubmed/18660683
50. Morey AF, Iverson AJ, Swan A, Harmon WJ, Spore SS, Bhayani S, Brandes SB. Bladder rupture after blunt trauma: guidelines for diagnostic imaging. J Trauma 2001 Oct;51(4):683-6.
http://www.ncbi.nlm.nih.gov/pubmed/11586159
51. Schneider RE. Genitourinary trauma. Emerg Med Clin North Am 1993 Feb;11(1):137-45.
http://www.ncbi.nlm.nih.gov/pubmed/8432245
52. Werkman HA, Jansen C, Klein JP, Ten Duis HJ. Urinary tract injuries in multiply-injured patients: a rational guideline for the initial assessment. Injury 1991 Nov;22(6):471-4.
http://www.ncbi.nlm.nih.gov/pubmed/1757139
53. Fuhrman GM, Simmons GT, Davidson BS, Buerk CA. The single indication for cystography in blunt trauma. Am Surg 1993 Jun;59(6):335-7.
http://www.ncbi.nlm.nih.gov/pubmed/8507053
54. Hochberg E, Stone NN. Bladder rupture associated with pelvic fracture due to blunt trauma. Urology 1993 Jun;41(6):531-3.
http://www.ncbi.nlm.nih.gov/pubmed/8516988
55. Abou-Jaoude WA, Sugarman JM, Fallat ME, Casale AJ. Indicators of genitourinary tract injury or anomaly in cases of paediatric blunt trauma. J Pediatr Surg 1996 Jan;31(1):86-9;discussion 90.
http://www.ncbi.nlm.nih.gov/pubmed/8632293
56. Baniel J, Schein M. The management of penetrating trauma to the urinary tract. J Am Coll Surg 1994 Apr;178(4):417-25.
http://www.ncbi.nlm.nih.gov/pubmed/8149045
57. Corriere JN Jr., Sandler CM. Management of extraperitoneal bladder rupture. Urol Clin North Am 1989 May;16(2):275-7.
http://www.ncbi.nlm.nih.gov/pubmed/2711545
58. Stine RJ, Avila JA, Lemons MF, Sickorez GJ. Diagnostic and therapeutic urologic procedures. Emerg Med Clin North Am 1988 Aug;6(3):547-78.
http://www.ncbi.nlm.nih.gov/pubmed/3292227
59. Carroll PR, McAninch JW. Major bladder trauma: the accuracy of cystography. J Urol 1983 Nov; 130(5):887-8.
http://www.ncbi.nlm.nih.gov/pubmed/6632094
60. Deck AJ, Shaves S, Talner L, Porter JR. Computerized tomography cystography for the diagnosis of traumatic bladder rupture. J Urol 2000 Jul;164(1):43-6.
http://www.ncbi.nlm.nih.gov/pubmed/10840421
61. Morey AF, Hernandez J, McAninch JW. Reconstructive surgery for trauma of the lower urinary tract. Urol Clin North Am 1999 Feb;26(1):49-60, viii.
http://www.ncbi.nlm.nih.gov/pubmed/10086050
62. Bonavita JA, Pollack HM. Trauma of the adult bladder and urethra. Semin Roentgenol 1983 Oct;18(4): 299-306.
http://www.ncbi.nlm.nih.gov/pubmed/6359436
63. MacMahon R, Hosking D, Ramsey EW. Management of blunt injury to the lower urinary tract. Can J Surg 1983 Sep;26(5):415-8.
http://www.ncbi.nlm.nih.gov/pubmed/6616359
64. Bigongiari LR, Zarnow H. Traumatic, inflammatory, neoplastic and miscellaneous lesions of the bladder. In: Land EK (ed.). *Medical Radiology of the Lower Urinary Tract*, 1994, Springer Verlag: Berlin, pp. 70-147.
65. Mee SL, McAninch JW, Federle MP. Computerized tomography in bladder rupture: diagnostic limitations. J Urol 1987 Feb;137(2):207-9.
http://www.ncbi.nlm.nih.gov/pubmed/3806805

66. Horstman WG, McClennan BL, Heiken JP. Comparison of computed tomography and conventional cystography for detection of traumatic bladder rupture. Urol Radiol 1991;12(4):188-93.
http://www.ncbi.nlm.nih.gov/pubmed/2042269
67. Lis LE, Cohen AJ. CT cystography in the evaluation of bladder trauma. J Comput Assist Tomogr 1990 May-Jun;14(3):386-9.
http://www.ncbi.nlm.nih.gov/pubmed/2335605
68. Vaccaro JP, Brody JM. CT cystography in the evaluation of major bladder trauma. Radiographics 2000 Sep-Oct;20(5):1373-81.
http://www.ncbi.nlm.nih.gov/pubmed/10992026
69. Dixon CM, Hricak H, McAninch JW. Magnetic resonance imaging of traumatic posterior urethral defects and pelvic crush injuries. J Urol 1992 Oct;148(4):1162-5.
http://www.ncbi.nlm.nih.gov/pubmed/1404629
70. Armenakas NA, McAninch JW, Lue TF, Dixon CM, Hricak H. Posttraumatic impotence: magnetic resonance imaging and duplex ultrasound in diagnosis and management. J Urol 1993 May;149(5Pt2): 1272-5.
http://www.ncbi.nlm.nih.gov/pubmed/8479013
71. Narumi Y, Hricak H, Armenakas NA, Dixon CM, McAninch JW. MR imaging of traumatic posterior urethral injury. Radiology 1993 Aug;188(2):439-43.
http://www.ncbi.nlm.nih.gov/pubmed/8327694
72. Thomae KR, Kilambi NK, Poole GV. Method of urinary diversion in nonurethral traumatic bladder injuries: retrospective analysis of 70 cases. Am Surg 1998 Jan;64(1):77-80;discussion 80-1.
http://www.ncbi.nlm.nih.gov/pubmed/9457042
73. Soong YK, Yu HT, Wang CJ, Lee CL, Huang HY. Urinary tract injury in laparoscopic-assisted vaginal hysterectomy. J Minim Invasive Gynecol 2007 Sep-Oct;14(5):600-5.
http://www.ncbi.nlm.nih.gov/pubmed/17848321

5. URETHRAL TRAUMA

5.1 Anatomical and aetiological considerations

The male urethra is divided into the anterior and posterior sections by the urogenital diaphragm. The posterior urethra consists of the prostatic and the membranous urethra. The anterior urethra consists of the bulbar and penile urethra. Only the posterior urethra exists in the female; the anterior urethra corresponds to the labia minora, which results from persistent separation of the urethral folds on the ventral surfaces of the genital tubercle.

5.1.1 Posterior urethral injuries

Road traffic accidents, falls, and crush injuries can cause pelvic fractures, which result in injuries to the posterior urethra. About two-thirds (70%) of pelvic fractures occur because of motor vehicle accidents. The incidence of pelvic fracture is 20% in survivors of motor accidents where fatalities have occurred. The incidence is nearly 50% in fatal pedestrian accidents. Twenty-five per cent of cases result from a fall from a height (1, 2).

Altogether, blunt trauma accounts for more than 90% of urethral injuries (3). Overall, the male posterior urethra is injured in 4-19% and the female urethra in 0-6% of all pelvic fractures (2, 4-12). The female urethra is rarely injured, except by contusion or laceration by bone fragments.

During crush or deceleration impact injury, the severe shearing forces necessary to fracture the pelvis are transmitted to the prostatomembranous junction, resulting in disruption of the prostate from its connection to the anterior urethra at the prostatic apex. Retrograde urethrography and magnetic resonance imaging (MRI) correlates to this location of the injury (13, 14). Cadaveric studies suggest that in most cases the membranous urethra is torn distally to the urogenital diaphragm (15).

An accurate knowledge of the functional anatomy of the sphincter mechanism is essential to the success of posterior urethral surgery. Continence after anastomotic reconstruction of subprostatic pelvic fracture urethral distraction defects depends upon the function of the bladder neck and of the distal urethral sphincter mechanism, each of which is competent and independently capable of maintaining continence in the absence of the other (16).

Unstable pelvic fractures (8, 11, 17-21), bilateral ischiopubic rami fractures ('straddle fracture'), and symphysis pubis diastasis have the highest likelihood of injuring the posterior urethra. In particular, the combination of straddle fractures with diastasis of the sacroiliac joint has the highest risk of urethral injury; the odds ratio is about 7 times higher than for either straddle injuries or sacroiliac ('Malgaigne') fractures alone (Table 7) (2).

Table 7: Odds ratio of suffering urethral injury with different types of pelvic fracture

Type of fracture	**Odds ratio**
Single ramus	0.6
Ipsilateral rami	0.8
Malgaigne's (vertical shear)	3.4
Straddle	3.9
Straddle plus sacroiliac	24.0

Lower urinary tract injury has been reported in about 16% of patients with unilateral rami fractures and in 41% of patients with bilateral rami fractures (22). Anteroposterior compression injuries from frontal crushes produce more severe pelvic fractures, major retroperitoneal bleeding and more frequent injury to the lower urinary tract than do lateral crashes (23).

Prostatomembranous urethral injuries can vary from simple stretching (25%) to partial rupture (25%) or complete disruptions (50%) (2). The more severe injuries result in prostatourethral displacement, with progressive scar formation encompassing the rupture defect. The incidence of double injuries involving the urethra and the bladder ranges between 10% and 20% in males, and may be intraperitoneal (17-39%), extraperitoneal (56-78%), or both (2, 7).

Urethral injuries, by themselves, are never life-threatening, except as a consequence of their close association with pelvic fractures and multiple organ injuries, which occur in about 27% of cases. Initially, the assessment and management of other associated injuries is usually more important than the assessment and management of the urethral injury (24).
The American Association for Surgery of Trauma (AAST) has proposed the classification given in Table 8.

Table 8: Organ injury scaling III classification of urethral injuries (25)

Grade	**Description**	**Appearance**
I	Contusion	Blood at the urethral meatus; Normal urethrogram
II	Stretch injury	Elongation of the urethra without extravasation on urethrography
III	Partial disruption	Extravasation of contrast at injury site with contrast visualised in the bladder
IV	Complete disruption	Extravasation of contrast at injury site without visualisation in the bladder; < 2 cm of urethral separation
V	Complete disruption	Complete transection with > 2 cm urethral separation or extension into the prostate or vagina

New classifications provide an anatomical classification and a means of comparing treatment strategies and outcomes (26, 27). The classification shown in Table 9 combines the best of previous classifications and has direct implications in clinical management.

Table 9: Classification of blunt anterior and posterior urethra

Grade	**Description**	**Appearance**
I	Stretch injury	Elongation of the urethra without extravasation on urethrography
II	Contusion	Blood at the urethral meatus No extravasation on urethrography
III	Partial disruption of anterior or posterior urethra	Extravasation of contrast at injury site with contrast visualised in the proximal urethra or bladder
IV	Complete disruption of anterior urethra	Extravasation of contrast at injury site without visualisation of proximal urethral or bladder

V	Complete disruption of posterior urethra	Extravasation of contrast at injury site without visualisation of bladder
VI	Complete or partial disruption of posterior urethra with associated tear of the bladder neck or vagina	

Clinical management is according to the injury grade:

- grade I no treatment required
- grades II and III can be managed conservatively with suprapubic cystostomy or urethral catheterisation
- grades IV and V will require open or endoscopic treatment, primary or delayed
- grade VI requires primary open repair.

5.1.1.1 Urethral injuries in children

Urethral injuries in children are similar to those in adults. The only significant difference is that straddle pelvic fractures, Malgaigne's fractures or the association of straddle plus sacroiliac joint fracture is more common in children than in adults. In addition, posterior urethral injuries can involve the prostatic urethra and the bladder neck, as well as the membranous urethra. The tear is often in the prostatic urethra or at the bladder neck because of the rudimentary nature of the prostate, and is more likely to be a complete rupture (69% versus 42%). Urethral stretching is less common than in adults. The more proximal the injury, the greater the risk of incontinence, impotence and stricture (2, 24, 28, 29).

5.1.1.2 Urethral injuries in women

These are rare events since the female urethra is short and mobile, without any significant attachments to the pubic bone. They usually occur in children. They are often accompanied by severe pelvic fractures, where bony fragments of the fractured pelvis can lacerate the urethra. Urethral injuries in females frequently extend into the bladder neck or vagina, and often disrupt the normal continence mechanism (4, 12). Injury to the female urethra is usually a partial tear of the anterior wall and is rarely a complete disruption of the proximal or distal urethra (29).

5.1.1.3 Penetrating injuries to the perineum

These can occur after external violence such as gunshot or stab wounds, or as iatrogenic injuries caused by endoscopic instruments or during surgery for vaginal repair. In developing countries, urethral and bladder neck damage occur quite often as a result of ischaemic injury during obstructed labour.

5.1.2 Anterior urethral injuries

Anterior urethral injuries result from blunt trauma more frequently than from penetrating trauma (Table 10).

Table 10: Aetiology of anterior urethral injuries

Cause	Example
Blunt trauma	• Vehicular accidents • Fall astride (straddle) • Kicks in the perineum • Blows in the perineum from bicycle handlebars, tops of fences, etc.
Sexual intercourse	• Penile fractures • Urethral intraluminal stimulation
Penetrating trauma	• Gunshot wounds • Stab wounds • Dog bites • External impalement • Penile amputations
Constriction bands	• Paraplegia
Iatrogenic injuries	• Endoscopic instruments • Urethral catheters/dilators

5.1.2.1 Blunt trauma

Vehicular accidents, falls or blows cause most anterior urethral injuries. In contrast to posterior urethral trauma,

they are rarely associated with pelvic fractures. They are usually straddle-type injuries caused by blows of blunt objects against the perineum, such as bicycle handlebars or the top of a fence. In this type of accident, the relatively immobile bulbar urethra is trapped and compressed by a direct force on it against the inferior surface of the symphysis pubis. These injuries are more common in children than in adults (28).

5.1.2.2 Intercourse-related trauma

A less common cause of blunt anterior urethral trauma is penile fracture. This rupture of the corpus cavernosum usually occurs during intercourse. In these injuries, the urethra is involved in 20% of the cases (30). Intraluminal stimulation of the urethra with foreign objects has also been reported to cause anterior urethral trauma. Most are short and incomplete, and occur in the distal penile urethra.

Surgery is rarely indicated and depends on the degree and extent of injury to the urethra.

5.1.2.3 Penetrating trauma

Penetrating injuries to the anterior urethra usually result from gunshot wounds and involve the pendulous and bulbar urethral segments equally. These injuries are associated with penile and testicular injury. These can involve the rectum, which may result in pelvic abscesses and the formation of fistulae (31, 32). Other less frequent causes of external anterior urethral injuries include stab wounds, penile amputation and impalement.

5.1.2.4 Constriction band-related trauma

Individuals with paraplegia who use a constriction device for urinary incontinence and forget to release the band because of the lack of sensation can cause severe ischaemic injuries involving the penis and urethra.

5. 1.2.5 Iatrogenic trauma

Iatrogenic urethral injuries caused by instruments are by far the most common cause of urethral trauma. Urethral ischaemic injuries related to cardiac bypass procedures are not infrequent and can result in long and fibrotic strictures. A separate section in this chapter discusses iatrognic trauma in more detail (see section 4.6).

5.2 Diagnosis: initial emergency assessment

5.2.1 Clinical assessment

The initial management of urethral injury is resuscitation of the patient. In the absence of blood at the meatus or genital haematoma, a urological injury is very unlikely and is excluded by catheterisation. Maintain airway and respiratory function, secure the cervical spine if necessary, and address blood loss if present. This is particularly important in posterior urethral injuries because of their close association with pelvic fractures.

The next step includes taking a complete history and carrying out physical, laboratory and radiographic evaluations in order to identify all injuries accurately. A diagnosis of acute urethral trauma should be suspected from the history. A pelvic fracture, or any external penile or perineal trauma, can be suggestive of urethral trauma (33, 34).

For penetrating injuries, the type of weapon used, including the calibre of the bullet, is helpful in assessing potential tissue damage. In a conscious patient, a thorough voiding history should be obtained to establish the time of last urination, the force of the urinary stream, whether urination is painful and whether haematuria is present. The following clinical indicators of acute urethral trauma warrant a complete urethral evaluation.

5.2.1.1 Blood at the meatus

This is present in 37-93% of patients with posterior urethral injury, and in at least 75% of patients with anterior urethral trauma (35, 36). When blood is present at the urethral meatus, do not attempt urethral instrumentation until the entire urethra is imaged. In an unstable patient, attempt to pass a urethral catheter, but if there is any difficulty, place a suprapubic catheter and perform a retrograde urethrogram when appropriate.

It is extremely unlikely that gentle passage of a urethral catheter will do any additional damage (37, 38), although it has been suggested that this may convert a partial tear into one that is complete (39). There are no convincing data indicating a higher rate of infection or urethral stricture after a single attempt at catheterisation (3). Indeed, if a urethral injury is suspected, urethrography prior to attempted catheterisation is the most prudent approach.

5.2.1.2 Blood at the vaginal introitus

This is present in more than 80% of female patients with pelvic fractures and co-existing urethral injuries (4).

5.2.1.3 Haematuria
Although non-specific, haematuria on a first-voided specimen may indicate urethral injury. The amount of urethral bleeding correlates poorly with the severity of the injury, as a mucosal contusion or small partial tear may be accompanied by copious bleeding, while total transection of the urethra may result in little bleeding (40).

5.2.1.4 Pain on urination or inability to void
The inability to void suggests urethral disruption.

5.2.1.5 Haematoma or swelling
With anterior urethral trauma, the pattern of the haematoma can be useful in identifying the anatomical boundaries violated by the injury. Extravasation of blood or urine in a sleeve distribution along the penile shaft indicates that the injury is confined by Buck's fascia. Disruption of Buck's fascia results in a pattern of extravasation limited only by Colles' fascia, and can extend to the coracoclavicular fascia superiorly and the fascia lata inferiorly. This results in a characteristic butterfly pattern of bruising in the perineum. In female patients with severe pelvic fractures, the presence of labial swelling may be an indicator of urethral injury. It can be caused by urinary extravasation and warrants immediate attention.

5.2.1.6 High-riding prostate
This is a relatively unreliable finding in the acute phase since the pelvic haematoma associated with pelvic fractures often precludes the adequate palpation of a small prostate, particularly in younger men (3). A boggy mass is usually palpated without recognition of a prostate gland (41). Rectal examination is more important as a tool to screen for rectal injuries, which can be associated with pelvic fractures. Blood on the examination finger is suggestive of a rectal injury. Assessment of concomitant genital injuries is mandatory in every case of external urethral trauma.

5.2.2 Radiographic examination
Retrograde urethrography is the gold standard for evaluating urethral injury (5, 29). A scout film should be performed first to assess the radiographic technique, and to detect pelvic fractures and foreign bodies, such as bullets. This is performed using a Foley catheter in the fossa navicularis, with the balloon inflated using 1-2 mL of saline to occlude the urethra. Then, 20-30 mL of contrast material is injected while films are taken in a 30° oblique position. When severe pelvic fractures and associated patient discomfort are present, the oblique position may not always be possible. The radiographic appearance of the urethra permits classification of the injury and facilitates the subsequent management.

If posterior urethral injury is suspected, a suprapubic catheter is inserted. Later on, a simultaneous cystogram and ascending urethrogram can be carried out to assess the site, severity and length of the urethral injury. This is usually done after 3 months if a delayed repair is considered.

When the proximal urethra is not visualised in a simultaneous cystogram and urethrogram, either MRI of the posterior urethra (42) or endoscopy through the suprapubic tract is used to define the anatomy of the posterior urethra. Since manipulation in the bladder can cause the bladder neck to open and give the false impression of incompetence, the endoscopic appearance of the bladder neck should be noted immediately on placing the scope into the bladder (43).

After assessing the endoscopic appearance of the bladder neck, the flexible endoscope can be advanced through the bladder neck into the posterior urethra to the level of obstruction. If there is a question about the length of the distraction, a simultaneous retrograde urethrogram can be performed while the endoscope is in the posterior urethra. The radiographic appearance of the bladder neck is important, but is not as reliable an indicator of continence as the endoscopic appearance is. Furthermore, there are patients who, despite evidence of an open or scarred bladder neck, will have acceptable continence after reconstruction. For this reason, the need for concomitant bladder neck surgery at the time of urethral reconstruction is debatable (43, 44).

Ultrasonography is not a routine investigation in the initial assessment of urethral injuries but can be very useful in determining the position of pelvic haematomas, or the exact location of the bladder when a suprapubic catheter is indicated.

Computed tomography and MRI have no place in the initial assessment of urethral injuries. However, they are useful in defining distorted pelvic anatomy after severe injury and assessing associated injuries of penile crura,

bladder, kidneys and intra-abdominal organs (14, 45).

5.2.3 Endoscopic examination

Urethroscopy does not have any role in the initial diagnosis of urethral trauma in males. In females, however, where the short urethra precludes adequate retrograde urethrography, urethroscopy is an important adjunct to the physical examination for the identification and staging of urethral injuries (46).

5.3 Management

The management of urethral injuries remains controversial because of the variety of injury patterns, associated injuries and treatment options available. In addition, urethral injuries are relatively uncommon, hence the limited experience of most urologists worldwide and the absence of randomised prospective studies.

5.3.1 Anterior urethral injuries

5.3.1.1 Blunt injuries

Partial tears can be managed with a suprapubic catheter or with urethral catheterisation (29, 37, 47). Suprapubic cystostomy has the advantage that it not only diverts the urine away from the site of injury, but also avoids urethral manipulation (48), as well as allowing for a simultaneous study to be carried out at a later date.

If the bladder is not easily palpable suprapubically, transabdominal sonography should be used to guide the placement of the catheter. The cystostomy tube is maintained for approximately 4 weeks to allow urethral healing. Voiding cystourethrography is then performed. Remove the suprapubic tube if normal voiding can be re-established and neither contrast extravasation nor stricture is present.

The potential early complications of acute urethral injuries include strictures and infections.

Extravasated blood or urine from the urethral tear produces an inflammatory reaction that can progress to the formation of an abscess. The extent of the infection depends on the fascial planes violated (see section 4.2). The potential sequelae of these infections include urethrocutaneous fistulae, peri-urethral diverticulae and, rarely, necrotising fasciitis. Prompt urinary diversion coupled with the appropriate administration of antibiotics decreases the incidence of these complications.

After the patient has adequately recovered from any associated injuries, and the urethral injury has stabilised, the urethra can be thoroughly re-evaluated radiographically. When necessary, the appropriate reconstructive procedure is planned.

Blunt anterior urethral injuries are associated with spongiosal contusion, which makes it more difficult to evaluate the limits of urethral debridement in the acute phase. Acute or early urethroplasty is therefore not indicated, and the best management is simply suprapubic diversion.

Satisfactory urethral luminal recanalisation occurs in approximately 50% of partial anterior urethral disruptions (47, 49). Short and flimsy strictures are managed with optical urethrotomy or urethral dilatation. Denser strictures require formal urethral reconstruction. Anastomotic urethroplasty is indicated in strictures of less than 1 cm in length.

Longer strictures of the anterior urethra should not be repaired by an end-to-end anastomosis, in order to avoid chordee. In these cases, flap urethroplasty is indicated. Almost all complete ruptures of the anterior urethra require anastomotic or patch urethroplasty at 3-6 months. The only exception to this is urethral injury associated with penile fracture; this usually results in partial urethral disruption and can be repaired at the time of cavernosal closure.

5.3.1.2 Open injuries

5.3.1.2.1 Male urethral injuries

Stab wounds, gunshot wounds and dog bites to the urethra often involve the penis and testes and often require immediate exploration. During surgery, the urethral injury can be surgically evaluated and repaired as needed. Urethral strictures form in fewer than 15% of these patients (50).

Primary urethral suturing involves direct visualisation of the severed urethral ends and creation of a watertight, tension-free repair. The patient should be in a supine position. Use a circumferential subcoronal incision to deglove the penis.

In complete disruptions, the corpus spongiosum is mobilised at the level of the injury and the urethral ends dissected distally and proximally. Urethral ends are spatulated, and end-to-end anastomosis is fashioned over a 14 French Foley catheter. Suture small lacerations with fine absorbable material. Careful overclosure of the corpus spongiosum and skin prevents the subsequent formation of fistulae (24). Keep urethral debridement to a minimum since the spongiosum is well vascularised and will usually heal well.

As with any surgery, give pre-operative antimicrobial prophylaxis. Some experts recommend the post-operative continuation of prophylactic antibiotics, but we are not aware of any data that prove that they help. After 10-14 days, obtain a peri-catheter retrograde urethrogram with the urethral catheter in situ. Provided there is no leakage at the anastomotic site, remove the urethral catheter. If there is leakage, leave the catheter in and repeat the cystourethrogram 1 week later.

If the urethra is so extensively disrupted that primary anastomosis is not feasible, then primary repair should be aborted. This occurs with defects of more than 1-1.5 cm in length. One should marsupialise the urethra preparatory to a two-stage urethral repair, and consider a suprapubic urinary diversion. Perform a delayed elective procedure a minimum of 3 months after injury. There is no role for acute placement of a graft or flap in the initial management of any urethral injury, since contamination or decreased blood supply can compromise such a repair (33).

5.3.1.2.2 Female urethral injuries

Most female urethral disruptions can be sutured primarily. These injuries often occur together with bladder ruptures. Frequently, if the bladder injury is going to be repaired primarily, the urethral disruption can be repaired at the same time. For proximal urethral injuries, urethral exposure is best obtained transvesically. Distal urethral injuries can be approached vaginally (29). Early repair of post-traumatic urethral fistulae can also be accomplished transvaginally (4, 12).

5.3.2 Posterior urethral injuries

It is important to distinguish between inflammatory or iatrogenic posterior urethral strictures and true pelvic fracture urethral distraction defects as the principles of their surgical management are entirely different. Urethral stricture indicates a narrowing of the urethral lumen. In urethral distraction defects, there is a gap between the two otherwise normal ends of the urethra. The dismembered ends of the urethra retract, and the space between them fills with fibrous tissue. There is no urethral wall in the scarred space, and any lumen represents merely a fistulous tract between the urethral stumps. A further difference between inflammatory strictures and distraction defects is that the urethral stumps are usually not fibrotic and can be re-anastomosed without tension after distraction injury. Once anastomosed, they usually heal without stricture (51).

Erectile dysfunction occurs in 20-60% of patients after traumatic posterior urethral rupture (51-55). The most important determining factor associated with impotence is the severity of the initial injury. The incidence of erectile dysfunction being caused by the open surgical repair itself is 5% or less (51, 56). Erectile dysfunction seems to be a direct result of the pelvic fracture plus urethral injury. King reported an incidence of 42% in cases of pelvic fracture and urethral injury, but only 5% when the urethra was not injured (53). Barbagli et al. reported an incidence of 60% in patients with posterior urethral injury, compared with 14% in patients with bulbar injury (57).

Factors that correlate with the development of impotence are age, defect length and the type of fracture. Bilateral pubic rami fractures are the most frequent cause of impotence. Impotence is most commonly neurogenic, due to bilateral damage of the cavernous nerves at the prostatomembranous urethra behind the symphysis pubis (58, 59). Associated vasculogenic erectile failure may occur in up to 80% of cases (60). Dixon et al. presented evidence that impotence may also be a consequence of avulsion of the corporus cavernosum from the ischium (14). In this series, five out of six patients with avulsion of the corpus cavernosum off the inferior pubic ramus, were impotent. Spontaneous return of potency may occur up to 2 years after injury (42). Gibson reported an incidence of improved sexual function after 18 months in 21% of patients (52).

5.3.2.1 Partial urethral rupture

Manage partial tears of the posterior urethra with a suprapubic or urethral catheter. Perform urethrography at 2-weekly intervals until healing has occurred (29, 37). They may heal without significant scarring or obstruction if managed by diversion alone (48,61). Manage residual or subsequent stricture with urethral dilatation or optical urethrotomy if short and flimsy, and with anastomotic urethroplasty if dense or long (24, 37).

5.3.2.2 Complete urethral rupture

Acute treatment options include:

- primary endoscopic realignment or
- immediate open urethroplasty (**which should be considered experimental** and rarely or never used in patients without associated rectal or bladder neck injury).

Delayed treatment options include:

- 'delayed primary urethroplasty' (which implies primary repair 2 weeks after injury and for **which there is a lack of supporting evidence in male patients**)
- delayed formal urethroplasty at 3 months after injury **(the most standard approach)**
- delayed endoscopic incision of the scar tissue between the urethral ends (so-called 'cut-to-the-light' or similar procedures).

5.3.2.3 Primary realignment

The management of complete posterior rupture of the urethra has changed in recent years. There is now more active orthopaedic management of pelvic fractures with immediate external and internal fixation. This has led to the option of early repair of urethral injuries (37).

In the absence of indications for immediate exploration, posterior urethral disruption can be managed in a delayed primary fashion. Primary realignment requires placement of a suprapubic tube at the time of initial injury, with repair undertaken when the patient is stable, usually within 7 days. At this time, patients are stable, and most pelvic bleeding has resolved. The aim of internal realignment is to correct severe distraction injuries rather than to prevent a stricture occurring, although it will also ensure that it is easily treated if it does occur (62).

Open realignment has been described (63), but it should be performed only in patients who undergo open abdominal or pelvic surgery for associated injuries or internal bone fixation. Haematomas that prevent adequate pelvic descent can be evacuated at this point in these cases.

Concomitant bladder neck or rectal injuries should usually be repaired immediately, and open or endoscopic urethral realignment over a catheter at the same time might be advisable. The reasons for immediate repair of bladder neck and rectal injury are:

1. Unrepaired bladder neck injury risks incontinence and infection of the pelvic fractures
2. Unrepaired rectal injury carries the obvious risk of sepsis and fistula, and early exploration is Indicated to evacuate contaminated haematomas and perform colostomy
3. Urethral realignment over a stenting catheter is appropriate in such cases (29, 40, 64-66).

The overall condition of the patient and the extent of the associated injuries greatly affect the decision to proceed with primary realignment. Most patients with pelvic crush injuries have multiple organ injuries. Associated lower extremity fractures can prevent placement in the lithotomy position, which may be required for primary realignment (although bedside flexible cystoscopy can be used). Head injuries increase the adverse risks of anaesthesia. If these conditions are controlled, such that a haemodynamically stable patient can safely undergo a lengthier anaesthesia and can be placed in the lithotomy position, endoscopic urethral realignment could be considered during the first 2 weeks after trauma.

The proposed benefits of primary alignment are:

1. A lower stricture rate than with suprapubic catheter placement alone (69% versus 10%) (6), which avoids a second operation for urethral reconstruction in about one-third of patients (3)
2. If scarring occurs, restoration of urethral continuity is simplified and may be accomplished by endoscopic procedures or dilatation
3. If urethroplasty is required later, it is technically easier when the prostate and urethra are well aligned; the disadvantage might be a higher incidence of erectile dysfunction and incontinence when compared with delayed reconstruction (6, 67).

The great variation of techniques used for primary realignment procedures confuses any comparison with delayed repair procedures (68-71). Primary realignment techniques include:

- simple passage of a catheter across the defect (70)
- catheter realignment using flexible/rigid endoscopes and biplanar fluoroscopy (72, 73)
- use of interlocking sounds ('railroading') or magnetic catheters to place the catheter (71, 74)
- pelvic haematoma evacuation and dissection of the prostatic apex (with or without suture anastomosis) over a catheter

- catheter traction or perineal traction sutures to pull the prostate back to its normal location (75).

Realignment may be insufficient to join the margins of the severed urethra completely, and 1.5-4.0 cm defects have been observed even after catheter realignment (76). This finding agrees with experimental animal data, which show that when the urethra is transacted and an apparently good urethral junction is achieved by catheter traction, there is no evidence of epithelialisation of the mucosal gap, but rather that the intervening area is filled with fibrous tissue (77).

Traction on the catheter might not improve the healing of the urethra, and could in fact harm continence. Sustained traction on the Foley balloon catheter can damage the remaining sphincter mechanism at the bladder neck as a result of pressure necrosis (3, 64). Series that use immediate urethral realignment with minimal traction without suture repair bolsters report the most favourable results (Table 11).

Endoscopic primary realignment fulfils these criteria and should be used when a primary procedure is contemplated. Open primary realignment in the absence of bladder neck injury or rectal injury has no place in the treatment of posterior urethral injuries because of its higher morbidity.

Table 11: Results of immediate realignment in complete urethral disruption (68, 70, 72, 74, 77-91)

Series	Ref.no.	No. of patients	Follow-up months (range)	Erectile dysfunction	Incontinence	Restricture rate
Gibson (1974)	77	35†	n/a	12 (34%)	1 (3%)	26 (74.3%)
Crassweller et al. (1977)	78	38	– (24-240)	19/42 (45%)	n/a	12 (31.6%)
Malek et al. (1977)‡	79	7	168 (96-264)	0	0	1 (14.3%)
Gelbard et al. (1989)	72	7	10.2 (2-24)	1/6 (16.7%)	0	2 (33%)
Cohen et al. (1991)	80	4	28 (17-35)	2 (50%)	0	2 (50%)
Melekos et al. (1992)	81	4	n/a	0	0	4 (100%)
Follis et al. (1992)	68	20	42 (1-360)	4 (20%)	2 (10%)	12 (60%)
El-Abd (1995)	82	44	n/a	35 (79.5%)	0	44 (100%)
Gheiler and Frontera (1997)	83	3	6 (5-9)	0	0	1 (33.3%)
Londergan et al. (1997)	84	4	20.2 (12-35)	1 (25%)	0	3 (75%)
Elliott and Barrett (1997)	85	53	126 (1->120)	11 (21%)	2 (3.8%)	36 (68%)
Porter et al. (1997)	70	10	10.9 (2-31)	1/7 (14%)	0	5 (50%)
Rehman et al. (1998)	86	3	– (11-26)	1 (16.7%)	0	2 (66.7%)
Sahin et al. (1998)	87	5	31 (21-53)	1 (20%)	1 (20%)	4 (80%)
Tahan et al. (1999)	88	13	29 -	3 (23%)	0	5 (38.5%)
Jepson et al. (1999)	89	8	50.4 (35-85)	3 (37.5%)	1 (12.5%)	5 (62.5%)
Asci et al. (1999)	90	20	39 (19-78)	4 (20%)	2 (10%)	9 (45%)
Ying-Hao et al. (2000)	91	4	56 (39-85)	0	0	1 (25%)
Moudouni et al. (2001)	92	23	68 (18-155)	4/29 (14%)	0	16 (69.5%)
Mouraviev et al. (2005)	74	57	< 24 (2-15)	19/57 (34%)	10/57 (10%)	28/57 (49%)
Total		362		130/368 (35.3%)§	19/362 (5.2%)	218/362 (60.2%)

**Stricture that requires internal urethrotomy, or open urethroplasty, or more than one dilatation;*

†5 patients with partial rupture;
‡children;
§some partial ruptures included.
This type of summary of the literature suggests that immediate realignment is associated with an impotence rate of approximately 35%, an incontinence rate of 5% and a restricture rate of 60%.

5.3.2.4 Immediate open urethroplasty
Immediate open urethroplasty of posterior injuries is not indicated because of poor visualisation and the inability to assess accurately the degree of urethral disruption during the acute phase, characterised by extensive swelling and ecchymosis. The difficulty in identifying structures and planes hampers adequate mobilisation and subsequent surgical apposition (24). Incontinence and impotence rates are higher than with the other techniques described in these guidelines (impotence 56%, incontinence 21%, restricture 49%) (6, 29, 48, 62, 65, 93, 94).

However, in posterior urethral injuries associated with concomitant bladder neck or rectal injuries, immediate open exploration, repair and urethral realignment over a catheter is advisable (29, 40, 64-66). In children, similar results have been reported with delayed repair and immediate open urethroplasty (63).

5.3.2.5 Delayed primary urethroplasty
Delayed primary urethroplasty is mainly indicated in female urethral disruption, although no large series exists. It requires placement of a suprapubic tube at the time of initial injury, with repair undertaken when the patient is stable, usually within 7 days. Fewer than 50 cases have been reported, and most of these are individual case reports only (12).

Delayed primary repair tries to preserve as much urethral length as possible, and to avoid the urethra becoming embedded in dense scar tissue with consequent incontinence. Surgical exploration should be attempted via the retropubic route for proximal injuries, and the vaginal route for distal injuries (29).

5.3.2.6 Delayed urethroplasty
Delayed urethroplasty is the procedure of choice and the gold standard for the treatment of posterior urethral distraction defects.

Most posterior urethral distraction defects are short, and these can generally be resolved by a perineal approach anastomotic repair, provided that they are not associated with extensive haematoma-fibrosis and the bladder neck mechanism is occlusive and competent. After division of the bulbar urethra at the distal point of obliteration, mobilisation of a normal bulbar urethra to the base of the penis generally achieves 4-5 cm of elastic lengthening. This is usually sufficient to achieve a tension-free 2 cm spatulated overlap anastomosis, after bridging a gap of 2.0-2.5 cm without rerouting (24).

This technique has the advantage that associated injuries, damaged skin and tissues, and pelvic haematoma have resolved by the time it is performed. The only problem with this approach would be the length of time that the patient must have a suprapubic catheter in place before definitive treatment.

When the prostatobulbar gap is longer than 2-3 cm as a result of a high dislocation of the prostate, or when the available elongation of the mobilised urethra has been foreshortened by damage caused by a previous surgical procedure, additional procedures may be required. The following manoeuvres are carried out sequentially to gain sufficient anterior urethral mobility to bridge up to 8 cm of separation, and are referred to as the 'progressive perineal approach' (95):

- midline separation of the proximal corporal bodies
- inferior pubectomy
- supracorporal urethral rerouting.

In addition to its use as an initial therapy for posterior urethral distraction injuries, the progressive perineal approach can also be applied successfully to salvage procedures following failed repair.

There is a number of circumstances that might preclude successful perineal anastomotic repair as either initial or salvage therapy. These circumstances probably represent fewer than 5% of cases and are shown in Table 12 (96, 97).

Table 12: Circumstances that might preclude successful perineal anastomotic repair as either initial or salvage therapy (96, 97)

Circumstance	Alternati ve procedure
Distraction defects longer than 7-8 cm	A tubed interposition flap of penile or peri-neoscrotal skin can be used for reconstruction. This is seldom required and most patients that require the use of flap urethroplasties have previous failed repairs of posterior urethral rupture (see section 4.3.2.7).
Fistulae	These might require a combined abdominoperineal approach to secure adequate closure.
Synchronous anterior urethral stricture	The presence of anterior urethral stricture may compromise the blood supply to the bulbar urethra following division of the bulbar arteries, and these patients should be treated cautiously.
Urinary incontinence	The distal urethral sphincter mechanism could be defunctionalised by urethral distraction, so urinary continence may be maintained primarily by the proximal bladder neck sphincter. Concomitant bladder neck injury might increase incontinence, and could require an abdominoperineal procedure to allow simultaneous bladder neck and urethral reconstruction. The most common cause of bladder neck incompetence is the circumferential tethering of the uninjured bladder neck by scarring. In such cases, it is usually possible to restore functional competence of the bladder neck by mobilising it meticulously. This can be accomplished by removal of the dense haematoma-fibrosis anchoring the bladder neck to the pubis, anteriorly and laterally. Secondary rescarring is prevented by placement of a local omental flap (44, 98).

The results of various techniques are reviewed by Koraitim (66) in a personal series of 100 patients combined with a review of 771 patients from published reports. Immediate and early realignment (n = 326) was associated with rates of 53% for stricture, 5% for incontinence, and 36% for impotence. Of the patients successfully managed with immediate realignment, 42% needed subsequent instrumentation to attempt stabilisation of stricture. Urethroplasty was ultimately necessary in 33%.

Primary suturing (n = 37) was associated with rates of 49% for stricture, 21% for incontinence, and 56% for impotence. In comparison, inserting a suprapubic catheter before delayed repair (n = 508) was associated with rates of 97% for stricture, 4% for incontinence, and 19% for impotence.

The restricture rate after delayed anastomotic urethroplasty was less than 10% (28, 38, 43, 51, 55, 99-102), and the risk of impotence caused by delayed urethroplasty was about 5% (37, 51, 55, 56, 65, 103-105).

The gold standard remains delayed urethral repair at a minimum of 3 months after trauma, using a one-stage perineal approach.

The results obtained in children are similar to those in adults. The higher incidence of abdominal surgery simply reflects the greater propensity to damage of the bladder neck in children (105-106).

5.3.2.7 Reconstruction of failed repair of posterior urethral rupture

Restenosis after delayed urethral repair mostly occurs within 6 months. If the anastomosis has a normal calibre at 6 months, then it is extremely unlikely that the patient will develop further stricturing (38).

The principles of salvage repair are similar to those of the initial procedure. Progressive perineal anastomotic repair alone can be successful in 85% of salvage urethroplasties. If an anastomotic repair cannot be performed, a one-stage substitution urethroplasty using a pedicle island of penile skin might be possible and could be more desirable than the final alternative, a two-stage scrotourethral inlay procedure or mesh split-thickness skin graft urethroplasty (63, 107, 108).

The main indications for a combined abdominoperineal surgical approach are:

- the presence of fistulous tracts to the bladder base, abdominal wall or rectum
- peri-urethral epithelialised cavities
- an ability to achieve the lithotomy position (97).

Restenosis to a luminal calibre of 12 French Foley catheter or smaller is required before a reduction in the urinary flow is perceived as abnormal (109). A wide calibre stricture may be observed or gently dilated. Optical urethrotomy is an alternative, particularly for a short, narrow stricture.

5.3.2.8 Delayed endoscopic optical incision

The principles of the procedure were described by Sachse in 1974 (109). A curved metal sound is passed through the suprapubic cystostomy into the blind-ended proximal urethra. The direct vision urethrotome is inserted into the urethra, and cuts are made towards the sound.

Blandy described a modification of this procedure: suprapubic passage of a cystoscope for transillumination of the thin perineal membrane and transurethral 'cutting-to-the-light' with an electrode (110). Today, the cut-to-the-light technique is sometimes carried out using C-arm fluoroscopy for stereotactic guidance. The urethral catheter is left in place for between 1 and 3 weeks, and the suprapubic drainage for an additional 2 weeks to confirm consistent voiding (111).

The results of several small series have been reported and are summarised in Table 13.

Table 13: Results of optical urethrotomy for traumatically obliterated pelvic urethra (82, 112-116, 118-123)

Series	Ref. no.	n	Follow-up months (range)	No. (%) requiring repeat urethrotomy	Erectile dysfunction
Gupta and Gill (1986)	112	10	15.1 (6-24)	10 (100%)	0
Chiouet et al. (1988)	113	8	43 (12-79)	7 (87.5%)	0
Marshall (1989)	114	10	n/a	10 (100%)	0
Barry (1989)	115	12	22 (1.5-85)	6 (50%)	0
DeVries and Anderson (1990)	116	4	< 4	1 (25%)	0
Kernohan et al. (1990)	118	7	35 (21-84)	7 (100%)	0
Yasuda et al. (1991)	119	17	44 (12-96)	7 (41.2%)	0
Quint and Stanisic (1993)	120	10	43 (7-108)	6 (60%)	0
El-Abd (1995)	82	284	n/a	272 (95.8%)	0
Goel et al. (1997)	121	13	17.7 (11-24)	10 (76.9%)	n/a
Levine and Wessells (2001)	122	6	60	6 (100%)	n/a
Dogra and Nabi (2002)*	123	61	30 (9-44)	11 (18%)	n/a
Total		445		354 (79.5%)	

**Laser urethrotomy.*

The procedure is only indicated if the urethral defect is short, the bladder neck is competent and there is minimal displacement of the prostate and proximal bulbous urethra (116). Although immediate restoration of urethral continuity is commonly possible, failure is common. Urethral dilatation, optical urethrotomy and transurethral resection of stricture will be needed in about 80% of patients. Most repeat urethrotomies are performed in the first year of follow-up.

It should be noted that after failure of the initial urethrotomy, alternative treatments should be considered, as repeat urethrotomy achieves only temporary improvement (124). Urethral false passage and rectal perforation have been reported (112, 116, 119). Stents are not currently recommended for patients with strictures following pelvic trauma, as fibrotic tissue tends to grow though into the lumen of the stent (43, 125-127).

5.4 Recommendations for treatment: algorithms

The optimal management of patients with prostatomembranous disruptions should not be thought of as delayed repair versus other types of treatment modalities. Each patient should be assessed and managed according to the initial clinical circumstances. It is impractical to suggest that all patients be managed by one single method because of the variability of each case and the severity of associated injuries. The intervention should be guided by the clinical circumstances. The following algorithms are suggested for the treatment of urethral injuries in males and females (Figures 5-7).

Figure 5: Management of posterior urethral injuries in men

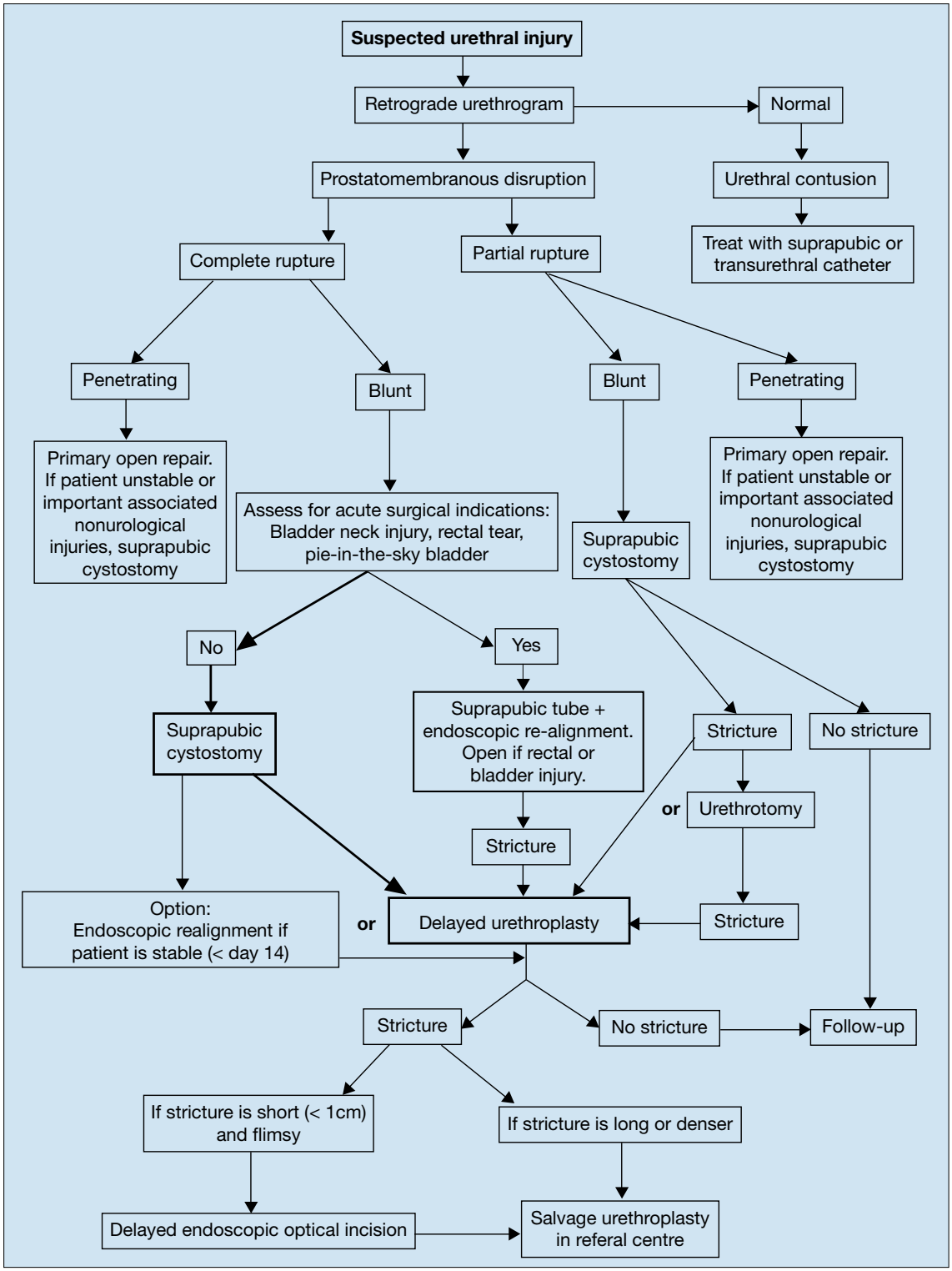

Figure 6: Management of anterior urethral injuries in men

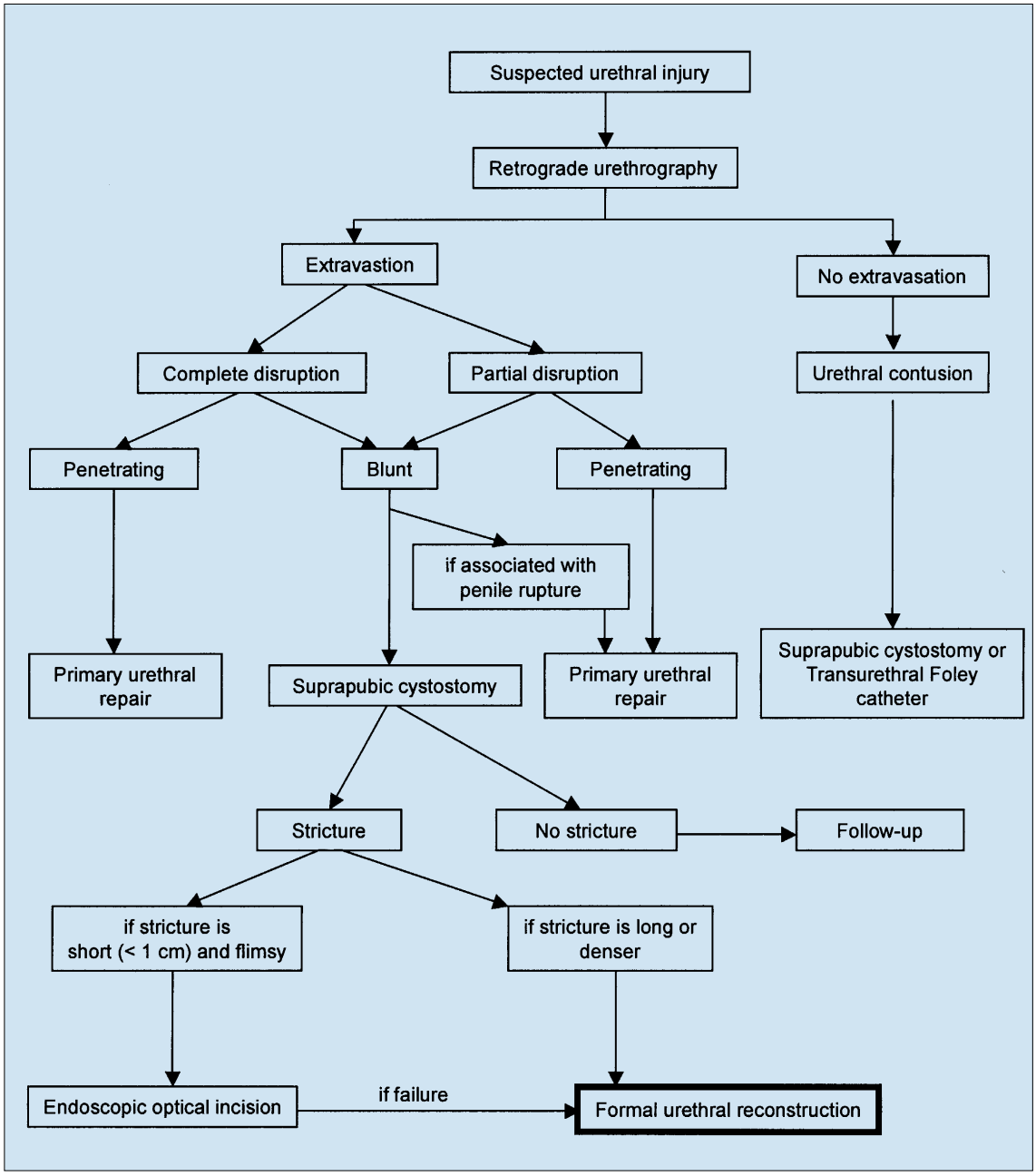

Figure 7: Management of urethral injuries in women

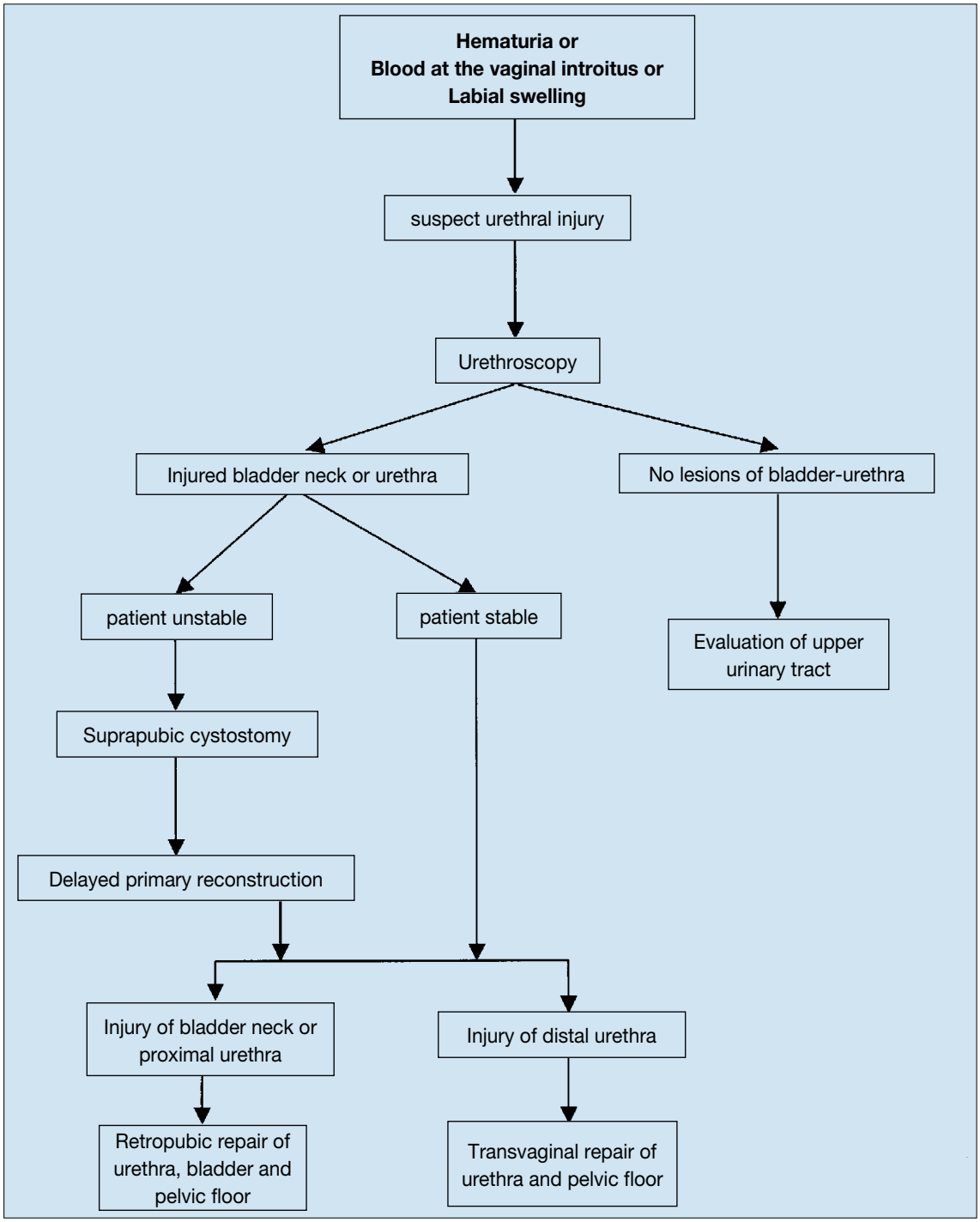

5.5 Iatrogenic urethral trauma

5.5.1 Introduction

The most common form of iatrogenic urethral trauma is that caused by instruments. Most of the relevant urethral lesions caused by iatrogenic trauma are strictures. These strictures are of variable location and severity. They often require different management strategies (128, 129).

5.5.2 Iatrogenic urethral trauma caused by catheterisation

The majority of iatrogenic lesions are the result of improper or prolonged catheterisation. They are surprisingly common and account for 32% of urethral strictures. Of these, 52% affect the bulbar and/or prostatic urethra (129) (level of evidence 3).

Improper insertion of a urethral catheter is a preventable cause of urethral trauma in male patients (130) (level of evidence 4). The incidence of this type of urethral injury, especially weighed against the total number of

urethral catheterisations performed in the same period of time, is difficult to evaluate, and there have been no statistical data published on this matter so far. However, the risk to an individual patient of a urethral injury caused by improper catheterisation during a hospital stay has been estimated to be 3.2:1000 (129).

Prolonged catheterisation contributes to stricture formation (129). The anterior urethra is primarily affected. The bladder neck is rarely affected (131) (level of evidence 1b). Iatrogenic urethral injuries can be prevented by the implementation of educational programmes for medical practitioners that are designed to decrease the exposure of patients to catheter-related risk factors (such as prolonged catheterisation and improper catheterisation) (132) (level of evidence 2b).

5.5.3 Iatrogenic urethral trauma caused by transurethral surgery

Transurethral procedures, especially transurethral resection of the prostate (TUR-P), are the second most common cause of iatrogenic urethral lesions. Electrical dispersion generated by unipolar electric current, and direct urethral injury related to the diameter of the instruments used are factors (133) (level of evidence 1b). Risk factors include:

- large prostate volume
- the presence of prostate cancer
- inexperienced surgeon.

Another cause of stricture formation following transurethral procedures is the form of post-operative urinary drainage used. Urethral catheterisation following transurethral procedures such as TUR-P, and general post-operative urinary drainage with silicone Foley catheters, both result in a higher incidence of stricture development (134) (level of evidence 1b).

5.5.4 Iatrogenic urethral trauma related to surgical prostate cancer treatment

A major source of iatrogenic urethral trauma is the treatment of prostate cancer. Urethral stricture after prostate cancer treatment can occur anywhere from the bladder neck to the meatus. The rate of bladder neck contracture after radical prostatectomy lies between 0.5% and 32%, varying according to the definition of stricture and individual practice (135, 136) (level of evidence 2a).

The incidence of urethral stricture after multiple forms of prostate cancer therapy is determined from the CaPSURE database, a registry of men with biopsy-proven prostate cancer. The incidence varies from 1.1-8.4%, depending on the form of cancer treatment. The risk is highest after radical prostatectomy or brachytherapy plus external beam radiotherapy. Stricture formation after prostatectomy occurred within the first 24 months, whereas onset was delayed after radiation therapy. In a multivariate analysis, the type of primary treatment, age and obesity were found to be significant predictors for stricture development (135) (level of evidence 2b).

New surgical methods, such as robot-assisted prostatectomy can also cause iatrogenic trauma. In a recent study, bladder neck contracture was found in 2% of these patients. This correlates to the stricture rate found after conventional radical prostatectomy (137) (level of evidence 2b).

5.5.5 Iatrogenic urethral trauma related to radiotherapy for prostate cancer treatment

Prostate brachytherapy (BT), external beam radiotherapy (EBRT), or a combination of the two are options for selected patients as the primary treatment for prostate cancer. Any of these options can cause urinary fistulas, with an incidence of 0.3-3% for patients after BT, and 0.0-0.6% of those treated with EBRT. Most fistulas will involve the rectum (138, 139) (level of evidence 3).

5.5.6 Iatrogenic urethral trauma related to major abdominal surgery

Iatrogenic injuries to the urethra can occur after abdominal and pelvic procedures. Pre-procedure bladder catheterisation must be performed to prevent or to reveal these complications (140) (level of evidence 2).

5.5.7 Symptoms of iatrogenic urethral injury

The symptoms of urethral injury caused by improper catheterisation or use of instruments are:

- penile and/or perineal pain (100%)
- urethral bleeding (86%) (4) (level of evidence 2b).

Failure accurately to diagnose and treat urethral injuries may lead to significant long-term sequelae (141).

5.5.8 Diagnosis

The diagnostic investigation of iatrogenic urethral trauma does not differ from that of other urethral injuries.

5.5.9 Treatment

Temporary urethral stenting with an indwelling catheter is a good conventional therapeutic option for treating acute false passage (142). The placement of a urethral catheter may be impossible, and endoscopic assistance or even placement of a suprapubic tube might be necessary (143) (level of evidence 3).

Iatrogenic prostatic urethral strictures after radical prostatectomy can be successfully treated by endoscopic management, either by incision or resection. Failure rates can be high, and repeat therapy might be necessary. The alternative is an indwelling catheter, urethral dilatation or open procedures. Open procedures might be required to salvage recurrent cases, but have increased morbidity (144) (level of evidence 2b).

Conservative treatment in patients with urethral lesions caused by radiotherapy is often ineffective. Major surgery or lifelong suprapubic diversion might ultimately be necessary (138, 139) (level of evidence 3).

Table 14 details the most common causes of stricture, and Figures 8-10 show flow diagrams for the treatment of stricture after urethral injury due to improper insertion of a catheter, radical prostatectomy and major abdominal surgery or radiotherapy, respectively.

Table 14 Aetiology of stricture

Causes of stricture
Improper catheterisation
Transurethral surgery
Prostate cancer surgery
Prostate cancer radiotherapy
Abdominal and pelvic surgery

5.5.10 Recommendations for treatment: algorithms

Figure 8: Flow diagram of treatment for iatrogenic urethral injury caused by improper insertion of a catheter

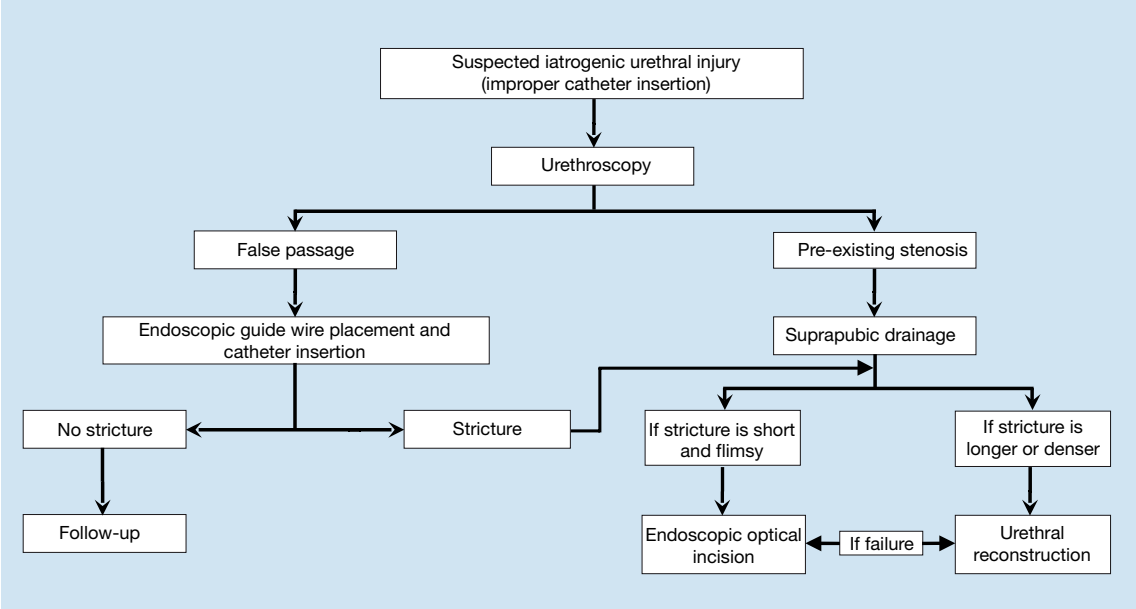

Figure 9: Flow diagram of treatment for stricture after radical prostatectomy

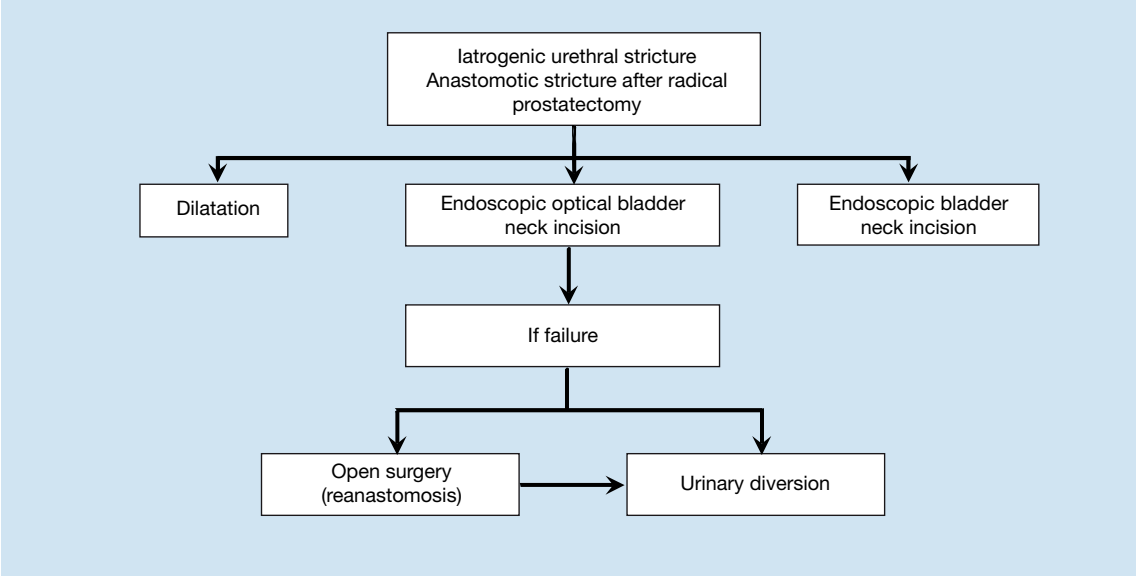

Figure 10: Flow diagram for treatment for stricture after major abdominal surgery or radiotherapy

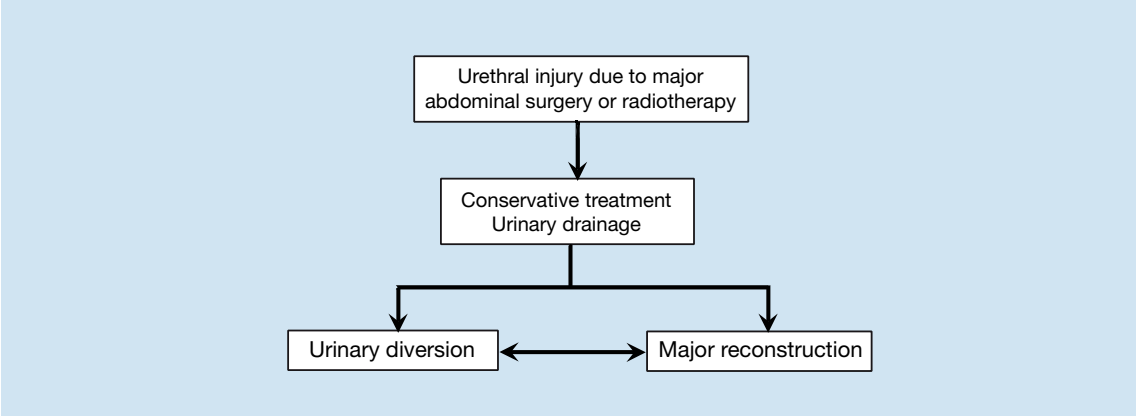

5.5.11 Recommendations

Recommendations
• Avoid traumatic catheterisation.
• Keep the length of time an indwelling catheter is present to a minimum.
• Major abdominal and pelvic surgery should be undertaken with a catheter inserted.

5.6 REFERENCES

1. Sevitt S. Fatal road accidents. Injuries, complications, and causes of death in 250 subjects. Br J Surg 1968 Jul;55(7):481-505 (level of evidence: 3). http://www.ncbi.nlm.nih.gov/pubmed/5663432
2. Koraitim MM, Marzouk ME, Atta MA, Orabi SS. Risk factors and mechanism of urethral injury in pelvic fractures. Br J Urol 1996 Jun;77(6):876-80 (level of evidence: 2b). http://www.ncbi.nlm.nih.gov/pubmed/8705225
3. Dixon CM. Diagnosis and acute management of posterior urethral disruptions, In: McAninch JW (ed). *Traumatic and reconstructive urology*. Philadelphia: WB Saunders, 1996, pp. 347-355 (level of evidence: 4).
4. Perry MO, Husmann DA. Urethral injuries in female subjects following pelvic fractures. J Urol 1992 Jan;147(1):139-43. http://www.ncbi.nlm.nih.gov/pubmed/1729508

5. Colapinto V. Trauma to the pelvis: urethral injury. Clin Ortho Rel Res 1980;Sep(151):46-55 (level of evidence: 3).
http://www.ncbi.nlm.nih.gov/pubmed/7418323
6. Webster GD, Mathes GL, Selli C. Prostatomembranous urethral injuries: a review of the literature and a rational approach to their management. J Urol 1983 Nov;130(5):898-902 (level of evidence: 4).
http://www.ncbi.nlm.nih.gov/pubmed/6355512
7. Carlin BI, Resnick MI. Indications and techniques for urologic evaluation of the trauma patient with suspected urologic injury. Semin Urol 1995 Feb;13(1):9-24 (level of evidence: 4).
http://www.ncbi.nlm.nih.gov/pubmed/7597359
8. Palmer JK, Benson GS, Corriere JN Jr. Diagnosis and initial management of urological injuries associated with 200 consecutive pelvic fractures. J Urol 1983 Oct;130(4):712-4 (level of evidence: 2b).
http://www.ncbi.nlm.nih.gov/pubmed/6887403
9. Lowe MA, Mason JT, Luna GK, Maier RV, Copass MK, Berger RE. Risk factors for urethral injuries in men with traumatic pelvic fractures. J Urol 1988 Sep;140(3):506-7 (level of evidence: 3).
http://www.ncbi.nlm.nih.gov/pubmed/3411661
10. Clark SS, Prudencio RF. Lower urinary tract injuries associated with pelvic fractures. Diagnosis and management. Surg Clin North Am. 1972 Feb;52(1):183-201 (level of evidence: 3).
http://www.ncbi.nlm.nih.gov/pubmed/5013219
11. Pokorny M, Pontes JE, Pierce JM Jr. Urological injuries associated with pelvic trauma. J Urol 1979 Apr;121(4):455-7 (level of evidence: 3).
http://www.ncbi.nlm.nih.gov/pubmed/439217
12. Hemal AK, Dorairajan LN, Gupta NP. Posttraumatic complete and partial loss of urethra with pelvic fracture in girls: an appraisal of management. J Urol 2000 Jan;163(1):282-7 (level of evidence: 3).
http://www.ncbi.nlm.nih.gov/pubmed/10604377
13. Colapinto V, McCallum RW. Injury to the male posterior urethra in fractured pelvis: a new classification. J Urol 1977 Oct;118(4):575-80 (level of evidence: 3).
http://www.ncbi.nlm.nih.gov/pubmed/916052
14. Dixon CM, Hricak H, McAninch JW. Magnetic resonance imaging of traumatic posterior urethral defects and pelvic crush injuries. J Urol 1992 Oct;148(4):1162-5 (level of evidence: 3).
http://www.ncbi.nlm.nih.gov/pubmed/1404629
15. Mouraviev VB, Santucci RA. Cadaveric anatomy of pelvic fracture urethral distraction injury: most injuries are distal to the external urinary sphincter. J Urol 2005 Mar;173(3):869-72 (level of evidence: 3).
http://www.ncbi.nlm.nih.gov/pubmed/15711300
16. Turner-Warwick R. Observations on the treatment of traumatic urethral injuries and the value of the fenestrated urethral catheter. Br J Surg 1973 Oct;60(10):775-81 (level of evidence: 3).
http://www.ncbi.nlm.nih.gov/pubmed/4748381
17. Basta AM, Blackmore CC, Wessells H. Predicting urethral injury from pelvic fracture patterns in male patients with blunt trauma. J Urol 2007 Feb;177(2): 571-5 (level of evidence: 2a).
http://www.ncbi.nlm.nih.gov./pubmed/17222635
18. Pennal GF, Tile M, Waddell JP, Garside H. Pelvic disruption: assessment and classification. Clin Orthop Relat Res.1980 Sep;(151):12-21 (level of evidence: 4).
http://www.ncbi.nlm.nih.gov/pubmed/7418295
19. Conolly WB, Hedberg EA. Observations on fractures of the pelvis. J Trauma 1969 Feb;9(2):104-111 (level of evidence: 3).
http://www.ncbi.nlm.nih.gov/pubmed/5763326
20. Flaherty JJ, Kelley R, Burnett B, Bucy J, Surian M, Schildkraut D, Clarke BG. Relationship of pelvic bone fracture patterns to injuries of urethra and bladder. J Urol 1968 Mar;99(3):297-300 (level of evidence: 3).
http://www.ncbi.nlm.nih.gov/pubmed/5689611
21. Devine PC, Devine CJ Jr. Posterior urethral injuries associated with pelvic fractures. Urology 1982 Nov;20(5):467-70 (level of evidence: 4).
http://www.ncbi.nlm.nih.gov/pubmed/7147524
22. Zorn G. [Fractures of the pelvis with urethral injuries, their treatment and results.] Bruns Beitr Klin Chir 1960;201:147-55 (level of evidence: 3). [article In German]
http://www.ncbi.nlm.nih.gov/pubmed/13788802
23. Siegel JH, Dalal SA, Burgess AR, Young JW. Pattern of organ injuries in pelvic fracture: impact force implications for survival and death in motor vehicle injuries. Accid Anal Prev 1990 Oct;22(5):457-66 (level of evidence: 3).
http://www.ncbi.nlm.nih.gov/pubmed/2222708

24. Chapple CR, Png D. Contemporary management of urethral trauma and the post-traumatic stricture. Curr Opin Urol 1999 May;9(3):253-60 (level of evidence: 4).
http://www.ncbi.nlm.nih.gov/pubmed/10726100
25. Moore EE, Cogbill TH, Jurkovich GJ, McAninch JW, Champion HR, Gennarelli TA, Malangoni MA, Shackford SR, Trafton PG. Organ injury scaling. III: Chest wall, abdominal vascular, ureter, bladder, and urethra. J Trauma 1992 Sep;33(3):337-9 (level of evidence: 4).
http://www.ncbi.nlm.nih.gov/pubmed/1404499
26. Goldman SM, Sandler CM, Corriere JN Jr, McGuire EJ. Blunt urethral trauma: a unified, anatomical mechanical classification. J Urol 1997 Jan;157(1):85-9 (level of evidence: 3).
http://www.ncbi.nlm.nih.gov/pubmed/8976222
27. Al-Rifaei M, Eid NI, Al-Rifaei A. Urethral injury secondary to pelvic fracture: anatomical and functional classification. Scand J Urol Nephrol 2001 Jun;35(3):205-11 (level of evidence: 3).
http://www.ncbi.nlm.nih.gov/pubmed/11487073
28. Koraitim MM. Posttraumatic posterior urethral strictures in children: a 20-year experience. J Urol 1997 Feb;157(2):641-5 (level of evidence: 3) .
http://www.ncbi.nlm.nih.gov/pubmed/8996388
29. Koraitim MM. Pelvic fracture urethral injuries: the unresolved controversy. J Urol 1999 May;161(5): 1433-41 (level of evidence: 4).
http://www.ncbi.nlm.nih.gov/pubmed/10210368
30. Nicolaisen GS, Melamud A, Williams RD, McAninch JW. Rupture of the corpus cavernosum: surgical management. J Urol 1983 Nov;130(5):917-9 (level of evidence: 3).
http://www.ncbi.nlm.nih.gov/pubmed/6632099
31. Gomez RG, Castanheira AC, McAninch JW. Gunshot wounds to the male external genitalia. J Urol 1993 Oct;150(4):1147-9 (level of evidence: 3).
http://www.ncbi.nlm.nih.gov/pubmed/8371375
32. Pontes JE, Pierce JM Jr. Anterior urethral injuries: four years of experience at the Detroit General Hospital. J Urol 1978 Nov;120(5):563-4 (level of evidence: 3).
http://www.ncbi.nlm.nih.gov/pubmed/568672
33. Armenakas NA, McAninch JW. Acute anterior urethral injuries: diagnosis and initial management. In: McAninch JW (ed). *Traumatic and reconstructive urology*. Philadelphia, PA:WB Saunders, 1996, pp. 543-550 (level of evidence: 4).
34. Armenakas NA, McAninch JW. A uniform approach to urethroplasty. Probl Urol 1994;8(2):254-68 (level of evidence: 4).
35. Lim PH, Chng HC. Initial management of acute urethral injuries. Br J Urol 1989 Aug;64(2):165-8 (level of evidence: 3).
http://www.ncbi.nlm.nih.gov/pubmed/2765784
36. McAninch JW. Traumatic injuries to the urethra. J Trauma 1981 Apr;21(4):291-7 (level of evidence: 3).
http://www.ncbi.nlm.nih.gov/pubmed/7218395
37. Venn SN, Mundy AR. Immediate management of major trauma to the urinary tract. Eur Urol 1998;33 (Curric Urol 3.1):1-8 (level of evidence: 4).
38. Mundy AR. Urethroplasty for posterior urethral strictures. Br J Urol 1996 Aug;78(2):243-7 (level of evidence: 2b).
http://www.ncbi.nlm.nih.gov/pubmed/8813921
39. Corriere JN Jr, Harris JD. The management of urological injuries in blunt pelvic trauma. Radiol Clin North Am 1981 Mar;19(1):187-93 (level of evidence: 4).
http://www.ncbi.nlm.nih.gov/pubmed/7194489
40. Antoci JP, Schiff M Jr. Bladder and urethral injuries in patients with pelvic fractures. J Urol 1982 Jul;128(1):25-6 (level of evidence: 3).
http://www.ncbi.nlm.nih.gov/pubmed/7109063
41. Fallon B, Wendt JC, Hawtrey CE. Urological injury and assessment in patients with fractured pelvis. J Urol 1984 Apr;131(4):712-4 (level of evidence: 3).
http://www.ncbi.nlm.nih.gov/pubmed/6708187
42. Koraitim MM and Reda IS. Role of magnetic resonance imaging in assessment of posterior urethral distraction defects. Urology 2007 Sep;70:403-6 (level of evidence: 3).
http://www.ncbi.nlm.nih.gov./pubmed/17905082
43. Jordan GH. Management of membranous urethral distraction injuries via the perineal approach. In: McAninch JW (ed). *Traumatic and reconstructive urology*. Philadelphia, PA: WB Saunders, 1996, pp. 393-409 (level of evidence: 4).

44. Iselin CE, Webster GD. The significance of the open bladder neck associated with pelvic fracture urethral distraction defects. J Urol 1999 Aug;162(2):347-51 (level of evidence: 3).
http://www.ncbi.nlm.nih.gov/pubmed/10411036
45. Kane NM, Francis IR, Ellis JH. The value of CT in the detection of bladder and posterior urethral injuries. Am J Roentgenol 1989 Dec;153(6):1243-6 (level of evidence: 3).
http://www.ncbi.nlm.nih.gov/pubmed/2816642
46. McAninch JW. Urethral injuries in female subjects following pelvic fractures (editorial comment). J Urol 1992;147(1):143 (level of evidence: 4).
47. Jackson DH, Williams JL. Urethral injury: a retrospective study. Br J Urol 1974 Dec;46(6):665-76 (level of evidence: 3).
http://www.ncbi.nlm.nih.gov/pubmed/4451833
48. Glassberg KI, Tolete-Velcek F, Ashley R, Waterhouse K. Partial tears of prostatomembranous urethra in children. Urology 1979 May;13(5):500-4 (level of evidence: 3).
http://www.ncbi.nlm.nih.gov/pubmed/442372
49. Cass AS, Godec CJ. Urethral injury due to external trauma. Urology 1978 Jun;11(6):607-11 (level of evidence: 3).
http://www.ncbi.nlm.nih.gov/pubmed/675928
50. Husmann DA, Boone TB, Wilson WT. Management of low velocity gunshot wounds to the anterior urethra: the role of primary repair versus urinary diversion alone. J Urol 1993 Jul;150(1):70-2 (level of evidence: 3).
http://www.ncbi.nlm.nih.gov/pubmed/8510278
51. Martínez-Piñeiro JA, Cárcamo P, García Matres MJ, Martínez-Piñeiro L, Iglesias JR, Rodríguez Ledesma JM. Excision and anastomotic repair for urethral stricture disease: experience with 150 cases. Eur Urol 1997;32(4):433-41 (level of evidence: 3).
http://www.ncbi.nlm.nih.gov/pubmed/9412802
52. Gibson GR. Impotence following fractured pelvis and ruptured urethra. Br J Urol 1970 Feb;42(1):86-8 (level of evidence: 3).
http://www.ncbi.nlm.nih.gov/pubmed/5435706
53. King J. Impotence after fractures of the pelvis. J Bone Joint Surg Am 1975 Dec;57(8):1107-9 (level of evidence: 3).
http://www.ncbi.nlm.nih.gov/pubmed/1201996
54. Dhabuwala CB, Hamid S, Katsikas DM, Pierce JM Jr. Impotence following delayed repair of prostatomembranous urethral disruption. J Urol 1990 Sep;144(3):677-8 (level of evidence: 3).
http://www.ncbi.nlm.nih.gov/pubmed/2388326
55. Corriere JN. 1-Stage delayed bulboprostatic anastomotic repair of posterior urethral rupture: 60 patients with 1-year followup. J Urol 2001 Feb;165(2):404-7 (level of evidence: 3).
http://www.ncbi.nlm.nih.gov/pubmed/11176383
56. Webster GD. Impotence following delayed repair of prostatomembranous urethral disruption (editorial comment). J Urol 1990;144(3):678 (level of evidence: 3).
57. Barbagli G, Selli C, Stomaci N, Delle Rose A, Trippitelli A, Lenzi R. Urethral trauma: radiological aspects and treatment options. J Trauma 1987 Mar;27(3):256-61 (level of evidence: 3).
http://www.ncbi.nlm.nih.gov/pubmed/3560267
58. Mark SD, Keane TE, Vandemark RM, Webster GD. Impotence following pelvic fracture urethral injury: incidence, aetiology and management. Br J Urol 1995 Jan;75(1):62-4 (level of evidence: 3).
http://www.ncbi.nlm.nih.gov/pubmed/7850299
59. Shenfeld OZ, Kiselgorf D, Gofrit ON, Verstandig AG, Landau EH, Pode D, Jordan GH, McAninch JW. The incidence and causes of erectile dysfunction after pelvic fractures associated with posterior urethral disruption. J Urol 2003 Jun;169(6):2173-6 (level of evidence: 3).
http://www.ncbi.nlm.nih.gov/pubmed/12771742
60. Armenakas NA, McAninch JW, Lue TF, Dixon CM, Hricak H. Posttraumatic impotence: magnetic resonance imaging and duplex ultrasound in diagnosis and management. J Urol 1993 May; 149(5 Pt 2):1272-5 (level of evidence: 3).
http://www.ncbi.nlm.nih.gov/pubmed/8479013
61. Turner-Warwick R. Prevention of complications resulting from pelvic fracture urethral injuries – and from their surgical management. Urol Clin North Am 1989 May;16(2):335-58 (level of evidence: 4).
http://www.ncbi.nlm.nih.gov/pubmed/2652859
62. Mundy AR. The role of delayed primary repair in the acute management of pelvic fracture injuries of the urethra. Br J Urol 1991 Sep;68(3):273-6 (level of evidence: 4).
http://www.ncbi.nlm.nih.gov/pubmed/1913069

63. Onen A, Oztürk H, Kaya M, Otçu S. Long-term outcome of posterior urethral rupture in boys: a comparison of different surgical modalities. Urology 2005 Jun;65(6):1202-7 (level of evidence: 3). http://www.ncbi.nlm.nih.gov./pubmed/15922424
64. Berman AT, Tom L. Traumatic separation of the pubic symphysis with associated fatal rectal tear: a case report and analysis of mechanism of injury. J Trauma 1974 Dec;14(12):1060-7 (level of evidence: 3). http://www.ncbi.nlm.nih.gov/pubmed/4431071
65. Muhlbauer S, Bard RH. Early definitive urologic management of patient with crush pelvic trauma and deep perineal laceration. Urology 1980 Jan;15(1):56-9 (level of evidence: 3). http://www.ncbi.nlm.nih.gov/pubmed/7352346
66. Koraitim MM. Pelvic fracture urethral injuries: evaluation of various methods of management. J Urol 1996 Oct;156(4):1288-91 (level of evidence: 3). http://www.ncbi.nlm.nih.gov/pubmed/8808856
67. Coffield KS, Weems WL. Experience with management of posterior urethral injury associated with pelvic fracture. J Urol 1977 Jun;117(6):722-4 (level of evidence: 3). http://www.ncbi.nlm.nih.gov/pubmed/559782
68. Follis HW, Koch MO, McDougal WS. Immediate management of prostatomembranous urethral disruptions. J Urol 1992 May;147(5):1259-62 (level of evidence: 2b). http://www.ncbi.nlm.nih.gov/pubmed/1569663
69. Herschorn S, Thijssen A, Radomski SB. The value of immediate or early catheterization of the traumatized posterior urethra. J Urol 1992 Nov;148(5):1428-31 (level of evidence: 3). http://www.ncbi.nlm.nih.gov/pubmed/1433542
70. Porter JR, Takayama TK, Defalco AJ. Traumatic posterior urethral injury and early realignment using magnetic urethral catheters. J Urol 1997 Aug;158(2):425-30 (level of evidence: 3). http://www.ncbi.nlm.nih.gov/pubmed/9224316
71. Guille F, Cipolla B, Leveque JM, Guirassy S, Olivo JF, Lobel B. Early endoscopic realignment of complete traumatic rupture of the posterior urethra. Br J Urol 1991 Aug;68(2):178-80 (level of evidence: 3). http://www.ncbi.nlm.nih.gov/pubmed/1884146
72. Gelbard MK, Heyman AM, Weintraub P. A technique for immediate realignment and catheterization of the disrupted prostatomembranous urethra. J Urol 1989 Jul;142(1):52-5 (level of evidence: 3). http://www.ncbi.nlm.nih.gov/pubmed/2733109
73. Turner-Warwick R. Complex traumatic posterior urethral strictures. J Urol 1977 Oct;118(4):564-74 (level of evidence: 3). http://www.ncbi.nlm.nih.gov/pubmed/916051
74. Mouraviev VB, Coburn M, Santucci RA. The treatment of posterior urethral disruption associated with pelvic fractures: comparative experience of early realignment versus delayed urethroplasty. J Urol 2005 Mar;173(3):873-6 (level of evidence: 3). http://www.ncbi.nlm.nih.gov/pubmed/15711301
75. Ragde H, McInnes GF. Transpubic repair of the severed prostatomembranous urethra. J Urol 1969 Mar;101(3):335-7 (level of evidence: 3). http://www.ncbi.nlm.nih.gov/pubmed/5765881
76. McRoberts JW, Ragde H. The severed canine posterior urethra: a study of two distinct methods of repair. J Urol 1970 Nov;104(5):724-9 (level of evidence: 2a). http://www.ncbi.nlm.nih.gov/pubmed/4922399
77. Gibson GR. Urological management and complications of fractured pelvis and ruptured urethra. J Urol 1974 Mar;111(3):353-5 (level of evidence: 3). http://www.ncbi.nlm.nih.gov/pubmed/4813576
78. Crassweller PO, Farrow GA, Robson CJ, Russell JL, Colapinto V. Traumatic rupture of the supramembranous urethra. J Urol 1977 Nov;118(5):770-1 (level of evidence: 3). http://www.ncbi.nlm.nih.gov/pubmed/562426
79. Malek RS, O'Dea MJ, Kelalis PP. Management of ruptured posterior urethra in childhood. J Urol 1977 Jan;117(1):105-9 (level of evidence: 3). http://www.ncbi.nlm.nih.gov/pubmed/830957
80. Cohen JK, Berg G, Carl GH, Diamond DD. Primary endoscopic realignment following posterior urethral disruption. J Urol 1991 Dec;146(6):1548-50 (level of evidence: 3). http://www.ncbi.nlm.nih.gov/pubmed/1942338

81. Melekos MD, Pantazakos A, Daouaher H, Papatsoris G. Primary endourologic re-establishment of urethral continuity after disruption of prostatomembranous urethra. Urology 1992 Feb;39(2):135-8 (level of evidence: 3).
http://www.ncbi.nlm.nih.gov/pubmed/1736505
82. el-Abd SA. Endoscopic treatment of posttraumatic urethral obliteration: experience in 396 patients. J Urol 1995 Jan;153(1):67-71 (level of evidence: 3).
http://www.ncbi.nlm.nih.gov/pubmed/7966794
83. Gheiler EL, Frontera JR. Immediate primary realignment of prostatomembranous urethral disruptions using endourologic techniques. Urology 1997 Apr;49(4):596-9 (level of evidence: 3).
http://www.ncbi.nlm.nih.gov/pubmed/9111631
84. Londergan TA, Gundersen LH, van Every MJ. Early fluoroscopic realignment for traumatic urethral injuries. Urology 1997 Jan;49(1):101-3 (level of evidence: 3).
http://www.ncbi.nlm.nih.gov/pubmed/9000194
85. Elliott DS, Barrett DM. Long-term followup and evaluation of primary realignment of posterior urethral disruptions. J Urol 1997 Mar;157(3):814-6 (level of evidence: 3).
http://www.ncbi.nlm.nih.gov/pubmed/9072573
86. Rehman J, Samadi D, Ricciardi R Jr, Kreutzer E. Early endoscopic realignment as primary therapy for complete posterior urethral disruptions. J Endourol 1998 Jun;12(3):283-9 (level of evidence: 3).
http://www.ncbi.nlm.nih.gov/pubmed/9658304
87. Sahin H, Bircan MK, Akay AF, Göçmen M, Bilici A. Endoscopic treatment of complete posterior urethral obliteration. Acta Urol Belg 1998 Dec;66(4):21-4 (level of evidence: 3).
http://www.ncbi.nlm.nih.gov/pubmed/10083629
88. Tahan H, Randrianantenaina A, Michel F. [Treatment of complete rupture of the posterior urethra by endoscopic realignment.] Prog Urol 1999 Jun;9(3):489-5 (level of evidence: 3). [article n French.]
http://www.ncbi.nlm.nih.gov/pubmed/104343238689.
89. Jepson BR, Boullier JA, Moore RG, Parra RO. Traumatic posterior urethral injury and early primary endoscopic realignment: evaluation of long-term follow-up. Urology 1999 Jun;53(6):1205-10 (level of evidence: 3).
http://www.ncbi.nlm.nih.gov/pubmed/10434323
90. Asci R, Sarikaya S, Büyükalpelli R, Saylik A, Yilmaz AF, Yildiz S. Voiding and sexual dysfunctions after pelvic fracture urethral injuries treated with either initial cystostomy and delayed urethroplasty or immediate primary urethral realignment. Scand J Urol Nephrol 1999 Aug;33(4):228-33 (level of evidence: 3).
http://www.ncbi.nlm.nih.gov/pubmed/10515084
91. Ying-Hao S, Chuan-Liang X, Xu G, Guo-Qiang L, Jian-Guo H. Urethroscopic realignment of ruptured bulbar urethra. J Urol 2000 Nov;164(5):1543-5 (level of evidence: 3).
http://www.ncbi.nlm.nih.gov/pubmed/11025700
92. Moudouni SM, Patard JJ, Manunta A, Guiraud P, Lobel B, Guillé F. Early endoscopic realignment of post-traumatic posterior urethral disruption. Urology 2001 Apr;57(4):628-32 (level of evidence: 3).
http://www.ncbi.nlm.nih.gov/pubmed/11306365
93. Weems WL. Management of genitourinary injuries in patients with pelvic fractures. Ann Surg 1979 Jun;189(6):717-23 (level of evidence: 3).
http://www.ncbi.nlm.nih.gov/pubmed/453943
94. Mark SD, Webster GD. Reconstruction of the failed repair of posterior urethral rupture, in McAninch JW (ed.). Traumatic and reconstructive urology. Philadelphia: WB Saunders, 1996, pp. 439-451 (level of evidence: 4).
95. Webster GD, Ramon J. Repair of pelvic fracture posterior urethral defects using an elaborated perineal approach: experience with 74 cases. J Urol 1991 Apr;145(4):744-8 (level of evidence: 3).
http://www.ncbi.nlm.nih.gov/pubmed/2005693
96. Webster GD, Ramon J, Kreder KJ. Salvage posterior urethroplasty after failed initial repair of pelvic fracture membranous urethral defects. J Urol 1990 Dec;144(6):1370-2 (level of evidence: 3).
http://www.ncbi.nlm.nih.gov/pubmed/2231930
97. MacDiarmid S, Rosario D, Chapple CR. The importance of accurate assessment and conservative management of the open bladder neck in patients with post-pelvic fracture membranous urethral distraction defects. Br J Urol 1995 Jan;75(1):65-7 (level of evidence: 3).
http://www.ncbi.nlm.nih.gov/pubmed/7850300
98. Mundy AR. Results and complications of urethroplasty and its future. Br J Urol 1993 Mar;71(3):322-5 (level of evidence: 3).
http://www.ncbi.nlm.nih.gov/pubmed/8477319

99. Santucci RA, Mario LA, McAninch JW. Anastomotic urethroplasty for bulbar urethral stricture: analysis of 168 patients. J Urol 2002 Apr;167(4):1715-9 (level of evidence: 3).
http://www.ncbi.nlm.nih.gov/pubmed/11912394
100. Zinman LM. The management of traumatic posterior urethral distraction defects. J Urol 1997 Feb; 157(2):511-2 (level of evidence: 4).
http://www.ncbi.nlm.nih.gov/pubmed/8996344
101. Corriere JN Jr, Rudy DC, Benson GS. Voiding and erectile function after delayed one-stage repair of posterior urethral disruption in 50 men with fractured pelvis. J Trauma 1994 Oct;37(4):587-9 (level of evidence: 3).
http://www.ncbi.nlm.nih.gov/pubmed/7932889
102. Flynn BJ, Delvecchio FC, Webster GD. Perineal repair of pelvic fracture urethral distraction defects: experience in 120 patients during the last 10 years. J Urol 2003 Nov;170(5):1877-80 (level of evidence: 3).
http://www.ncbi.nlm.nih.gov/pubmed/14532797
103. Fiala R, Zátura F, Vrtal R. [Personal experience with treatment of posttraumatic urethral distraction defects.] Acta Chir Orthop Traumatol Cech 2001;68(2):99-104 (level of evidence: 3). [article in Czech]
http://www.ncbi.nlm.nih.gov/pubmed/11706724
104. Koraitim MM. The lessons of 145 posttraumatic posterior urethral strictures treated in 17 years. J Urol 1995 Jan;153(1):63-6 (level of evidence: 3).
http://www.ncbi.nlm.nih.gov/pubmed/7966793
105. Podestá ML. Use of the perineal and perineal-abdominal (transpubic) approach for delayed management of pelvic fracture urethral obliterative strictures in children: long-term outcome. J Urol 1998 Jul;160(1):160-4 (level of evidence: 3).
http://www.ncbi.nlm.nih.gov/pubmed/9628640
106. Hafez AT, El-Assmy A, Sarhan O, El-Hefnawy AS, Ghoneim MA. Perineal anastomotic urethroplasty for managing post-traumatic urethral strictures in children: the long-term outcome. BJU Int. 2005 Feb;95(3):403-6 (level of evidence: 3).
http://www.ncbi.nlm.nih.gov/pubmed/15679803
107. Wadhwa SN, Chahal R, Hemal AK, Gupta NP, Dogra PN, Seth A. Management of obliterative posttraumatic posterior urethral strictures after failed initial urethroplasty. J Urol 1998 Jun;159(6): 1898-902 (level of evidence: 3).
http://www.ncbi.nlm.nih.gov/pubmed/9598483
108. Cooperberg MR, McAninch JW, Alsikafi NF, Elliott SP.Urethral reconstruction for traumatic posterior urethral disruption: outcomes of a 25-year experience. J Urol 2007 Nov;178(5):2006-10 (level of evidence: 3).
http://www.ncbi.nlm.nih.gov./pubmed/17869302
109. Sachse H. Zur behandlung der Harnrohrenstriktur: Die transuretrale schlitzung unter Sicht mit scharfem Schinitt. Fortschr Med 1974 Jan;92:12-15 (level of evidence: 3). [article in German]
110. Blandy JP. Urethral stricture. Postgrad Med J 1980 Jun;56(656):383-418 (level of evidence: 4).
http://www.ncbi.nlm.nih.gov/pubmed/6997851
111. Lieberman SF, Barry JM. Retreat from transpubic urethroplasty for obliterated membranous urethral strictures. J Urol 1982 Aug;128(2):379-81 (level of evidence: 3).
http://www.ncbi.nlm.nih.gov/pubmed/7109114
112. Gupta NP, Gill IS. Core-through optical internal urethrotomy in management of impassable traumatic posterior urethral strictures. J Urol 1986 Nov;136(5):1018-21 (level of evidence: 3).
http://www.ncbi.nlm.nih.gov/pubmed/3773060
113. Chiou RK, Gonzalez R, Ortlip S, Fraley EE. Endoscopic treatment of posterior urethral obliteration: long-term followup and comparison with transpubic urethroplasty. J Urol 1988 Sep;140(3):508-11 (level of evidence: 3).
http://www.ncbi.nlm.nih.gov/pubmed/3411662
114. Marshall FF. Endoscopic reconstruction of traumatic urethral transections. Urol Clin North Am 1989 May;16(2):313-8 (level of evidence: 4).
http://www.ncbi.nlm.nih.gov/pubmed/2711549
115. Barry JM. Visual urethrotomy in the management of the obliterated membranous urethra. Urol Clin North Am 1989 May;16(2):319-24 (level of evidence: 4).
http://www.ncbi.nlm.nih.gov/pubmed/2711550
116. deVries CR, Anderson RU. Endoscopic urethroplasty: an improved technique. J Urol 1990 Jun;143(6): 1225-6 (level of evidence: 3).
http://www.ncbi.nlm.nih.gov/pubmed/2342187

117. Leonard MP, Emtage J, Perez R, Morales A. Endoscopic management of urethral stricture: 'cut to the light' procedure. Urology 1990 Feb;35(2):117-20 (level of evidence: 3). http://www.ncbi.nlm.nih.gov/pubmed/2305533
118. Kernohan RM, Anwar KK, Johnston SR. Complete urethral stricture of the membranous urethra: a different perspective. Br J Urol 1990 Jan;65(1):51-4 (level of evidence: 3). http://www.ncbi.nlm.nih.gov/pubmed/2310932
119. Yasuda T, Yamanishi T, Isaka S, Okano T, Masai M, Shimazaki J. Endoscopic re-establishment of membranous urethral disruption. J Urol 1991 May;145(5):977-9 (level of evidence: 3). http://www.ncbi.nlm.nih.gov/pubmed/2016813
120. Quint HJ, Stanisic TH. Above and below delayed endoscopic treatment of traumatic posterior urethral disruptions. J Urol 1993 Mar;149(3):484-7 (level of evidence: 3). http://www.ncbi.nlm.nih.gov/pubmed/8437251
121. Goel MC, Kumar M, Kapoor R. Endoscopic management of traumatic posterior urethral stricture: early results and followup. J Urol 1997 Jan;157(1):95-7 (level of evidence: 3). http://www.ncbi.nlm.nih.gov/pubmed/8976224
122. Levine J, Wessells H. Comparison of open and endoscopic treatment of posttraumatic posterior urethral strictures. World J Surg 2001 Dec;25(12):1597-601 (level of evidence: 2b). http://www.ncbi.nlm.nih.gov/pubmed/11775198
123. Dogra PN, Nabi G. Core-through urethrotomy using the neodynium: YAG laser for obliterative urethral strictures after traumatic urethral disruption and/or distraction defects: long-term outcome. J Urol 2002 Feb;167(2Pt1):543-6 (level of evidence: 3). http://www.ncbi.nlm.nih.gov/pubmed/11792915
124. Pansadoro V, Emiliozzi P. Internal urethrotomy in the management of anterior urethral strictures: longterm followup. J Urol 1996 Jul;156(1):73-5 (level of evidence: 3). http://www.ncbi.nlm.nih.gov/pubmed/8648841
125. Williams G. Stents in the lower urinary tract. Am Urol Assoc Update Ser 1993;12:26.
126. Milroy EJ, Chapple C, Eldin A, Wallsten N. A new treatment for urethral strictures: a permanently implanted urethral stent. J Urol 1989 May;141(5):1120-2 (level of evidence: 3). http://www.ncbi.nlm.nih.gov/pubmed/2709498
127. Baert L, Verhamme L, Van Poppel H, Vandeursen H, Baert J. Long-term consequences of urethral stents. J Urol 1993 Sep;150(3):853-5 (level of evidence: 3). http://www.ncbi.nlm.nih.gov/pubmed/8345599
128. Jordan GH, Schlossberg SM. Surgery of the penis and urethra. In: Walsh PC, Retik AB, Vaughan ED Jr., Wein AJ (eds). Campbell's Urology. 8th ed. Philadephia, PA: WB Saunders, 2002; pp. 3886-3952.
129. Fenton AS, Morey AF, Aviles R, Garcia CR. Anterior urethral stricture: etiology and characteristics. Urology 2005 Jun;65(6):1055-8. http://www.ncbi.nlm.nih.gov/pubmed/15913734
130. Buddha S. Complication of urethral catheterisation. Lancet 2005 Mar;365(9462):909. http://www.ncbi.nlm.nih.gov/pubmed/15752537
131. Hammarsten J, Lindqvist K. Suprapubic catheter following transurethral resection of the prostate: a way to decrease the number of urethral strictures and improve the outcome of operations. J Urol 1992 Mar;147(3):648-51. http://www.ncbi.nlm.nih.gov/pubmed/1538447
132. Kashefi C, Messer K, Barden R, Sexton C, Parsons JK. Incidence and prevention of iatrogenic urethral injuries: J Urol 2008 Jun;179(6):2254-7. http://www.ncbi.nlm.nih.gov/pubmed/18423712
133. Vicente J, Rosales A, Montlleó M, Caffaratti J. Value of electrical dispersion as a cause of urethral stenosis after endoscopic surgery. Eur Urol 1992;21(4):280-3. http://www.ncbi.nlm.nih.gov/pubmed/1459149
134. Hammarsten J, Lindqvist K, Sunzel H. Urethral strictures following transurethral resection of the prostate. The role of the catheter. Br J Urol 1989 Apr;63(4):397-400. http://www.ncbi.nlm.nih.gov/pubmed/2713622
135. Elliott SP, Meng MV, Elkin EP, McAninch JW, Duchane J, Carroll PR; CaPSURE investigators. Incidence of urethral stricture after primary treatment for prostate cancer: data from CaPSURE. J Urol 2007 Aug;178(2):529-34. http://www.ncbi.nlm.nih.gov/pubmed/17570425
136. Park R, Martin S, Goldberg JD, Lepor H. Anastomotic strictures following radical prostatectomy: insights into incidence, effectiveness of intervention, effect on continence, and factors predisposing to occurrence. Urology 2001 Apr;57(4):742-6. http://www.ncbi.nlm.nih.gov/pubmed/11306394

137. Msezane LP, Reynolds WS, Gofrit ON, Shalhav AL, Zagaja GP, Zorn KC. Bladder neck contracture after robot-assisted laparoscopic radical prostatectomy: evaluation of incidence and risk factors and impact on urinary function. J Endourol 2008 Jan;22(1):97-104.
http://www.ncbi.nlm.nih.gov/pubmed/18326071
138. Chrouser KL, Leibovich BC, Sweat SD, Larson DW, Davis BJ, Tran NV, Zincke H, Blute ML. Urinary fistulas following external radiation or permanent brachytherapy for the treatment of prostate cancer. J Urol 2005 Jun;173(6):1953-7.
http://www.ncbi.nlm.nih.gov/pubmed/15879789
139. Marguet C, Raj GV, Brashears JH, Anscher MS, Ludwig K, Mouraviev V, Robertson CN, Polascik TJ. Rectourethral fistula after combination radiotherapy for prostate cancer. Urology 2007 May;69(5): 898-901.
http://www.ncbi.nlm.nih.gov/pubmed/17482930
140. Polat O, Gül O, Aksoy Y, Ozbey I, Demirel A, Bayraktar Y. Iatrogenic injuries to ureter, bladder and urethra during abdominal and pelvic operations. Int Urol Nephrol 1997;29(1):13-8.
http://www.ncbi.nlm.nih.gov/pubmed/9203032
141. Hadjizacharia P, Inaba K, Teixeira PG, Kokorowski P, Demetriades D, Best C. Evaluation of immediate endoscopic realignment as a treatment modality for traumatic urethral injuries. J Trauma 2008 Jun; 64(6):1443-9.
http://www.ncbi.nlm.nih.gov/pubmed/18545107
142. Gökalp A, Yildirim I, Aydur E, Göktepe S, Basal S, Yazicioglu K. How to manage acute urethral false passage due to intermittent catheterization in spinal cord injured patients who refused insertion of an indwelling catheter. J Urol 2003 Jan;169(1):203-6.
http://www.ncbi.nlm.nih.gov/pubmed/12478136
143. Maheshwari PN, Shah HN. Immediate endoscopic management of complete iatrogenic anterior urethral injuries: a case series with long-term results. BMC Urol 2005 Nov;5:13.
http://www.ncbi.nlm.nih.gov/pubmed/16281970
144. Pansadoro V, Emiliozzi P. Iatrogenic prostatic urethral strictures: classification and endoscopic treatment. Urology 1999 Apr;53(4):784-9.
http://www.ncbi.nlm.nih.gov/pubmed/10197857

6. GENITAL TRAUMA

6.1 Background

Traumatic injuries to the genitourinary tract are seen in 2-10% of patients admitted to hospitals (1-5). Of these injuries, between one-third and two-thirds of cases are associated with injuries to the external genitalia (1). The incidence of genital trauma is higher in men than in women, not only because of anatomical differences but also due to increased exposure to violence, the performance of aggressive sports and a higher incidence of motor vehicle accidents. In addition, an increase in domestic violence has led to an increase in gunshot and stab wounds over the last several years (6-9). Approximately 35% of all gunshot wounds are affiliated with genital injuries (10).

Genitourinary trauma is seen in all age groups, most frequently in males between 15-40 years. However, 5% of patients are less than 10 years old (10). Genitourinary trauma is commonly caused by blunt injuries (80%) but the risk of associated injuries to neighbouring organs (bladder, urethra, vagina, rectum, bowel) after blunt trauma is higher in females than in males.

Penetrating external genital trauma is seen in about 20% with 40-60% of all penetrating genitourinary lesions involving the external genitalia (11-13).

In men, blunt genital trauma frequently occurs unilaterally. Only 1% present as bilateral scrotal or testicular injuries (10). Penetrating scrotal injuries affect both testes in 30% of cases (10, 14). In both genders, penetrating genital injuries occur with other associated injuries in 70% of patients.

The accurate diagnosis and treatment of patients with penetrating injuries are of utmost importance.

However, it is essential that physicians and nurses treating trauma patients are aware of an increased risk of hepatitis B and/or C infection in this cohort (7). Recently, a 38% infection rate with hepatitis B and/ or C was reported in males with penetrating gunshot or stab wounds to the external genitalia (7). This was significantly higher compared to normal population, and exposes emergency staff to an increased risk.

6.2 Pathophysiology

Proper management of genital trauma requires information about the accident, involved persons, animals,

vehicles and weapons order to estimate the injury and potential risk of associated lesions.

6.2.1 Blunt trauma

In males, a direct blow to the erect penis may cause penile fracture. Usually the penis slips out of the vagina and strikes against the symphysis pubis or perineum. This most frequently (60%) occurs during consensual intercourse (15). Penile fracture is caused by rupture of the cavernosal tunica albuginea, and may be associated with subcutaneous haematoma, and lesions of the corpus spongiosum or urethra in 10-22% (16, 17).

Due to the thickness of the tunica albuginea in the flaccid state (approximately 2 mm), blunt trauma to the flaccid penis does not usually cause tearing of the tunica. In these cases, only subcutaneous haematoma with intact tunica albuginea may be seen.

Blunt trauma to the scrotum can cause testicular dislocation, testicular rupture and/or subcutaneous scrotal haematoma. Traumatic dislocation of the testicle occurs rarely. It is most common in victims of motor vehicle accidents or auto-pedestrian accidents (18-21). Bilateral dislocation of the testes has been reported in up to 25% of cases (21). It can be classified as:

1. Subcutaneous dislocation with epifascial displacement of the testis
2. Internal dislocation; in these cases, the testis is positioned in the superficial external inguinal ring, inguinal canal or abdominal cavity.

Testicular rupture is found in approximately 50% of cases of direct blunt scrotal trauma (22). It may occur under intense, traumatic compression of the testis against the inferior pubic ramus or symphysis, resulting in a rupture of the tunica albuginea of the testis. Wasko and Goldstein estimated that a force of approximately 50 kg is necessary to cause testicular rupture (23).

In females, blunt trauma to the vulva is rarely reported. The incidence of traumatic vulvar haematomas after vaginal deliveries has been reported as 1 in 310 deliveries (24). The frequency in non-obstetric vulvar haematomas is even lower, with only individual cases reported (25). Although blunt trauma to the female external genitals is rarely reported, the presence of vulvar haematoma is closely related to an increased risk of associated vaginal, pelvic or abdominal injuries. Goldman et al. reported that blunt injuries of the vulva and vagina were associated with pelvic trauma in 30%, after consensual intercourse in 25%, sexual assault in 20% and other blunt trauma in 15% (26).

6.2.2 Penetrating trauma

Penetrating trauma to the external genitalia is frequently associated with complex injuries of other organs. In children, penetrating injuries are most frequently seen after straddle-type falls or laceration of genital skin due to falls on sharp objects (10, 27).

Increasing civilian violence has led to a rising incidence of stab and/or gunshot injuries associated with injuries of the genitourinary tract. The extent of injuries associated with guns is related to the calibre and velocity of the missile (8). Handguns or pistols range from 0.22 to 0.45 calibre and produce bullet velocities of 200-300 meters/second (m/s). In addition, “magnum” handguns have larger gunpowder loads, and transmit 20-60% more energy than standard handguns due to the higher velocity of the missile. Injuries by rifles cause even more extensive lesions. Rifles have a calibre ranging from 0.17 to 0.460, with bullet velocities up to 1000 m/s.

Missiles with a velocity of approximately 200-300 m/s are considered “low velocity”. These bullets only induce a ‘permanent cavity’. The energy transmitted to the tissue along the projectile path is much less than in high-velocity missiles, so that tissue destruction in low-velocity guns is less extensive (8). High-velocity missiles (velocity of 800-1000 m/s) have an explosive effect with high-energy transmission to the tissue causing a ‘temporary cavity’ in addition to the permanent cavity. Due to the high-energy released, gaseous tissue vaporization induces extensive damage often associated with life-threatening injuries.

Gunshot wounds are classified as penetrating, perforating or avulsive. Penetrating injuries are caused by low-velocity missiles, with bullets often retained in the tissue and a small, ragged entry wound. Perforating gunshot wounds are frequently seen in low to high-velocity missiles. In these cases, the missile passes through the tissue with a small entry wound, but larger, exit one. Serious injuries are associated with avulsive gunshot wounds caused by high-velocity missiles, with a small entry wound comparable to the calibre but a large tissue defect at the exit wound.

In any penetrating trauma, tetanus vaccination is mandatory and should be given using active (tetanus toxoid booster) and passive immunization (250 IE human tetanus immunoglobulin) if the patient’s last immunization was given more than 5 years ago (28). For current recommendations for tetanus vaccination, see information from the Robert Koch Institute, Germany (http://www.rki.de/INFEKT/INFEKT.HTM).

Although animal bites are common, bites injuring the external genital are rare. Wounds are usually minor, but have a risk of wound infection. The most common bacterial infection by a dog bite is *Pasturella*

Multicida, which accounts for up to 50% of infections (28). Other commonly involved organisms are *Escherichia coli, Streptococcus viridans, Staphylococcus aureus, Eikenella corrodens, Capnocytophaga canimorsus, Veillonella parvula, Bacteroides* and *Fusobacterium spp*. (28-30).

The first choice of antibiotics is penicillin-amoxiclavulanic acid followed by doxycycline, cephalosporine or erythromycine for 10-14days (31–33). After any animal bite, one has to consider the possibility of rabies infection. In cases where rabies is locally present, vaccination must be given to prevent life-threatening infection (34). Besides vaccination, local wound management is an essential part of post-exposure rabies prophylaxis. If rabies infection is suspected, vaccination should be considered in relation to the animal involved, specific nature of the wound and attack (provoked/unprovoked) and the appearance of the animal (aggressive, foam at the mouth). In high risk patients, vaccination with human rabies immunoglobulin and human diploid cell vaccine is recommended (34, 35).

Genital bites from humans can rarely occur, but can also become infected. Wound infections in these cases may include *Streptococci, Staphylococcus aureus, Haemophilus spp., Bacteroides spp*. and other anaerobes. Transmission of viruses (e.g. hepatitis B, hepatitis C, HIV) following human bites is much less common but should be considered especially in risk groups. Since transmission of viral diseases may occur, risk assessment should be made and, if appropriate, hepatitis B vaccine/immunoglobulin and/or HIV post-exposure prophylaxis offered. For further details see Guidelines for the Management of Human Bite Injuries (36).

Wound manangement should include cleaning with warm running water or disinfectants. Debridement should be conservative, due to the regenerative capacity of genital skin (36).Antibiotic therapy may be considered only in cases with infected wounds using amoxiclavulanic acid as first line therapy, or, alternatively clindamycin.

6.3 Risk factors

There are certain sports with an increased risk for genital trauma. Off-road bicycling and motorbike riding, especially on bikes with a dominant petrol tank, accidents from in-line hockey skating and rugby footballers have been associated with blunt testicular trauma (37-40). Any kind of full contact sports, without the use of necessary protective aids, may be associated with genital trauma.

Besides these risk groups, self-mutilation of the external genitalia have also been reported in psychotic patients and transsexuals (29).

6.4 Diagnosis

Investigating genital trauma requires information concerning the accident and a thorough history and physical examination, if possible. Trauma to external genitalia at any age may be due to abusive assault. In these cases, the extraordinary emotional situation of the patient must be considered and the privacy of the patient respected. In suspicious cases, a sexual assault forensic exam is necessary. Swabs or vaginal smears should be taken for detection of spermatozoa (27) and local legal protocols followed closely. A thorough history and examination (in some cases under anaesthesia), photodocumentation, and identification of forensic material may be important. Genital injury is seen frequently (42%) after sexual abuse, and must be considered when such injuries present at any age (41). In a recent report, only 38% of the forensic samples tested positive for an ejaculate and / or sperm. This may be due to delayed presentation or lack of vaginal / anal ejaculation (42-43).

In patients with gunshot wounds to the genitals several pieces of information will be useful: close or far range, calibre and type of weapon. Get a urinalysis. The presence or macro- and or microhaematuria requires a retrograde urethrogram in males (see above Chapter 4, Urethral trauma). In females, flexible or rigid cystoscopy has been recommended to exclude urethral and bladder injury (26, 44). In women with genital injuries and blood at the vaginal introitus, further gynaecologic investigation to exclude vaginal injuries (44). The potential for significant injury should never be discounted in those patients who also may have blood in the vaginal vault from menstruation. Complete vaginal inspection with specula is mandatory. Depending on the nature of the injury, this may require sedation or general anaesthesia to be completed comfortably.

6.4.1 Blunt penile trauma

6.4.1.1 Penile fracture

Penile fracture is associated with a sudden cracking or popping sound, pain and immediate detumescence. Local swelling of the penile shaft develops quickly, due to enlarging haematoma. Bleeding may spread along the fascial layers of the penile shaft and extend to the lower abdominal wall if Buck's fascia is also ruptured. The rupture of the tunica may be palpable if the hematoma is not too large. Physical exam and history usually confirm the diagnosis, but in rare cases imaging may be required.

Cavernosography or magnetic resonance imaging (MRI) (45-47) can identify lacerations of the tunica albuginea in unclear cases (48). In case of tunical laceration, surgical correction with suturing of the ruptured area is indicated.

6.4.2 Blunt testicular trauma

Testicular rupture is associated with immediate pain, nausea, vomiting and sometimes fainting. The hemiscrotum is tender, swollen, and eccymotic. The testis itself may be difficult to palpate. High-resolution, real-time ultrasonography with a high resolution probe (minimum 7.5MHz or higher) should be performed to determine intra- and/or extratesticular haematoma, testicular contusion or rupture (49-57). In children, scrotal ultrasonography must be performed with a 10-12MHz probe.

The literature is contradictory as to the real usefulness of ultrasound over exam alone. Some studies report convincing results with accuracy of 94% (29, 49, 54, 55). Others reported poor specificity (78%) and sensitivity (28%) for differentiation of testicular rupture or haematocele, and accuracy as low as 56% (52).

Colour doppler-duplex ultrasonography may provide useful information when used to evaluate testicular perfusion. In case of inconclusive scrotal sonography, testicular computed tomography (CT) or MRI may be helpful (58). However, these techniques did not specifically increase the detection of testicular rupture. It may be most prudent to surgically explore these equivocal patients. If imaging studies cannot definitively exclude testicular rupture, surgical exploration is indicated.

6.4.3 Blunt female trauma

In females with blunt trauma to the external genitalia, imaging studies of the pelvis with ultrasound, CT or MRI should be performed since additional injuries and extensive intrapelvic haematoma are frequently found (27, 44).

6.4.4 Penetrating trauma

In penetrating trauma of the external genital in men, urethrography should be performed in all patients (irrespective of urinalysis). Associated pelvic or abdominal trauma may also require an abdominal CT. CT cystography should be performed in pelvic injuries associate with microhaematuria. In females, the use of diagnostic laparoscopy for identification of intraperitoneal injuries has been reported prior to explorative laparotomy (27). This approach is only reasonable in haemodynamic stable patients, in whom CT cannot exclude presence of associated bowel injuries or significant intra-abdominal bleeding.

6.5 Treatment

6.5.1 Penile trauma

6.5.1.1 Blunt trauma

Subcutaneous haematoma, without associated rupture of the cavernosal tunica albuginea does not require surgical intervention. In these cases, nonsteroidal analgesics and ice-packs are recommended (13).

Benign penile injuries can be distinguished from penile fracture, because fracture is always associated with with rapid post-traumatic detumescence. In penile fracture, surgical intervention with closure of the tunica albuginea is recommended. Closure can be obtained by using either absorbable or non-absorbable sutures, with good long-term outcome and protection of potency. Post-operative complications were reported in 9%, including superficial wound infection and impotence in 1.3% (15, 59). Conservative management of penile fracture is not recommended. It increases complications such as penile abscess, missed urethral disruption, penile curvature and persistent haematoma requiring delayed surgical intervention (59). Late complications after conservative management were fibrosis and angulations in 35% and impotence in up to 62% (15, 59).

6.5.1.2 Penetrating trauma

In penetrating penile trauma, surgical exploration and conservative debridement of necrotic tissue is recommended in most severe injuries. Non-operative management is recommended in small superficial injuries with intact Buck's fascia (13). Even in extended injuries of the penis, primary alignment of the disrupted tissues may allow for acceptable healing because of the robust penile blood supply (29). In extended loss of penile shaft skin, split-thickness grafts can be placed, either acutely or after the wound bed has been prepared by several days of wet/dry dressing changes and infection is under control. McAninch et al. recommended the use of a skin graft thickness of at least 0.015 inch in order to reduce the risk of contraction (29).

6.5.2 Testicular trauma

6.5.2.1 Blunt trauma

Blunt trauma to the scrotum can cause significant haematocele even without testicular rupture. Conservative management is recommended in haematoceles smaller than three times the size of the contralateral testis (6).

In large haematoceles, non-operative management often fails, and often requires delayed surgery (> 3 days). These patients suffer from a higher rate of orchiectomy than acutely-operated patients, even in non-ruptured testis (10, 22, 29, 60, 61).

Early surgical intervention resulted in > 90% preservation of the testis whereas delayed surgery necessitates orchiectomy in 45-55% (22). Additionally, non-operative management is associated with

prolonged hospital stays. Large hematocoles should be treated surgically, irrespective of testicle contusion or rupture. At the very least, the blood-clot should be evacuated from the tunica vaginalis sac to relieve disability and hasten recovery. Patients initially treated nonoperatively may need delayed surgery if they develop infection or undue pain.

In testicular rupture, surgical exploration with excision of necrotic testicular tubules and closure of the tunica albuginea is indicated. This results in a high rate of testicular preservation and normal endocrine function. Traumatic dislocation of the testis is treated by manual replacement and secondary orchidopexy. If primary manual reposition cannot be performed, immediate orchidopexy is indicated.

6.5.2.2 Penetrating trauma

Penetrating injuries to the scrotum require surgical exploration with conservative debridement of non-viable tissue. Depending on the extent of the injury, primary reconstruction of testis and scrotum can be performed in most cases. In complete disruption of the spermatic cord, realignment without vaso-vasostomy may be considered if surgically feasible (62). Staged secondary microsurgical vaso-vasostomy can be performed after rehabilitation, although there are only a few cases reported (62). If there is extensive destruction of the tunica albuginea, mobilization of a free tunica vaginalis flap can be performed for testicular closure. If the patient is unstable or reconstruction cannot be achieved, orchiectomy is indicated.

Prophylactic antibiotics are recommended by experts after scrotal penetrating trauma, although data to support this approach is lacking. Tetanus prophylaxis is mandatory. Postoperative complications were reported in 8% of patients who underwent testicular repair after penetrating trauma (13).

Extended laceration of scrotal skin requires surgical intervention for skin closure. Due to the elasticity of the scrotum, most defects can be primarily closed, even if the lacerated skin is only minimally attached to scrotum (29). Local wound management with extensive initial wound debridement and washout is important for scrotal convalescence.

6.5.3 Vulvar injuries

Blunt trauma to the vulva is rare and commonly present as a large haematoma. However, in contrast to men, blunt vulvar or perineal trauma may be associated with voiding problems. Bladder catheterization will usually be required. Vulvar haematomas usually do not require surgical intervention, although they can cause significant blood loss, even requiring red blood cell transfusions. Data are scarce (25-27, 44), but in haemodynamically stable women, non-steroidal anti-inflammatory medication and cold packs are used. In massive vulvar haematoma or haemodynamically unstable patients, surgical intervention, lavage and drainage is indicated (63).

Antibiotics are recommended by experts after major vulvar trauma, but data supporting this approach are lacking. It is important to emphasize that vulvar haematoma and/or blood at the vaginal introitus are an indication for vaginal exploration under sedation or general anaesthesia in order to identify possible associated vaginal and/or rectal injuries (44). In case of vulvar laceration, suturing after conservative debridement is indicated. If there are associated injuries to the vagina, these can be repaired immediately by primary suturing. Additional injuries to the bladder, rectum or bowel may require laparotomy for closure. The rectal injuries may also require colostomy.

6.6 REFERENCES

1. Brandes SB, Buckman RF, Chelsky MJ, Hanno PM. External genitalia gunshot wounds: a ten-year experience with fifty-six cases. J Trauma 1995 Aug;39(2):266-71. http://www.ncbi.nlm.nih.gov/pubmed/7674395
2. Marekovic Z, Derezic D, Krhen I, Kastelan Z. Urogenital war injuries. Mil Med 1997 May;162(5):346-8. http://www.ncbi.nlm.nih.gov/pubmed/9155106
3. Salvatierra O Jr, Rigdon WO, Norris DM, Brady TW. Vietnam experience with 252 urological war injuries. J Urol 1969 Apr;101(4):615-20. http://www.ncbi.nlm.nih.gov/pubmed/5776049
4. Tucak A, Lukacevic T, Kuvezdic H, Petek Z, Novak R. Urogenital wounds during the war in Croatia in 1991/1992. J Urol 1995 Jan;153(1):121-2. http://www.ncbi.nlm.nih.gov/pubmed/7966742
5. Archbold JA, Barros d'sa AA, Morrison E. Genito-urinary tract injuries of civil hostilities. Br J Surg 1981 Sep;68(9):625-31. http://www.ncbi.nlm.nih.gov/pubmed/7272689
6. Tiguert R, Harb JF, Hurley PM, Gomes De Oliveira J, Castillo-Frontera RJ, Triest JA, Gheiler EL. Management of shotgun injuries to the pelvis and lower genitourinary system. Urology 2000 Feb;55(2): 193-7. http://www.ncbi.nlm.nih.gov/pubmed/10688077

7. Cline KJ, Mata JA, Venable DD, Eastham JA. Penetrating trauma to the male external genitalia. J Trauma 1998 May;44(3):492-4 .
http://www.ncbi.nlm.nih.gov/pubmed/9529176
8. Jolly BB, Sharma SK, Vaidyanathan S, Mandal AK. Gunshot wounds of the male external genitalia. Urol Int 1994;53(2):92-6.
http://www.ncbi.nlm.nih.gov/pubmed/7801424
9. Bertini JE Jr, Corriere JN Jr. The etiology and management of genital injuries. J Trauma 1988 Aug;28(8):1278-81.
http://www.ncbi.nlm.nih.gov/pubmed/3411650
10. Monga M, Hellstrom WJ. Testicular Trauma. Adolesc Med 1996 Feb;7(1):141-148.
http://www.ncbi.nlm.nih.gov/pubmed/10359963
11. Selikowitz SM. Pentrating high-velocity genitourinary injuries. Part I. Statistics mechanism and renal wounds. Urology 1977 Apr;9(4):371-6.
http://www.ncbi.nlm.nih.gov/pubmed/855062
12. Brandes SB, Buckmann RF, Chelsky MJ, Hanno PM. External genitalia gunshot wounds: a ten year experience with fifty-six cases. J Trauma 1995 Aug;39(2):266-71.
http://www.ncbi.nlm.nih.gov/pubmed/7674395
13. Phonsombat S, Master VA, McAninch JW: Penetrating external genitalia trauma: a 30-year single institution experience. J Urology 2008 Jul;180(1):192-5.
http://www.ncbi.nlm.nih.gov/pubmed/18499189
14. Cass AS, Ferrara L, Wolpert J, Lee J. Bilateral testicular injury from external trauma. J Urol 1988 Dec;140(6):1435-6.
http://www.ncbi.nlm.nih.gov/pubmed/3193512
15. Haas CA, Brown SL, Spirnak JP. Penile fracture and testicular rupture. World J Urol 1999 Apr;17(2): 101-6.
http://www.ncbi.nlm.nih.gov/pubmed/10367369
16. Nicolaisen GS, Melamud A, Williams RD, McAninch JW. Rupture of the corpus cavernosum: surgical management. J Urol 1983 Nov;130(5):917-9.
http://www.ncbi.nlm.nih.gov/pubmed/6632099
17. Tsang T, Demby AM. Penile fracture with urethral injury. J Urol 1992 Feb;147(2):466-8.
http://www.ncbi.nlm.nih.gov/pubmed/1732623
18. Lee JY, Cass AS, Streitz JM. Traumatic dislocation of testes and bladder rupture. Urology 1992 Dec;40(6):506-8.
http://www.ncbi.nlm.nih.gov/pubmed/1466102
19. Shefi S, Mor Y, Dotan ZA, Ramon J. Traumatic testicular dislocation: a case report and review of published reports. Urology 1999 Oct;54(4):744.
http://www.ncbi.nlm.nih.gov/pubmed/10754145
20. Pollen JJ, Funckes C. Traumatic dislocation of the testes. J Trauma 1982 Mar;22(3):247-9.
http://www.ncbi.nlm.nih.gov/pubmed/7069812
21. Nagarajan VP, Pranikoff K, Imahori SC, Rabinowitz R. Traumatic dislocation of testis. Urology 1983 Nov;22(5):521-4.
http://www.ncbi.nlm.nih.gov/pubmed/6649208
22. Cass AS, Luxenberg M. Testicular injuries. Urology 1991 Jun;37(6):528-30.
http://www.ncbi.nlm.nih.gov/pubmed/2038785
23. Wasko R, Goldstein AG. Traumatic rupture of the testicle. J Urol 1966 May;95(5):721-3.
http://www.ncbi.nlm.nih.gov/pubmed/5935538
24. Sotto LS, Collins RJ. Perigenital Hematomas; analysis of forty-seven consecutive cases. Obstet Gynecol 1958 Sep;13:259-63.
http://www.ncbi.nlm.nih.gov/pubmed/13578292
25. Propst AM, Thorp JM Jr. Traumatic vulvar hematomas: conservative versus surgical management. South Med J 1998 Feb;91(2):144-6.
http://www.ncbi.nlm.nih.gov/pubmed/9496865
26. Goldman HB, Idom CB Jr, Dmochowski RR. Traumatic injuries of the female external genitalia and their association with urological injuries. J Urol 1998 Mar;159(3):956-9.
http://www.ncbi.nlm.nih.gov/pubmed/9474191
27. Okur H, Küçïkaydin M, Kazez A, Turan C, Bozkurt A. Genitourinary tract injuries in girls. Br J Urol 1996 Sep;78(3):446-9.
http://www.ncbi.nlm.nih.gov/pubmed/8881959
28. Donovan JF, Kaplan WE. The therapy of genital trauma by dog bite. J Urol 1989 May;141(5):1163-5.
http://www.ncbi.nlm.nih.gov/pubmed/2651716

29. McAninch JW, Kahn RI, Jeffrey RB, Laing FC, Krieger MJ. Major traumatic and septic genital injuries. J Trauma 1984 Apr;24(4):291-8.
http://www.ncbi.nlm.nih.gov/pubmed/6368854
30. Presutti RJ: Prevention and treatment of dog bites. Am Fam Physician 2001 Apr; 63(8):1567-72.
http://www.ncbi.nlm.nih.gov/pubmed/11327433
31. Lewis KT, Stiles M. Management of cat and dog bites. Am Fam Physician 1995 Aug;52(2):479-85, 489-90.
http://www.ncbi.nlm.nih.gov/pubmed/7625323
32. Presutti RJ. Bite wounds. Early treatment and prophylaxis against infectious complications. Postgrad Med 1997 Apr;101(4):243-4, 246-52, 254.
http://www.ncbi.nlm.nih.gov/pubmed/9126216
33. Talan DA, Citron DM, Abrahamian FM, Moran GJ, Goldstein EJ. Bacteriologic analysis of infected dog and cat bites. Emergency Medicine Animal Bite Infection Study Group. N Engl J Med 1999 Jan;340(2): 85-92.
http://www.ncbi.nlm.nih.gov/pubmed/9887159
34. Dreesen DW, Hanlon CA. Current recommendations for the prophylaxis and treatment of rabies. Drugs 1998 Nov;56(5):801-9.
http://www.ncbi.nlm.nih.gov/pubmed/9829154
35. Anderson CR. Animal bites. Guidelines to current management. Postgrad Med 1992 Jul;92(1):134-6, 139-46,149.
http://www.ncbi.nlm.nih.gov/pubmed/1614928
36. Guidelines for the Management of Human Bite Injuries. Health Protection Agency North West 2007.
http://www.hpa.org.uk/web/HPAwebFile/HPAweb_C/1194947350692
37. Frauscher F, Klauser A, Stenzl A, Helweg G, Amort B, zur Nedden D. US findings in the scrotum of extreme mountain bikers. Radiology 2001 May;219(2):427-31.
http://www.ncbi.nlm.nih.gov/pubmed/11323467
38. de Peretti F, Cambas PM, Veneau B, Argenson C. [Fuel tanks of motorcycles. Role in severe trauma of the pelvis.] Presse Med 1993 Jan;22(2):61-3. [article in French]
http://www.ncbi.nlm.nih.gov/pubmed/8493205
39. Herrmann B, Crawford J. Genital injuries in prepubertal girls from inline skating accidents. Pediatrics 2002 Aug;110(2 Pt 1):e16.
http://www.ncbi.nlm.nih.gov/pubmed/12165615
40. Lawson JS, Rotem T, Wilson SF. Catastrophic injuries to the eyes and testicles in footballers. Med J Aust 1995 Sep;163(5):242-4.
http://www.ncbi.nlm.nih.gov/pubmed/7565208
41. McGregor MJ, Du Mont J, Myhr TL. Sexual assault forensic medical examination: is evidence related to successful prosecution? Ann Emerg Med 2002 Jun;39(6):639-47.
http://www.ncbi.nlm.nih.gov/pubmed/12023707
42. Dardamissis E, Gee A, Kaczmarski E, Kempster J, Lighton L, Mutton K, Philp R, Scott J, Wood T on behalf of the North West Policy Group. Guidance for healthcare professionals on dealing with injuries where teeth break the skin. Health Care Protection Agency, October 2007.
http://www.hpa.org.uk/web/HPAwebFile/HPAweb_C/1194947350692
43. A national protocol for sexual assault medical forensic examinations adults/adolescents. U.S. Dept of Justice. Office on Violence Against Women, September 2004.
http://www.ncjrs.gov/pdffiles1/ovw/206554.pdf
44. Husmann DA. Editorial Comment. J Urol 1998;159:959.
45. Karadeniz T, Topsakal M, Ariman A, Erton H, Basak D. Penile fracture: differential diagnosis, management and outcome. Br J Urol 1996 Feb;77(2):279-81.
http://www.ncbi.nlm.nih.gov/pubmed/8800899
46. Pretorius ES, Siegelman ES, Ramchandani P, Banner MP. MR imaging of the penis. Radiographics 2001 Oct;21 Spec No:S283-98, discussion S298-9.
http://www.ncbi.nlm.nih.gov/pubmed/11598264
47. Fedel M, Venz S, Andreessen R, Sudhoff F, Loening SA. The value of magnetic resonance imaging in the diagnosis of suspected penile fracture with atypical clinical findings. J Urol 1996 Jun;155(6): 1924-7.
http://www.ncbi.nlm.nih.gov/pubmed/8618289
48. Uder M, Gohl D, Takahashi M, Derouet H, Defreyne L, Kramann B, Schneider G. MRI of penile fracture: diagnosis and therapeutic follow-up. Eur Radiol 2002 Jan;12(1):113-20.
http://www.ncbi.nlm.nih.gov/pubmed/11868085

49. Pavlica P, Barozzi L. Imaging of the acute scrotum. Eur Radiol 2001;11(2):220-8.
http://www.ncbi.nlm.nih.gov/pubmed/11218018
50. Micallef M, Ahmad I, Ramesh N, Hurley M, McInerney D. Ultrasound features of blunt testicular injury. Injury 2001 Jan;32(1):23-6.
http://www.ncbi.nlm.nih.gov/pubmed/11164397
51. Patil MG, Onuora VC. The value of ultrasound in the evaluation of patients with blunt scrotal trauma. Injury 1994 Apr;25(3):177-8.
http://www.ncbi.nlm.nih.gov/pubmed/8168890
52. Corrales JG, Corbel L, Cipolla B, Staerman F, Darnault P, Guille F, Lobel B. Accuracy of ultrasound diagnosis after blunt testicular trauma. J Urol 1993 Dec;150(6):1834-6.
http://www.ncbi.nlm.nih.gov/pubmed/8080482
53. Mulhall JP, Gabram SG, Jacobs LM. Emergency management of blunt testicular trauma. Acad Emerg Med 1995 Jul;2(7):639-43.
http://www.ncbi.nlm.nih.gov/pubmed/8521212
54. Martinez-Piñeiro L Jr, Cerezo E, Cozar JM, Avellana JA, Moreno JA, Martinez-Piñeiro JA. Value of testicular ultrasound in the evaluation of blunt scrotal trauma without haematocele. Br J Urol 1992 Mar;69(3):286-90.
http://www.ncbi.nlm.nih.gov/pubmed/1568102
55. Fournier GR Jr, Laing FC, McAninch JW. Scrotal ultrasonography and the management of testicular trauma. Urol Clin North Am 1989 May;16(2):377-85.
http://www.ncbi.nlm.nih.gov/pubmed/2652862
56. Kratzik C, Hainz A, Kuber W, Donner G, Lunglmayr G, Frick J, Schmoller HJ. Has ultrasound influenced the therapy concept of blunt scrotal trauma? J Urol 1989 Nov;142(5):1243-6.
http://www.ncbi.nlm.nih.gov/pubmed/2681835
57. Andipa E, Liberopoulos K, Asvestis C. Magnetic resonance imaging and ultrasound evaluation of penile and testicular masses. World J Urol 2004 Nov;22(5):382-91.
http://www.ncbi.nlm.nih.gov/pubmed/15300391
58. Muglia V, Tucci S Jr, Elias J Jr, Trad CS, Bilbey J, Cooperberg PL. Magnetic resonance imaging of scrotal diseases: when it makes the difference. Urology 2002 Mar;59(3):419-23.
http://www.ncbi.nlm.nih.gov/pubmed/11880084
59. Orvis BR, McAninch JW. Penile rupture. Urol Clin North Am 1989 May;16(2):369-75.
http://www.ncbi.nlm.nih.gov/pubmed/2652861
60. Altarac S. Management of 53 cases of testicular trauma. Eur Urol 1994;25(2):119-23.
http://www.ncbi.nlm.nih.gov/pubmed/8137851
61. Cass AS, Luxenberg M. Value of early operation in blunt testicular contusion with hematocele. J Urol 1988 Apr;139(4):746-7.
http://www.ncbi.nlm.nih.gov/pubmed/3352037
62. Altarac S. A case of testicle replantation. J Urol 1993 Nov;150(5 Pt 1):1507-8.
http://www.ncbi.nlm.nih.gov/pubmed/8411440
63. Virgili A, Bianchi A, Mollica G, Corazza M. Serious hematoma of the vulva from a bicycle accident. A case report. J Reprod Med 2000 Aug;45(8):662-4.
http://www.ncbi.nlm.nih.gov/pubmed/10986686

7. MASS CASUALTY EVENTS, TRIAGE AND DAMAGE CONTROL

7.1 Definition

A mass casualty event is one in which the number of injured people is significantly higher than the number of healthcare providers available (1). A mass casualty disaster does not therefore necessarily involve a large number of victims, but is related to the disproportion between the number of victims and the size of the medical team available (2, 3). There is little published data on how best to handle these events.

7.2 Causes of mass casualty events

Potential mass casualty events include:

- The collapse of buildings or bridges
- earthquakes

- floods
- tsunamis
- train collisions
- aircraft catastrophes
- civilian terrorism.

Most mass injury caused by civilian terrorism is caused by explosions. The combined effects of blast, shrapnel, bomb projectiles and burns result in multiple penetrating injuries involving several body systems and unpredictable degrees of damage.

7.3 Mechanisms of explosive injury

The mechanism of injury in explosions is divided into three phases:

- **Primary blast injury:** this is caused by the powerful shock wave that spreads from the site of the explosion. The most commonly injured organs are those containing air (lungs and ears), but any tissue can be damaged by the pressure wave passing through the body. Urogenital injuries as a direct result of primary blast have not been described in survivors of blast injuries.
- **Secondary blast injury:** this is produced by the debris and projectiles set in motion by the explosion. Penetrating injuries to the urogenital system, as to any organ, have been described.
- **Tertiary injury:** this occurs when the victim displaced by the blast wave hits a fixed object. An acceleration-deceleration mechanism produces severe injuries to organs, large blood vessels and bones. Blunt renal, ureteral and bladder injuries are induced by this mechanism.

The patterns and severity of injury after explosions differ according to the location of the event. Explosions in confined spaces (e.g. buildings or buses) are more devastating than those that occur in open spaces because of amplification of the blast wave by reflection, and structural collapse, which can cause further injury.

7.4 Triage

Triage after mass casualty events is difficult, controversial, and full of difficult ethical and moral questions. Disaster triage requires one to differentiate the few critically injured that can be saved by immediate intervention from the many with non-life-threatening injuries for whom treatment can be delayed.

Triage divides patients into four groups (4, 5):

1. Patients with life-threatening injuries that require immediate intervention, presenting with **A**irway compromise, **B**reathing failure and/or **C**irculatory compromise from ongoing external haemorrhage.
2. Patients with severe but non-life-threatening injuries, in whom treatment can be acceptably delayed: major fractures, vascular injuries of the limbs and large soft tissue wounds.
3. 'Walking wounded' with minimal injuries.
4. Patients who are so severely injured that treatment would require allocation of resources and time that would deny other, more salvageable patients, timely care. These patients are given minimal or no treatment, and re-evaluated when resources become available. There is no absolute definition for this group because triage is individualised according to the number and severity of casualties related to the available resources.

Triage contradicts the everyday principles of care, in which the goal is maximal and optimal care for every individual patient. Triage is necessary in mass casualty scenarios because of the need to provide effective treatment to the maximum number of salvageable patients within the limited resources.

7.4.1 Primary triage

Primary triage begins when trained medical teams arrive at the event. It is concerned with the initial stabilisation and rapid evacuation of the prioritised victims to the nearest hospital.

7.4.2 Secondary triage

Secondary triage begins at the medical facility that is receiving the mass casualties. The most experienced trauma surgeon who is not taking part in surgical or resuscitation procedures performs triage.

7.4.3 Re-triage

Re-triage is performed frequently. After all the victims have undergone triage, the senior surgeon repeats triage and reclassifies patients as necessary.

Repeat triage is important. It avoids under-triage, which results in serious injury being missed, or over-triage, which results in some patients being assigned for immediate care when in fact they do not have critical injuries.

The surgeon in charge is responsible for directing specialty surgical consultants, including urologists, and assigning them responsibility for specific patients as dictated by the specific injuries.

7.5 Principles of 'damage control'

Damage control is a prioritised three-phase approach to patients with major injuries (6). The first phase consists of rapid control of haemorrhage, wound contamination, and faecal spillage using simple measures and temporary abdominal closure. The second phase is resuscitation in the intensive care unit (ICU), with the goal of restoring normal temperature, coagulation, perfusion and oxygenation of tissues. Then, in the third stage, definitive surgery and abdominal wall closure is performed in stable patients.

Damage control is a life-saving strategy for patients with multiple injuries that has been adopted by trauma surgeons as a result of the observation that such patients often die from hypothermia, coagulopathy, and acidosis-induced physiological insults (7, 8, 9). In unstable patients, extensive and time-consuming reconstructive procedures could further destabilise the patient beyond recovery.

Identifying those critically injured patients who are candidates for damage control is difficult. The most senior trauma surgeon should make the decisions, in co-operation with other specialist surgeons.

Damage control principles have also been successfully adopted in the context of civilian mass casualty events, military field surgery, and initial treatment in rural areas with long-range transfers (9, 10).

7.6 Urological aspects of 'damage control'

In events involving mass casualties, the principles of triage and damage control are the same. Damage control can theoretically lower the mortality rates by allowing a limited number of qualified personnel to treat more patients.

Urologists are frequently consulted in patients with multiple injuries, and should be familiar with the damage control approach. Damage control is well suited to urological trauma, and should result in more efficient interaction with the trauma team, improved patient survival and lower morbidity.

In fact, because urological surgery is often elective, management of urological trauma has traditionally consisted of temporary measures followed by definitive surgery later on, which meshes well with modern damage control principles (8). It is important to be aware of damage control opportunities, and to maximise the quality of care with creative improvisation.

7.6.1 The urological consultation in the emergency room during mass casualty events

7.6.1.1 Responsibility and primary overall assessment

After primary assessment and triage by the surgeon in charge, a urological consultation might be required for patients triaged to groups 2 (severe but not immediately life-threatening injuries) and 3 ('walking wounded' with mild injuries). The urologist might even become primarily responsible for these patients if they are stable and have few other injuries.

It is important to remember that under-triage can happen during a mass casualty event. A complete re-assessment of the patient assigned must therefore be performed, paying attention to the whole body so as to detect previously unnoticed injuries. This assessment should be quick but comprehensive. Conduct a rapid ABCDE survey (**A**irway, **B**reathing, **C**irculation, **D**isability or neurological status, **E**xposure) as dictated by advanced trauma life support (ATLS) principles (3). Urological care should begin only after the patient is cleared for the presence of other injuries.

7.6.1.2 Imaging

Evaluation of patients with penetrating and blunt abdominal or pelvic trauma usually includes imaging procedures such as contrast computed tomography (CT) scans or retrograde cystourethrography (11, 12). However, when mass casualty protocols are instituted, decisions on care must be made with a minimum of imaging procedures. In those situations, create a unidirectional flow of patients in order to avoid the bottleneck that usually occurs in imaging departments. The 'normal' pattern of sending patients for imaging and then returning them to the accident and emergency department for re-evaluation may not be feasible.

7.6.1.3 Primary management

Following initial primary evaluation, there are several possible scenarios:

1. Haemodynamically unstable patients with suspected intra-abdominal bleeding are transferred urgently to the operating theatre without any pre-operative imaging.
2. Stable patients with suspected renal injuries (penetrating trauma to the upper abdomen/flanks/ lower chest, blunt abdominal trauma and gross haematuria) should have delayed imaging once the protocols of mass casualties are cancelled, or when resources become available. These patients should be transferred to surgical wards and re-evaluated by the urologist as soon as possible.
3. Patients with suspected bladder or urethral injuries (pelvic fractures, high riding prostate on rectal examination, blood at the urethral meatus and/or inability to void) need to undergo imaging of the lower urinary tract, but this is not urgent as these injures are not considered life-threatening (13).
4. In cases of suspected urethral injuries, the 'minimal acceptable treatment' will be one gentle trial of catheterising the bladder or insertion of a suprapubic cystostomy, followed by transfer of the patient to the surgical ward for later evaluation (14).
5. Bladder injuries following blunt or penetrating trauma are usually associated with other severe injuries (15) and thus require a prioritising surgical approach. The first priority in this scenario is the treatment of the associated life-threatening injuries. Bladder drainage is a sufficient first measure, but should be followed by delayed evaluation aiming to obtain accurate diagnosis and to distinguish between intraperitoneal and extraperitoneal bladder rupture.
6. Blunt injuries of the external genitalia are often isolated and can be managed conservatively. On the other hand, penetrating injuries of the genitalia are often associated with injuries of adjacent abdominal organs and haemodynamic instability (7). In mass casualty scenarios, external genital injuries should be operated on only if they have resulted in major haemorrhage. Surgery can be performed in the operating theatre or in a well-equipped shock room in the accident and emergency department. Compression dressings, or clamping/ligation of bleeding vessels are highly efficient manoeuvres that require a minimum of time. When severe haemorrhage is not present, any further diagnostic steps can be postponed. The patient can be transferred to the surgical ward for later re-evaluation followed by delayed reconstruction.

Urological consultations during a mass casualty scenario should be performed according to the following principles:

1. Rule out under-triage by the surgeon in charge, and perform a rapid primary survey of every patient.
2. Avoid unnecessary imaging procedures such as CT scans and retrograde urethrography. These procedures should be performed later, after re-evaluation of the patient, and after mass casualty protocols have been suspended.
3. Treat unstable patients who are to have surgery using damage control principles.
4. Stable patients with suspected renal injuries should be transferred to the surgical ward without imaging procedures. Re-evaluate if there is any change in their haemodynamic status, or when possible as dictated by the constraints of the mass casualty event. Patients managed in this delayed fashion should be treated according to traditional trauma management protocols.
5. 'Minimal acceptable' procedures should be performed in order to transfer patients to the surgical wards, e.g. suprapubic drainage of the bladder when bladder or urethral injuries are suspected, clamping and ligation of bleeding vessels from wounds to the external genitalia, etc.

7.6.2 The urological consultation in the operating room during mass casualty events

During emergency laparotomy, urologists are usually present in the operating theatre along with the general surgeons.

During mass casualty events, the principle of 'minimum acceptable intervention' for the 'maximum salvageable outcome' applies. Procedures should be directed at the rapid control of active bleeding, and management of urinary extravasation by simple diversion measures. Complex and time-consuming reconstructive procedures should be delayed whenever possible.

7.6.2.1 Renal trauma

The ultimate goal of all renal exploration in the setting of major traumatic renal injury is to control life-threatening bleeding and to preserve the maximal amount of viable renal parenchyma (16).

Renal reconstruction might be too time-consuming in the context of an unstable, multiply injured patient, or in the scenario of mass casualties in which the operating theatre should not be occupied by time-consuming reconstructive procedures (17).

Whenever major active haemorrhage of renal origin can be ruled out, it is best not to explore the injured kidney,

even if a secondary delayed laparotomy will eventually be needed (18).

In unstable patients, packing the renal fossa with laparotomy pads and transferring the patient to the surgical ICU is best. Later, a planned second-look laparotomy is better than time-consuming reconstruction (19). Alternatively, especially in briskly bleeding patients, speedy nephrectomy may be required.

Haemostatic techniques, many of which were developed for hepatic surgery and splenic trauma, can be used to control renal parenchymal bleeding (20):

- mattress sutures through the parenchyma (renorrhaphy), similar to the sutures used in extensive hepatorrhaphy (7)
- packing with dry folded laparotomy pads as described for peri-hepatic tamponade (7)
- Fibrin hemostatic agents, may be used to control bleeding.
- absorbable mesh kidney bags maintain renal parenchymal fragments in contact with each other and ensure lasting haemostasis (21)
- urinary extravasation may be ignored during the acute phase; acutely, urine leak will be drained by intraoperatively placed drains; defer ureteral stents or percutaneous nephrostomies
- the abdomen is temporarily closed with towel clips or other measures.

Following urgent primary exploration, patients should be carefully monitored in an ICU. When they are sufficiently stable, begin radiological assessment of their injuries and plan their definitive operative management accordingly.

Delayed imaging is obtained by CT scan. If the extent of renal injury has not been clearly defined at the initial laparotomy (by choosing not to explore the retroperitoneal haematoma), a CT scan performed before the second laparotomy can help in decision-making. CT allows the existence and function of the contralateral kidney to be documented, the kidney injury to be graded according to traditional protocols, and a clinical plan to be created, which will then determine the selection of operative or non-operative management of the renal trauma, and whether nephrectomy or reconstruction is to be attempted.

In patients who are haemodynamically unstable after the initial acute damage control laparotomy, or in patients with deteriorating haemodynamic parameters (indicating ongoing or delayed bleeding), the management options are angiographic embolisation of the bleeding kidney or re-operation. This decision should be made according to several factors:

- the general status of the patient
- the presence of associated injuries that have been treated according to damage control principles (bowel injuries, packed liver, or splenic injuries) and that need re-operation irrespective of the renal injury
- the availability of angiography.

7.6.2.2 Ureteral injuries

Although excellent results can be achieved with acute ureteral reconstruction, the surgery is time-consuming and might not be appropriate in the mass casualty setting.

During mass casualty events, diagnostic procedures such as the intraoperative injection of indigo carmine, intraoperative intravenous pyelography (IVP) or retrograde ueretropyelography that are intended to evaluate ureteral injuries should be discouraged.

If a ureteral injury is suspected but not clearly identified, a drain may be left in place. If urine leaks, a nephrostomy tube can be placed post-operatively.

If a partial ureteral tear is identified (less than half circumference) and the ureter looks viable, a double J-stent may be inserted over a guide wire through the tear, and the tear quickly closed with interrupted absorbable stitches.

When complete ureteral injuries are identified, definitive repair should not be performed. Dissection of the ureteral stumps should be avoided as it interferes with the blood supply. Instead:

- place a single J or 8 French feeding tube into the ureter
- tie the distal end of the ureter over the tube
- exteriorise it through a small stab incision
- tie it to the skin.

The distal ureteral stump does not need to be ligated, and any unnecessary manipulation should be avoided.

Tying off the injured ureteral segment and inserting a percutaneous nephrostomy post-operatively (22, 23) is a viable alternative, but is not the procedure of choice.
In rare, selected cases, nephrectomy is required to treat ureteral injury, but only in cases of severe associated injuries of the ipsilateral kidney (24).

Ureteral injuries are rarely life-threatening and should be addressed only after other injuries have been attended to. In an unstable patient, temporary measures to control urine spillage should be performed, for example:

- tying off of the injured ureteral segment and post-operative insertion of percutaneous nephrostomy (15, 19)
- placement of a single J or feeding tube into the ureter, tying the distal end of the ureter over the tube and exteriorising it (15, 19, 23).

Intraoperative placement of a nephrostomy tube is time-consuming and should be avoided (15, 19).

7.6.2.3 Bladder injury

Bladder injuries should be classified, when time and resources allow, as extraperitoneal or intraperitoneal. Extraperitoneal injuries can usually be managed with bladder drainage alone. Intraperitoneal injuries require surgical exploration and layered closure of the bladder wall (13). The degree to which penetrating bladder injury can be treated non-surgically is not known. However, non-surgical management of iatrogenic bladder injuries has been reported, and could be effective after penetrating injury (11, 19).

7.6.2.3.1 Auxiliary damage control measures

Examples of auxiliary damage control measures that could be applicable include:

- the placement of externalised ureteral stents can provide external urinary drainage in extensive bladder rupture (19)
- packing or arteriography and selective embolisation can be applied in cases of bladder haemorrhage in patients who are unsuitable for urgent pelvic exploration (13, 19)
- the placement of a pelvic suction drain for urinary evacuation (19).

7.6.2.4 Urethral injury

Urethral injury of any kind is never life-threatening per se, but the associated injuries might cause haemodynamic instability. The patient is usually seen by the urologist during an operation performed because of the other injuries. In this situation, no matter whether the urethral tear is posterior or anterior, partial or complete, drainage through a suprapubic or urethral catheter should be obtained without prior imaging.

7.6.2.5 Injury of the external genitalia

Traumatic injuries of the external genitalia are much more common in men than in women, probably because of the anatomical differences (11, 25). Blunt injuries of the genitalia are usually isolated, and can be managed conservatively. Penetrating injuries of the genitalia are often associated with injuries of adjacent abdominal organs and related haemodynamic instability (12). In mass casualty events, both types of injury should be managed by watchful waiting. Urethral or testicular imaging and surgical exploration should be deferred.

7.6.2.5.1 Temporary damage control measures

Temporary damage control measure that might be applicable include:

- compression dressing of the penis
- packing of penetrating testicular injuries
- tampons for vulvar lacerations.

7.7 Summary

- Damage control surgery has become the standard approach in the management of unstable patients, and is especially useful in a mass trauma event.
- Medical teams should be well prepared ahead of time to deal with mass casualty events.
- All surgical sub-specialists involved in trauma management should be very familiar with the principles of triage and damage control.

7.8 REFERENCES

1. Slater MS, Trunkey DD. Terrorism in America. An evolving threat. Arch Surg 1997 Oct;132(10):1059-66 http://www.ncbi.nlm.nih.gov/pubmed/9336502

2. Caro D. Major disasters. Lancet 1974 Nov:30;2(7892):1309-10.
http://www.ncbi.nlm.nih.gov/pubmed/4139541
3. Weighlt JA, Krantz BE, Ali J et al. Advanced Trauma Life Support Student Course Manual. American College of Surgeons Committee on Trauma, 6th edn. Chicago, 1997.
4. Frykberg ER. Medical management of disasters and mass casualties from terrorist bombings: how can we cope? J Trauma 2002 Aug;53(2):201-12.
http://www.ncbi.nlm.nih.gov/pubmed/12169923
5. Jacobs LM Jr, Ramp JM, Breay JM. An emergency medical system approach to disaster planning. J Trauma 1979 Mar;19(3):157-62.
http://www.ncbi.nlm.nih.gov/pubmed/458880
6. Rotondo MF, Schwab CW, McGonigal MD, Phillips GR 3rd, Fruchterman TM, Kauder DR, Latenser BA, Angood PA. 'Damage control': an approach for improved survival in exsanguinating penetrating abdominal injury. J Trauma 1993 Sep;35(3):375-82.
http://www.ncbi.nlm.nih.gov/pubmed/8371295
7. Feliciano DV, Moore EE, Mattox KL. Trauma damage control. In: Mattox KL, Feliciano DV, Moore EE (eds). *Trauma*, 4th edn, New York: McGraw-Hill, 2000, Chapter 39, pp. 907-931.
8. Hirshberg A, Mattox KL. 'Damage control' in trauma surgery. Br J Surg 1993 Dec;80(12):1501-2.
http://www.ncbi.nlm.nih.gov/pubmed/8298911
9. Rignault DP. Recent progress in surgery for the victims of disaster, terrorism, and war--Introduction. World J Surg. 1992 Sep-Oct;16(5):885-7.
http://www.ncbi.nlm.nih.gov/pubmed/1462624
10. Holcomb JB, Helling TS, Hirshberg A. Military, civilian and rural application of the damage control philosophy. Mil Med 2001 Jun;166(6):490-3.
http://www.ncbi.nlm.nih.gov/pubmed/11413725
11. Lynch D, Martínez-Piñeiro L, Plas E, Serafetinidis E, Turkeri L, Santucci R, Hohenfellner M. Guidelines on urological trauma. European Association of Urology. Edition presented at the 23rd EAU Annual Congress, 2008, ISBN 978-90-70244-91-0
http://www.uroweb.org/files/uploadedfiles/guidelines/urotrauma.pdf
12. Krieger JN, Algood CB, Mason JT, Copass MK, Ansell JS. Urological trauma in the Pacific Northwest: etiology, distribution, management and outcome. J Urol 1984 Jul;132(1):70-3.
http://www.ncbi.nlm.nih.gov/pubmed/6726964
13. Pansadoro A, Franco G, Laurenti C, Pansadoro V. Conservative treatment of intraperitoneal bladder perforation during transurethral resection of bladder tumor. Urology 2002 Oct;60(4):682-4.
http://www.ncbi.nlm.nih.gov/pubmed/12385934
14. Peterson NE. Genitourinary trauma, in Mattox KL, Feliciano DV, Moore EE (eds). Trauma, 4th edn, New York: McGraw-Hill, 2000, Chapter 37, pp. 839-79.
15. McAninch JW, Santucci RA. Genitourinary trauma, In: Walsh PC., Retik AB, Darracott Vaughan E, Jr., Wein AJ (eds). In: *Campbell's Urology*, 8th edn. Philadelphia: W.B. Saunders, 2002, Chapter 105, pp. 3707-3744.
16. Brandes SB, McAninch JW. Renal trauma: a practical guide to evaluation and management. Digital Urology Journal.
http://www.duj.com/Article/McAninch/McAninch.html
17. Brandes SB, McAninch JW. Reconstructive surgery for trauma of the upper urinary tract. Urol Clin North Am 1999 Feb;26(1):183-99.
http://www.ncbi.nlm.nih.gov/pubmed/10086060
18. Wessells H, McAninch JW, Meyer A, Bruce J. Criteria for nonoperative treatment of significant penetrating renal lacerations. J Urol 1997 Jan;157(1):24-7.
http://4www.ncbi.nlm.nih.gov/pubmed/8976207
19. Coburn M. Damage control for urologic injuries. Surg Clin North Am 1997 Aug;77(4):821- 34.
http://www.ncbi.nlm.nih.gov/pubmed/9291984
20. Shekarris B, Stoller ML. The use of fibrin sealant in urology. J Urol 2002 Mar;167(3):1218-25.
http://www.ncbi.nlm.nih.gov/pubmed/11832701
21. Chaabouni MN, Bittard M. [Application of peri-renal prosthesis (vicryl mesh) in the conservative treatment of multiple ruptured kidney fragments.] Ann Urol 1996;30(2):61-3.
http://www.ncbi.nlm.nih.gov/pubmed/8767808
22. Brandes S, Coburn M, Armenakas N, McAninch J. Diagnosis and management of ureteric injury: an evidence-based analysis. BJU Int 2004 Aug;94(3):277-89.
http://www.ncbi.nlm.nih.gov/pubmed/15291852

23. Best CD, Petrone P, Buscarini M, Demiray S, Kuncir E, Kimbrell B, Asensio JA. Traumatic ureteral injuries: a single institution experience validating the American Association for the Surgery of Trauma-Organ Injury Scale grading scale. J Urol 2005 Apr;173(4):1202-5. http://www.ncbi.nlm.nih.gov/pubmed/15758748
24. Hirshberg A, Wall MJ Jr, Mattox KL. Planned reoperation for trauma: a two year experience with 124 consecutive patients. J Trauma 1994 Sep;37(3):365-9. http://www.ncbi.nlm.nih.gov/pubmed/8083894
25. Van der Horst C, Martinez Portillio FJ, Seif C, Groth W, Jünemann KP. Male genital injury: diagnostics and treatment. BJU Int 2004 May;93(7):927-30. http://www.ncbi.nlm.nih.gov/pubmed/15142139

8. ABBREVIATIONS USED IN THE TEXT

This list is not comprehensive for the most common abbreviations

AAST	American Association for the Surgery of Trauma
ATLS	advanced trauma life support
BT	Transperineal, interstitial, permanent prostate brachytherapy
BUN	blood urea nitrogen
CT	computed tomography
DMSA	dimercaptosuccinic acid
EBRT	External beam radiotherapy
ePTFE	polytetrafluoroethylene
GR	grade of recommendation
HIV	human immunodeficiency virus
hpf	high-power field
ICU	intensive care unit
IVP	intravenous pyelography/pyelogram
KUB	kidney-ureter-bladder
MRI	magnetic resonance imaging
m/s	metres per second
PCNL	percutaneous nephrolithotomy
rbc/hpf	red blood cells per high-power field
TOT	transobturator tape
TUR-P	Transurethral resection of the prostate
TVT	tension-free vaginal tape

Conflict of interest

All members of the Urological Traume Guidelines writing panel have provided disclosure statements on all relationships that they have and that might be perceived to be a potential source of conflict of interest. This information is kept on file in the European Association of Urology Central Office database. This guidelines document was developed with the financial support of the European Association of Urology. No external sources of funding and support have been involved. The EAU is a non-profit organisation and funding is limited to administrative assistance and travel and meeting expenses. No honoraria or other reimbursements have been provided.