

EAU GUIDELINES ON UROLOGICAL TRAUMA

(Limited text update March 2016)

N.D. Kitrey (Chair), N. Djakovic, M. Gonsalves, F.E. Kuehhas,
N. Lumen, E. Serafetinidis, D.M. Sharma, D.J. Summerton
Guidelines Associates: P-J. Elshout, A. Sujenthiran,
E. Veskimäe

Eur Urol 2010 May;57(5):791-803

Eur Urol 2012 Oct;62(4):628-39

Eur Urol 2015 May;67(5):925-9

Eur Urol 2015 May;67(5):930-6

Introduction

Genito-urinary trauma is seen in both sexes and in all age groups, but is more common in males. Traumatic injuries are classified according to the basic mechanism into **penetrating** and **blunt**.

Penetrating trauma is further classified according to the velocity of the projectile:

1. High-velocity projectiles (e.g. rifle bullets - 800-1000m/sec).
2. Medium-velocity (e.g. handgun bullets - 200-300 m/sec).
3. Low-velocity items (e.g. knife stab).

High-velocity weapons inflict greater damage as the bullets transmit large amounts of energy to the tissues, resulting in damage to a much larger area than the projectile tract itself. In lower velocity injuries, the damage is usually confined to the track of the projectile.

Blast injury is a complex cause of trauma as it commonly includes both blunt and penetrating trauma, and may also be accompanied by a burn injury.

Initial evaluation and management

The first priority is stabilisation of the patient and treatment of associated life-threatening injuries. A direct history is obtained from the patient (if conscious) or from witnesses/emergency personnel (if patient unconscious and/or seriously injured).

In penetrating injuries, assess size of the weapon in stab-bings, and the type and calibre of the weapon used in gunshot wounds. The medical history should be as detailed as possible. It is important to recognise the high risk of hepatitis B and C infection in trauma patients and take appropriate precautions.

In any penetrating trauma, tetanus vaccination should be considered according to the patient's vaccination history and nature of the wound.

Renal Trauma

Renal injuries are associated with youth and male gender and the incidence is about 4.9 per 100,000 population.

Grade	Description
1	Contusion or non-expanding subcapsular haematoma, no laceration
2	Non-expanding perirenal haematoma, cortical laceration < 1 cm deep without extravasation
3	Cortical laceration > 1 cm without urinary extravasation

4	Laceration: through corticomedullary junction into collecting system or vascular: segmental renal artery or vein injury with contained haematoma
5	Laceration: shattered kidney or vascular: renal pedicle injury or avulsion

* Adapted from the American Association for the Surgery of Trauma (AAST).

Advance one grade for multiple injuries up to grade 3.

Diagnostic evaluation

- Haemodynamic stability should be assessed upon admission.
- History: time and setting of incident, past renal surgery, known renal abnormalities.
- Lab: visible haematuria, dipstick urine analysis, serial haematocrit, baseline serum creatinine.
- In blunt trauma with visible- or non-visible haematuria and hypotension, a history of rapid deceleration injury and/or significant associated injuries should undergo radiographic evaluation.
- Any degree of haematuria after penetrating abdominal or thoracic injury requires urgent imaging.
- Imaging: computed tomography (CT) scan, with and without intravenous contrast material, in haemodynamically stable patients.
- Angiography can be used for diagnosis and simultaneous selective embolisation of bleeding vessels if necessary.

Management

- Following blunt renal trauma, stable patients should be managed conservatively with close monitoring of vital signs.
- Isolated grade 1-3 stab and low-velocity gunshot wounds in stable patients, after complete staging, should be managed expectantly.

- Indications for renal exploration include:
 - haemodynamic instability;
 - exploration for associated injuries;
 - expanding or pulsatile peri-renal haematoma identified during laparotomy;
 - grade 5 vascular injury (Figures 1 & 2).
- Radiological embolisation is indicated in patients with active bleeding from renal injury, but without other indications for immediate abdominal operation.
- Intraoperatively, reconstruction should be attempted once haemorrhage is controlled and there is sufficient viable renal parenchyma.

Figure 1: Evaluation of blunt renal trauma in adults

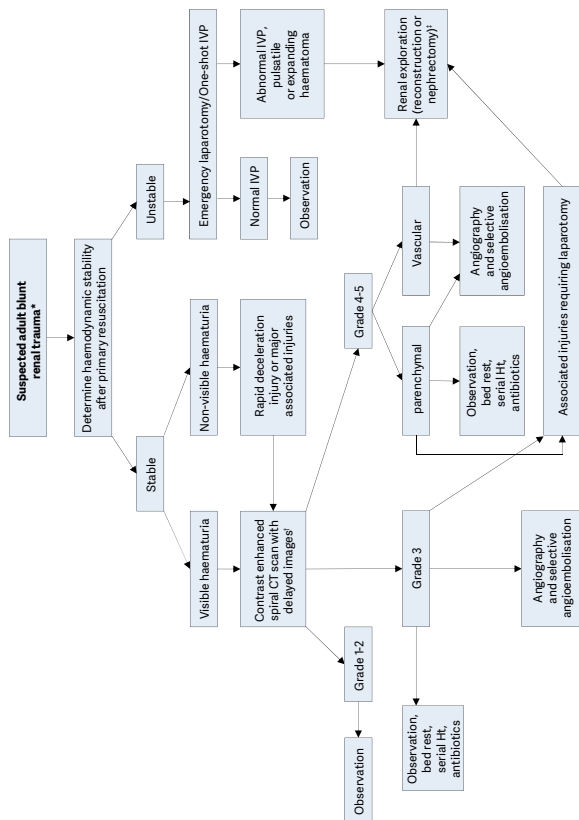
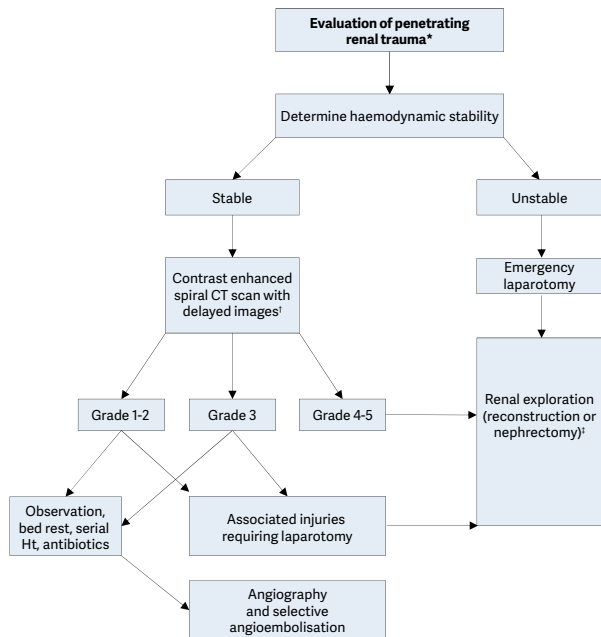


Figure 2: Evaluation of penetrating renal trauma in adults



Post-operative care, follow-up and complications

- Repeat imaging is recommended in cases of suspected complications; fever, flank pain, or falling haematocrit.
- Nuclear scintigraphy is useful for documenting functional recovery.
- First follow up should be at approximately 3 months after major injury and should include: physical examination, urinalysis, individualised radiological investigation, blood pressure measurement and serum determination of renal function.

- Long-term follow-up should be decided on a case-by-case basis.
- Medical management and minimally invasive techniques should be the first choice for the management of complications.

Iatrogenic renal injuries

- Iatrogenic renal injuries are procedure-dependent (1.8-15%).
- Significant injury requiring intervention is rare.
- Most common injuries are vascular.
- Renal allografts are more susceptible.
- Injuries occurring during surgery are rectified immediately.
- Symptoms suggestive of a significant injury require investigation.
- Patients with minor injuries should be treated conservatively.
- Severe or persistent injuries require intervention with embolisation.
- In stable patients, a second embolisation should be considered in case of failure.

Ureteral Trauma

Ureteral injuries are quite rare - most are iatrogenic. They are often missed intra-operatively, usually involve the lower ureter, and may result in severe sequelae. Risk factors include advanced malignancy, prior surgery or irradiation - i.e. conditions which alter the normal anatomy. Preoperative prophylactic stents do not prevent ureteral injury, but may assist in its detection. External ureteral trauma usually accompanies severe abdominal and pelvic injuries. Gunshot wounds account for the majority of penetrating ureteral trauma, while motor vehicle accidents account for most of blunt injuries.

Diagnostic evaluation

- A high index of suspicion of ureteral injury should be

maintained because the majority of cases are diagnosed late and predispose the patient to pain, infection, and renal function impairment.

- Haematuria is an unreliable indicator.
- Extravasation of contrast material in CT is the hallmark sign of ureteral trauma, and in unclear cases, a retrograde or antegrade urography is required for confirmation.

Management

- Partial injury can be managed with ureteral stenting or urinary diversion by a nephrostomy.
- In complete injuries, ureteral reconstruction following temporary urinary diversion is required.
- The type of repair procedure depends on the site of the injury (Table 2), and it should follow the principles outlined in Table 3.
- Proximal- and mid-ureteral injuries can often be managed by primary uretero-ureterostomy, while a distal injury is often treated with ureteral reimplantation.

Site of injury	Reconstruction options
Upper ureter	Uretero-ureterostomy Transuretero-ureterostomy Uretero-calycostomy
Mid ureter	Uretero-ureterostomy Transuretero-ureterostomy Ureteral reimplantation and a Boari flap
Lower ureter	Ureteral reimplantation Ureteral reimplantation with a psoas hitch
Complete	Ileal interposition graft Autotransplantation

Table 3: Principles of surgical repair of ureteral injury
Debridement of necrotic tissue
Spatulation of ureteral ends
Watertight mucosa-to-mucosa anastomosis with absorbable sutures
Internal stenting
External drain
Isolation of injury with peritoneum or omentum

Bladder Trauma

Bladder injuries can be due to external (blunt or penetrating) or iatrogenic trauma. Iatrogenic trauma is caused by external laceration or internal perforation (mainly during TURB). Blunt bladder injuries are strongly associated with pelvic fractures. Bladder injuries are classified as extraperitoneal, intraperitoneal or combined.

Diagnostic evaluation

Clinical signs and symptoms

External trauma

- Cardinal sign: visible haematuria.
- Others: abdominal tenderness, inability to void, bruises over the suprapubic region, and abdominal distension (in case of urinary ascites).
- Penetrating bladder injury: entrance- and exit wounds in lower abdomen or perineum.
- Bloody urethrorrhagia: suspect concomitant urethral injury.

Iatrogenic trauma

- External perforation: extravasation of urine, visible laceration, clear fluid in the surgical field, appearance of the bladder catheter, and blood and/or gas (in case of laparoscopy) in the urine bag.
- Internal perforation: fatty tissue or bowel between detrusor

muscle fibres, inability to distend the bladder, low return of irrigation fluid and/or abdominal distension.

- Postoperative symptoms of unrecognised bladder perforation: haematuria, lower abdominal pain, abdominal distension, ileus, peritonitis, sepsis, urine leakage from the wound, decreased urinary output, and increased serum creatinine.

Imaging

Cystography (conventional or CT-cystography)

- Fill the bladder with at least 350 mL of dilute contrast material.
- CT cystography is preferred in case of other possible abdominal injuries or causes of abdominal pain.
- Standard evaluation for external trauma and in case of suspicion of an iatrogenic bladder injury in the postoperative setting.
- Imperative in case of visible haematuria combined with pelvic fracture.

Cystoscopy

- To detect intra-operative bladder injuries.
- Recommended after minimally invasive synthetic suburethral sling operations by retropubic route and major gynaecologic operations.
- Optional after any other type of sling procedure or transvaginal mesh procedure.

Management

Surgical repair (two-layer vesicorrhaphy)

- Penetrating injury.
- Blunt intraperitoneal injury.
- Blunt extraperitoneal injury with internal osteosynthetic fixation of pelvic fracture.
- (large) Iatrogenic internal intraperitoneal injury.

- Intra-operative recognised injury.
- In case of bladder neck involvement, bony fragment(s) in the bladder, concomitant rectal injury and/or bladder wall entrapment.
- Intraperitoneal bladder ruptures by blunt trauma, and any type of bladder injury by penetrating trauma, must be managed by emergency surgical exploration and repair.

Conservative management (urinary catheter)

- Conservative management is an option for small, uncomplicated, iatrogenic intraperitoneal bladder perforations.
- In the absence of bladder neck involvement and/or associated injuries that require surgical intervention, extraperitoneal bladder ruptures caused by blunt trauma are managed conservatively.
- Postoperative recognised extraperitoneal perforation.
- Blunt extraperitoneal perforation.
- Iatrogenic internal extraperitoneal perforation.
- Small internal intraperitoneal perforation in absence of ileus and peritonitis. Placement of an intraperitoneal drain is optional.

Urethral Trauma

- Injuries to the anterior urethra (AU) are caused by trauma during sexual intercourse (associated with penile fracture), penetrating trauma, placement of penile constriction bands, and from iatrogenic trauma e.g. endoscopic instruments, catheterisation.
- Injuries to the posterior urethra (PU) occur with pelvic fractures, mostly as a result of motor vehicle accidents. The male PU is injured in 4-19% of pelvic fractures, and the female urethra in 0-6% of all pelvic fractures.
- The combination of straddle fractures with diastasis of the sacroiliac joint has the highest risk of urethral injury.
- Injuries can vary from simple stretching to partial rupture

to complete disruptions.

- Urethral injuries in women are rare.

Diagnostic evaluation

- Blood at the external urethral meatus is the most common clinical sign, and indicates the need for further diagnostic work up.
- Although non-specific, haematuria on a first voided specimen may indicate urethral injury. The amount of urethral bleeding correlates poorly with the severity of injury.
- Pain on urination or inability to void may indicate disruption.
- Blood at the vaginal introitus is present in more than 80% of female patients with pelvic fractures and co-existing urethral injuries.
- Rectal examination may reveal a “high riding” prostate. However, this is an unreliable finding. Blood on the examination finger is suggestive of a rectal injury associated with pelvic fracture.
- Urethral bleeding or urinary extravasation can cause penile and scrotal swelling and haematoma.
- Retrograde urethrography is the gold standard for evaluating urethral injury and urethral catheterisation should be avoided until the urethra is imaged.
- In an unstable patient, however, an attempt can be made to pass a urethral catheter (gently, by someone with urological experience). If this is not possible, a suprapubic catheter is inserted and a retrograde urethrogram is performed later.
- In females, urethroscopy may be an important adjunct for the identification and staging of urethral injuries.

Management

While intervention should be guided by the clinical circumstances, the following treatment is suggested:

- Retrograde urethrography is the gold standard for evaluating urethral injuries.
- Delayed formal urethroplasty is the procedure of choice for the treatment of posterior urethral distraction defects.
- Partial posterior urethral ruptures should be treated by urethral or suprapubic catheterisation.
- Blunt anterior urethral injuries should be treated by suprapubic diversion.

Iatrogenic urethral trauma

- Most commonly caused by urethral instrumentation, and results in stricture formation.
- Due to their variable location and severity, they often require different management strategies.
- Short and flimsy strictures can be treated by urethrotomy.
- If the stricture is longer or denser, urethroplasty should be considered.

Genital Trauma

Of all genito-urinary injuries, one-third to two-thirds involve the external genitalia and is much more common in males - due to anatomical differences and increased frequency of road traffic accidents, physical sports, violent crime, and war-fighting. 80% is blunt trauma, 20% is due to penetrating injuries.

Diagnostic evaluation

- Urinalysis should be performed.
- Visible- and/or non-visible haematuria require a retrograde urethrogram in males, and consideration of cystoscopy in females.
- In women with genital injuries and blood at the vaginal introitus, further gynaecologic investigation to exclude vaginal injury.
- In cases of suspected sexual abuse gynaecologic and

forensic support and advice is necessary and the emotional situation and privacy of the patient must be respected.

Blunt penile trauma

- Usually results from trauma to the erect penis during sexual intercourse or masturbation.

Penile fracture

- Sudden cracking or popping sound, pain and immediate detumescence.
- Local swelling of the penile shaft is seen and this may extend to the lower abdominal wall.
- The rupture of the tunica may be palpable.
- Thorough history and examination confirms diagnosis
- Imaging (US or magnetic resonance imaging [MRI]) may be useful.

Management

- Subcutaneous haematoma, without associated rupture of the cavernosal tunica albuginea does not require surgical intervention. Nonsteroidal analgesics and ice-packs are recommended.
- In penile fracture, early surgical intervention with closure of the tunica albuginea is recommended.
- Intra-operative flexible cystoscopy is useful to diagnose urethral injury and to further localise tunical damage.
- Conservative management of penile fracture is not recommended.

Penetrating penile trauma

- Rarely seen in isolation.
- Due to gunshot/knife injury, animal or human bites, assault and industrial or self-inflicted mutilation.
- Non-operative management is recommended in small superficial injuries with intact Buck's fascia.

- More significant injuries require surgical exploration and debridement of necrotic tissue.
- In extended injuries of the penis, primary alignment of the disrupted tissues may allow for acceptable healing because of the robust penile blood supply.
- In avulsion of the penis, resuscitate the patient and attempt re-implantation of the penis (if not too badly damaged) - ideally microsurgical.

Blunt scrotal trauma

- May result in testicular dislocation, haematocoele, testicular rupture and/or scrotal haematoma.
- Dislocation of the testicle is rare. Treat by manual replacement and secondary orchidopexy. If manual reposition cannot be performed, immediate orchidopexy is indicated.
- If haematocoele is smaller than three times the size of the contralateral testis – conservative management.
- If large haematocoele - explore.
- If testicular rupture suspected, explore, evacuate clot and any necrotic testicular tubules and close the tunica albuginea.

Penetrating scrotal trauma

- Surgical exploration with conservative debridement of nonviable tissue.
- Primary reconstruction of testis and scrotum can be performed in most cases.
- In complete disruption of the spermatic cord, realignment without vaso-vasostomy may be considered.
- In extensive destruction of the tunica albuginea, mobilisation of a free tunica vaginalis flap can be performed for testicular closure.
- If reconstruction cannot be achieved, orchiectomy is indicated.

- In IED blast injury, the extensive loss of genital tissue often requires complex and staged reconstructive surgical procedures.

Genital trauma in females

- In blunt trauma to the external genitalia, imaging studies of the pelvis with US, CT, or MRI should be performed.
- Vulvar haematomas usually do not require surgical intervention, but in massive vulvar haematoma or haemodynamically unstable patients, surgical intervention, lavage and drainage is indicated.
- In vulvar laceration, suturing after conservative debridement is indicated with concomitant primary repair of any associated vaginal injuries.

Polytrauma, Damage Control and Mass Casualty Events

Urological trauma is often associated with significant and higher priority injuries in the polytraumatised patient. Damage control principles govern the management of the severely injured patient and urologists need to understand their role in the context of polytrauma.

Damage control is a three-phase approach - rapid control of haemorrhage and wound contamination, resuscitation in the intensive care unit, and delayed definitive surgery.

Procedures should be directed at the rapid control of bleeding, debridement of dead and devitalised tissue, and minimising urinary extravasation by simple diversionary measures.

A mass casualty event is one in which the number of injured people is significantly higher than the number of healthcare providers available. Examples include the collapse of buildings or bridges, earthquakes, floods, tsunamis, train collisions, aircraft catastrophes, civilian terrorism.

Triage sorts patients into four groups:

1. Patients with life-threatening injuries that require immediate intervention, presenting with **A**irway compromise, **B**reathing failure and/or **C**irculatory compromise from ongoing external haemorrhage.
2. Patients with severe but non-life-threatening injuries, in whom treatment can be acceptably delayed: major fractures, vascular injuries of the limbs and large soft tissue wounds.
3. 'Walking wounded' with minimal injuries.
4. Patients who are so severely injured that treatment would require allocation of resources and time that would deny other, more salvageable patients, timely care. These patients are given minimal or no treatment, and re-evaluated when resources become available. There is no absolute definition for this group because triage is individualised according to the number and severity of casualties related to the available resources.

Principles urological consultations during a mass casualty scenario:

- Rule out under-triage by the surgeon in charge, and perform a rapid primary survey of every patient.
- Avoid unnecessary imaging procedures such as CT scans and retrograde urethrography. These procedures should be performed later, after mass casualty protocols have been suspended.
- Treat unstable patients who are to have surgery using damage control principles.
- Stable patients with suspected renal injuries should be transferred to the surgical ward without imaging procedures. Re-evaluate if there is any change in their haemodynamic status, or when possible as dictated by the constraints of the mass casualty event. Patients managed in this delayed fashion should be treated according to

traditional trauma management protocols.

- 'Minimal acceptable' procedures should be performed in order to transfer patients to the surgical wards, e.g. suprapubic drainage of the bladder when bladder or urethral injuries are suspected, clamping and ligation of bleeding vessels from wounds to the external genitalia, etc.

This short booklet text is based on the more comprehensive EAU Guidelines (ISBN 978-90-79754-98-4) available to all members of the European Association of Urology at their website, <http://www.uroweb.org>.