

# EAU GUIDELINES ON UROTHELIAL CARCINOMAS OF THE UPPER URINARY TRACT (UTUCs)

*(Limited text update March 2016)*

M. Rouprêt, M. Babjuk, A. Böhle, M. Burger, E. Compérat, N. Cowan, E. Kaasinen, J. Palou, B.W.G. van Rhijn, S.F. Shariat, R. Sylvester, R. Zigeuner  
Guidelines Associates: M. Bruins, J.L. Dominguez-Escrig, B. Peyronnet, T. Seisen

**Eur Urol 2011 Apr;59(4):584-94**

**Eur Urol 2013 Jun;63(6):1059-71**

**Eur Urol 2015 Nov;68(5):868-79**

## Epidemiology

UTUCs are uncommon and account for only 5-10% of urothelial cell carcinomas. They have a similar morphology to bladder carcinomas and nearly all UTUCs are urothelial in origin.

## Staging and grading systems

The UICC 2009 TNM (Tumour, Node, Metastasis Classification) for renal pelvis and ureter is used for staging (Table 1).

## Tumour grade

There are currently two main classifications used for UTUCs; the 1973 WHO classification, which classifies tumours into three grades, G1, G2 and G3, and the 2004 WHO classification, which classifies tumours into three groups:

- Papillary urothelial neoplasia of low malignant potential;
- Low-grade carcinomas;
- High-grade carcinomas.

Upper urinary tract tumours with low malignant potential are very rare.

**Table 1: TNM Classification 2009**

<b>T - Primary tumour</b>	
TX	Primary tumour cannot be assessed
T0	No evidence of primary tumour
Ta	Non-invasive papillary carcinoma
Tis	Carcinoma <i>in situ</i>
T1	Tumour invades subepithelial connective tissue
T2	Tumour invades muscle
T3	(Renal pelvis) Tumour invades beyond muscularis into peripelvic fat or renal parenchyma (Ureter) Tumour invades beyond muscularis into periureteric fat
T4	Tumour invades adjacent organs or through the kidney into perinephric fat
<b>N - Regional lymph nodes</b>	
NX	Regional lymph nodes cannot be assessed
N0	No regional lymph node metastasis
N1	Metastasis in a single lymph node 2 cm or less in the greatest dimension
N2	Metastasis in a single lymph node more than 2 cm but not more than 5 cm in the greatest dimension or multiple lymph nodes, none more than 5 cm in greatest dimension
N3	Metastasis in a lymph node more than 5 cm in greatest dimension
<b>M - Distant metastasis</b>	
M0	No distant metastasis
M1	Distant metastasis

## Diagnosis

UTUCs are diagnosed using imaging, cystoscopy, urinary cytology and diagnostic ureteroscopy. The benefits of ureteroscopy for pre-operative assessment should also be discussed with the patient.

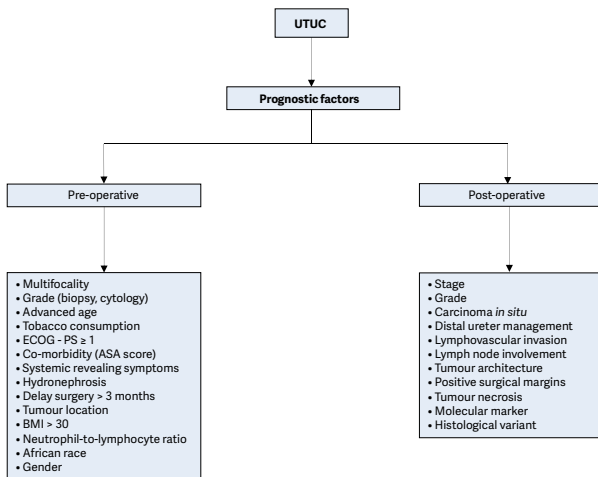
<b>Recommendations for the diagnosis of UTUCs</b>	<b>GR</b>
Perform urinary cytology as part of a standard diagnostic work-up.	A
Perform a cystoscopy to rule out concomitant bladder tumour.	A
Perform a CT-urography for the diagnostic work-up.	A
Use diagnostic ureteroscopy and biopsy in cases where additional information will impact treatment decisions.	C
Perform retrograde ureteropyelography in case CT-urography or ureteroscopy do not reliably reveal the presence or extent of the tumour.	C

*CT-urography = computed tomography urography.*

## Prognosis

UTUCs invading the muscle wall usually have a very poor prognosis. Recognised prognostic facts, as listed in Figure 1.

**Figure 1: UTUCs - Prognostic factors**

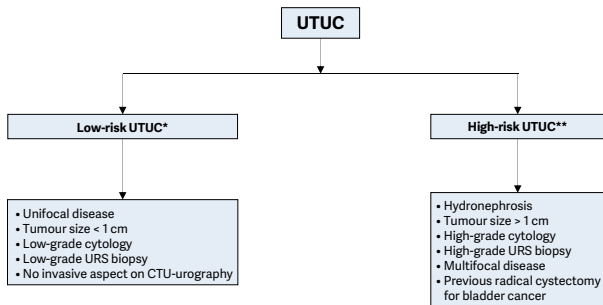


*ASA = American Society of Anesthesiologists; BMI = body mass index; ECOG = Eastern Cooperative Oncology Group; PS = performance score.*

### **Risk stratification**

It is necessary to 'risk-stratify' UTUC cases before treatment to identify those patients (and tumours) who are more suitable for kidney-sparing management rather than radical extirpative surgery (Figure 2).

**Figure 2: Pre-intervention risk stratification of UTUCs**



\*All of these factors need to be present.

\*\* Any of these factors need to be present.

CTU = computed tomography urography;

URS = ureterorenoscopy.

## **Disease management (see also Figs. 3 & 4)**

### **Localised disease**

#### *Kidney-sparing surgery*

Kidney-sparing surgery for low-risk UTUCs consists of surgery preserving the upper urinary renal unit. It is used in imperative cases (renal insufficiency, solitary functional kidney). It can also be discussed in low-risk patients in case of a functional contralateral kidney. Kidney-sparing surgery in low-risk UTUCs potentially allows avoiding the morbidity associated with open radical surgery without compromising oncological outcomes and kidney function.

<b>Recommendations for the kidney-sparing management of UTUCs</b>	<b>GR</b>
Offer kidney-sparing management as primary treatment option to patients with low-risk tumour and two functional kidneys.	C
In patients with solitary kidney and/or impaired renal function, offer kidney-sparing management, providing it will not compromise the oncological outcome. This decision will have to be made on a case-by-case basis, engaging the patient in a shared decision-making process.	C
In high-risk cancers, offer a kidney-sparing approach for distal ureteral tumours and in imperative cases (solitary kidney and/or impaired renal function).	C
<b>Offer kidney-sparing management in case of:</b>	
<ul style="list-style-type: none"> <li>• Unifocal tumour;</li> <li>• Tumour &lt; 1 cm;</li> <li>• Low-grade tumour;</li> <li>• No evidence of infiltrative lesion on CTU;</li> <li>• Understanding of close follow-up.</li> </ul>	B
If treatment is done endoscopically, use a laser.	C

*CTU = computed tomography urography.*

The instillation of bacillus Calmette-Guérin or mitomycin C in the urinary tract by percutaneous nephrostomy or via a ureteric stent is technically feasible after conservative treatment of UTUCs. However, the benefits have not been confirmed.

### *Radical nephroureterectomy*

Open RNU with bladder cuff excision is the standard treatment for high-risk UTUC, regardless of tumour location.

<b>Recommendations for radical nephroureterectomy</b>	<b>GR</b>
RNU is the standard in high-risk UTUC, regardless of tumour location.	B
<b>Use RNU in the following situations:</b>	
• Suspicion of infiltrating UTUC on imaging;	B
• High-grade tumour (urinary cytology);	B
• Multifocality (with two functional kidneys);	B
• Non-invasive but large (> 1 cm) UTUC.	B
<b>RNU techniques:</b>	
• Remove the bladder cuff;	A
• Perform a lymphadenectomy in invasive UTUC;	C
• Offer a postoperative bladder instillation to lower the bladder recurrence rate.	B
Open and laparoscopic approaches have equivalent efficacy and safety in T1–T2/N0 UTUCs.	B

RNU = radical nephroureterectomy.

### Advanced disease

RNU has no benefit in metastatic (M+) disease, but may be used in palliative care. As UTUCs are urothelial tumours, platinum-based chemotherapy should give similar results to those in bladder cancer. Currently, insufficient data are available to provide any recommendations.

Radiotherapy is scarcely relevant nowadays, both as a unique therapy and associated with chemotherapy as a tumour adjuvant.

### Follow-up after initial treatment

In all cases, there should be strict follow-up after radical management to detect metachronous bladder tumours, as well as invasive tumours, local recurrence and distant metastases. In conservative management, the ipsilateral upper urinary tract requires careful follow-up due to the high risk of recurrence.

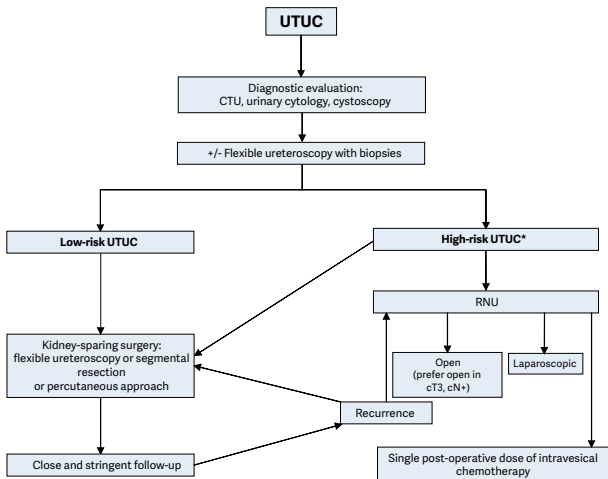
<b>Recommendations for follow-up of UTUC after initial treatment</b>	<b>GR</b>
<b>After RNU, <math>\geq</math> five years</b>	
<i>Non-invasive tumour</i>	
<ul style="list-style-type: none"> <li>Perform cystoscopy/urinary cytology at three months, and then annually.</li> </ul>	C
<ul style="list-style-type: none"> <li>Perform CT-urography every year.</li> </ul>	C
<i>Invasive tumour</i>	
<ul style="list-style-type: none"> <li>Perform cystoscopy/urinary cytology at three months, and then annually.</li> </ul>	C
<ul style="list-style-type: none"> <li>Perform CT-urography every six months for two years, and then annually.</li> </ul>	C
<b>After kidney-sparing management, <math>\geq</math> five years</b>	
<ul style="list-style-type: none"> <li>Perform urinary cytology and CTU at three and six months, and then annually.</li> </ul>	C
<ul style="list-style-type: none"> <li>Perform cystoscopy, ureteroscopy and cytology <i>in situ</i> at three and six months, and then every six months for two years, and then annually.</li> </ul>	C

*CT-urography = computed tomography urography;*

*RNU = radical nephroureterectomy.*



**Figure 3: Proposed flowchart for the management of UTUC**



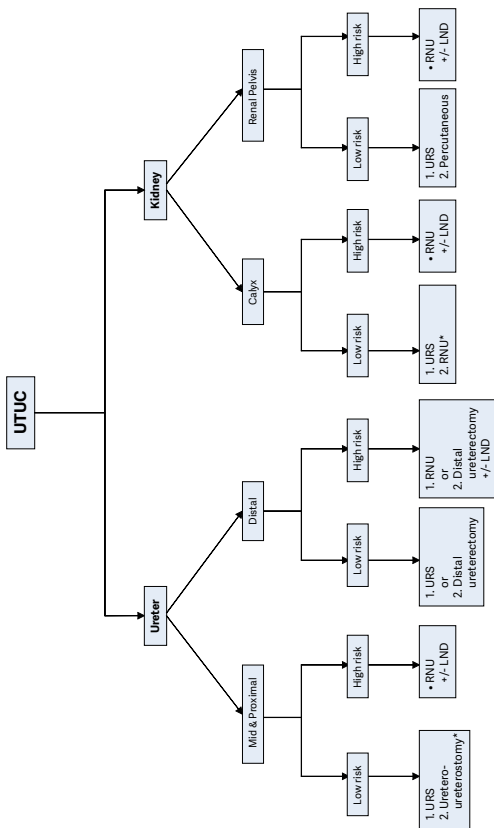
*\*In patients with a solitary kidney, consider a more conservative approach.*

CTU = computed tomography urography;

RNU = nephroureterectomy.

*This short booklet text is based on the more comprehensive EAU Guidelines (ISBN: 978-90-79754-98-4), available to all members of the European Association of Urology at their website: <http://www.uroweb.org/guidelines/>.*

**Figure 4: Surgical treatment according to location and risk status**



1. First treatment option

2. Secondary treatment option

\*In case not amenable to endoscopic management.