



## Guidelines

# EAU Guidelines on Penile Curvature

Konstantinos Hatzimouratidis<sup>a,\*</sup>, Ian Eardley<sup>b</sup>, François Giuliano<sup>c</sup>, Dimitrios Hatzichristou<sup>a</sup>, Ignacio Moncada<sup>d</sup>, Andrea Salonia<sup>e</sup>, Yoram Vardi<sup>f</sup>, Eric Wespes<sup>g</sup>

<sup>a</sup>2nd Department of Urology, Aristotle University of Thessaloniki, Thessaloniki, Greece; <sup>b</sup>Department of Urology, St James University Hospital, Leeds, UK;

<sup>c</sup>Service d'Urologie, CHU de Bicêtre, Le Kremlin Bicêtre, France; <sup>d</sup>Urology Department, Hospital General Universitario Gregorio Marañón, Madrid, Spain;

<sup>e</sup>Department of Urology, Scientific Institute H. San Raffaele, Milan, Italy; <sup>f</sup>Neuro-Urology Unit, Rambam Medical Centre, Carmel Medical Centre, Haifa, Israel;

<sup>g</sup>Urology Department, Hôpital Erasme, Brussels, Belgium

### Article info

#### Article history:

Accepted May 15, 2012

Published online ahead of print on May 25, 2012

#### Keywords:

Penile curvature  
Peyronie's disease  
Acquired  
Congenital  
EAU guidelines  
Penile abnormalities  
Medical management  
Surgical management  
Pharmacotherapy

### Abstract

**Context:** Penile curvature can be congenital or acquired. Acquired curvature is secondary due to La Peyronie (Peyronie's) disease.

**Objective:** To provide clinical guidelines on the diagnosis and treatment of penile curvature.

**Evidence acquisition:** A systematic literature search on the epidemiology, diagnosis, and treatment of penile curvature was performed. Articles with the highest evidence available were selected and formed the basis for assigning levels of evidence and grades of recommendations.

**Evidence synthesis:** The pathogenesis of congenital penile curvature is unknown. Peyronie's disease is a poorly understood connective tissue disorder most commonly attributed to repetitive microvascular injury or trauma during intercourse. Diagnosis is based on medical and sexual histories, which are sufficient to establish the diagnosis. Physical examination includes assessment of palpable nodules and penile length. Curvature is best documented by a self-photograph or pharmacologically induced erection. The only treatment option for congenital penile curvature is surgery based on plication techniques.

Conservative treatment for Peyronie's disease is associated with poor outcomes. Pharmacotherapy includes oral potassium para-aminobenzoate, intralesional treatment with verapamil, clostridial collagenase or interferon, topical verapamil gel, and iontophoresis with verapamil and dexamethasone. They can be efficacious in some patients, but none of these options carry a grade A recommendation. Steroids, vitamin E, and tamoxifen cannot be recommended. Extracorporeal shock wave treatment and penile traction devices may only be used to treat penile pain and reduce penile deformity, respectively.

Surgery is indicated when Peyronie's disease is stable for at least 3 mo. Tunical shortening procedures, especially plication techniques, are the first treatment options. Tunical lengthening procedures are preferred in more severe curvatures or in complex deformities. Penile prosthesis implantation is recommended in patients with erectile dysfunction not responding to pharmacotherapy.

**Conclusions:** These European Association of Urology (EAU) guidelines summarise the present information on penile curvature. The extended version of the guidelines is available on the EAU Web site ([www.uroweb.org/guidelines/](http://www.uroweb.org/guidelines/)).

© 2012 European Association of Urology. Published by Elsevier B.V. All rights reserved.

\* Corresponding author. Aristotle University of Thessaloniki, Kimiseos Theotokou 26B, 57010 Pefka, Thessaloniki, Greece. Tel. +30 23 10 99 15 43; Fax: +30 23 10 67 60 92.  
E-mail address: [promahon@otenet.gr](mailto:promahon@otenet.gr) (K. Hatzimouratidis).

## 1. Introduction

Penile curvature can be congenital or acquired. Congenital curvature is discussed in these guidelines as a distinct pathology in the adult population without any other concomitant abnormality present such as urethral abnormalities.

Acquired curvature is secondary due to La Peyronie disease (referred to as *Peyronie's disease*). The condition was given its name in 1743 by a French physician, François Gigot de La Peyronie, although he was not the first one to describe it [1].

## 2. Methodology

A systematic literature search of the Medline database was performed. The controlled vocabulary of the medical subject headings (MeSH) database uses the specific term *penile induration* for Peyronie's disease. There is no specific MeSH term for congenital penile curvature. To identify relevant articles, the search included the MeSH terms *congenital abnormalities*, *penis/\*abnormalities*, *male*, and the free-text term *congenital penile curvature*. A total of 48 articles were identified for congenital penile curvature and 1200 articles for Peyronie's disease. The panel reviewed all these records and selected the articles with the highest evidence available. However, in several subject areas, the only articles available for discussion had low levels of evidence.

## 3. Congenital penile curvature

### 3.1. Epidemiology and physiopathology

Congenital curvature is rare, and there is no evident cause [2]. A single study analysing the ultrastructure of the tunica albuginea demonstrated widening and fragmentation of collagen fibres, with complete disappearance of striation and transformation into electron-dense, fibrous granulated material and elastin accumulation [3].

### 3.2. Patient evaluation

The medical and sexual histories are usually sufficient to establish the diagnosis of congenital penile curvature. Physical examination during erection is only useful to document curvature and exclude other pathologies. Erectile function is normal, but it can be compromised by excessive curvature [4].

### 3.3. Treatment

The treatment of this pathology is only surgical and can be performed at any time in adults. Plication techniques are used almost exclusively with high curvature correction rates (67–97%) [4–6]. The use of grafting material in isolated congenital penile curvature is too limited to draw any conclusions. Table 1 summarises the conclusions on patient evaluation and treatment of congenital penile curvature.

## 4. Peyronie's disease

### 4.1. Epidemiology, physiopathology, and natural history

Prevalence rates of 0.4–9% have been published [7]. The aetiology of Peyronie's disease is unknown. However, an insult (repetitive microvascular injury or trauma) to the tunica albuginea is the most widely accepted hypothesis [8]. Peyronie's disease starts with an acute inflammatory process. This is characterised by increased proliferation of the tunical fibroblasts, some of which differentiate into myofibroblasts, with excessive deposition of collagen, the persistence of fibrin, and elastin fragmentation. A prolonged inflammatory response will result in the remodelling of connective tissue into a dense fibrotic plaque. Penile plaque formation can result in curvature, which, if severe, may prevent vaginal intromission. The most commonly associated comorbidities and risk factors are diabetes, hypertension, lipid abnormalities, ischaemic cardiopathy, erectile dysfunction, smoking, and excessive consumption of alcohol [9]. Dupuytren contracture is more common in patients with Peyronie's disease, affecting 9–39% of patients; 4% of patients with Dupuytren contracture have reported Peyronie's disease (Table 2). Younger men and whites are at increased risk for Peyronie's disease after radical pelvic surgery (eg, radical prostatectomy) [10].

With time, penile curvature is expected either to worsen in 30–50% of patients or stabilise in 47–67% of patients. Spontaneous improvement is reported in only 3–13% of patients [11]. An improvement in penile curvature is more likely to occur in the early stage of disease, rather than in a later phase when the plaque has formed and become densely calcified. Pain is present in 35–45% of patients during the early stage of disease. Pain tends to resolve with time in 90% of men, usually during the first 12 mo after onset (Table 2).

In addition to the physiologic and functional alteration of the penis, validated mental health questionnaires have shown that 48% of men with Peyronie's disease have mild or

**Table 1 – Conclusions on patient evaluation and treatment of congenital penile curvature**

Conclusions	LE
The medical and sexual histories are usually sufficient to establish the diagnosis of congenital penile curvature. Physical examination during erection is useful for documentation of the curvature and exclusion of other pathologies.	3
Surgery is the only treatment option that can be performed at any time in adult life. Plication techniques have been used almost exclusively in cases of isolated penile curvature with high curvature correction rates.	3

LE = level of evidence.

**Table 2 – Conclusions on epidemiology, physiopathology and natural history of Peyronie's disease**

Conclusions	LE
Peyronie's disease is a connective tissue disorder characterised by the formation of a fibrotic lesion or plaque in the tunica albuginea that leads to penile deformity.	2
The contribution of associated comorbidities or risk factors (eg, diabetes, hypertension, lipid abnormalities, and Dupuytren contracture) to the pathophysiology of Peyronie's disease is still unclear.	3
Two phases of the disease can be distinguished. The first phase is the acute inflammatory phase (painful erections, "soft" nodule/plaque), and the second phase is the fibrotic/calcifying phase with formation of hard palpable plaques (disease stabilisation).	2
Spontaneous resolution is uncommon (3–13%), and most patients experience disease progression (30–50%) or stabilisation (47–67%). Pain is usually present during the early stages of the disease but tends to resolve with time in 90% of men.	2
LE = level of evidence.	

moderate depression sufficient to warrant medical evaluation [12].

#### 4.2. Patient evaluation

The aim of the initial evaluation is to provide information on the presenting symptoms and their duration (erectile pain, palpable nodules, curvature, length, rigidity, and girth) and erectile function status.

Patients likely to have active disease are those with short symptom duration, pain during erection, or a recent change in penile curvature. It is often difficult to evaluate whether the inflammatory phase has ended, but resolution of pain and stability of the curvature for at least 3 mo are well-accepted criteria of disease stabilisation and, when indicated, a patient's referral for surgical intervention [11].

Penile examination consists generally of a palpable node or plaque. The whole of the penis should be examined. There is currently no standardised approach for measuring the penis, but it is recommended that the penis be measured dorsally at full stretch from the base of the penis to the tip of the glans. Plaque size is measured in the erect penis. There is no correlation between plaque size and the degree of curvature. The measurement of length during erection is important because it has a direct impact on treatment decisions. Girth-related changes are often self-reported by the patient [13].

Erectile function can be assessed using validated instruments such as the International Index of Erectile Function (IIEF). Erectile dysfunction is mainly due to penile vascular disease, and it has an impact on the treatment strategy [14]. However, it should be noted that IIEF has not been validated specifically in Peyronie's disease patients because it has an impact on the treatment strategy.

Sonographic measurement of the plaque's size is inaccurate and operator dependent, and it is not recommended in everyday clinical practice. Duplex ultrasonography may be required to assess vascular parameters.

An objective assessment of penile curvature with an erection is mandatory. This can be done using a home (self-) photograph of an erection that has either been obtained naturally (preferably) or by using a vacuum-assisted erection test or an intracavernosal injection of a vasoactive agent [13]. Table 3 summarises the recommendations on the evaluation of Peyronie's disease.

#### 4.3. Nonoperative treatment

Conservative treatment of Peyronie's disease is primarily focused on patients in the early stage when symptoms are present and the plaque is not densely fibrotic or calcified [15]. Several nonoperative treatment options have been used (Table 4). No single drug has been approved by the European Medical Association for the treatment of Peyronie's disease. Only potassium para-aminobenzoate (Potaba) has been classified as "possibly effective" by the US Food and Drug Administration for Peyronie's disease.

The results of studies on conservative treatment for Peyronie's disease are often contradictory, making it difficult to provide recommendations in the everyday real-life setting. Table 5 summarises the recommendations on nonoperative treatment of Peyronie's disease.

##### 4.3.1. Oral treatment

**4.3.1.1. Vitamin E.** Vitamin E (tocopherol) is a fat-soluble compound that acts as a natural antioxidant to reduce the number of oxygen-free radicals produced in energy metabolism. It is commonly prescribed by most urologists

**Table 3 – Summary of recommendations on the evaluation of Peyronie's disease**

Guidelines recommendations on the evaluation of Peyronie's disease	LE	GR
Medical and sexual histories in patients with Peyronie's disease must include duration of the disease, penile pain, change of penile deformity, difficulty in vaginal intromission due to deformity, and erectile dysfunction.	2	B
Physical examination must include assessment of palpable nodules, penile length, extent of curvature (self-photograph, vacuum-assisted erection test, or pharmacologically induced erection) and any other possibly related diseases (Dupuytren contracture, Ledderhose disease).	2	B
Sonographic measurement of the plaque's size is inaccurate and operator dependent. It is not recommended in everyday clinical practice.	3	C
Duplex ultrasonography is required to ascertain vascular parameters associated with erectile dysfunction.	2	B
LE = level of evidence; GR = grade of recommendation.		

**Table 4 – Nonoperative treatments for Peyronie's disease**

Oral treatments
Vitamin E
Potassium para-aminobenzoate (Potaba)
Tamoxifen
Colchicine
Acetyl esters of carnitine
Pentoxifylline
Intralesional treatments
Steroids
Verapamil
Clostridial collagenase
Interferon
Topical treatments
Verapamil
Iontophoresis
Extracorporeal shock wave lithotripsy
Traction devices
Vacuum devices

in once- or twice-daily doses of 400 IU because of its wide availability, low cost, and safety. However, a double-blind placebo-controlled crossover study failed to show a significant effect on penile deformity or plaque size [16].

**4.3.1.2. Potassium para-aminobenzoate (Potaba).** Potassium para-aminobenzoate is thought to exert an antifibrotic effect through an increase in oxygen uptake by the tissues, a rise in the secretion of glycosaminoglycans, and enhancement of the activity of monoamine oxidases. In a prospective double-blinded controlled study in 41 patients with Peyronie's disease, penile pain was significantly improved by potassium para-aminobenzoate (12 g/d for 12 mo) but not penile curvature and penile plaque size [17]. In another prospective randomised double-blind placebo-controlled trial in 103 patients with Peyronie's disease, potassium para-aminobenzoate (3 g/d four times daily for 12 mo) decreased penile plaque size significantly but had no effect on penile curvature or penile pain [18].

Treatment-emergent adverse events are nausea, anorexia, pruritus, anxiety, chills, cold sweats, confusion, and difficulty concentrating, but no serious adverse events have been reported.

**4.3.1.3. Tamoxifen.** Tamoxifen is a nonsteroidal oestrogen receptor antagonist. Its proposed mechanism of action in Peyronie's disease involves the modulation of transforming growth factor (TGF) $\beta$ 1 secretion by fibroblasts. A placebo-controlled randomised study was performed in 25 patients in the late stage of Peyronie's disease, with a mean disease duration of 20 mo. Tamoxifen 20 mg twice daily for 3 mo failed to show any significant improvement in pain, curvature, or plaque size [19].

**4.3.1.4. Colchicine.** Colchicine is a medicine often used to treat acute attacks of gout and used in Peyronie's disease on the basis of its anti-inflammatory effect. Preliminary results in 24 men showed that half of the men given colchicine (0.6–1.2 mg daily for 3–5 mo) found that painful erections and penile curvature improved; penile plaque decreased or disappeared in 50% [20]. In another study in 60 men (colchicine 0.5–1 mg daily for 3–5 mo with escalation to 2 mg twice daily), penile pain resolved in 95% and penile curvature improved in 30% [21]. Reported treatment-emergent adverse events with colchicine are gastrointestinal effects (nausea, vomiting, diarrhoea), which can be improved by dose escalation.

The combination of vitamin E and colchicine (600 mg/d and 1 mg every 12 h, respectively) for 6 mo in patients with early-stage Peyronie's disease resulted in a significant improvement in plaque size and curvature, but not in pain compared with ibuprofen 400 mg/d for 6 mo [22].

**4.3.1.5. Acetyl esters of carnitine.** It has been suggested that carnitine can reduce intracellular calcium levels in endothelial cells, which in turn may eventually suppress

**Table 5 – Summary of recommendations on nonoperative treatment of Peyronie's disease**

Guidelines recommendations on nonoperative treatment for Peyronie's disease	LE	GR
Conservative treatment for Peyronie's disease is primarily aimed at treating patients in the early stage of disease. It is an option in patients not fit for surgery or when surgery is not acceptable to the patient.	3	C
Oral treatment with potassium para-aminobenzoate may result in a significant reduction in penile plaque size and penile pain as well as penile curvature stabilisation.	1b	B
Intralesional treatment with verapamil may induce a significant reduction in penile curvature and plaque volume.	1b	C
Intralesional treatment with clostridial collagenase showed significant decreases in the deviation angle, plaque width, and plaque length.	2b	C
Intralesional treatment with interferon may improve penile curvature, plaque size and density, and pain.	1b	B
Topical verapamil gel 15% may improve penile curvature and plaque size.	1b	B
Iontophoresis with verapamil 5 mg and dexamethasone 8 mg may improve penile curvature and plaque size.	1b	B
Extracorporeal shock wave treatment fails to improve penile curvature and plaque size, and it should not be used with this intent but may be beneficial for penile pain.	1b	B
Penile traction devices and vacuum devices may reduce penile deformity and increase penile length.	3	C
Recommendations against treatment	LE	GR
Intralesional treatment with steroids is not associated with a significant reduction in penile curvature, plaque size, or penile pain, and intralesional treatment with steroids can therefore not be recommended.	1b	B
Oral treatment with vitamin E and tamoxifen are not associated with significant reduction in penile curvature, plaque size, or penile pain and therefore should not be used for this purpose.	2b	B
Other oral treatments (acetyl esters of carnitine, pentoxifylline) are not recommended.	3	C

LE = level of evidence; GR = grade of recommendation.

fibroblast proliferation and collagen production, thus reducing penile fibrosis. In a randomised double-blind study in 48 patients with early-stage Peyronie's disease, patients were randomised to acetyl-L-carnitine (1 g twice daily) compared with tamoxifen (20 mg twice daily). After 3 mo, acetyl-L-carnitine was significantly more effective than tamoxifen in reducing pain and curvature and in inhibiting disease progression, but not in reducing penile plaque size (both tamoxifen and carnitine significantly reduced plaque size) [23].

The combination of propionyl-L-carnitine (2 g/d for 3 mo) with intralesional verapamil (10 mg weekly for 10 wk) significantly reduced penile curvature, plaque size, and disease progression compared with intralesional verapamil combined with tamoxifen (40 mg/d) for 3 mo [24].

**4.3.1.6. Pentoxifylline.** Pentoxifylline is a nonspecific phosphodiesterase inhibitor that downregulates TGF $\beta$ 1 and increases fibrinolytic activity. An increase of nitric oxide levels may be effective in preventing the progression of Peyronie's disease or reversing fibrosis. In 62 patients with Peyronie's disease, pentoxifylline treatment for 6 mo appeared to stabilise or reduce calcium content in penile plaques and tended to improve penile curvature [25].

**4.3.1.7. Phosphodiesterase type 5 inhibitors.** The rationale for the use of a phosphodiesterase type 5 (PDE5-I) in Peyronie's disease comes from animal studies showing that they can reduce the collagen/smooth muscle and collagen III/I ratios and increase the apoptotic index in the Peyronie's disease-like plaque [26]. In a retrospective controlled study, daily tadalafil (2.5 mg for 6 mo) resulted in statistically significant ( $p < 0.05$ ) resolution of septal scar in 69% of patients compared with 10% in the control group (no treatment). However, this study included patients with isolated septal scars without evidence of penile deformity [27]. Therefore, no recommendation can be given for PDE5-I in patients with Peyronie's disease.

#### 4.3.2. Intralesional treatment

The injection of pharmacologically active agents directly into the penile plaque results in localised delivery and higher drug concentrations inside the plaque.

**4.3.2.1. Steroids.** Intralesional steroids are thought to act by opposing the inflammatory milieu responsible for Peyronie's plaque progression via inhibition of phospholipase A2 and suppression of the immune response and by decreasing collagen synthesis. In the only single-blind placebo-controlled study with intralesional administration of betamethasone, no statistical significant changes were reported in penile deformity, penile plaque size, and penile pain during erection [28]. Adverse effects include tissue atrophy, thinning of the skin, and immune suppression.

**4.3.2.2. Verapamil.** The rationale for the intralesional use of verapamil (a calcium channel antagonist) in patients with Peyronie's disease is based on *in vitro* data demonstrating the transport of extracellular matrix molecules, including

collagen, fibronectin, and glycosaminoglycans, as a calcium-dependent process, along with a concomitant increase in collagenase activity, modification of the inflammatory response in the early phase of the disorder, and inhibition of fibroblast proliferation in the plaques. In the only randomised placebo-controlled study, no statistical significant differences were reported in plaque size, penile curvature, penile pain during erection, and plaque "softening" [29].

**4.3.2.3. Clostridial collagenase.** Clostridial collagenase is a chromatographically purified bacterial enzyme that selectively attacks collagen, which is known to be the primary component of the Peyronie's disease plaque. In a prospective randomised placebo-controlled double-blind study comparing the effects on plaque size and penile deformity of intralesional purified clostridial collagenase (6000–14 000 U) and saline placebo, the overall response was 36% with clostridial collagenase compared with 4% with placebo ( $p < 0.007$ ) [30]. Follow-up was only 3 mo. Response rates were even higher in patients with smaller plaques and curvature  $< 60^\circ$ . The efficacy of intralesional collagenase injections (three injections of clostridial collagenase, 10 000 U/0.25 cm<sup>3</sup> per injection, administered over 7–10 d and subsequently administered over 7–10 d at 3 mo) was assessed over a non-placebo-controlled short-term follow-up study in a small population of men with Peyronie's disease. Although methodologically biased, this study showed significant decreases from baseline in the deviation angle, plaque width, and plaque length. The most commonly reported side effects were penile pain, contusions, and ecchymosis.

**4.3.2.4. Interferon.** Interferon  $\alpha$ -2b has been shown to decrease fibroblast proliferation, extracellular matrix production, and collagen production from fibroblasts and improve the wound-healing process from Peyronie's disease plaques *in vitro*. Intralesional injections ( $5 \times 10^6$  units of interferon  $\alpha$ -2b in 10 ml saline two times per week for 12 wk) significantly improved penile curvature, plaque size and density, and pain compared with placebo [31]. Side effects include myalgias, arthralgia, sinusitis, fever, and flulike symptoms. These can be effectively treated with nonsteroidal anti-inflammatory drugs before interferon injection.

#### 4.3.3. Topical treatments

**4.3.3.1. Topical verapamil.** In a small randomised placebo-controlled study, topical verapamil (gel 15% applied topically to the penile shaft twice daily) significantly improved penile curvature, plaque size, and penile pain [32]. Treatment results significantly improved after 9 mo compared with 3 mo, showing that a prolonged treatment period may be important. However, there is a lack of evidence that topical verapamil applied to the penile shaft produces adequate levels of active compound within the tunica albuginea.

**4.3.3.2. Iontophoresis.** Iontophoresis (also known as transdermal electromotive drug administration or electromotive drug administration) has been introduced to try and



improve the local uptake of drugs. In a randomised double-blind controlled study, iontophoresis with verapamil 5 mg and dexamethasone 8 mg resulted in a statistically significant improvement in penile curvature and plaque size [33]. However, in another randomised double-blind placebo-controlled study, penile curvature was not statistically improved after iontophoresis with verapamil 10 mg [34]. Iontophoresis is not associated with any significant adverse event.

**4.3.3.3. Extracorporeal shock wave lithotripsy.** The mechanism of action involved in extracorporeal shock wave lithotripsy (ESWL) for Peyronie's disease is still unclear, but there are two hypotheses. In the first hypothesis, ESWL may work by directly damaging and remodelling the penile plaque. In the second hypothesis, ESWL may increase the vascularity of the area by generating heat, resulting in an inflammatory reaction, with increased macrophage activity causing plaque lysis and eventually leading to plaque resorption. In a prospective randomised double-blind placebo-controlled study, four weekly treatment sessions of ESWL, with each session consisting of 2000 focused shock waves, resulted in significant improvement only for penile pain [35].

**4.3.3.4. Traction devices.** The application of continuous traction in Dupuytren contracture increases the activity of degradative enzymes. This initially leads to a loss of tensile strength and ultimately to solubilisation. It is followed by an increase in newly synthesised collagen. This concept has been applied in an uncontrolled study including 10 patients with Peyronie's disease in which the FastSize Penis Extender was applied as the only treatment for 2–8 h/d for 6 mo [36]. Penile curvature reduced in all men from 10° to 45°, with an average reduction of 33% (range: 51–34°). Stretched penile length increased to 0.5–2.0 cm, and erect girth increased to 0.5–1.0 cm, with a correction of the hinge effect in four of four men. There were no adverse events such as skin changes, ulcerations, hypoesthesia, or diminished rigidity.

**4.3.3.5. Vacuum devices.** The application of vacuum devices follows the same principles as traction devices. Their efficacy was assessed in an uncontrolled study (31 patients completed the study) [37]. The study used a vacuum device for 10 min twice daily over a 12-wk period. Penile pain reduced significantly ( $p = 0.012$ ). Stretched penile length also increased significantly ( $p = 0.029$ ) with a mean of 0.5 cm. Reduction of the curvature was reported in 67% of patients; 10% had worsening curvature and 23% showed no change. Half of the patients were satisfied with the outcome, and the remainder had their curvature corrected surgically.

#### 4.4. Surgical treatment

Although conservative treatment for Peyronie's disease should usually resolve painful erections, only a small percentage of men experience significant straightening of the penis. The aim of surgery is to correct curvature and allow satisfactory intercourse. Surgery is indicated only in

patients with stable disease for at least 3 mo, although a 6- to 12-mo period has also been suggested [38].

Specific issues that should be mentioned during patient consent are the risks of penile shortening, erectile dysfunction, penile numbness, the risk of recurrent curvature, the potential for palpation of knots and stitches underneath the skin, and the potential need for circumcision at the time of surgery.

Two major types of repair may be considered for both congenital penile curvature and Peyronie's disease: penile shortening and penile lengthening procedures. Penile shortening procedures include the Nesbit wedge resection and the plication techniques performed on the convex side of the penis. Penile lengthening procedures are performed on the concave side of the penis and require the use of a graft. They aim to minimise penile shortening caused by Nesbit or plication of the tunica albuginea or are used to correct complex deformities. Penile degloving, with associated circumcision to prevent postoperative phimosis, is considered the standard approach for all types of procedures. However, recent data suggest circumcision is not always necessary [39]. Finally, in patients with Peyronie's disease and erectile dysfunction not responding to medical treatments, surgical correction of the curvature with concomitant penile prosthesis implantation should be considered.

There are no standardised questionnaires for the evaluation of surgical outcomes. Data from well-designed prospective studies are scarce, with a low level of evidence. Most data are mainly based on retrospective studies, typically noncomparative and nonrandomised, or on expert opinion.

##### 4.4.1. Penile shortening procedures

In 1965, Nesbit was the first to describe the removal of tunical ellipses opposite a nonelastic corporal segment to treat congenital penile curvature [6]. Fourteen years later, this technique became a successful treatment option for Peyronie's disease [40]. This operation is based on a 5- to 10-mm transverse elliptical excision of the tunica albuginea or approximately 1 mm for each 10° of curvature. The overall short- and long-term results of the Nesbit operation are excellent. Complete penile straightening is achieved in >80% of patients [40]. Recurrence of the curvature and penile hypoesthesia are uncommon (about 10%), and the risk of postoperative erectile dysfunction is minimal. Penile shortening is the most commonly reported outcome of the Nesbit procedure [40]. However, shortening of only 1–1.5 cm has been reported for about 85% of patients, which is rarely the cause for postoperative sexual dysfunction. Patients often perceive the loss of length as greater than it actually is. It is therefore advisable to measure and document the penile length perioperatively, both before and after the straightening procedure, whatever the technique used [13].

Plication procedures use the same principle as the Nesbit operation but are simpler to perform. They are based on single or multiple longitudinal incisions on the convex side of the penis closed in a horizontal way [41]. Another modification has been described as the "16-dot" technique

**Table 6 – Types of grafts used in Peyronie’s disease surgery**

Autologous grafts
Dermis
Vein grafts
Tunica albuginea
Tunica vaginalis
Temporalis fascia
Buccal mucosa
Allografts
Cadaveric pericardium
Cadaveric fascia lata
Cadaveric dura matter
Cadaveric dermis
Xenografts
Porcine small intestinal submucosa
Bovine pericardium
Porcine dermis
Synthetic grafts
Gore-Tex
Dacron

with minimal tension under local anaesthesia [42]. The use of nonabsorbable sutures reduced recurrence of the curvature. Results and satisfaction rates are similar to the Nesbit procedure.

**4.4.2. Penile lengthening procedures**

Tunical lengthening procedures entail an incision in the short (concave) side of the tunica to increase the length of the concave side, creating a tunical defect that is covered by a graft. However, plaque removal may be associated with high rates of postoperative erectile dysfunction due to venous leakage [43].

Table 6 lists the types of grafts used in Peyronie’s disease surgery, and Table 7 reports the results of the different surgical treatments for Peyronie’s disease [44–53].

The risk of erectile dysfunction seems to be greater for penile lengthening procedures. Recurrent curvature implies a failure to wait until the disease has stabilised, a reactivation of the condition following the development of stable disease, or the use of reabsorbable sutures that lose their strength before fibrosis has resulted in an acceptable strength of the repair. Penile numbness is a potential risk of any surgical procedure involving mobilisation of the dorsal neurovascular bundle. Neurapraxia usually occurs due to bruising of the dorsal sensory nerves. Because the usual deformity is a dorsal deformity, the procedure most likely to induce this complication is a lengthening (grafting) procedure for a dorsal deformity.

**4.4.3. Penile prosthesis**

Penile prosthesis implantation is typically reserved for the treatment of Peyronie’s disease in patients with erectile dysfunction, especially when they do not respond to a PDE5-I. Although all types of penile prostheses can be used, implantation of an inflatable penile prosthesis seems to be the most effective in these patients [54].

**4.4.4. Treatment algorithm**

If the degree of curvature is >60° or is a complex curvature, or if the penis is significantly shortened in patients with a good erectile function (with or without pharmacologic treatment), then a grafting procedure is feasible. If there is erectile dysfunction that is not responding to pharmacologic treatment, the best option is the implantation of an inflatable penile prosthesis, with or without an associated procedure over the penis (modelling, plication, or even grafting plus the prosthesis). Table 8 summarises the recommendations on the surgical treatment of Peyronie’s

**Table 7 – Results of surgical treatments for Peyronie’s disease\***

	Tunical shortening procedures		Tunical lengthening procedures
	Nesbit	Plication	Grafts
Penile shortening, %	4.7–30.8	41–90	0–40
Penile straightening, %	79–100	58–100	74–100
Persistent or recurrent curvature, %	4–26.9	7.7–10.6	0–16.7
Postoperative erectile dysfunction, %	0–13	0–22.9	0–15
Penile hypoesthesia, %	2–21	0–21.4	0–16.7
Technical modifications	1	At least 3	Many types of grafts and techniques used

\* Data from different noncomparable studies [44–53].

**Table 8 – Summary of recommendations on surgical treatment of Peyronie’s disease**

Guidelines recommendations on surgical treatment for penile curvature	LE	GR
Surgery is indicated when Peyronie’s disease is stable for at least 3 mo (without pain or deformity deterioration), which is usually the case after 12 mo from the onset of symptoms, and intercourse is compromised due to deformity.	3	C
Penile length, curvature severity, erectile function (including response to pharmacotherapy in case of erectile dysfunction), and patient expectations must be assessed prior to surgery.	3	C
Tunical shortening procedures, especially plication techniques, are the first treatment options for congenital penile curvature and for Peyronie’s disease with adequate penile length, curvature <60°, and absence of special deformities (hourglass, hinge).	2b	B
Grafting techniques are the preferred treatment option for patients with Peyronie’s disease with no adequate penile length, curvature >60°, and presence of special deformities (hourglass, hinge).	2b	B
Penile prosthesis implantation, with or without any additional procedure (modelling, plication, or grafting), is recommended in Peyronie’s disease patients with erectile dysfunction not responding to pharmacotherapy.	2b	B

LE = level of evidence; GR = grade of recommendation.

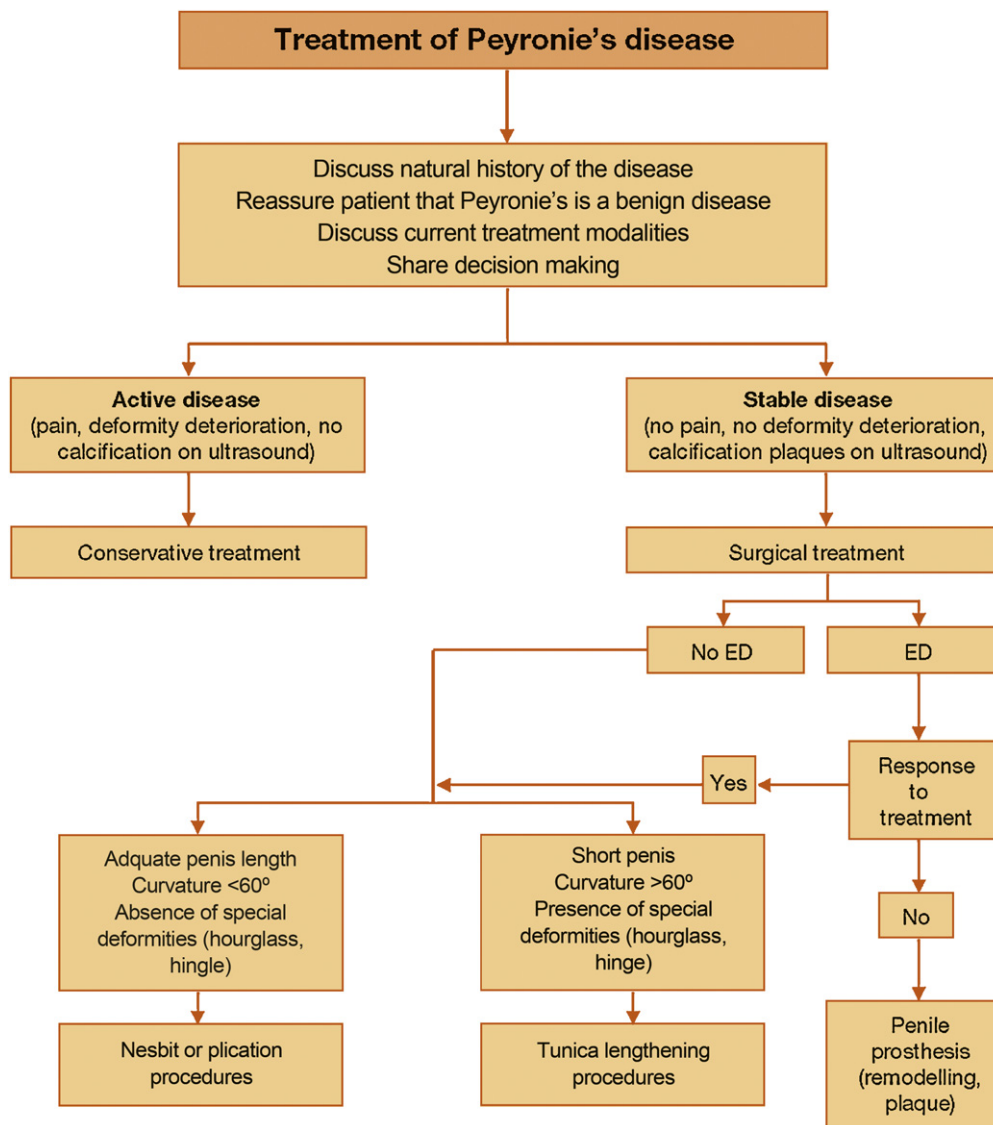


Fig. 1 – Treatment algorithm for Peyronie's disease. ED = erectile dysfunction.

disease, and the proposed treatment algorithm is presented in Figure 1.

**Author contributions:** Konstantinos Hatzimouratidis had full access to all the data in the study and takes responsibility for the integrity of the data and the accuracy of the data analysis.

**Study concept and design:** Hatzimouratidis, Wespes.

**Acquisition of data:** Hatzimouratidis, Eardley, Giuliano, Hatzichristou, Moncada, Salonia, Vardi, Wespes.

**Analysis and interpretation of data:** Hatzimouratidis, Wespes.

**Drafting of the manuscript:** Hatzimouratidis, Wespes.

**Critical revision of the manuscript for important intellectual content:** Hatzimouratidis, Eardley, Giuliano, Hatzichristou, Moncada, Salonia, Vardi, Wespes.

**Statistical analysis:** None.

**Obtaining funding:** None.

**Administrative, technical, or material support:** Hatzimouratidis, Wespes.

**Supervision:** Hatzimouratidis, Wespes.

**Other (specify):** None.

**Financial disclosures:** Konstantinos Hatzimouratidis certifies that all conflicts of interest, including specific financial interests and relationships and affiliations relevant to the subject matter or materials discussed in the manuscript (eg, employment/affiliation, grants or funding, consultancies, honoraria, stock ownership or options, expert testimony, royalties, or patents filed, received, or pending), are the following: Konstantinos Hatzimouratidis receives company speaker honoraria and participates in trials for Lilly. Eric Wespes is a company consultant for Pfizer, Bayer, and Lilly. Ian Eardley receives company speaker honoraria from Recordati, Lilly, and Bayer Schering. He participates in trials for Pfizer, Lilly, Allergan, and Johnson & Johnson.



François Giuliano is a company consultant for Pfizer, Johnson & Johnson, Bayer, Lilly, and Pfizer. He receives company speaker honoraria from Lilly, Pfizer, Johnson & Johnson, and Sanofi-Aventis and participates in trials for Eli Lilly and Pfizer. He receives research grants from Bayer-Schering, Aeterna-Zentaris, Sanofi-Aventis, Spectrum, DSP, and Johnson & Johnson. Dimitrios Hatzichristou has nothing to declare. Ignacio Moncada is a company consultant and receives company speaker honoraria from Lilly and Bayer. He also receives company speaker honoraria from GSK and AMS and participates in trials for Lilly, Bayer, and Auxilium. Andrea Salonia is a company consultant for Bayer Schering Pharma, Eli Lilly Italy, and Pierre Fabre. Yoram Vardi has equity interests in Pfizer, Lilly, and Bayer.

**Funding/Support and role of the sponsor:** None.

## References

- [1] Musitelli S, Bossi M, Jallous H. A brief historical survey of "Peyronie's disease". *J Sex Med* 2008;5:37–46.
- [2] Montag S, Palmer LS. Abnormalities of penile curvature: chordee and penile torsion. *Sc World J* 2011;11:1470–8.
- [3] Darewicz B, Kudelski J, Szyńska B, Nowak HF, Darewicz J. Ultrastructure of the tunica albuginea in congenital penile curvature. *J Urol* 2001;166:1766–8.
- [4] Ebbehøj J, Metz P. Congenital penile angulation. *Br J Urol* 1987;60:264–6.
- [5] Bar Yosef Y, Binyamini J, Matzkin H, Ben-Chaim J. Midline dorsal plication technique for penile curvature repair. *J Urol* 2004;172:1368–9.
- [6] Nesbit RM. Congenital curvature of the phallus: report of three cases with description of corrective operation. *J Urol* 1965;93:230–2.
- [7] Sommer F, Schwarzer U, Wassmer G, et al. Epidemiology of Peyronie's disease. *Int J Impot Res* 2002;14:379–83.
- [8] Gonzalez-Cadavid NF, Rajfer J. Mechanisms of disease: new insights into the cellular and molecular pathology of Peyronie's disease. *Nat Clin Pract Urol* 2005;2:291–7.
- [9] Rhoden EL, Riedner CE, Fuchs SC, Ribeiro EP, Halmenschlager G. A cross-sectional study for the analysis of clinical, sexual and laboratory conditions associated to Peyronie's disease. *J Sex Med* 2010;7:1529–37.
- [10] Tal R, Heck M, Teloken P, Siegrist T, Nelson CJ, Mulhall JP. Peyronie's disease following radical prostatectomy: incidence and predictors. *J Sex Med* 2010;7:1254–61.
- [11] Bekos A, Arvaniti M, Hatzimouratidis K, Moysidis K, Tzortzis V, Hatzichristou D. The natural history of Peyronie's disease: an ultrasonography-based study. *Eur Urol* 2008;53:644–51.
- [12] Nelson CJ, Diblasio C, Kendirci M, Hellstrom W, Guhring P, Mulhall JP. The chronology of depression and distress in men with Peyronie's disease. *J Sex Med* 2008;5:1985–90.
- [13] Levine LA, Greenfield JM. Establishing a standardized evaluation of the man with Peyronie's disease. *Int J Impot Res* 2003;15(Suppl 5):S103–12.
- [14] Greenfield JM, Lucas S, Levine LA. Factors affecting the loss of length associated with tunica albuginea plication for correction of penile curvature. *J Urol* 2006;175:238–41.
- [15] Hellstrom WJ. Medical management of Peyronie's disease. *J Androl* 2009;30:397–405.
- [16] Pryor JP, Farell CF. Controlled clinical trial of vitamin E in Peyronie's disease. *Prog Reprod Biol* 1983;9:41–5.
- [17] Shah PJR, Green NA, Adib RS, Hamilton Stewart PA, Smith P, Coxon R. A multicentre double-blind controlled clinical trial of potassium para-amino-benzoate (POTABA) in Peyronie's disease. *Progr Reprod Biol Med J* 1983;9:61–7.
- [18] Weidner W, Hauck EW, Schnitker J. Potassium paraaminobenzoate (POTABA) in the treatment of Peyronie's disease: a prospective, placebo-controlled, randomized study. *Eur Urol* 2005;47:530–6, discussion 535–6.
- [19] Teloken C, Rhoden EL, Graziotin TM, Ros CT, Sogari PR, Souto CA. Tamoxifen versus placebo in the treatment of Peyronie's disease. *J Urol* 1999;162:2003–5.
- [20] Kadioglu A, Tefekli A, Koksalt T, Usta M, Erol H. Treatment of Peyronie's disease with oral colchicine: long-term results and predictive parameters of successful outcome. *Int J Impot Res* 2000;12:169–75.
- [21] Akkus E, Carrier S, Rehman J, Breza J, Kadioglu A, Lue TF. Is colchicine effective in Peyronie's disease? A pilot study. *Urology* 1994;44:291–5.
- [22] Prieto Castro RM, Leva Vallejo ME, Regueiro Lopez JC, Anglada Curado FJ, Alvarez Kindelan J, Requena Tapia MJ. Combined treatment with vitamin E and colchicine in the early stages of Peyronie's disease. *BJU Int* 2003;91:522–4.
- [23] Biagiotti G, Cavallini G. Acetyl-L-carnitine vs tamoxifen in the oral therapy of Peyronie's disease: a preliminary report. *BJU Int* 2001;88:63–7.
- [24] Cavallini G, Biagiotti G, Koverech A, Vitali G. Oral propionyl-L-carnitine and intraplaque verapamil in the therapy of advanced and resistant Peyronie's disease. *BJU Int* 2002;89:895–900.
- [25] Brant WO, Dean RC, Lue TF. Treatment of Peyronie's disease with oral pentoxifylline. *Nat Clin Pract Urol* 2006;3:111–5, quiz 116.
- [26] Ferrini MG, Kovanez I, Nolzaco G, Rajfer J, Gonzalez-Cadavid NF. Effects of long-term vardenafil treatment on the development of fibrotic plaques in a rat model of Peyronie's disease. *BJU Int* 2006;97:625–33.
- [27] Chung E, Deyoung L, Brock GB. The role of PDE5 inhibitors in penile septal scar remodeling: assessment of clinical and radiological outcomes. *J Sex Med* 2011;8:1472–7.
- [28] Cipollone G, Nicolai M, Mastroprimiano G, Iantorno R, Longeri D, Tenaglia R. Betamethasone versus placebo in Peyronie's disease [in Italian]. *Arch Ital Urol Androl* 1998;70:165–8.
- [29] Shirazi M, Haghpanah AR, Badiie M, Afrasiabi MA, Haghpanah S. Effect of intralesional verapamil for treatment of Peyronie's disease: a randomized single-blind, placebo-controlled study. *Int Urol Nephrol* 2009;41:467–71.
- [30] Gelbard MK, James K, Riach P, Dorey F. Collagenase versus placebo in the treatment of Peyronie's disease: a double-blind study. *J Urol* 1993;149:56–8.
- [31] Hellstrom WJ, Kendirci M, Matern R, et al. Single-blind, multicenter, placebo controlled, parallel study to assess the safety and efficacy of intralesional interferon alpha-2B for minimally invasive treatment for Peyronie's disease. *J Urol* 2006;176:394–8.
- [32] Fitch 3rd WP, Easterling WJ, Talbert RL, Bordovsky MJ, Mosier M. Topical verapamil HCl, topical trifluoperazine, and topical magnesium sulfate for the treatment of Peyronie's disease—a placebo-controlled pilot study. *J Sex Med* 2007;4:477–84.
- [33] Di Stasi SM, Giannantoni A, Stephen RL, et al. A prospective, randomized study using transdermal electromotive administration of verapamil and dexamethasone for Peyronie's disease. *J Urol* 2004;171:1605–8.
- [34] Greenfield JM, Shah SJ, Levine LA. Verapamil versus saline in electromotive drug administration for Peyronie's disease: a double-blind, placebo controlled trial. *J Urol* 2007;177:972–5.
- [35] Palmieri A, Imbimbo C, Longo N, et al. A first prospective, randomized, double-blind, placebo-controlled clinical trial evaluating extracorporeal shock wave therapy for the treatment of Peyronie's disease. *Eur Urol* 2009;56:363–70.
- [36] Levine LA, Newell M, Taylor FL. Penile traction therapy for treatment of Peyronie's disease: a single-center pilot study. *J Sex Med* 2008;5:1468–73.

- [37] Raheem AA, Garaffa G, Raheem TA, et al. The role of vacuum pump therapy to mechanically straighten the penis in Peyronie's disease. *BJU Int* 2010;106:1178–80.
- [38] Hellstrom WJ, Bivalacqua TJ. Peyronie's disease: etiology, medical, and surgical therapy. *J Androl* 2000;21:347–54.
- [39] Garaffa G, Sacca A, Christopher AN, Ralph DJ. Circumcision is not mandatory in penile surgery. *BJU Int* 2010;105:222–4.
- [40] Pryor JP. Correction of penile curvature and Peyronie's disease: why I prefer the Nesbit technique. *Int J Impot Res* 1998;10:129–31.
- [41] Sassine AM, Wespes E, Schulman CC. Modified corporoplasty for penile curvature: 10 years' experience. *Urology* 1994;44:419–21.
- [42] Gholami SS, Lue TF. Correction of penile curvature using the 16-dot plication technique: a review of 132 patients. *J Urol* 2002;167:2066–9.
- [43] Dalkin BL, Carter MF. Venogenic impotence following dermal graft repair for Peyronie's disease. *J Urol* 1991;146:849–51.
- [44] Devine Jr CJ, Horton CE. Surgical treatment of Peyronie's disease with a dermal graft. *J Urol* 1974;111:44–9.
- [45] El-Sakka AI, Rashwan HM, Lue TF. Venous patch graft for Peyronie's disease. Part II: outcome analysis. *J Urol* 1998;160:2050–3.
- [46] Hatzichristou DG, Hatzimouratidis K, Apostolidis A, Tzortzis V, Bekos A, Ioannidis E. Corporoplasty using tunica albuginea free grafts for penile curvature: surgical technique and long-term results. *J Urol* 2002;167:1367–70.
- [47] Gelbard MK, Hayden B. Expanding contractures of the tunica albuginea due to Peyronie's disease with temporalis fascia free grafts. *J Urol* 1991;145:772–6.
- [48] Cormio L, Zucchi A, Lorusso F, et al. Surgical treatment of Peyronie's disease by plaque incision and grafting with buccal mucosa. *Eur Urol* 2009;55:1469–76.
- [49] Fallon B. Cadaveric dura mater graft for correction of penile curvature in Peyronie disease. *Urology* 1990;35:127–9.
- [50] Knoll LD. Use of porcine small intestinal submucosal graft in the surgical management of Peyronie's disease. *Urology* 2001;57:753–7.
- [51] Faerber GJ, Konnak JW. Results of combined Nesbit penile plication with plaque incision and placement of Dacron patch in patients with severe Peyronie's disease. *J Urol* 1993;149:1319–20.
- [52] Chun JL, McGregor A, Krishnan R, Carson CC. A comparison of dermal and cadaveric pericardial grafts in the modified Horton-Devine procedure for Peyronie's disease. *J Urol* 2001;166:185–8.
- [53] Taylor FL, Levine LA. Surgical correction of Peyronie's disease via tunica albuginea plication or partial plaque excision with pericardial graft: long-term follow up. *J Sex Med* 2008;5:2221–8, discussion 2229–30.
- [54] Wilson SK. Surgical techniques: modeling technique for penile curvature. *J Sex Med* 2007;4:231–4.

**UROLOGY  
WEEK 2012**

[www.urologyweek.org](http://www.urologyweek.org)

Urology Week is an initiative of the European Association of Urology, which brings together national urological societies, urology experts and patient groups with the aim to build awareness of prostate conditions among the general public. Every year, various educational and media events take place during this week throughout Europe. If you would like to organise an event in your country or find out more, please visit the official website of this initiative.

**STEP UP!**  
Join the campaign  
17-21 September

facebook

twitter

LinkedIn



This year's focus will be on patient education and awareness of prostate conditions.  
Join us in September 2012 – bring Urology Week to your country.

**eau**  
European  
Association  
of Urology