



European Association of Urology

# **GUIDELINES ON PAEDIATRIC UROLOGY**

H. Riedmiller, P. Androulakakis, D. Beurton, R. Kocvara, U. Köhl

# TABLE OF CONTENTS

page

1. Phimosis	5
1.1 Background	5
1.2 Diagnosis	5
1.3 Treatment	5
1.4 References	5
2. Cryptorchidism	7
2.1 Background	7
2.2 Diagnosis	7
2.3 Treatment	7
2.4 References	8
3. Hypospadias	11
3.1 Background	11
3.2 Diagnosis	11
3.3 Treatment	11
3.3.1 Complications	12
3.4 References	13
4. Incontinence	15
4.1 Background	15
4.2 Classification	15
4.2.1 Enuresis	15
4.2.2 Urinary incontinence	15
4.3 Diagnosis	16
4.4 Treatment	16
4.4.1 Nocturnal enuresis	16
4.4.2 Diurnal enuresis	16
4.4.3 Urinary incontinence	16
4.4 References	17
5. Dilatation of the upper urinary tract	19
5.1 Background	19
5.2 Diagnosis	19
5.2.1 Ultrasound examination	19
5.2.2 Voiding cystourethrography	19
5.2.3 Diuresis renography	19
5.2.4 Static renal scintigraphy	19
5.2.5 Intravenous urogram	19
5.2.6 Whitaker's test	19
5.3 Treatment	20
5.3.1 UPJ-stenosis	20
5.3.2 Megaureter	20
5.3.3 Ureterocele	20
5.3.4 Retrocaval ureter	21
5.3.5 Bilateral hydronephrosis	21
5.4 References	22
6. Urinary tract infection (UTI)	24
6.1 Classification	24
6.2 Diagnosis	24
6.3 Treatment	24
6.3.1 Asymptomatic bacteriuria	24
6.3.2 Acute UTI without pyelonephritis	25
6.3.3 Pyelonephritis	25
6.3.4 Complicated UTI	25
6.3.5 Antibiotic prophylaxis	25
6.4 References	25

7. Reflux	27
7.1 Background	27
7.1.1 Secondary reflux	27
7.2 Classification	27
7.3 Diagnosis	27
7.3.1 Secondary reflux	28
7.4 Treatment	29
7.4.1 Conservative therapy	29
7.4.2 Surgical therapy	29
7.4.3 Endoscopic therapy	29
7.4.4 Open surgery	29
7.4.5 Follow-up	30
7.5 References	30
8. Paediatric nephrolithiasis	33
8.1 Background	33
8.2 Diagnosis	33
8.3 Treatment	33
8.3.1 Conservative treatment	34
8.3.2 Metaphylaxis of paediatric nephrolithiasis	34
8.4 References	34
9. Obstructive pathology of renal duplications: ureterocele and ectopic ureter	37
9.1 Background	37
9.1.1 Ureterocele	37
9.1.2 Ectopic ureter	37
9.2 Classification	37
9.2.1 Ectopic ureterocele	37
9.2.2 Orthotopic ureterocele	37
9.2.3 Caecoureterocele	37
9.3 Diagnosis	38
9.3.1 Ureterocele	38
9.3.2 Ectopic ureter	38
9.4 Treatment	38
9.4.1 Ureterocele	38
9.4.2 Ectopic ureter	39
9.5 References	39
10. Intersex (abnormal sexual differentiation)	41
10.1 Background	41
10.2 Classification	42
10.2.1 Female pseudohermaphrodite	43
10.2.2 Male pseudohermaphrodite	43
10.2.3 True hermaphrodite	43
10.2.4 Mixed gonadal dysgenesis	43
10.2.5 Pure gonadal dysgenesis	43
10.3 Diagnosis	43
10.3.1 The neonatal emergency	43
10.3.2 Late diagnosis and management	44
10.4 Treatment	45
10.4.1 Genitoplasty	45
10.4.2 Indications for the removal of gonads	45
10.5 References	45
11. Urodynamics	47
11.1 Standardization of investigations	47
11.1.1 Residual urine	47
11.1.2 Uroflowmetry	47
11.1.3 Cystometry	47

11.1.4 Video-urodynamic evaluation	47
11.1.5 Urethral pressure profile (sphincterometry)	48
11.1.6 Electromyography of the external sphincter	48
11.2 References	48
12. Abbreviations used in the text	50

# 1. PHIMOSIS

## 1.1 BACKGROUND

At the end of the first year of life, retraction of the foreskin behind the glandular sulcus is possible in only about 50% of boys; this rises to approximately 89% by the age of three. The incidence of phimosis is 8% in 6- to 7-year-olds and just 1% in males aged 16 to 18 years.

Paraphimosis must be regarded as an emergency situation: retraction of a too narrow prepuce behind the glans penis into the glandular sulcus may interfere with perfusion of the preputial surface distally from the constrictive ring and possibly of the glans penis with the risk of consecutive necrosis.

## 1.2 DIAGNOSIS

If the prepuce is not or only partly retractable, or shows a constrictive ring on drawing back over the glans penis, a disproportion between the width of the foreskin and the diameter of the glans penis has to be assumed. In addition to the constricted foreskin, there may be adhesions between the inner surface of the prepuce and the glandular epithelium and/or a frenulum breve. A frenulum breve leads to a ventral deviation of the glans once the foreskin is retracted.

The diagnosis of paraphimosis is made by physical examination.

## 1.3 TREATMENT

Treatment of phimosis in children is dependent on parents' preferences and can be plastic or radical circumcision after completion of the second year of life. In case of complicating findings, such as recurrent urinary tract infections (UTIs) or ballooning of the foreskin during micturition, circumcision should be performed without delay regardless of the patient's age. Plastic circumcision has the objective of achieving a widening of the foreskin circumference with full retractability, while the foreskin is preserved cosmetically. In the same session, adhesions are released and an associated frenulum breve is corrected by frenulotomy with ligation of the frenular artery. Routine neonatal circumcision to prevent penile carcinoma is not indicated. Contraindications of the operation are acute local infection and congenital anomalies of the penis, particularly hypospadias, as the foreskin may be required for plastic correction.

As a conservative treatment option, a corticoid ointment (0.05–0.1%) can be administered twice a day over a period of 20–30 days. This treatment is not indicated in babies and children still wearing diapers, but may be considered around the third year of life.

Treatment of paraphimosis consists of manual compression of the oedematous tissue with the subsequent attempt to retract the tightened foreskin over the glans penis. If this manoeuvre fails, a dorsal incision of the constrictive ring is required. Depending on the local findings, a circumcision is carried out immediately or can be performed in a second session.

## 1.4 REFERENCES

1. **American Academy of Pediatrics Task Force on Circumcision.**  
Report of the Task Force on Circumcision. *Pediatrics* 1989; 84: 388–391.
2. **Baskin LS, Canning DA, Snyder HM III, Duckett JW.**  
Surgical repair of urethral circumcision injuries. *J Urol* 1997; 158: 2269–2271.
3. **Baskin LS, Canning DA, Snyder HM, Duckett JW.**  
Treating complications of circumcision. *Pediatr Emerg Care* 1996; 12: 62–68.
4. **Cansever G.**  
Psychological effects of circumcision. *Brit J Med Psychol* 1965; 38: 321–331.
5. **Christensen-Szalamski JJ, Boyce WT, Harrell H, Gardner MM.**  
Circumcision and informed consent. Is more always better? *Med Care* 1987; 25: 856–867.
6. **Goepel M, P Rathert.**  
Leitlinie zur Phimose. *Urologe A*, 1998; 37: 664–665.
7. **Griffiths DM, Atwell JD, Freeman NV.**  
A prospective study of the indications and morbidity of circumcision in children. *Eur Urol* 1985; 11: 184–187.

8. **Maxwell LG, Yaster M.**  
Analgesia for neonatal circumcision: no more studies, just do it [editorial comment].  
*Arch Pediatr Adolesc Med* 1999; 153: 444–445.
9. **Moses S, Bailey RC, Ronald AR.**  
Male circumcision: assessment of health benefits and risks. *Sex Transm Infect* 1998; 74: 368–373.
10. **Niku SD, Stock JA, Kaplan GW.**  
Neonatal circumcision. *Urol Clin North Am* 1995; 22: 57–65.
11. **Preston EN.**  
Whither the foreskin? *JAMA* 1970; 213: 1853–1858.
12. **Schoen EJ.**  
The status of circumcision of newborns. *New Engl J Med* 1990; 322: 1308–1312.
13. **Schoen EJ.**  
Advantages and disadvantages of neonatal circumcision [letter]. *JAMA* 1997; 278: 201.
14. **Taylor JR, Lockwood AP, Taylor AJ.**  
The prepuce: specialized mucosa of the penis and its loss to circumcision. *Br J Urol* 1996; 77: 291–295.
15. **To T, Agaha M, Dick PT, Feldman W.**  
Cohort study on circumcision of newborn boys and subsequent risk of urinary tract infection. *Lancet* 1998; 352: 1813–1816.
16. **Upadhyay V, Hammodat HM, Pease PH.**  
Post-circumcision meatal stenosis. *N Z Med J* 1998; 111: 57–58.
17. **Van Howe RS.**  
Cost-effective treatment of phimosis. *Pediatrics* 1998; 102: E43.
18. **Wallerstein E.**  
Circumcision. The uniquely American medical enigma. *Urol Clin North Am* 1985; 12: 123–132.
19. **Williams N, Kapila L.**  
Complications of circumcision. *Br J Surg* 1993; 80: 1231–1236.
20. **Wiswell TE, Geschke DW.**  
Risks from circumcision during the first month of life compared with those for uncircumcised boys.  
*Pediatrics* 1989; 83: 1011–1015.
21. **Wiswell TE, Tencer HL, Welch CA, Chamberlain JL.**  
Circumcision in children beyond the neonatal period. *Pediatrics* 1993; 92: 791–793.

## 2. CRYPTORCHIDISM

### 2.1 BACKGROUND

The incidence of maldescensus testis after the first year of life is 1.8–2%. A distinction is made between abdominal, inguinal or prescrotal testis retention and epifascial, femoral or penodorsal testis ectopy. Sliding and pendulous (retractile) testes are particular variations of cryptorchidism. Sliding testis with a too short spermatic cord relocates into its non-physiological position when pulled into the scrotum and then released. Pendulous (retractile) testis with hypertrophic cremaster muscle fibres is associated with an intermittent retraction of the usually orthotopic testis.

### 2.2 DIAGNOSIS

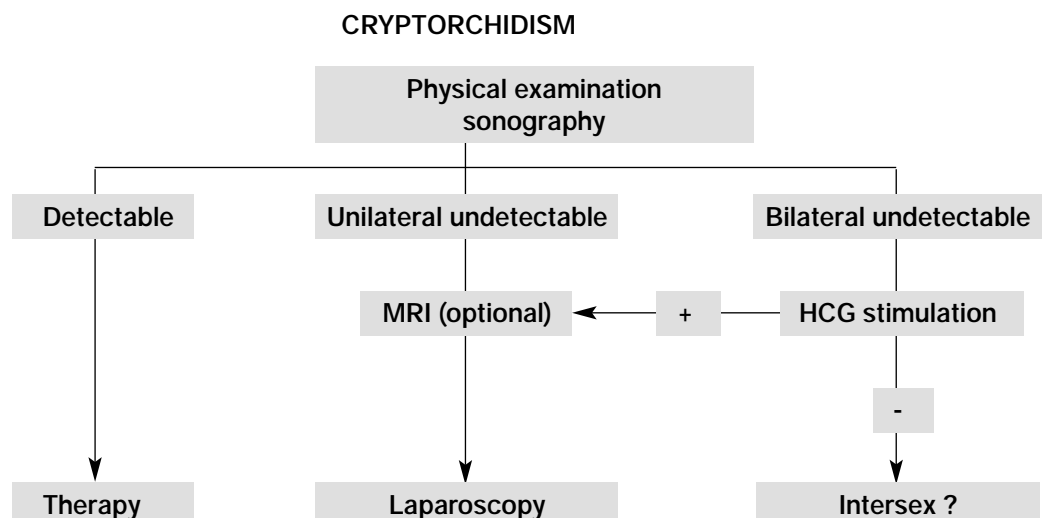
Maldescensus testis is diagnosed by clinical examination and sonography. Sonography and magnetic resonance imaging (MRI) may help in localizing the impalpable testis; the accuracy of the latter is 90% for intra-abdominal testis. Once abdominal retention is suspected, laparoscopy has been established as a diagnostic and therapeutic procedure. In this procedure, the testis can be localized in its abdominal position and placed scrotally using the technique appropriate to the anatomical conditions. A human chorionic gonadotrophin (HCG) stimulation test, as evidence of testosterone-producing testis tissue, should precede operative exploration for bilaterally impalpable testes.

### 2.3 TREATMENT

The objective of treatment is to achieve an orthotopic scrotal position of the testis, before the child's second birthday, in order to prevent irreversible damage of spermatogenesis in the affected testis. Hormone therapy (optional) is applied for testis retention only. It is ineffective for ectopy, but can be helpful for preparation of local tissue: HCG as an intramuscular injection (9000–30,000 IU in different protocols) or luteinizing hormone releasing hormone (LHRH) as a nasal spray (400 µg, three times daily). Both methods are effective in about 20–30% of cases. Follow-up is important because the benefits may fail after a period of time.

Surgical orchidofuniculolysis and orchidopexy are first-line treatment options. Pendulous (retractile) testes are not indicated for surgical repair. Absolute indications for a primary surgical approach are testis retention after failed hormone therapy or after previous inguinal surgery, testis ectopy and all maldescended testes with associated pathology (hernia and/or open processus vaginalis). Inguinal access of the spermatic cord is gained after opening the inguinal canal. Associated pathological conditions (open processus vaginalis, inguinal hernia) are dealt with in the same session. After the spermatic chord and testis have been freed of connective tissue and cremaster fibres have been resected, the testis is relocated tension free by pexis in the scrotum. If no testis or spermatic funicle tissue can be found during exploration of the inguinal canal, opening of the peritoneum and intraperitoneal orchidofuniculolysis is performed. If the spermatic funicle is too short, the Fowler-Stephens technique (ligation and dissection of the spermatic vessels) can be applied. Pre-conditions are intact deferent duct and epididymis vessels; these are tested by a temporary clamping of the testicular artery. In rare cases, auto-transplantation by microsurgical anastomosis of the testis vessels with the epigastric vasculature can be considered.

Table 1: Management of cryptorchidism



## 2.4 REFERENCES

1. **Alaish SM, Stylianos S.**  
Diagnostic laparoscopy. *Curr Opin Pediatr* 1998; 10: 323–327
2. **Arnbjornsson E, Mikaelsson C, Lindhagen T, Ivarsson SA.**  
Laparoscopy for non-palpable testis in childhood: is inguinal exploration necessary when vas and vessels are not seen? *Eur J Pediatr Surg* 1996; 6: 7–9.
3. **Balaji KC, Diamond DA.**  
Laparoscopic diagnosis and management of transverse testicular ectopia. *Urology* 1995; 46: 879–880.
4. **Bourguignon JP, Vanderschueren Lodeweyckx M.**  
Hormonal treatment of cryptorchidism: lessons from 15 years of worldwide experience. *Acta Urol Belg* 1995; 63: 77–81.
5. **Brown RA, Millar AJ, Jee LD, Cywes C.**  
The value of laparoscopy for impalpable testes. *S Afr J Surg* 1997; 35: 70–73.
6. **Bukowski TP, Wacksman J, Billmire DA, Lewis AG, Sheldon CA.**  
Testicular auto-transplantation: a 17-year review of an effective approach to the management of the intra-abdominal testis [see comments]. *J Urol* 1995; 154: 558–561.
7. **Caldamone AA, Amaral JF.**  
Laparoscopic stage 2 Fowler-Stephens orchiopexy. *J Urol* 1994; 152: 1253–1256.
8. **Canavese F, Cortes MG, Magro P, Lonati L, Teruzzi E, de Sanctis C, Lala R.**  
Cryptorchidism: medical and surgical treatment in the 1st year of life. *Pediatr Surg Int* 1998; 14: 2–5.
9. **Cortes D.**  
Cryptorchidism — aspects of pathogenesis, histology and treatment. *Scand J Urol Nephrol Suppl* 1998; 196: 1–54.
10. **Cortes D, Thorup JM, Lenz K, Beck BL, Neilsen OH.**  
Laparoscopy in 100 consecutive patients with 128 impalpable testes. *Br J Urol* 1995; 75: 281–287.
11. **Davenport M.**  
ABC of general paediatric surgery. Inguinal hernia, hydrocele, and the undescended testis. *BMJ* 1996; 312: 564–567.
12. **Davenport M, Brain C, Vandenberg C, Zappala S, Duffy P, Ransley PG, Grant D.**  
The use of the hCG stimulation test in the endocrine evaluation of cryptorchidism. *Br J Urol* 1995; 76: 790–794.
13. **De Boe V, De Backer A, Braeckman J.**  
Laparoscopy: any indication in the work-up and treatment of undescended testis? *Acta Urol Belg* 1995; 63: 89–91.
14. **Docimo SG.**  
The results of surgical therapy for cryptorchidism: a literature review and analysis. *J Urol* 1995; 154: 1148–1152.
15. **Duckett JW.**  
Pediatric laparoscopy: prudence, please [editorial]. *J Urol* 1994; 151: 742–743.



16. **Esposito C, Garipoli V.**  
The value of 2-step laparoscopic Fowler-Stephens orchiopexy for intra-abdominal testes [see comments]. *J Urol* 1997; 158: 1952–1954.
17. **Fahlenkamp D, Winfield HN, Schonberger B, Mueller W, Loening SA.**  
Role of laparoscopic surgery in pediatric urology. *Eur Urol* 1997; 32: 75–84.
18. **Fedder J, Boesen M.**  
Effect of a combined GnRH/hCG therapy in boys with undescended testicles: evaluated in relation to testicular localization within the first week after birth. *Arch Androl* 1998; 40: 181–186.
19. **Ferro F, Lais A, Gonzalez Serva L.**  
Benefits and afterthoughts of laparoscopy for the non-palpable testis. *J Urol* 1996; 156: 795–798.
20. **Gill B, Kogan S.**  
Cryptorchidism. Current concepts. *Pediatr Clin North Am* 1997; 44: 1211–1227.
21. **Gordon N.**  
Undescended testes: screening and early operation. *Br J Clin Pract* 1995; 49: 318–320.
22. **Hadziselimovic F.**  
Cryptorchidism: the disease and its management. *Acta Urol Belg* 1995; 63: 83–88.
23. **Hadziselimovic F, Herzog B.**  
Treatment with a luteinizing hormone-releasing hormone analogue after successful orchiopexy markedly improves the chance of fertility later in life. *J Urol* 1997; 158: 1193–1195.
24. **Hamm B.**  
Sonography of the testis and epididymis. *Andrologia* 1994; 26: 193–210.
25. **Kiely EA.**  
Scientific basis of testicular descent and management implications for cryptorchidism. *Br J Clin Pract* 1994; 48: 37–41.
26. **King LR.**  
Orchiopexy for impalpable testis: high spermatic vessel division is a safe maneuver. *J Urol* 1998; 160: 2457–2460.
27. **Lam WW, Tam PK, Ai VH, Chan KL, Cheng W, Chan FL, Leong L.**  
Gadolinium-infusion magnetic resonance angiogram: a new, noninvasive, and accurate method of preoperative localization of impalpable undescended testes. *J Pediatr Surg* 1998; 33: 123–126.
28. **Lee PA.**  
Consequence of cryptorchidism: relationship to etiology and treatment. *Curr Probl Pediatr* 1995; 25: 232–236.
29. **Maddern GJ, Sutherland PD.**  
Laparoscopic exploration for a presumed intra-abdominal testicle. *Endosc Surg Allied Technol* 1994; 2: 293.
30. **McAleer IM, Packer MG, Kaplan GW, Scherz HC, Krous HF, Billman GF.**  
Fertility index analysis in cryptorchidism. *J Urol* 1995; 153: 1255–1258.
31. **Nane I, Ziyilan O, Esen T, Kocak T, Ander H, Tellaloglu S.**  
Primary gonadotropin releasing hormone and adjunctive human chorionic gonadotropin treatment in cryptorchidism: a clinical trial. *Urology* 1997; 49: 108–111.
32. **Nguyen HT, Coakley F, Hricak H.**  
Cryptorchidism: strategies in detection. *Eur Radiol* 1999; 9: 336–343.
33. **O'Hali W, Anderson P, Giacomantonio M.**  
Management of impalpable testes: indications for abdominal exploration. *J Pediatr Surg* 1997; 32: 918–920.
34. **Palmer LS, Gill B, Kogan SJ.**  
Endocrine analysis of childhood monorchism. *J Urol* 1997; 158: 594–596.
35. **Polascik TJ, Chan-Tack KM, Jeffs RD, Gearhart JP.**  
Reappraisal of the role of human chorionic gonadotropin in the diagnosis and treatment of the non-palpable testis: a 10-year experience. *J Urol* 1996; 156: 804–806.
36. **Puri P, Nixon HH.**  
Bilateral retractile testes subsequent effects on fertility. *J Pediatr Surg* 1977; 12: 563.
37. **Pyörälä S, Huttunen NP, Uhari M.**  
A review and meta-analysis of hormonal treatment of cryptorchidism. *J Clin Endocrinol Metab* 1995; 80: 2795–2799.
38. **Rabinowitz R, Hulbert WC Jr.**  
Cryptorchidism. *Pediatr Rev* 1994; 15: 272–274.
39. **Ritchey ML, Bloom D.**  
Summary of the urology section. *American Academy of Pediatrics. Pediatrics* 1995; 96: 138–143.

40. **Sarihan H, Sari A, Abes M, Dinc H.**  
Non-palpable undescending testis. Value of magnetic resonance imaging. *Minerva Urol Nefrol* 1998; 50: 233–236.
41. **Rübber H, Goepel M.**  
Leitlinie zum Kryptorchismus. *Urologe A* 1998; 37: 666–667.
42. **Siemer S, Uder M, Humke U, Bonnet L, Zeigler M.**  
Diagnostik des nicht tastbaren Hodens im Kindesalter: Laparoskopie oder Kernspintomographie? *Urologe A* 1998; 37: 648–652.
43. **Tzvetkova P, Tzvetkova D, Kanchev L, Yanev V.**  
HCG stimulation test for diagnosis of androgen deficiency. *Arch Androl* 1997; 39: 163–171.
44. **Vaysse P.**  
Laparoscopy and impalpable testis a prospective multicentric study (232 cases). GECl. Groupe d'Etude en Coelochirurgie Infantile. *Eur J Pediatr Surg* 1994; 4: 329–332.
45. **Yu TJ, Lai MK, Chen WF, Wan YL.**  
Two-stage orchiopexy with laparoscopic clip ligation of the spermatic vessels in prune-belly syndrome. *J Pediatr Surg* 1995; 30: 870–872.

## 3. HYPOSPADIAS

### 3.1 BACKGROUND

Depending on the localization of the external urethral orifice, hypospadias can be subdivided into distal (75%; glandular, coronary, subcoronary), intermediate (13%) and proximal (12%; penoscrotal, scrotal, perineal) forms. Differentiation between functionally necessary and aesthetically feasible operative procedures is important for therapeutic decision-making. As all surgical procedures carry the risk of complications, thorough pre-operative counselling of the parents is crucial.

### 3.2 DIAGNOSIS

Apart from the description of the local findings (position, shape and width of the orifice, size of the penis, information on the curvature of the penis on erection and inflammation), the diagnostic evaluation includes assessment of associated anomalies:

- Open processus vaginalis (in 9% of cases)
- Testis in a high position (in 5% of mild forms of hypospadias; in 31% of posterior hypospadias)
- Anomalies of the upper urinary tract (3%)

Severe hypospadias with unilaterally or bilaterally impalpable testis and scrotal transposition require a complete genetic work up. In case of ambiguous genitalia, retrograde genitography should be performed soon after birth to exclude an adrenogenital syndrome (AGS).

A thorough physical examination, urinalysis and usually sonography are performed routinely in all forms of hypospadias. Excretory urogram or voiding cystourethrography (VCUG) are required only when the findings in the investigations mentioned above are inconclusive. Urine trickling and ballooning of the urethra requires exclusion of meatal stenosis by careful inspection.

### 3.3 TREATMENT

Surgical intervention is recommended for intermediate and more severe forms of hypospadias, and for distal forms with associated pathology (penile curvature, meatal stenosis and phimosis). In simple distal hypospadias, cosmetic correction should be performed only after a thorough discussion of the psychological aspects and clarification of the lack of a functional indication.

The therapeutic objective is to correct the penile curvature, to form a neo-urethra and to bring the neo-meatus to the tip of the glans penis, if possible. The use of magnifying spectacles and special suture materials, knowledge of a variety of plastic surgical techniques (use of rotational skin flaps, as well as free tissue transfer), the handling of dermatomes, wound care and post-operative treatment are essential for a satisfactory outcome.

Pre-operative treatment with the local application of testosterone propionate over a period of 4 weeks can be helpful. For distal forms of hypospadias a range of techniques are available (e.g. Mathieu, MAGPI, King, Duplay, Snodgrass, Onlay). Along with the 'skin' chorda, the connective tissue of the genuine chorda and the distal corpus spongiosum, running longitudinally under the glans on both sides of the urethral channel, are usually responsible for the curvature. If there is a residual curvature after chordectomy, and if the remaining skin channel of the open urethra is thin and of poor circulation, incision or excision of the urethral plate may be required. In corporeal dysproportion, orthoplasty (modification of Nesbit dorsal corporeal plication) must be added. Orthoplasty (Nesbit, modified Nesbit, Schröder-Essed) and closure may be considered in a two-stage procedure.

The Onlay technique with preservation of the urethral plate and avoidance of circumferential anastomosis is the method of choice, with low complication rates for moderate and severe hypospadias. Prerequisite is an intact and well-vascularized urethral plate, or a satisfactory result after the first session with a straight penis and a well-covered shaft. If the urethral plate is not completely preserved (after excision or division), a tube-onlay flap or an inlay-onlay flap are used. The two-stage procedure may be an option in severe hypospadias. If preputial or penile skin is not available, buccal mucosa, bladder mucosa and free skin grafts can be used.

Only fine absorbable suture materials should be used (6/0–7/0). For blood coagulation, bipolar instruments are required along with swabs soaked in 1:10,000 epinephrine solution. Glans preparation may be facilitated by infiltration with a 1:100,000 epinephrine solution. Tourniquets should not be used for longer than 20 minutes.

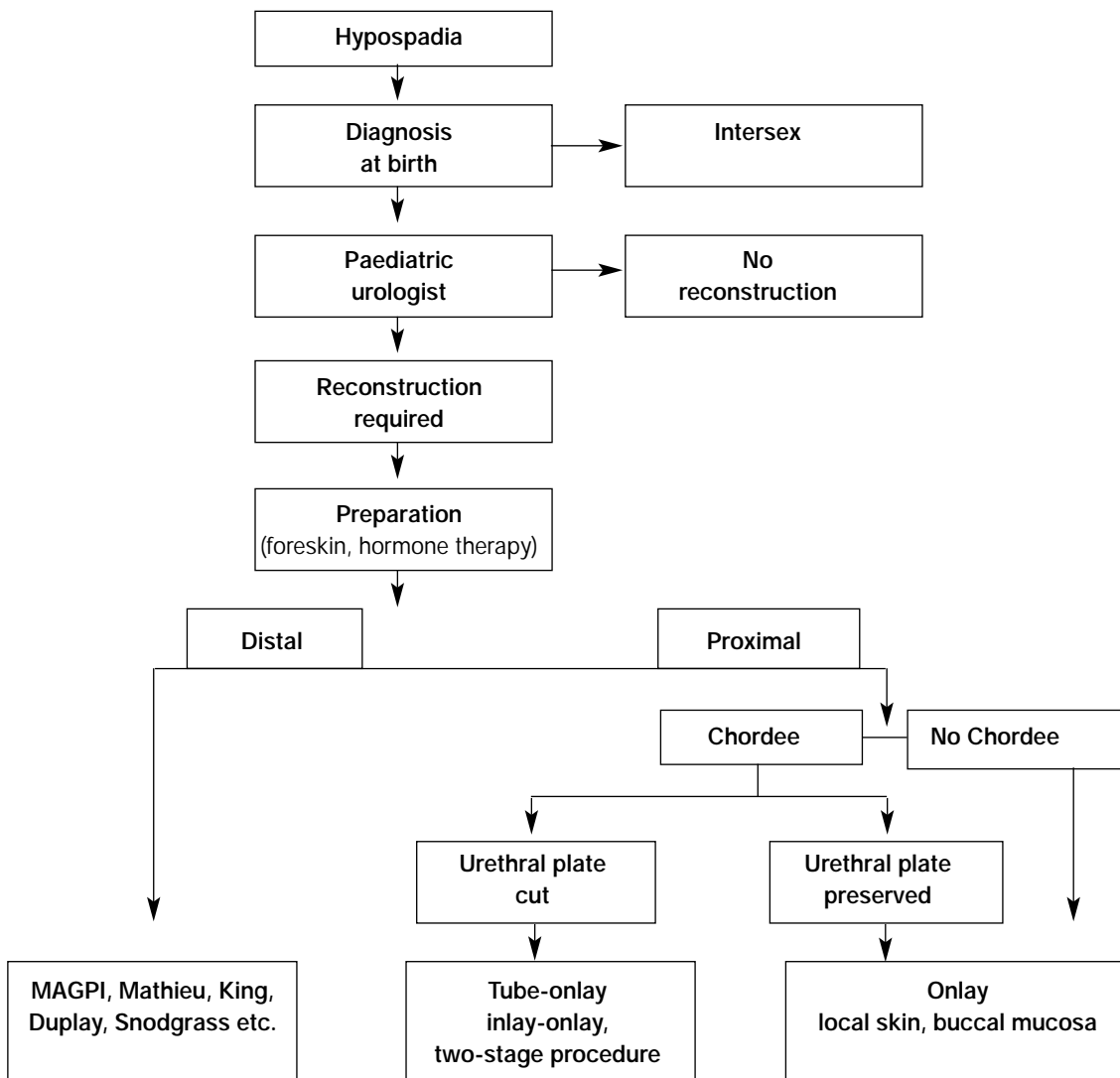
After preparation of the dorsal neurovascular bundle, modified Nesbit sutures (monofilic non-resorbable suture material 4/0–5/0, e.g. Goretex, Prolene) are placed with the knots folded in. Urine is drained via a transurethral or suprapubic catheter. In case of a suprapubic catheter, the neo-urethra should be stented. For urethral stenting and drainage, an 810 F catheter with multiple side holes is used ending in the bulbar urethra (not into the bladder). Circular dressings with slight compression, as well as an antibiotic administration have become established procedures.

### 3.3.1 Complications

Whereas meatal narrowing after splint removal can be corrected by careful stretching and the Dittel device, operative revision is needed in cases of a scarred meatus as slitting and stretching are ineffective in the long term. In urethral stricture, open surgery should be performed after one attempt at internal urethrotomy. With fistulae, revision should not be planned before a lapse of 6 months. Urethral stricture should be excluded intra-operatively as a cause of the fistula. To prevent the recurrent fistula formation, a dartos flap or a free tunica vaginalis patch may be used. Attention should be paid to adequate subsequent cover with mobilized Scarpa's fasciae.

Correction of a minor residual curvature, sometimes reported by the parents, should be discouraged, as it has no functional relevance. It can be easily corrected after puberty, if significant.

**Table 2: Algorithm for the management of hypospadias**



### 3.4 REFERENCES

1. **Abu Arafah W, Chertin B, Zilberman M, Farkas A.**  
One-stage repair of hypospadias: experience with 856 cases. *Eur Urol* 1998; 34: 365–367.
2. **Ahmed S, Gough DC.**  
Buccal mucosal graft for secondary hypospadias repair and urethral replacement. *Br J Urol* 1997; 80: 328–330.
3. **Aho MO, Tammela OK, Tammela TL.**  
Aspects of adult satisfaction with the result of surgery for hypospadias performed in childhood. *Eur Urol* 1997; 32: 218–222.
4. **Asopa HS.**  
Newer concepts in the management of hypospadias and its complications. *Ann R Coll Surg Engl* 1998; 80: 161–168.
5. **Baskin LS, Duckett JW.**  
Dorsal tunica albuginea plication for hypospadias curvature. *J Urol* 1994; 151: 1668–1671.
6. **Baskin LS, Duckett JW, Ueoka K, Seibold J, Snyder HM.**  
Changing concepts of hypospadias curvature lead to more onlay island flap procedures. *J Urol* 1994; 151: 191–196.
7. **Borer JG, Retik AB.**  
Current trends in hypospadias repair. *Urol Clin North Am*, 1999; 26: 15–37.
8. **Bracka A.**  
Hypospadias repair: the two-stage alternative. *Br J Urol* 1995; 76 Suppl 3: 31–41.
9. **Bronshtein M, Riechler A, Zimmer EZ.**  
Prenatal sonographic signs of possible fetal genital anomalies. *Prenat Diagn* 1995; 15: 215–219.
10. **Burbige KA.**  
Simplified postoperative management of hypospadias repair. *Urology* 1994; 43: 719–721.
11. **Buson H, Smiley D, Reinberg Y, Gonzalez R.**  
Distal hypospadias repair without stents: is it better? *J Urol* 1994; 151: 1059–1060.
12. **Caldamone AA, Edstrom LE, Koyle MA, Rabinowitz R, Hulbert WC.**  
Buccal mucosal grafts for urethral reconstruction. *Urology* 1998; 51: 15–19.
13. **De Grazia E, Cigna RM, Cimador M.**  
Modified-Mathieu's technique: a variation of the classic procedure for hypospadias surgical repair. *Eur J Pediatr Surg* 1998; 8: 98–99.
14. **Dubois R, Pelizzo G, Nasser H, Valmalle AF, Dodat H.**  
Les fistules de l'uretère après traitement chirurgical d'hypospadias. A propos d'une série de 74 cas. *Prog Urol* 1998; 8: 1029–1034.
15. **Duckett JW.**  
The current hype in hypospadiology. *Br J Urol* 1995; 76 Suppl 3: 1–7.
16. **Fichtner J, Filipas D, Mottrie AM, Voges GE, Hohenfellner R.**  
Analysis of meatal location in 500 men: wide variation questions need for meatal advancement in all pediatric anterior hypospadias cases. *J Urol* 1995; 154: 833–834.
17. **Fichtner J, Thüroff J.**  
Leitlinie zur Hypospadie und therapeutische Empfehlungen. *Urologe A* 1998; 37: 665–666.
18. **Fichtner J, Fisch M, Filipas D, Thüroff JW, Hohenfellner R.**  
Refinements in buccal mucosal grafts urethroplasty for hypospadias repair. *World J Urol* 1998; 16: 192–194.
19. **Ghali AMA, El-Malik EMA, Al-Malki T, Ibrahim AH.**  
One-stage hypospadias repair. Experience with 544 cases. *Eur Urol* 1999; 36: 436–442.
20. **Hayashi Y, Mogami M, Kojima Y, Mogami T, Sasaki S, Azemoto M, Maruyama T, Tatsura H, Tsugaya M, Kohri K.**  
Results of closure of urethrocutaneous fistulas after hypospadias repair. *Int J Urol* 1998; 5: 167–169.
21. **Kinkead TM, Borzi PA, Duffy PG, Ransley PG.**  
Long-term follow-up of bladder mucosa graft for male urethral reconstruction. *J Urol* 1994; 151: 1056–1058.
22. **Kocvara R, Dvoracek J.**  
Chirurgická oprava hypospadie zivenym lalokem onlay. *Rozhl Chir* 1995; 74: 322–326.
23. **Kocvara R, Dvoracek J.**  
Inlay-onlay flap urethroplasty for hypospadias and urethral stricture repair. *J Urol* 1997; 158: 2142–2145.
24. **Meyer Junghanel L, Petersen C, Mildenerger H.**  
Experience with repair of 120 hypospadias using Mathieu's procedure. *Eur J Pediatr Surg* 1995; 5: 355–357.
25. **Mollard P, Basset T, Mure PY.**  
Traitement moderne de l'hypospadias. *J Urol Paris* 1996; 102: 9–17.
26. **Mollard P, Mure PY.**  
Hypospadias proximal. *Arch Esp Urol* 1998; 51: 551–559.

27. **Mureau MA, Slijper FM, Slob AK, Verhulst FC.**  
Psychosocial functioning of children, adolescents, and adults following hypospadias surgery: a comparative study. *J Pediatr Psychol* 1997; 22: 371–387.
28. **Ohsumi N.**  
Post-operative compressive penile dressing using fibrin seal (Tisseel) and tulle gauze for hypospadias repair [letter]. *Plast Reconstr Surg* 1998; 101: 1737–1738.
29. **Palmer LS, Gill B, Kogan SJ.**  
Endocrine analysis of childhood monorchism. *J Urol* 1997; 158: 594–596.
30. **Perovic S, Vukadinovic V.**  
Onlay Island Flap Urethroplasty for severe hypospadias: a variant of the technique. *J Urol* 1994; 151: 711–714.
31. **Retik AB, Bauer SB, Mandell J, Peters CA, Colodny A, Atala A.**  
Management of severe hypospadias with a 2-stage repair. *J. Urol* 1994; 152: 749–751.
32. **Riedmiller H.**  
Hypospadias 2000. *Akt Urol* 2000; 31:147–148.
33. **Rosenbloom AL.**  
Evaluation of severe hypospadias [letter; comment]. *J Pediatr* 1998; 133: 169–170.
34. **Smith EP, Wacksman J.**  
Evaluation of severe hypospadias [editorial; comment]. *J Pediatr* 1997; 131: 344–346.
35. **Snodgrass W, Koyle M, Manzoni G, Hurwitz R, Caldamone A, Ehrlich R.**  
Tubularized incised plate hypospadias repair: results of a multicenter experience. *J Urol* 1996; 156: 839–841.
36. **Snodgrass W.**  
Tubularized incised plate hypospadias repair: indications, technique, and complications. *Urology* 1999; 54: 6–11.
37. **Snow BW, Cartwright PC, Unger K.**  
Tunica vaginalis blanket wrap to prevent urethrocutaneous fistula: an 8-year experience. *J Urol* 1995; 153: 472–473.
38. **Stock JA, Hanna MK.**  
Distal urethroplasty and glanuloplasty procedure: results of 512 repairs. *Urology* 1997; 49: 449–451.
39. **Ulman I, Erikci V, Avanoğlu A, Gokdemir A.**  
The effect of suturing technique and material on complication rate following hypospadias repair. *Eur J Pediatr Surg* 1997; 7: 156–157.
40. **Uygur MC, Erol D, Germiyanoglu G.**  
Lessons from 197 Mathieu hypospadias repairs performed at a single institution. *Pediatr Surg Int* 1998; 14: 192–194.
41. **Weidner IS, Moller H, Jensen TK, Skakkebaek NE.**  
Risk factors for cryptorchidism and hypospadias. *J Urol* 1999; 161: 1606–1609.

## 4. INCONTINENCE

### 4.1 BACKGROUND

As a result of maturation, children usually become continent during the day-time by the second year and at night by the fourth year. In cases of persistent wetting, a distinction has to be made between enuresis and urinary incontinence. Particular attention should be paid to:

- Anatomic defects of sphincteric muscle and bladder (e.g. complete epispadias, bladder exstrophy, urogenital sinus, ectopic ureter)
- Impaired innervation of bladder and sphincteric muscle (e.g. myelomeningocele)
- Functional disturbances of the bladder and sphincteric muscle.

### 4.2 CLASSIFICATION

#### 4.2.1 Enuresis

This is defined as a normal void occurring at an inappropriate or socially unacceptable time or place. Children with nocturnal enuresis void in bed while asleep and are generally not aroused by the wetting. The condition is mono-symptomatic and has a clear familial tendency.

##### *Primary nocturnal enuresis*

Involuntary bed wetting from the time of birth without an uninterrupted period of at least 6 months.

##### *Secondary (onset) nocturnal enuresis*

Involuntary bed wetting after a dry period of at least 6 months.

##### *Nocturnal polyuria enuresis*

This describes nocturnal enuresis in children who have urine production in excess of their functional bladder capacity, as shown by voiding charts.

##### *Diurnal enuresis*

Wetting in attention-deficit disorders; voiding is complete; bladder and urethral function are normal.

#### 4.2.2 Urinary incontinence

This is defined as the involuntary loss of urine, objectively demonstrable and constituting a social or hygienic problem. It denotes a symptom (patient's recognition of involuntary urine loss), a sign (the objective demonstration of urine loss) and a condition (the urodynamic demonstration of urine loss). Day-time, night-time or both day- and night-time incontinence may be encountered. Urinary incontinence is classified according to aetiology:

##### *Incontinence associated with anatomic abnormalities of the urinary tract*

Ectopic ureter, ureterocele, prune-belly syndrome, bladder exstrophy, epispadias, posterior urethral valves and cloacal abnormalities.

##### *Incontinence associated with neurogenic disorder*

Spinal dysraphism, caudal regression condition and other central nervous system (CNS) disorders.

##### *Functional incontinence in non-neuropathic bladder sphincter dysfunction (urge syndrome and dysfunctional voiding)*

Often associated with recurrent UTIs and occur predominantly in girls.

## 4.3 DIAGNOSIS

The basic diagnostic evaluation includes:

- History (including family and social history)
- Physical, urological and gross neurological examination (urinalysis and culture, specific gravity)
- Sonography (residual urine, bladder wall thickness, upper tracts)
- Frequency-volume chart (after treatment of infection)

If the basic evaluation does not reveal any pathology, an enuresis (uncomplicated, mono-symptomatic) can be assumed and no further examinations are required.

Further evaluation is required if any pathology is revealed in the basic evaluation and includes:

- Uroflow (if pathological, repeated uroflow and uroflow-electromyography (EMG) study)
- VCUG in case of thickened bladder wall and/or residual urine, in case of pathological, but co-ordinated micturition
- (Video) urodynamics on suspicion of functional voiding disturbances
- Intravenous urogram (optional if sonography is normal)
- Examination under anaesthesia (urethrocystoscopy, urethral calibration, mainly for UTIs)
- Extended neurological, radiological and psychiatric examinations (including MRI of the spinal cord)
- Radionuclide renal study to assess renal function

## 4.4 TREATMENT

### 4.4.1 Nocturnal enuresis (mono-symptomatic)

Therapy is started when the condition becomes distressing and the child becomes motivated to be dry, usually after the age of 5–6 years. Behavioural therapy including motivation, counselling about regular voiding and drinking habits, classical conditioning with an alarm-clock, and appropriate handling of constipation, is the first option. Complete dryness in 70% and considerable improvement in 12% of cases can be achieved by treatment with 10–40 mg DDAVP (Desmopressin) nasal spray over a maximum period of 6 months. However, relapse occurs in almost all cases after discontinuation of the medication. Oxybutynin can be helpful in some cases with wetting at the beginning of the night (uninhibited contractions of the bladder).

### 4.4.2 Diurnal enuresis (in children with attention disorders)

Support and education of parents, appropriate school placement and pharmacotherapy (tricyclic antidepressants), usually handled by child psychiatrists, are the treatment options.

### 4.4.3 Urinary incontinence

If recurrent UTIs are present, long-term antibiotic therapy should be started, initially for 6 months. Urinary incontinence is treated according to the aetiology and to urodynamic findings.

*Incontinence associated with anatomical abnormalities of the urinary tract*

Treatment is within the framework of the operative repair of the abnormality.

*Incontinence associated with neurogenic disorder*

The cornerstone of treatment in young children is oriented towards the protection of renal function and efficient evacuation of the bladder. When the child becomes motivated to be dry (usually after the age of 5 years), the persistent urinary incontinence is addressed. Clean intermittent catheterization to ensure an efficient bladder emptying is mostly applied in patients with detrusor-sphincter dyssynergia. Medical therapy is applied according to the urodynamic findings:

- Detrusor hyperreflexia: oxybutynin, propiverin, tolterodine
- Detrusor sphincter dyssynergia: alpha-blockers, polysynaptic inhibitor (baclofenum)

Surgical therapy can be conducted in the case of renal function deterioration, in persistent high filling detrusor pressure and/or urinary incontinence. Options include bladder augmentation, treatment of sphincter weakness and formation of a catheterizable channel.

*Functional incontinence in non-neuropathic bladder-sphincter dysfunction*

Urge syndrome: Bladder rehabilitation (counselling about regular voiding and drinking habits, about the technique of voiding); pharmacotherapy (oxybutynin, propiverin, tolterodine); intravesical stimulation and



transcutaneous neuromodulation (optional).

Dysfunctional voiding (detrusor sphincter dysco-ordination): Bladder rehabilitation (counselling about regular voiding and drinking habits, about the technique of voiding, biofeedback, clean intermittent catheterization if residual urine is significant) and pharmacotherapy (alpha blockers, polysynaptic inhibitor-baclofenum).

Lazy bladder syndrome: Counselling about regular voiding; clean intermittent catheterization; treatment of constipation and intravesical stimulation.

Hinman syndrome: According to urodynamic examination; counselling about regular voiding, usually clean intermittent catheterization if emptying not complete.

#### 4.4 REFERENCES

1. **Chandra M.**  
Nocturnal enuresis in children. *Curr Opin Pediatr* 1998; 10: 167–173.
2. **Cisternino A, Passerini Glazel G.**  
Bladder dysfunction in children. *Scand J Urol Nephrol Suppl* 1995; 173: 25–28; discussion 29.
3. **Elder JS.**  
Bladder rehabilitation: the effect of a cognitive training programme on urge incontinence. *J Urol* 1997; 158: 1642.
4. **Hjalmas K.**  
What's new in nocturnal enuresis? Old concepts and new knowledge. *European Union of General Practitioners Reference Book - Clinical Care*. Kennedy (ed), 1998/99.
5. **Hoebeke P, Vande Walle J, Everaert K, Van Laecke E, Van Gool JD.**  
Assessment of lower urinary tract dysfunction in children with non- neuropathic bladder sphincter dysfunction. *Eur Urol* 1999; 35: 57–69.
6. **Hoebeke P, Raes A, Vande Walle J, Van Laecke E.**  
Urodynamics in children: what and how to do it? *Acta Urol Belg* 1998; 66: 23–30.
7. **Hoekx L, Wyndaele JJ, Vermandel A.**  
The role of bladder biofeedback in the treatment of children with refractory nocturnal enuresis associated with idiopathic detrusor instability and small bladder capacity. *J Urol* 1998; 160: 858–860.
8. **Holland AJ, King PA, Chauvel PJ, O'Neill MK, McKnight DL, Barker AP.**  
Intravesical therapy for the treatment of neurogenic bladder in children. *Aust N Z J Surg* 1997; 67: 731–733.
9. **Holmdahl G, Sillen U, Bachelard M, Hansson E, Hermansson G, Hjalmas K.**  
The changing urodynamic pattern in valve bladders during infancy. *J Urol* 1995; 153: 463–467.
10. **Imada N, Kawauchi A, Tanaka Y, Watanabe H.**  
The objective assessment of urinary incontinence in children. *Br J Urol* 1998; 81 Suppl 3: 107–108.
11. **Kaplinsky R, Greenfield S, Wan J, Fera M.**  
Expanded followup of intravesical oxybutynin chloride use in children with neurogenic bladder. *J Urol* 1996; 156: 753–756.
12. **Kjolseth D, Madsen B, Knudsen LM, Norgaard JP, Djurhuus JC.**  
Biofeedback treatment of children and adults with idiopathic detrusor instability. *Scand J Urol Nephrol* 1994; 28: 243–247.
13. **Loening Baucke V.**  
Urinary incontinence and urinary tract infection and their resolution with treatment of chronic constipation of childhood. *Pediatrics* 1997; 100: 228–232.
14. **Madersbacher H, Schultz-Lampel D.**  
Leitlinie zur Abklärung der Harninkontinenz bei Kindern. *Urologe A* 1998; 37.
15. **Nijman RJ.**  
Pitfalls in urodynamic investigations in children. *Acta Urol Belg* 1995; 63: 99–103.
16. **Norgaard JP.**  
Technical aspects of assessing bladder function in children. *Scand J Urol Nephrol Suppl* 1995; 173: 43–6; discussion 46–47.
17. **Norgaard JP, Van Gool JD, Hjalmas K, Djurhuus JC, Hellstrom AL.**  
Standardization and definitions in lower urinary tract dysfunction in children. *International Children's Continence Society*. *Br J Urol*, 1998. 81 Suppl 3: 1–16.
18. **Opsomer RJ, Clapuyt P, De Groote P, Van Cangh PJ, Wese FX.**  
Urodynamic and electrophysiological testing in pediatric neurourology. *Acta Urol Belg* 1998; 66: 31–34.
19. **Schultz-Lampel D, Thüroff JW.**  
Enuresis. *Urologe A* 1997; 36: W265–274.

20. **Shoukry MS, El Salmly S, Aly GA, Mokhless I.**  
Urodynamic predictors of upper tract deterioration in children with myelodysplasia.  
Scand J Urol Nephrol 1998; 32: 94–97.
21. **Starr NT.**  
Pediatric gynecology urologic problems. Clin Obstet Gynecol 1997; 40: 181–199.
22. **Wan J, Greenfield S.**  
Enuresis and common voiding abnormalities. Pediatr Clin North Am 1997; 44: 1117–1131.
23. **Wennergren H, Oberg B.**  
Pelvic floor exercises for children: a method of treating dysfunctional voiding. Br J Urol 1995; 76: 9–15.
24. **Williams MA, Noe HN, Smith RA.**  
The importance of urinary tract infection in the evaluation of the incontinent child.  
J Urol 1994; 151: 188–190.
25. **Wojcik LJ, Kaplan GW.**  
The wet child. Urol Clin North Am 1998; 25: 735–744.
26. **Van Gool JD et al.**  
Conservative management in children.  
Incontinence. Abrams, Khoury, Wein. (eds). Health Publication Ltd: Plymouth, 1999, 487–550.
27. **Yannakoyorgos K, Ioannides E, Zahariou A, Anagnostopoulos D, Kasselas V, Kalinderis A.**  
Management of nocturnal enuresis in children with desmopressin and bladder physiotherapy.  
Pediatr Surg Int 1998; 13: 281–284.

# 5. DILATATION OF THE UPPER URINARY TRACT

## 5.1 BACKGROUND

Hydronephrosis is detectable within the uterus by ultrasound from the 16th week of pregnancy. The commonest causes are ureteropelvic junction (UPJ)-stenosis, megaureters, urethral valve syndrome, vesicorenal reflux and multicystic renal dysplasia.

## 5.2 DIAGNOSIS

### 5.2.1 Ultrasound examination

Ectasia (anterior-posterior diameter of the renal pelvis, caliceal ectasia), kidney size, thickness of the parenchyma, cortical echo-pattern, width of the ureter, bladder wall thickness and residual urine are assessed during ultrasound examination. With a diameter of the renal pelvis greater than 15 mm, obstruction of the upper urinary tract is likely and correction may be considered. The first ultrasound examination of prenatally diagnosed ectasia of the renal pelvis should be carried out within the first 2 days of life, after 3–5 days and after 3 weeks. A normal ultrasound during the first days of life can be secondary to the oliguria of the newborn.

### 5.2.2 Voiding cystourethrography (VCUG)

Of patients with UPJ-stenosis or megaureter, 14% show a vesicorenal reflux (VRR) at the same time. Reflux should be verified or ruled out by conventional VCUG pre-operatively. Isotope VCUG (lower exposure to radiation) is used for follow-up.

### 5.2.3 Diuresis renography

Because of its low radiation exposure, Tc99m-MAG3 is the radionuclide of choice in diuresis renography. The examination is carried out after standardized hydration with a transurethral catheter in place. Renal arterial perfusion, intrarenal cortical transit and excretion of the tracer into the collecting system are measured. If excretion is impaired, it takes longer for half the maximum activity of the radio-isotope to reach the renal pelvis (T1/2) after application of furosemide. With rapid absorption of the tracer and prompt washing out effect on diuresis (T1/2 < 10 min), obstruction is unlikely. Impaired or deteriorating split renal function in newborns or young infants with upper tract dilatation may be the best indicator of significant obstruction.

### 5.2.4 Static renal scintigraphy

Renal scintigraphy with di-mercaptosuccinic acid (DMSA) is an ideal method for assessment of renal morphology, acute infectious changes, renal scars and functional impairment, for example in multicystic renal dysplasia and reflux nephropathy. This investigation should not usually be used within the first 2 months of life.

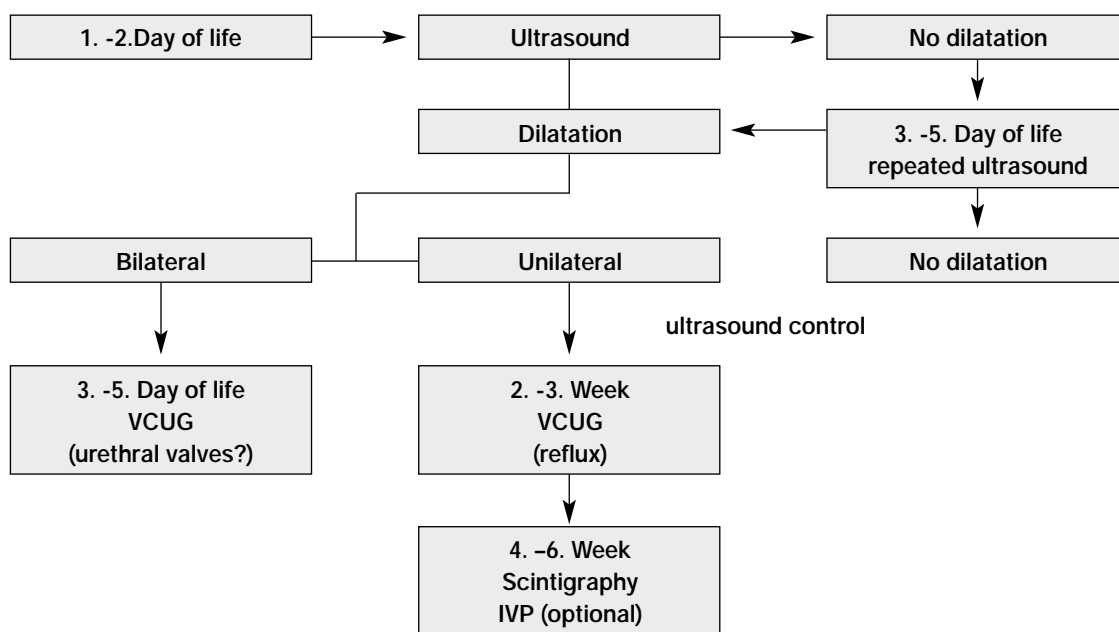
### 5.2.5 Intravenous urogram (IVU)

The IVU is an optional examination method and may be performed pre-operatively and in case of inconclusive findings on sonography. The indication for an IVU in the first year of life is problematical.

### 5.2.6 Whitaker's test

Whitaker's test is carried out as an optional antegrade pressure flow study if diagnosis of obstruction is obscure. The measurement involves continuous perfusion of the renal pelvis via a percutaneous puncture or, if necessary, nephrostomy. Shortcomings of Whitaker's test are the unphysiologically high perfusion rate, lack of normal ranges in children, dependence on the examiner and the invasiveness of the procedure.

**Table 3: Follow-up of prenatally diagnosed dilatation of the upper urinary tract**



## 5.3 TREATMENT

### 5.3.1 UPJ-stenosis

Symptomatic UPJ-stenosis requires surgical correction, whereas asymptomatic unilateral UPJ-stenosis can be subjected to surveillance depending on the grade of obstruction and split renal function. If function does not improve within 3–6 months in patients with a renal function of less than 10% on the affected side, nephrectomy should be considered, especially when symptoms occur (e.g. UTI, hypertension, flank pain). Patients with a function of less than 40% should undergo pyeloplasty. If the partial function is greater than 40%, operative intervention is indicated only if new symptoms occur or function drops more than 10% with time. Sonography should be performed every 4 weeks. Renal function scintigraphy must be repeated within 1 year. Children with a pre-operative partial function below 45% show enhanced growth and an improved overall renal function post-operatively.

### 5.3.2 Megaureter

According to the official international classification, megaureters are subdivided into primary and secondary, obstructive and/or refluxive and non-refluxive, non-obstructive. Treatment of the refluxive megaureter is dealt with in the section on vesicoureteral reflux (VUR). The diagnostic evaluation is the same as in unilateral hydronephrosis. The degree of obstruction and the split renal function is determined by renal scintigraphy and IVU.

In view of equivalent results of surveillance, surgical intervention based only on the excretory urogram is now rare. With spontaneous remission rates of up to 85% in primary obstructive megaureters, high drainage by means of Sober's or ring-ureterocutaneostomy is no longer justified.

Operative ureterocystoneostomy according to Cohen, Politano-Leadbetter or the Psoas-Hitch-technique can be considered as an operative measure. Indications for surgical treatment of megaureter are recurrent infections under prophylactic antibiotic medication, deterioration of split renal function, reflux persisting for more than 1 year under prophylaxis and significant obstruction.

### 5.3.3 Ureterocele

Orthotopic ureterocele is a rare finding in children, exclusively observed in females and mostly associated with a single kidney system. It seldom requires surgical intervention, mostly due to complications (e.g. lithiasis). Diagnostic evaluation follows the scheme 'Unilateral hydronephrosis'. VCUG is mandatory prior to a planned operation. An excretory urogram and cystourethroscopy provide additional information on specific questions.

Ectopic ureterocele is dealt with in the section 'Obstructive pathology of renal duplication' (see chapter 9).

### 5.3.4 Retrocaval ureter

A retrocaval ureter is not an anomaly of the ureter but of the vena cava. Diagnostic evaluation follows the scheme 'Unilateral hydronephrosis' (including excretory urogram). In this rare condition, the ureter is divided, its course corrected and end-to-end anastomosis is performed.

### 5.3.5 Bilateral hydronephrosis

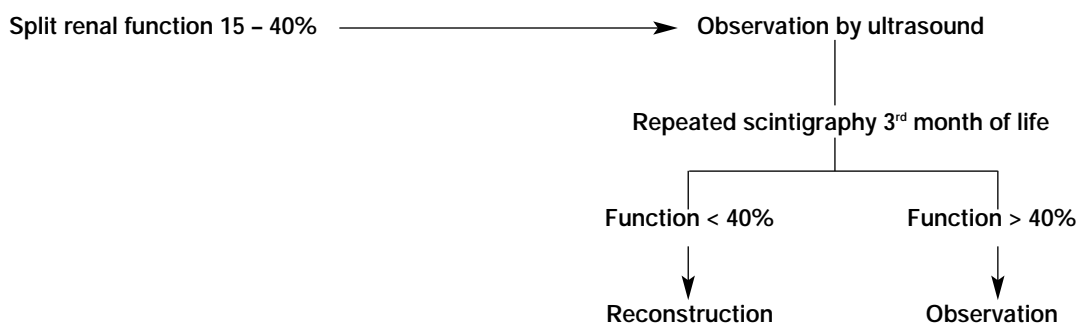
Bilateral hydronephrosis and megaureter are very rare in girls and require an individual approach, which cannot be dealt with by an algorithm. In boys, the most frequent cause is infravesical obstruction by urethral valves. The obstruction may result in the formation of a trabecular bladder with secondary megaureters and hydronephrosis. After sonography, a VCUG should be carried out without delay. If no pathological findings are discovered, further evaluation follows the 'Unilateral hydronephrosis' scheme. In cases of reflux, diagnostic evaluation follows the 'Reflux' scheme (see chapter 7). In cases of infravesical obstruction with urinary retention, a suprapubic catheter should be inserted immediately and an antegrade VCUG carried out later. Sonography and serum creatine controls should be monitored daily. If sonographic findings improve and serum creatinine falls below 0.6 mg/dL, endoscopic valve resection should be planned between the first and sixth month of life (depending on the baby's size and weight). Endoscopy should take place when the traumatization of the urethra can be minimized. In case of early endoscopic treatment, a stent can be placed in the urethra (6–8 ch) pre-operatively. If there is no improvement of sonographic findings and the serum creatinine does not fall below 0.6 mg/dL, supravescical diversion is necessary and delayed reconstruction 6 to 9 months later should be planned.

Immediate supravescical diversion is indicated (rarely) in a septic patient with a gross bilateral dolichomegaureter and renal impairment, or in a gross bilateral dolichomegaureter and renal insufficiency that does not respond or continues to deteriorate. The endoscopic cold valve ablation (transurethral or suprapubic) is then performed according to the development of patient conditions and the possibility of spontaneous voiding. A VCUG and a radiological imaging of the diverted upper urinary tract should be carried out pre-operatively.

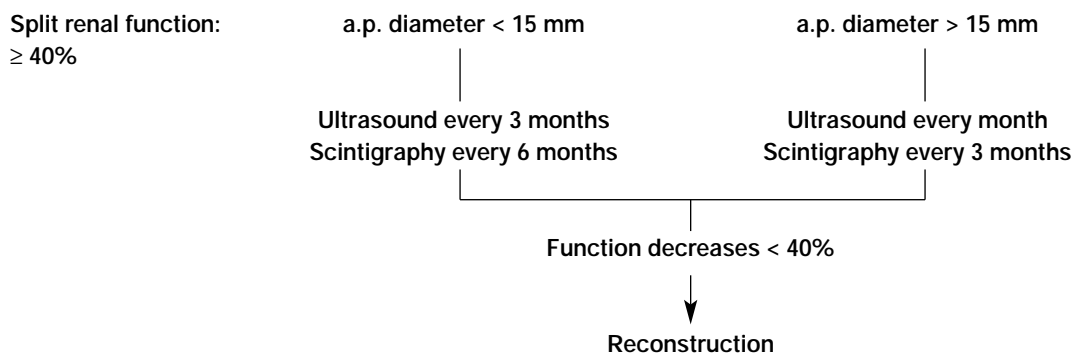
**Table 4: Management of prenatally diagnosed hydronephrosis I**



**Table 5: Management of prenatally diagnosed hydronephrosis II**



**Table 6: Management of prenatally diagnosed hydronephrosis III**



#### 5.4 REFERENCES

1. **Ahmed S, Crankson S, Sripathi V.**  
 Pelviureteric obstruction in children: conventional pyeloplasty is superior to endo-urology.  
*Aust N Z J Surg* 1998; 68: 641–642.
2. **Anton Pacheco Sanchez J, Gomez Fraile A, Aransay Brantot A, Lopez Vazquez F, Encinas Goenechea A.**  
 Diuresis renography in the diagnosis and follow-up of non-obstructive primary megaureter.  
*Eur J Pediatr Surg* 1995; 5: 338–341.
3. **Arun N, Kekre NS, Nath V, Gopalakrishnan G.**  
 Is open pyeloplasty still justified? *Br J Urol* 1997; 80: 379–381.
4. **Belman AB.**  
 A perspective on vesicoureteral reflux. *Urol Clin North Am* 1995; 22: 139–150.
5. **Bomalaski MD, Hirschl RB, Bloom DA.**  
 Vesicoureteral reflux and ureteropelvic junction obstruction: association, treatment options and outcome. *J Urol* 1997; 157: 969–974.
6. **Borhan A, Kogan BA, Mandell J.**  
 Upper ureteral reconstructive surgery. *Urol Clin North Am* 1999; 26: 175–181.
7. **Chevalier RL, Klahr S.**  
 Therapeutic approaches in obstructive uropathy. *Semin Nephrol* 1998; 18: 652–658.
8. **Dhillon HK.**  
 Prenatally diagnosed hydronephrosis: the Great Ormond Street experience.  
*Br J Urol* 1998; 81 Suppl 2: 39–44.
9. **DiSandro MJ, Kogan BA.**  
 Neonatal management. Role for early intervention. *Urol Clin North Am* 1998; 25: 187–197.
10. **Ebel KD.**  
 Uroradiology in the fetus and newborn: diagnosis and follow-up of congenital obstruction of the urinary tract. *Pediatr Radiol* 1998; 28: 630–635.
11. **Jaby O, Lottmann H, Bonnin F, Weisgerber G, El Ghoneimi A, Aigrain Y.**  
 Mega uretere primitif obstructif: reimplantation sur vessie psoique de premiere intention.  
*Ann Urol Paris* 1998; 32: 197–201.
12. **Khan AM, Holman E, Pasztor I, Toth C.**  
 Endopyelotomy: experience with 320 cases. *J Endourol* 1997; 11: 243–246.
13. **King LR.**  
 Hydronephrosis. When is obstruction not obstruction? *Urol Clin North Am* 1995; 22: 31–42.
14. **Koff SA.**  
 Neonatal management of unilateral hydronephrosis. Role for delayed intervention.  
*Urol Clin North Am* 1998; 25: 181–186.
15. **Liu HY, Dhillon HK, Yeung CK, Diamond D, Duffy PG, Ransley PG.**  
 Clinical outcome and management of prenatally diagnosed primary megaureters.  
*J Urol* 1994; 152: 614–617.
16. **Mollard P, Foray P, De Godoy JL, Valignat C.**  
 Management of primary obstructive megaureter without reflux in neonates. *Eur Urol* 1993; 24: 505–510.
17. **Nonomura K, Yamashita T, Kanagawa K, Itoh K, Koyanagi T.**  
 Management and outcome of antenatally diagnosed hydronephrosis. *Int J Urol* 1994; 1: 121–128.

18. **Rascher W, Bonzel KE, Guth-Tougelidis B, Kropfl D, Meyer-Schwickerath M, Reiners C.**  
Angeborene Fehlbildungen des Harntrakts. Rationelle postpartale Diagnostik.  
Monatsschr Kinderheilkd 1992; 140: 78–83.
19. **Reddy PP, Mandell J.**  
Prenatal diagnosis. Therapeutic implications. Urol Clin North Am 1998; 25: 171–180.
20. **Rickwood AM, Harney VV, Jones MO, Oak S.**  
'Congenital' hydronephrosis: limitations of diagnosis by fetal ultrasonography.  
Br J Urol 1995; 75: 529–530.
21. **Rickwood AM, Jee LD, Williams MP, Anderson PA.**  
Natural history of obstructed and pseudo-obstructed megaureters detected by prenatal ultrasonography. Br J Urol 1992; 70: 522–525.
22. **Ringert RH, Kallerhoff M.**  
Leitlinie zur Diagnostik der Harntransportstörungen in der Kinderurologie. Urologe A 1998; 37: 573–574.
23. **Roarke MC, Sandler CM.**  
Provocative imaging. Diuretic renography. Urol Clin North Am 1998; 25: 227–249.
24. **Ward AM, Kay R, Ross JH.**  
Ureteropelvic junction obstruction in children. Unique considerations for open operative intervention.  
Urol Clin North Am 1998; 25: 211–217.
25. **Wilcox D, Mouriquand P.**  
Management of megaureter in children. Eur Urol 1998; 34: 73–78.

## 6. URINARY TRACT INFECTION (UTI)

### 6.1 CLASSIFICATION

#### Asymptomatic bacteriuria

Significant bacteriuria can be documented in consecutive urine samples without any symptoms.

#### Cystitis

The infection is limited to the bladder; irritative symptoms are present, but no systemic symptoms or fever.

#### Acute pyelonephritis

Febrile infection of the renal parenchyma.

#### Complicated UTI

Due to a urine transport disturbance, malformation or a relevant bladder voiding disturbance.

### 6.2 DIAGNOSIS

Indications for chemical and microbiological urine examination include fever of unknown origin, unclear growth impairment in infants, unclear abdominal complaints or flank pain, frequency, dysuria, smelly urine and gross haematuria. In infants and small children, urine is usually collected in a bag attached to the external genitalia. A positive urine culture requires confirmation by suprapubic puncture (withdrawal of urine by transurethral catheterization is optional). Once the child can void on demand, mid-stream urine is used in boys and transurethral catheterization in girls.

The urine examination consists of paper-strip tests, microscopy and microbiology. Only the examination of bladder puncture urine achieves a sensitivity of > 95%. In cases of a positive urine culture, complete blood count, differential blood count, erythrocyte sedimentation rate (ESR) and C-reactive protein (CRP) are determined together with clinical examination.

Sonography is performed to assess kidney volume, parenchymal echogenicity, thickness and scarring, anomalies (e.g. duplex system), hydronephrosis, dilatation of the ureter and calculi. Bladder wall thickness, bladder configuration, dilatation of the ureter (VCUG, to rule out reflux) and residual urine are assessed with a full bladder. In case of pyelocaliectasis, an IVU should be considered. A VCUG should be carried out after successful antibiotic therapy.

**Table 7: Differential diagnosis of pyelonephritis**

	Pyelonephritis likely	Pyelonephritis unlikely
ESR	> 25 mm n. W	< 25 mm n. W
CRP	> 1 mg/mL	< 1 mg/mL
Body temp.	> 38.5 °C	> 38.5 °C
Leucocytosis/left shift	Present	Not present
Leucocyte casts in urine	Evidence	No evidence
Kidney volume	Enlarged	Not enlarged

ESR = erythrocyte sedimentation rate; CRP = C-reactive protein

### 6.3 TREATMENT

#### 6.3.1 Asymptomatic bacteriuria

No treatment is required in children with a normal urinary tract; functional voiding disturbances should be excluded.



### 6.3.2 Acute UTI without pyelonephritis

Trimethoprim/sulphamethoxazole, trimethoprim (mono-), oral cephalosporins or amoxicillin (third choice) is given for 3–5 days.

### 6.3.3 Pyelonephritis

Intravenous antibiotic therapy with a broad-spectrum penicillin or cephalosporin is started immediately. In case of non-sensitive bacteria, a reserve antibiotic agent is chosen. In newborns, treatment should last for 14–21 days. The therapy is then continued orally for 7–14 days. In impaired renal function, the dosage is adjusted according to the serum creatinine level. Therapy can be stopped when urine culture is sterile and all signs of inflammation have disappeared. DMSA scintigraphy may be performed 3 months after the end of treatment. In obstructive pyelonephritis, urinary drainage should be considered as an emergency.

### 6.3.4 Complicated UTI

Efficient management of complicated UTIs requires appropriate treatment of the underlying condition (e.g. impaired urinary drainage).

### 6.3.5 Antibiotic prophylaxis

Nitrofurantoin and trimethoprim are currently considered as first-line treatment; alternatives are amoxicillin or cephalosporins. Long-term antibiotic prophylaxis is required particularly in children with VRR. Other indications for antibiotic prophylaxis are recurrent cystitis with or without voiding disturbances, medullary sponge kidneys, kidney duplication with reflux to the lower pole, ectopic ureters, dilatation of the upper urinary tract, ureterocele and neurogenic bladder dysfunction (e.g. MMC or tethered chord syndrome).

## 6.4 REFERENCES

1. **Ahmed SM, Swedlund SK.**  
Evaluation and treatment of urinary tract infections in children.  
*Am Fam Physician* 1998; 57: 1573–1580, 1583–1584.
2. **Alon US, Ganapathy S.**  
Should renal ultrasonography be done routinely in children with first urinary tract infection?  
*Clin Pediatr Phil* 1999; 38: 21–25.
3. **Auringer ST.**  
Pediatric urology update. *Urol Clin North Am* 1997; 24: 673–681.
4. **Bitar CN, Steele RW.**  
Use of prophylactic antibiotics in children. *Adv Pediatr Infect Dis* 1995; 10: 227–262.
5. **Coulthard MG, Lambert HJ, Keir MJ.**  
Occurrence of renal scars in children after their first referral for urinary tract infection.  
*BMJ* 1997; 315: 918–919.
6. **Downs SM.**  
Technical report: urinary tract infections in febrile infants and young children. The Urinary Tract Subcommittee of the American Academy of Pediatrics Committee on Quality Improvement.  
*Pediatrics* 1999; 103: e54.
7. **Hansson S, Martinell J, Stokland E, Jodal U.**  
The natural history of bacteriuria in childhood. *Infect Dis Clin North Am* 1997; 11: 499–512.
8. **Hellerstein S.**  
Urinary tract infections. Old and new concepts. *Pediatr Clin North Am* 1995; 42: 1433–1457.
9. **Nuutinen M, Uhari M, Murphy MF, Hey K.**  
Clinical guidelines and hospital discharges of children with acute urinary tract infections.  
*Pediatr Nephrol* 1999; 13: 45–49.
10. **Rosenfeld DL, Fleischer M, Yudd A, Makowsky T.**  
Current recommendations for children with urinary tract infections. *Clin Pediatr Phila* 1995; 34: 261–264.
11. **Rushton HG.**  
Urinary tract infections in children. Epidemiology, evaluation, and management.  
*Pediatr Clin North Am* 1997; 44: 1133–1169.
12. **Shalaby-Rana E, Lowe LH, Blask AN, Majd M.**  
Imaging in pediatric urology. *Pediatr Clin North Am* 1997; 44: 1065–1089.
13. **Shapiro E, Elder JS.**  
The office management of recurrent urinary tract infection and vesicoureteral reflux in children.  
*Urol Clin North Am* 1998; 25: 725–734.
14. **Smellie JM, Rigden SP.**  
Pitfalls in the investigation of children with urinary tract infection. *Arch Dis Child* 1995; 72: 251–255.

15. **Stapleton A, Stamm WE.**  
Prevention of urinary tract infection. *Infect Dis Clin North Am* 1997; 11: 719–733.
16. **Stark H.**  
Urinary tract infections in girls: the cost-effectiveness of currently recommended investigative routines. *Pediatr Nephrol* 1997; 11: 174–177.
17. **Weidner W, Ringert R-H, Rascher W.**  
Leitlinie zur Harnwegsinfektion im Kindesalter. *Urologe A* 1998; 37: 669–770.
18. **Weiss RA.**  
Update on childhood urinary tract infections and reflux. *Semin Nephrol* 1998; 18: 264–269.
19. **Williams MA, Noe HN, Smith RA.**  
The importance of urinary tract infection in the evaluation of the incontinent child. *J Urol* 1994; 151: 188–190.

## 7. REFLUX

### 7.1 BACKGROUND

VUR or VRR are defined as non-physiological back-flow of urine from the urinary bladder into the ureter or the renal pelvis. The worst consequence of both primary and secondary VRR is the development of progressive renal failure secondary to recurrent pyelonephritic episodes and subsequent loss of renal parenchyma.

Ten to 15% of patients with reflux suffer from a renin-dependent hypertension as a sequela of focal ischaemia due to parenchymal scarring. The probability of hypertension is highly correlated with the extent and number of parenchymal scars. Reflux is found in 0.5–1% of normal children without UTIs. While in newborns the incidence of reflux is the same in both sexes, in later life, girls are approximately four times more frequently affected than boys.

In children with recurrent UTI, the incidence of VUR is significantly higher (about 14–29% of kindergarten and school girls and about 30% of boys of the corresponding age).

The main symptoms of VUR are recurrent and occasionally febrile UTIs. Radiological investigations verify uni- or bilateral reflux in 30–50% of cases. A VRR may also make itself apparent in later stages by its consequences, such as hypertension, renal insufficiency or delayed renal growth. Undetected reflux may lead to reflux nephropathy.

#### 7.7.1 Secondary reflux

Predecessor of a secondary reflux is not an inborn primary disturbance of the terminal ureter, but rather an anatomically or functionally obstructive or inflammatory illness of the bladder, or direct damage to a previously intact orifice. It seems that many refluxes, especially of lower grade I–III, are secondary refluxes and may disappear with the maturation of the bladder function.

### 7.2 CLASSIFICATION

The International Reflux Study Committee introduced a uniform system for the description of reflux, based on the earlier classification by Heikel and Parkkulainen, in 1985. Furthermore, a standardized performance of a voiding cystourethrogram was described to allow comparative studies.

**Table 8: Grading system for reflux**

Grade I	Reflux does not reach the renal pelvis; varying degrees of ureteral dilatation
Grade II	Reflux reaches the renal pelvis; no dilatation of the collecting system; normal fornices
Grade III	Mild or moderate dilatation of the ureter, with or without kinking; moderate dilatation of the collecting system; normal or minimally deformed fornices
Grade IV	Moderate dilatation of the ureter with or without kinking; moderate dilatation of the collecting system; blunt fornices, but impressions of the papillae still visible
Grade V	Gross dilatation and kinking of the ureter, marked dilatation of the collecting system; papillary impressions no longer visible; intraparenchymal reflux

Apart from reflux grading, a description of the position and morphology of the ureteral orifices (normal, stadium, horseshoe or golf-hole orifice) are helpful for planning treatment. The position of an orifice should be categorised as A (trigonal), B, C or D (markedly lateral).

### 7.3 DIAGNOSIS

All patients awaiting clarification of a reflux should undergo a basic diagnostic work up, comprising laboratory tests (kidney function), urine status and urine cultures, together with a detailed medical history and physical examination. Direct evidence of a reflux or its exclusion, obtained by VCUG or sonography supplements the initial diagnosis. An optional IVU is performed before surgery and in any case with an inconclusive sonography. During the examination, a catheter should be in place.

Without exposure to radiation, sonography can provide detailed information on the size of the kidney,

any possible duplicate formations, the shape and size of the collecting system, and also permits assessment of the renal parenchyma. Detection of reflux itself is only possible by using special contrast media and in case of gross reflux.

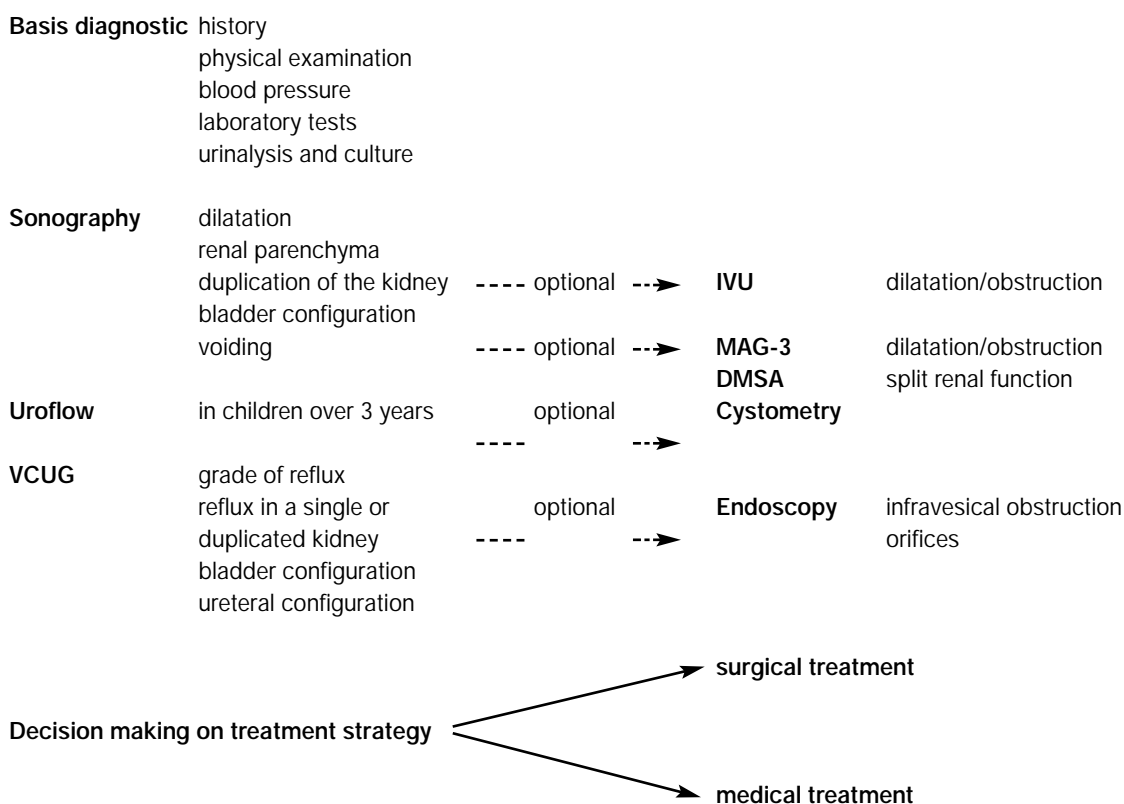
If VCUG or sonography is negative, but clinical evidence of a suspected reflux persists, the examination should be repeated after an interval; the grade of the reflux is not constant under different conditions of examination.

If residual urine is apparent after micturition, without presence of an infravesical obstruction, a urodynamic examination should be performed in order to exclude bladder/sphincter dysfunction and thus secondary reflux.

Evidence of or exclusion of a reflux can also be provided by nuclear medicinal methods. Due to the much lower exposure to radiation, a radionuclide cystography to verify or to exclude reflux can also be used, especially for follow-up examinations.

Endoscopic examination is helpful in case of planned operative treatment and can provide evidence of a pathological configuration of the ureteral orifices and position, as well as the exclusion of infravesical obstruction. The examination is carried out under anaesthesia and preparation made for subsequent reflux correction. For any reflux therapy to be performed endoscopically, the configuration of the ureteral orifices is of greater importance than the reflux grading; in case of a golf-hole orifice, the prospects of success are markedly lower.

**Table 9: Algorithm for the stepwise diagnosis of a primary reflux**



IVU = intravenous urogram; DMSA = di-mercaptosuccinic acid; VCUG = voiding cystourethrography.

### 7.3.1 Secondary reflux

Diagnosis and treatment of the underlying disease are, of course, primary aspects in secondary acquired reflux. If reflux persists after successful treatment of the underlying condition, therapy of reflux is oriented with respect to clinical conditions. In order to diagnose a secondary reflux, it has to be ensured that VCUG was carried out in a non-inflammatory interval and, if necessary, repeated after clearing up the infection. Further diagnosis then proceeds according to the same rules as primary reflux.

## 7.4 TREATMENT

The objective of treatment is the avoidance of late complications, such as reflux nephropathy. Therapeutic options consist of conservative medical treatment and endoscopic or open surgical procedures. The choice is influenced by the age of the patient, the grade of reflux, the position or configuration of the ureteral orifices and the clinical course.

**Table 10: Treatment of reflux I**

1 year		Conservative
1 – 5 year(s)	Grade I - III	Conservative
	Grade IV – V	Surgery
> 5 years	Boys	Indication for surgery is rare
	Girls	Surgery (due to higher rate of infections, esp. during pregnancy)

**Table 11: Treatment of reflux II**

<ul style="list-style-type: none"> <li>• Recurrent febrile infections despite antibiotic prophylaxis</li> <li>• Additional malformation (double kidney, Hutch diverticulum, ectopic ureter)</li> </ul>	
--	--

### 7.4.1 Conservative therapy

The objective of conservative therapy is prevention of febrile UTIs. Along with an ample supply of liquid and regular complete voidance of the bladder (if necessary with double micturition), a good hygiene and a low dosage of prophylactic long-term antibiotics are central aspects of conservative therapy.

The assumption that in some patients VRR disappears without surgical intervention justifies a conservative approach. The chance of a spontaneous improvement only exists, however, for young patients with a low-grade reflux and without serious pathology of the ureteral orifices. If reflux persists up to an age in which spontaneous disappearance can no longer be expected, then girls should be submitted to operative reconstruction. In boys > 5 years, antibiotic prophylaxis may be stopped as the indication for reflux correction is rare. If febrile UTIs occur under antibiotic prophylaxis, the conservative strategy should be omitted and surgical intervention should be planned.

### 7.4.2 Surgical therapy

Surgery should not be performed before the age of 6 months.

### 7.4.3 Endoscopic therapy

Currently, experience with endoscopic treatment as an operative option is limited.

### 7.4.4 Open surgery

Various techniques for reflux correction have been described (e.g. Lich-Gregoir, Politano-Leadbetter, Cohen, Psoas-Hitch), the principle being to lengthen the intramural part of the ureter by submucosal embedding of the ureter. A high success rate of over 95%, with only a small rate of complications, is shared by all surgical procedures.

As a rule, prior to extravesical procedures an endoscopy should be performed, whereas the ureteral orifices can be directly visualized with intravesical operations. Other important technical details are an absolutely tension free ureteral anastomosis, as well as meticulous preservation of the blood supply of the distal ureter. In addition, a sufficient length and width of the tunnel is mandatory.

In case of a bilateral reflux the Lich-Gregoir as well as the Psoas-Hitch procedure should be performed in two stages to prevent bladder dysfunction.

### 7.4.5 Follow-up

After surgical reflux correction, patients require peri-operative antibiotic therapy, this being continued as prophylaxis for 6 weeks post-operatively. Optionally, a VCUG is carried out 3 months post-operatively in order to prove successful reflux correction. Obstruction of the upper urinary tract is ruled out by sonography on patients' discharge and this should be repeated after 4–6 weeks if any sign of obstruction is present. In all other cases, a routine ultrasound is carried out 3 months post-operatively.

All patients with parenchymal damage at the time of reflux correction should receive a control scintigraphy 12 months post-surgery. The follow-up examination should include blood pressure controls for early detection of renal hypertension.

### 7.5 REFERENCES

1. **Aaronson IA, Rames RA, Greene WB, Walsh LG, Hasal UA, Garen PD.**  
Endoscopic treatment of reflux: migration of Teflon to the lungs and brain. *Eur Urol* 1993; 23: 394–399.
2. **Agarwal SK, Khoury AE, Abramson RP, Churchill BM, Argiropoulos G, McLorie GA.**  
Outcome analysis of vesicoureteral reflux in children with myelodysplasia. *J Urol* 1997; 157: 980–982.
3. **Agarwal SK, McLorie GA, Grewal D, Joyner BD, Bagli DJ, Khoury AE.**  
Urodynamic correlates of resolution of reflux in meningomyelocele patients. *J Urol* 1997; 158: 580–582.
4. **Aragona F, D'Urso L, Scremin E, Salmaso R, Glazel GP.**  
Polytetrafluoroethylene giant granuloma and adenopathy: long-term complications following subureteral polytetrafluoroethylene injection for the treatment of vesicoureteral reflux in children. *J Urol* 1997; 158: 1539–1542.
5. **Austenfeld MS, Snow BW.**  
Complications of pregnancy in women after reimplantation for vesicoureteral reflux. *J Urol* 1988; 140: 1103–1106.
6. **Bailey RR, Lynn KL, Robson RA.**  
End-stage reflux nephropathy. *Ren Fail* 1994; 16: 27–35.
7. **Beetz R, Schulte-Wissemann H, Troger J, Reidmiller H, Mannhardt W, Schofer O, Hohenfellner R.**  
Long-term follow-up of children with surgically treated vesicorenal reflux: postoperative incidence of urinary tract infections, renal scars and arterial hypertension. *Eur Urol* 1989; 16: 366–371.
8. **Belman AB.**  
A perspective on vesicoureteral reflux. *Urol Clin North Am* 1995; 22: 139–150.
9. **Belman AB.**  
Vesicoureteral reflux. *Pediatr Clin North Am* 1997; 44: 1171–1190.
10. **Bhatti HA, Khattak H, Boston VE.**  
Efficacy and causes of failure of endoscopic subureteric injection of Teflon in the treatment of primary vesicoureteric reflux. *Br J Urol* 1993; 71: 221–225.
11. **Brühl P, Van AH, Mallmann R.**  
Antireflux procedure by Lich-Gregoir. Indications and results. *Eur Urol* 1988; 14: 37–40.
12. **Cooper A, Atwell J.**  
A long-term follow-up of surgically treated vesicoureteric reflux in girls. *J Pediatr Surg* 1993; 28: 1034–1036.
13. **Craig JC, Irwig LM, Christie J, Lam A, Onikul E, Knight JF, Sureshkumar P, Roy LP.**  
Variation in the diagnosis of vesicoureteric reflux using micturating cystourethrography. *Pediatr Nephrol* 1997; 11: 455–459.
14. **Dewan PA, Goh DW.**  
Subureteric Polytef injection in the management of vesico-ureteric reflux in children. *J Paediatr Child Health* 1994; 30: 324–327.
15. **Dodat H, Takvorian P, Mure PY, Canterino I, Pouillaude JM.**  
Analyse des echecs du traitement endoscopique du reflux vesico renal chez l'enfant par injections de teflon ou de collagene et resultats preliminaires des injections de Macroplastique. *Prog Urol* 1995; 5: 58–68.
16. **Elder JS.**  
Antenatal hydronephrosis. Fetal and neonatal management. *Pediatr Clin North Am* 1997; 44: 1299–1321.
17. **Garin EH, Campos A, Homsy Y.**  
Primary vesicoureteral reflux: review of current concepts. *Pediatr Nephrol* 1998; 12: 249–256.
18. **Heikel PE, Parkkulainen KV.**  
Vesicoureteral reflux in children. *Ann Radiol* 1966; 9: 1–6.
19. **Hjalmas K, Lohr G, Tamminen-Möbius T, Seppanen J, Olbing H, Wikstrom S.**  
Surgical results in the International Reflux Study in Children (Europe). *J Urol* 1992; 148: 1657–1661.

20. **Janetschek G, Reissigl A, Peschel R, Bartsch G.**  
Laparoskopische Eingriffe in der Kinderurologie. *Urologe A* 1994; 33: 31–37.
21. **Janetschek G, Radmayr C, Bartsch G.**  
Laparoscopic ureteral anti-reflux plasty reimplantation. First clinical experience. *Ann Urol Paris* 1995; 29: 101–105.
22. **Jungers P, Houillier P, Chauveau D, Choukroun G, Moynot A, Skhiri H, Labrunie M, Descamps-Latscha B, Grunfeld JP.**  
Pregnancy in women with reflux nephropathy. *Kidney Int* 1996; 50: 593–599.
23. **Kennelly MJ, Bloom DA, Ritchey ML, Panzl AC.**  
Outcome analysis of bilateral Cohen cross-trigonal ureteroneocystostomy. *Urology* 1995; 46: 393–395.
24. **Kershen RT, Atala A.**  
New advances in injectable therapies for the treatment of incontinence and vesicoureteral reflux. *Urol Clin North Am* 1999; 26: 81–94.
25. **Khatib M, Packham DK, Becker GJ, Kincaid Smith P.**  
Pregnancy-related complications in women with reflux nephropathy. *Clin Nephrol* 1994; 41: 50–55.
26. **Lebowitz RL, Olbing H, Parkkulainen KV, Smellie JM, Tamminen-Möbius TE.**  
International system of radiographic grading of vesicoureteric reflux. *Pediatr Radiol* 1985; 15: 105–109.
27. **Linn R, Ginesin Y, Bolkier M, Levin DR.**  
LichGregoir anti-reflux operation: a surgical experience and 520 years of follow-up in 149 ureters. *Eur Urol* 1989; 16: 200–203.
28. **Mackie CG, Stephens FD.**  
Duplex kidneys: A correlation of renal dysplasia with position of the ureteral orifice. *J Urol* 1975; 114: 274–280.
29. **Malek RS, Svensson J, Neves RJ, Torres VE.**  
Vesicoureteral reflux in the adult. III. Surgical correction: risks. *J Urol* 1983; 130: 882–886.
30. **Malizia AA, Reiman HM, Myers RP, Sande JR, Barham SS, Benson RC, Dewanjee MK, Utz WJ.**  
Migration and granulomatous reaction after periurethral injection of Polytef (Teflon). *JAMA* 1984; 251: 3277–3281.
31. **Mansfield JT, Snow BW, Cartwright PC, Wadsworth K.**  
Complications of pregnancy in women after childhood reimplantation for vesicoureteral reflux: an update with 25 years of followup. *J Urol* 1995; 154: 787–790.
32. **McGladdery SL, Aparicio S, Verrier Jones K, Roberts R, Sacks SH.**  
Outcome of pregnancy in an OxfordCardiff cohort of women with previous bacteriuria. *Q J Med* 1992; 83: 533–539.
33. **Merckx L, De Boe V, Braeckman J, Verboven M, Piepsz A, Keuppens F.**  
Endoscopic submucosal Teflon injection (STING): an alternative treatment of vesicoureteric reflux in children. *Eur J Pediatr Surg* 1995; 5: 34–36.
34. **Ortenberg J.**  
Endoscopic treatment of vesicoureteral reflux in children. *Urol Clin North Am* 1998; 25: 151–156.
35. **Piepsz A, Tamminen-Möbius T, Reiners C, Heikkila J, Kivisaari A, Nilsson NJ, Sixt R, Ridson RA, Smellie JM, Soderborg B.**  
Five-year study of medical or surgical treatment in children with severe vesico-ureteral reflux dimercap-tosuccinic acid findings. International Reflux Study Group in Europe. *Eur J Pediatr* 1998; 157: 753–758.
36. **Puri P, Granata C.**  
Multicenter survey of endoscopic treatment of vesicoureteral reflux using polytetrafluoroethylene. *J Urol* 1998; 160: 1007–1011.
37. **Puri P, Ninan GK, Surana R.**  
Subureteric Teflon injection (STING). Results of a European survey. *Eur Urol* 1995; 27: 71–75.
38. **Riedmiller H, Becht E, Hertle L, Jacobi G, Hohenfellner R.**  
Psoas-Hitch ureteroneocystostomy: experience with 181 cases. *Eur Urol* 1984; 10: 145–150.
39. **Riedmiller H, Riedmiller RL, Jacobi GH, Hohenfellner R.**  
Therapie des vesiko-renalen Refluxes im Kindesalter. *Dtsch Med Wochenschr* 1983; 108: 1522–1524.
40. **Riedmiller H, Köhl U.**  
Leitlinie zur Abklärung des vesikorenenalen Reflux und therapeutische Empfehlungen. *Urologe A* 1998; 37: 667–668.
41. **Ritchey ML, Bloom D.**  
Summary of the urology section. *American Academy of Pediatrics. Pediatrics* 1995; 96: 138–143.
42. **Roberts JA.**  
Mechanisms of renal damage in chronic pyelonephritis (reflux nephropathy). *Curr Top Pathol* 1995; 88: 265–287.

43. **Rosenfeld DL, Fleischer M, Yudd A, Makowsky T.**  
Current recommendations for children with urinary tract infections. *Clin Pediatr Phila* 1995; 34: 261–264.
44. **Shapiro E, Elder JS.**  
The office management of recurrent urinary tract infection and vesicoureteral reflux in children. *Urol Clin North Am* 1998; 25: 725–734.
45. **Shoukry MS, El Salmi S, Aly GA, Mokhless I.**  
Urodynamic predictors of upper tract deterioration in children with myelodysplasia. *Scand J Urol Nephrol* 1998; 32: 94–97.
46. **Sirota L, Hertz M, Laufer J, Jonas P, Boichis H.**  
Familial vesicoureteral reflux: a study of 16 families. *Urol Radiol* 1986; 8: 22–24.
47. **Smellie, JM, Rigden SP.**  
Pitfalls in the investigation of children with urinary tract infection. *Arch Dis Child* 1995; 72: 251–255.
48. **Smellie JM, Prescod NP, Shaw PJ, Ridson RA, Bryant TN.**  
Childhood reflux and urinary infection: a follow-up of 10-41 years in 226 adults. *Pediatr Nephrol* 1998; 12: 727–736.
49. **Smellie JM, Rigden SP, Prescod NP.**  
Urinary tract infection: a comparison of four methods of investigation. *Arch Dis Child* 1995; 72: 247–250.
50. **Smellie JM.**  
The intravenous urogram in the detection and evaluation of renal damage following urinary tract infection. *Pediatr Nephrol* 1995; 9: 213–219.
51. **Snodgrass W.**  
The impact of treated dysfunctional voiding on the nonsurgical management of vesicoureteral reflux. *J Urol* 1998; 160: 1823–1825.
52. **Stokland E, Hellstrom M, Hansson S, Jodal U, Oden A, Jacobsson B.**  
Reliability of ultrasonography in identification of reflux nephropathy in children. *BMJ* 1994; 309: 235–239.
53. **Thüroff JW, Altwein JE, Marberger M, Hartmann I, Hohenfellner R.**  
Der primäre vesiko-ureterale Reflux im Erwachsenenalter. *Akt Urol* 1979; 10: 329–339.
54. **Toomey JM, Brown BS.**  
The histological response to intracordal injection of Teflon paste. *Laryngoscope* 1967; 77: 110–120.
55. **Vandenbossche M, Delhove O, Dumortier P, Deneft F, Schulman CC.**  
Endoscopic treatment of reflux: experimental study and review of Teflon and collagen. *Eur Urol* 1993; 23: 386–393.
56. **Williams MA, Noe HN, Smith RA.**  
The importance of urinary tract infection in the evaluation of the incontinent child. *J Urol* 1994; 151: 188–190.
57. **Wingen AM, Koskimies O, Olbing H, Seppanen J, Tamminen-Möbius T.**  
Growth and weight gain in children with vesicoureteral reflux receiving medical versus surgical treatment: 10-year results of a prospective, randomized study. *International Reflux Study in Children (European Branch)*. *Acta Paediatr* 1999; 88: 56–61.



## 8. PAEDIATRIC NEPHROLITHIASIS

### 8.1 BACKGROUND

Stone disease in children is uncommon and stone formation is often associated with metabolic disorders, chronic infections and/or morphological anomalies of the urinary tract. Recurrence rate is only high in cases of metabolic disorders and may be the initial manifestation of a congenital and subsequently chronic disease. It is important to realize that stone formation is not a disease in itself, but a consequence of an underlying disorder. Treatment of paediatric nephrolithiasis must therefore comprise a strategy to clear the actual stone burden reliably, diagnose and, ideally, eliminate the underlying pathology. Effective measures should be taken to prevent recurrent disease.

### 8.2 DIAGNOSIS

Children are considered to be high-risk patients and need a full metabolic work up. The patient's history is particularly important as many metabolic disorders are hereditary [e.g. autosomal recessive disorders (cystinuria, primary hyperoxaluria, 2,8-dihydroxyadenine and xanthine calculi); autosomal dominant disorders (renal tubular acidosis, idiopathic hypercalciuria)]. In cases of a positive family history, an unfavourable clinical course has to be reckoned with.

In children, hypercalciuria with hypercalcaemia is frequently caused by immobilization (e.g. during fracture treatment). Another rare condition is hyperparathyroidism. As stone formation only occurs in a subset of immobilized children, a complete metabolic work up should be performed, as other metabolic disorders may facilitate the manifestation.

It must also be emphasized that the normal values of the excretion rate of lithogenous and inhibitory agents in adults cannot be applied to children, but requires correction for body weight (mmol/kg/d) as below. Variation between laboratories must also be considered.

**Table 12: Critical values for renal excretion in children: when to start therapy**

	mmol/kg*d <sup>-1</sup>
Calcium	> 0.1
Oxalate	> 0.0063
Uric acid	> 0.063
Citrate*	< 0.01
Cystine	heterozygous 0.0058–0.0117 homozygous > 0.024
Magnesium	< 0.045
Phosphate	> 0.483

\*Please note the presence of citrate splitting bacteria in the urine sample

### 8.3 TREATMENT

The first-line treatment of paediatric nephrolithiasis in the absence of obstructive uropathy is extracorporeal shock wave lithotripsy (ESWL). When planning interventional stone therapy in children the necessity of general anaesthesia must be taken into account for percutaneous litholapaxy (PNL), ureterorenoscopy (URS) and, depending on the child's age, for ESWL. For this reason, the treatment option with the highest probability of success in a single or at most two sessions should be chosen. In a few cases, this can only be achieved by open surgery, which, generally, is indicated if obstruction of the urinary tract requires correction in the same session.

Several factors affect interventional stone treatment in children: size, localization and composition of the calculus, and urinary tract configuration. With larger stones, the probability of a single ESWL session for complete clearance decreases. Disintegration is particularly difficult in cystine calculi. The size of the stone must be viewed in relation to the size of the kidney and the draining system. A stone or a fragment may lead to

serious complications in children because of the narrow ureteral lumen. On the other hand, a relatively large stone may pass more easily than in adults.

Indications and complications of interventional stone therapy in children are similar to those in adults. Even problems with Steinstrasse are much less frequent in children. The ESWL treatment of children less than 100 cm in height was initially thought to be impossible. That has changed with special positioning techniques (e.g. protecting the lungs with polystyrene) and lithotriptors with a more confined shock wave focus. Detrimental long-term effects on renal function and growth have been ruled out in recent studies.

In small children, general anaesthesia is mandatory. Percutaneous endoscopic procedures can be performed safely in children beyond their fourth year of life. Ureteroscopy is also an option in the treatment of nephrolithiasis in children.

### 8.3.1 Conservative treatment

Conservative stone treatment of paediatric nephrolithiasis follows the same rules as in adult patients (e.g. medical dissolution of uric acid stones, antibiotic agents for infection stones).

### 8.3.2 Metaphylaxis of paediatric nephrolithiasis

Metaphylaxis of paediatric nephrolithiasis follows the principles detailed in the AWMF guidelines. (2) Dosage of metaphylactic drugs, however, requires appropriate adaptation. Examples of adapted dosages are given below.

**Table 13: Metaphylaxis in paediatric nephrolithiasis: corrected dosages**

Urinary excretion	30–40 mL/kg*d <sup>-1</sup>
Sodium/potassium citrate	0.9–2.0 mEq/kg*d <sup>-1</sup>
Allopurinol	4 mg/kg*d <sup>-1</sup>
Magnesium	5.7 mg/kg*d <sup>-1</sup>
Ammonium chloride test	100 mg/kg*d <sup>-1</sup>

Metaphylaxis of paediatric nephrolithiasis also includes a high fluid intake, nutritional and dietetic aspects. In patients with metabolic disease (e.g. cystinuria, renal tubular acidosis, hypercalciuria, rare cases of enzymatic defects [uric acid]), only a medical metaphylaxis should be considered.

## 8.4 REFERENCES

- Brändle E, Hautmann R.**  
Leitlinie zum Harnsteinleiden bei Kindern. [http://www.dgu.de/lei/5\\_98.htm](http://www.dgu.de/lei/5_98.htm).
- Brändle E, Hautmann R.**  
Leitlinie zur Metaphylaxe des Harnsteinleidens: <http://www.rz.uni-duesseldorf.de/www/AWMF/II/urol-026.htm> (Arbeitsgemeinschaft der Wissenschaftlichen Medizinischen Fachgesellschaften).
- al Busaidy SS, Prem AR, Medhat M, Giriraj D, Gopakumar P, Bhat HS.**  
Paediatric ureteric calculi: efficacy of primary in situ extracorporeal shock wave lithotripsy. *Br J Urol* 1998; 82: 90–96.
- Carvajal Busslinger MI, Gygi C, Ackermann D, Kaiser G, Bianchetti M.**  
Urolithiasis in childhood: when to do what? *Eur J Pediatr Surg* 1994; 4: 199–200.
- Cohen TD, Ehreth J, King LR, Preminger GM.**  
Pediatric urolithiasis: medical and surgical management. *Urology* 1996; 47: 292–303.
- Diamond DA, Rickwood AM, Lee PH, Johnston JH.**  
Infection stones in children: a twenty-seven-year review. *Urology* 1994; 43: 525–527.
- Drach GW.**  
Metabolic evaluation of pediatric patients with stones. *Urol Clin North Am* 1995; 22: 95–100.
- Esen T, Krautschick A, Alken P.**  
Treatment update on pediatric urolithiasis. *World J Urol* 1997; 15: 195–202.
- Goel MC, Baserge NS, Bbu RV, Sinha S, Kapoor R.**  
Pediatric kidney: functional outcome after extracorporeal shock wave lithotripsy. *J Urol* 1996; 155: 2044–2046.
- Grasso M, Chalik Y.**  
Principles and applications of laser lithotripsy: experience with the holmium laser lithotrite. *J Clin Laser Med Surg* 1998; 16: 3–7.
- Gros DA, Thakkar RN, Lakshmanan Y, Ruffing V, Kinsman SL, Docimo SG.**  
Urolithiasis in spina bifida. *Eur J Pediatr Surg* 1998; 8 Suppl 1: 68–69.

12. **Gschwend JE, Haag U, Hollmer S, Kleinschmidt K, Hautmann RE.**  
Impact of extracorporeal shock wave lithotripsy in pediatric patients: complications and long-term follow-up. *Urol Int* 1996; 56: 241–245.
13. **Harmon EP, Neal DE, Thomas R.**  
Pediatric urolithiasis: review of research and current management. *Pediatr Nephrol* 1994; 8: 508–512.
14. **Hasanoglu E, Bunyan N, Tumer L, Bozkirili I, Demirel F, Karoglan U.**  
Extracorporeal shock wave lithotripsy in children. *Acta Paediatr* 1996; 85: 377–379.
15. **Husmann DA, Milliner DS, Segura JW.**  
Ureteropelvic junction obstruction with concurrent renal pelvic calculi in the pediatric patient: a long-term followup. *J Urol* 1996; 156: 741–743.
16. **Kamoun A, Zghal A, Daudon M, Ben Ammar S, Zerelli L, Abdelmoula J, Chauachi B, Houissa T, Belkahia C, Lakhoua R.**  
La lithiase urinaire de l'enfant: contributions de l'anamnese, de l'exploration biologique et de l'analyse physique des calculs au diagnostic etiological. *Arch Pediatr* 1997; 4: 629–638.
17. **Knipper A, Thomas S, Bohle A, Jocham D.**  
Ureterorenoskopie bei Kindern. *Urologe A* 1995; 34: 494–498.
18. **Kovacevic L, Kovacevic S, Smoljanic Z, Peco-Antic A, Kostic N, Gajic M, Kovacevic N, Jovanovic O.**  
Funkcije tubula bubrega kod dece s hiperkalciurijom. *Srp Arh Celok Lek* 1998; 126: 223–227.
19. **Kovacevic L, Kovacevic S, Smoljanic Z, Peco-Antic A, Kostic N, Gajic M, Kovacevic N, Jovanovic O.**  
Lzlučivanje natrijuma kod dece s litogenim poremećajima. *Srp Arh Celok Lek* 1998; 126: 321–326.
20. **Kroovand RL.**  
Pediatric urolithiasis. *Urol Clin North Am* 1997; 24: 173–184.
21. **Lifshitz DA, Lingeman JE, Zafar PS, Hollensbe OW, Nghuis AW, Evan AP.**  
Alterations in predicted growth rates of pediatric kidneys treated with extracorporeal shockwave lithotripsy. *J Endourol* 1998; 12: 469–475.
22. **Lim DJ, Walker RD, Ellsworth PI, Newman RC, Cohen MS, Barraza MA, Stevens PS.**  
Treatment of pediatric urolithiasis between 1984 and 1994. *J Urol* 1996; 156: 702–705.
23. **Longo JA, Netto NR Jr.**  
Extracorporeal shock-wave lithotripsy in children. *Urology* 1995; 46: 550–552.
24. **Minevich E, Rousseau MB, Wacksman J, Lewis AG, Sheldon CA.**  
Pediatric ureteroscopy: technique and preliminary results. *J Pediatr Surg* 1997; 32: 571–574.
25. **Miyake O, Yoshimura K, Yoshioka T, Koide T, Okuyama A.**  
High urinary excretion level of citrate and magnesium in children: potential etiology for the reduced incidence of pediatric urolithiasis. *Urol Res* 1998; 26: 209–213.
26. **Moazam F, Nazir Z, Jafarey AM.**  
Pediatric urolithiasis: to cut or not to cut. *J Pediatr Surg* 1994; 29: 761–764.
27. **Mor Y, Elmasry YE, Kellett MJ, Duffy PG.**  
The role of percutaneous nephrolithotomy in the management of pediatric renal calculi. *J Urol* 1997; 158: 1319–1321.
28. **Nazli O, Cal C, Ozyurt C, Gunaydin G, Cureklibatir I, Avci V, Erhan O.**  
Results of extracorporeal shock wave lithotripsy in the pediatric age group. *Eur Urol* 1998; 33: 333–336.
29. **Pelzer JO, Leumann E, Schwobel MG.**  
The role of surgery and lithotripsy in childhood urolithiasis. *Eur J Pediatr Surg* 1994; 4: 196–198.
30. **Picramenos D, Deliveliotis C, Alexopoulou K, Mkrichoritis C, Kostakopoulos A, Dimopoulos C.**  
Extracorporeal shock wave lithotripsy for renal stones in children. *Urol Int* 1996; 56: 86–89.
31. **Rasheed K, Memon A.**  
Ureterorenoscopy in children. *J Pak Med Assoc (JPMA)* 1994; 44: 195–196.
32. **Reusz GS, Dobos M, Byrd D, Sallay P, Miltenyi M, Tulassay T.**  
Urinary calcium and oxalate excretion in children. *Pediatr Nephrol* 1995; 9: 39–44.
33. **Rodman JS.**  
Struvite stones. *Nephron* 1999; 81 Suppl 1: 50–59.
34. **Rosenfeld DL, Preston MP, Salvaggi Fadden K.**  
Serial renal sonographic evaluation of patients with Lesch-Nyhan syndrome. *Pediatr Radiol* 1994; 24: 509–512.
35. **Schultz-Lampel D, Lampel A, Lazica M, Thüroff JW.**  
Extrakorporale Stosswellenlithotripsie im Kindesalter. *Urologe A* 1997; 36: 200–208.
36. **Shroff S, Watson GM.**  
Experience with ureteroscopy in children. *Br J Urol* 1995; 75: 395–400.

37. **Stapleton FB.**  
What is the appropriate evaluation and therapy for children with hypercalciuria and hematuria?  
Semin Nephrol 1998; 18: 359–360.
38. **Van Horn AC, Hollander JB, Kass EJ.**  
First and second generation lithotripsy in children: results, comparison and followup.  
J Urol 1995; 153: 1969–1971.

# 9. OBSTRUCTIVE PATHOLOGY OF RENAL DUPLICATION: URETEROCELE AND ECTOPIC URETER

## 9.1 BACKGROUND

Ureterocele and ectopic ureter are the two main anomalies associated with a complete renal duplication. At present, antenatal ultrasonography detects both conditions in the majority of cases and diagnosis is confirmed at birth by physical examination, radiography and, occasionally, cystoscopy. In other cases, for example in adults, these anomalies are revealed by clinical symptoms: UTI, disturbances of micturition and urinary incontinence.

### 9.1.1 Ureterocele

Ureterocele is a cystic dilatation developed on the intravesical part of the ureter corresponding to the upper pole of a renal duplication. It is more frequent in females than in males, the overall prevalence being 1 in 4,000 births.

### 9.1.2 Ectopic ureter

Ectopic ureter is less frequent than ureterocele (1 in 40,000 births), but is again more common in females (male to female ratio, 1:5). Eighty percent of ectopic ureters are associated with a complete renal duplication.

In females, the ureteral orifice may be located:

- In the urethra, from bladder neck to meatus (35%)
- In the vaginal vestibule (30%)
- In the vagina (25%)
- In the uterus and Fallopian tube (rarely)

In males, the ureteral orifice may be located:

- In the posterior urethra above the verumontanum and never below the external sphincter (60%)
- In the seminal tract (vas deferens, ejaculatory ducts, seminal vesicles) (40%)

## 9.2 CLASSIFICATION

Ureteroceles are usually obstructive for the upper pole moiety, but the degree of obstruction and functional impairment is variable according to the type of ureterocele and upper pole dysplasia. In the orthotopic form, there is often no or only mild obstruction and frequently the function of the moiety is normal or slightly impaired; the corresponding ureter may be dilated. In the ectopic form, the upper pole is altered, frequently dysplastic and hypofunctional or non-functional. The corresponding ureter is a dolichomegareter. In the caecoureterocele, the upper pole of the renal duplication is always dysplastic and non-functional.

### 9.2.1 Ectopic ureterocele

Ectopic ureterocele is the most common form of ureterocele (> 80%) and occurs bilaterally in about 40% of cases. It is voluminous, dissociating the trigone and slipping into the urethra, and can rarely prolapse through the urethral meatus. The ureterocele orifice is tight, rarely large, located near the bladder neck either in the bladder itself or in the urethra below the bladder neck. The ureter corresponding to the lower pole moiety is raised by the ureterocele and frequently refluxing or compressed by the ureterocele, leading to an obstructive megareter. A contralateral renal duplication is associated in 50% of cases. Occasionally, very large ureteroceles are responsible for reflux or obstruction of the contralateral upper tract.

### 9.2.2 Orthotopic ureterocele

Orthotopic ureterocele accounts for 15% of cases. It is exclusively observed in females, and is small and located strictly intravesically. Orthotopic ureteroceles are mostly combined with a single kidney system.

### 9.2.3 Caecoureterocele

Caecoureterocele is very rare, occurring in less than 5% of cases. It is small, associated with an ectopic ureter and located in the urethra below the bladder neck.

## 9.3 DIAGNOSIS

### 9.3.1 Ureterocele

Prenatal ultrasound reveals easily voluminous obstructive ureteroceles. In cases of a very small upper pole or a slightly obstructive ureterocele, prenatal diagnosis will be difficult. If prenatal diagnosis has been impossible, the following clinical symptoms – beside incidental findings – can reveal the congenital anomaly at birth or later:

1. At birth, a prolapsed and sometimes strangulated ureterocele may be observed in front of the urethral orifice. In a neonate boy, it might cause acute urinary retention, simulating urethral valves.
2. The early symptom of pyelonephritis in either sex may lead to the diagnosis.
3. Later symptoms can include dysuria, recurrent cystitis and urgency.

In cases of prenatal diagnosis at birth, ultrasonography confirms the ureteral dilatation ending at the upper pole of a renal duplication. It also demonstrates the presence of an ureterocele in the bladder, with a dilated ureter behind the bladder.

At this point it is important to assess the function of the upper pole using excretory urography and/or nuclear renography in the region of interest. Urography might visualize the morphological status of the upper pole and lower moieties and of the contralateral kidney. A VCUG is mandatory in identifying an ipsilateral or contralateral reflux and to assess the degree of intraurethral prolapse of the ureterocele.

When the differential diagnosis between ureterocele and ectopic megaureter is difficult, urethrocystoscopy might reveal the pathology.

### 9.3.2 Ectopic ureter

Most of the ectopic megaureters are diagnosed primarily by ultrasound. In some cases, clinical symptoms can lead to diagnosis:

1. In neonates: pyuria and acute pyelonephritis.
2. In older girls: dribbling incontinence with concurrent normal micturition is characteristic. In such cases, the ectopic orifice may be found in the meatal region. Significant fluor vaginalis may be the equivalent of incontinence in little girls.
3. In pre-adolescent males: epididymitis is the usual clinical presentation and a palpable seminal vesicle may be found on digital rectal examination.

Ultrasonography, excretory urography, nuclear studies, VCUG and cystoscopy are the diagnostic tools to assess the function, to detect reflux and to rule out ipsilateral compression of the lower pole and urethral obstruction. In the clarification of incontinence in girls, a methylene blue filling of the bladder can be helpful: in case of loss of uncoloured urine, an ectopic ureter must be present. It is rarely necessary to perform a CT scan to find a small upper pole moiety invisible on IVU or by sonography.

## 9.4 TREATMENT

### 9.4.1 Ureterocele

The management is controversial between endoscopic decompression, partial nephro-ureterectomy or complete primary reconstruction. The choice of a therapeutic modality depends on the following criteria: clinical status of the patient (e.g. urosepsis), age of the patient, renal function of the upper pole, presence or absence of reflux, obstruction of the ipsilateral ureter and pathology of the contralateral ureter.

#### *Early diagnosis*

1. In a clinically asymptomatic child with an ureterocele and non- or hypofunctional upper pole, without significant obstruction of the lower pole and without bladder outlet obstruction, a prophylactic antibiotic treatment is given for 3 months until surgery is performed.
2. In the presence of obstruction of the lower pole ureter or of the contralateral ureter, or urethral obstruction, an immediate endoscopic incision or puncture is recommended in combination with prophylactic antibiotic treatment. After 3 months a re-evaluation is performed.

Re-evaluation: If decompression is effective and there is no reflux (approximately 25%), medical treatment is stopped and follow-up is based on urine cultures and ultrasound. If decompression is not effective or significant reflux is present or obstruction of the ipsi- or contralateral ureters and/or bladder neck obstruction, secondary surgery is necessary varying from partial nephrectomy to complete unilateral reconstruction (depending on upper pole function).

#### *Late diagnosis*

1. Non-functional upper pole, no further pathology: heminephro-ureterectomy is the method of choice.
2. Presence of significant reflux or obstruction: excision of the ureterocele and re-implantation of the ureter/ureters, heminephro-ureterectomy according to the function of the upper pole.

Bladder outlet obstruction caused by ureterocele: endoscopic incision might be an optional therapy, with awareness of secondary surgery in the majority of the patients.

#### **9.4.2 Ectopic ureter**

In the majority of cases, the upper pole is dysplastic and requires heminephro-ureterectomy. For the exceptional case in which the upper pole has function worth preserving, ureteral re-implantation into the bladder or ureteropyelostomy in combination with partial ureterectomy are therapeutic options.

### **9.5 REFERENCES**

#### *Ureterocele*

1. **Austin PF, Cain MP, Casale AJ, Hiatt AK, Rink RC.**  
Prenatal bladder outlet obstruction secondary to ureterocele. *Urology* 1998; 52: 1132–1135.
2. **Borer JG, Cisek LJ, Atala A, Diamond DA, Retik AB, Peters CA.**  
Pediatric retroperitoneoscopic nephrectomy using 2 mm instrumentation. *J Urol* 1999; 162: 1725–1729; discussion 1730.
3. **Cain MP, Pope JC, Casale AJ, Adams MC, Keating MA, Rink RC.**  
Natural history of refluxing distal ureteral stumps after nephrectomy and partial ureterectomy for vesicoureteral reflux. *J Urol* 1998; 160: 1026–1027.
4. **Cendron J, Melin Y, Valayer J.**  
Traitement simplifié de l'urétérocele chez l'enfant. A propos de 35 cas. *Chir Pédi* 1980; 21: 121–124.
5. **Decter RM, Roth DR, Gonzales ET.**  
Individualized treatment of ureteroceles. *J Urol* 1989; 142: 535–537.
6. **Di Benedetto V, Montfort G.**  
How prenatal ultrasound can change the treatment of ectopic ureterocele in neonates? *Eur J Pediatr Surg* 1997; 7: 338–340.
7. **El Ghoneimi A, Lottmann H, Odet E, Bonnin F, Aigrain Y.**  
L'urétéropyélostomie dans les duplicités obstructives, une intervention simple et fiable chez l'enfant. *Ann Urol (Paris)* 1998; 32: 241–246.
8. **Husmann D, Strand B, Ewalt D, Clement M, Kramer S, Allen T.**  
Management of ectopic ureterocele associated with renal duplication: a comparison of partial nephrectomy and endoscopic decompression. *J Urol* 1999; 162: 1406–1409.
9. **Janetschek G, Seibold J, Radmayr C, Bartsch G.**  
Laparoscopic heminephroureterectomy in pediatric patients. *J Urol* 1997; 158: 1928–1930.
10. **Jayanthi VR, Koff SA.**  
Long-term outcome of transurethral puncture of ectopic ureteroceles: initial and late problems. *J Urol* 1999; 162: 1077–1080.
11. **Moscovici J, Galinier P, Berrogain N, Juricic M.**  
Traitement des urétéroceles avec duplicité pyélo-urétérale chez l'enfant. A propos de 64 observations. *Ann Urol (Paris)* 1999; 33: 369–376.
12. **Montfort G, Ruys JM, Coquet M, Roth K, Louis C, Bocciardi A.**  
Surgical management of duplex ureteroceles. *J Ped Surg* 1992; 27: 634–638.
13. **Pfister C, Ravasse P, Barret E, Petit T, Mitrofanoff P.**  
The value of endoscopic treatment for ureteroceles during the neonatal period. *J Urol* 1998; 159: 1006–1009.
14. **Rickwood AMK, Reiner I, Jones M, Pournaras C.**  
Current management of duplex system ureteroceles: experience with 41 patients. *Br J Urol* 1992; 70: 196–200.
15. **Roy GT, Desai S, Cohen RC.**  
Ureteroceles in children: an ongoing challenge. *Pediatr Surg Int* 1997; 12: 44–48.
16. **Sherz HC, Kaplan GW, Packer MG, Brock WA.**  
Ectopic ureteroceles surgical management with preservation of continence. Review of 60 cases. *J Urol* 1989; 142: 538–541.
17. **Stephens D.**  
Coeco-ureteroceles and concepts on the embryology and etiology of ureteroceles. *Aust – New Zeal J Surg* 1971; 40: 239–248.

### ***Ectopic ureter***

1. **Carico C, Lebowitz RL.**  
Incontinence due to an infrasphincteric ectopic ureter: why the delay in diagnosis and what the radiologist can do about it. *Pediatr Radiol* 1998; 28: 942-949.
2. **Cendron J, Schulman CC.**  
Ectopie urétérale. In: *Urologie pédiatrique*. Flammarion Médecine Sciences: Paris, 1985, 147-153.
3. **El Ghoneimi A, Miranda J, Truong T, Montfort G.**  
Ectopic ureter with complete ureteric duplication: conservative surgical management. *J Pédiatr Surg* 1996; 31: 467-472.
4. **Komatsu K, Niikura S, Maeda Y, Ishiura Y, Yokoyama O, Namiki M.**  
Single ectopic vaginal ureter diagnosed by computed tomography. *Urol Int* 1999; 63: 147-150.
5. **Plaire JC, Pope JC, Kropp BP, Adams MC, Keating MA, Rink RC, Casale AJ.**  
Management of ectopic ureters: experience with the upper tract approach. *J Urol* 1997; 158: 1245-1247.
6. **Robert M, Ennouchi JM, Chevallier P, Guiter J, Averous M.**  
Diagnostic des abouchements ectopiques de l'uretère dans le tractus séminal. *Progr Urol* 1993; 3: 1028-1033.
7. **Smith FL, Ritchie EL, Maizels M, Zaontz MR, Hsueh W, Kaplan WE, Firlit CF.**  
Surgery for duplex kidneys with ectopic ureters: ipsilateral ureteroureterectomy versus polar nephrectomy. *J Urol* 1989; 142: 532-534.
8. **Sumfest JM, Burns MW, Mitchell ME.**  
Pseudoureterocele: potential for misdiagnosis of an ectopic ureter as a ureterocele. *Br J Urol* 1995; 75: 401-405.

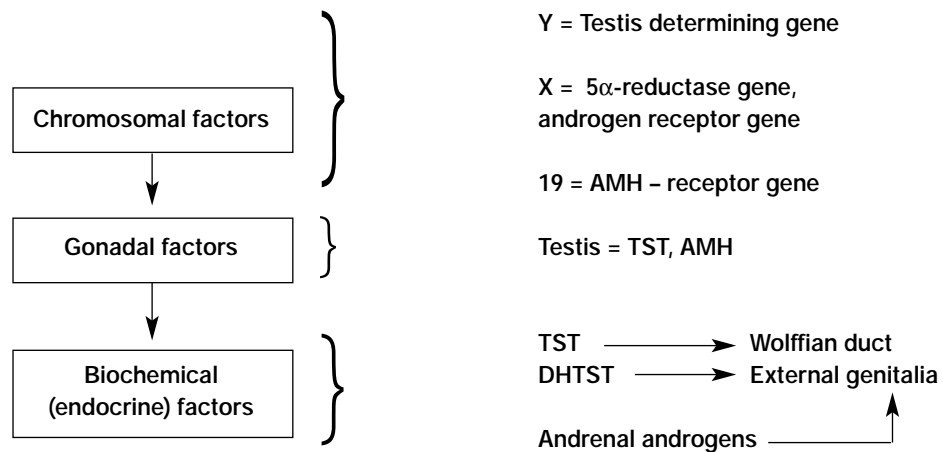


# 10. INTERSEX (ABNORMAL SEXUAL DIFFERENTIATION)

## 10.1 BACKGROUND

Disorders of sexual differentiation most often manifest themselves by the abnormal appearance of the external genitalia as the baby is born, casting doubt on the baby's gender and a lot of anxiety on his/her family. The anatomy and physiology of differentiation of the internal and external sexual organs in the foetus is regulated by factors at three different levels.

**Table 14: Factors involved in normal sexual differentiation**

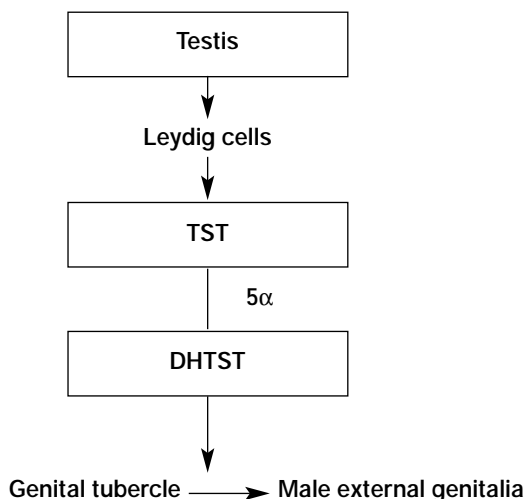


TST = testosterone; AMH = anti-Mullerian hormone; DHTST = dihydrotestosterone

With very few exceptions, a normal 46XX or 46XY karyotype leads to normal sex determination and gonadal differentiation. The presence of the so-called SRY gene (sex-determining region Y) on the short arm of the Y chromosome leads to differentiation of the foetal gonad into testis, while the absence of one X chromosome (i.e. 45XO) will lead to early loss of gonadal germ cells and ovarian fibrous degeneration.

The normally functioning foetal testis induces further somatic male differentiation by means of: a) anti-Mullerian hormone (AMH), secreted by the Sertoli cells, which is responsible for Mullerian duct regression; and b) testosterone (TST) secreted by the Leydig cells, which is responsible for the maintenance and male differentiation of the Wolffian ducts and virilization of the urogenital sinus and external genitalia (genital tubercle), after its intracellular conversion to dihydrotestosterone (DHTST) by 5 $\alpha$  reductase.

**Table 15: Somatic male differentiation via testicular hormones**



Both AMH and DHTST need the presence of their respective cellular receptors in order to exercise their function. Disorders of AMH or TST (DHTST) biosynthesis or action may lead to intersex states. The fact that the androgen-receptor gene lies on the X chromosome explains the virilization of the female foetus in the AGS.

**Table 16: Effects of inadequate biosynthesis or action of AMH, TST or DHTST**

AMH↓	Retention of Mullerian structures
TST↓	Inadequate differentiation of Wolffian duct structures (i.e. epididymis, vas deferens, seminal vesicles)
DHTST↓	Inadequate differentiation of genital tubercle → inadequate masculinization of external genitalia (severe hypospadias, microphallus)

AMH = anti-Mullerian hormone, TST = testosterone, DHTST = dihydrotestosterone

## 10.2 CLASSIFICATION

The classification proposed by Allen in 1976 (based on gonadal histology with subclassifications made primarily by aetiology), has the advantage that gonadal histology is less uncertain to interpret than is dependence on karyotype or morphology of the external genitalia.

**Table 17: Classification of intersex states (modified from Allen 1976). Major categories grouped by gonadal histology, subclassification by aetiology**

<p><b>I. Ovary only = female pseudohermaphrodite → karyotype 46XX</b></p> <p>A. Secondary to endogenous androgens (CAH)</p> <ul style="list-style-type: none"> <li>21-hydroxylase deficiency</li> <li>11β-hydroxylase deficiency</li> <li>3β-ol-dehydrogenase deficiency</li> </ul> <p>B. Secondary to maternal androgens (exogenous ingestion – endogenous production)</p> <p><b>II. Testis only = male pseudohermaphrodite → karyotype 46XY</b></p> <p>A. Secondary to inadequate androgen (TST) production</p> <ul style="list-style-type: none"> <li>20α-hydroxylase deficiency</li> <li>3β-ol-dehydrogenase deficiency</li> <li>17α-hydroxylase deficiency</li> <li>17,20-desmolase deficiency</li> <li>17-ketosteroid reductase deficiency</li> </ul> <p>B. Secondary to inadequate conversion of TST to DHTST → 5α reductase deficiency</p> <p>C. Secondary to inadequate androgen (TST/DHTST) utilization (androgen receptor deficiency)</p> <ul style="list-style-type: none"> <li>Incomplete</li> <li>Complete (testicular feminization)</li> </ul> <p>D. Secondary to deficient AMH → hernia uteri inguinalis</p> <p><b>III. Testis plus ovary = true hermaphrodite → Karyotype 46XY, 46XX, mosaic</b></p> <p><b>IV. Testis plus streak = mixed gonadal dysgenesis → karyotype most often 45XO/46XY</b></p> <p><b>V. Streak plus streak = pure gonadal dysgenesis → karyotype 45XO (Turner's syndrome), 46XX, 46XY</b></p> <p><b>VI. Miscellaneous (? Dysgenetic testes ? teratogenic factors)</b></p>
---

CAH = congenital adrenal hyperplasia; TST = testosterone; AMH = anti-Mullerian hormone; DHTST = dihydrotestosterone.

### 10.2.1 Ovary only (female pseudohermaphrodite)

46XX patients with normal ovaries and uterus, with virilized external genitalia due to the endogenous overproduction of androgens by the foetal adrenal glands (CAH, AGS). These patients account for approximately two-thirds of intersex states in clinical practice.

### 10.2.2 Testis only (male pseudohermaphrodite)

46XY patients with inadequate virilization of the external genitalia due to deficient biosynthesis of TST, inadequate conversion of TST to DHTST (lack of 5 $\alpha$ -reductase) or inadequate TST/DHTST utilization (lack of androgen receptors). Also patients with AMH deficiency with adequate male external genitalia and retained Mullerian structures, i.e. tubes and uterus (hernia uteri inguinalis).

### 10.2.3 Testis plus ovary (true hermaphrodite)

Patients possess both ovarian and testicular tissue in various combinations. Their karyotype varies, i.e. 46XX, 46XY or mosaic 46XX/46XY. True hermaphrodites make up approximately 10% of intersex cases.

### 10.2.4 Testis plus streak gonad (mixed gonadal dysgenesis)

The second most common category of intersexuality. Most common karyotype 45XO/46XY mosaicism. The existing testis is infertile and Mullerian structures may be present on both sides. There is a high risk of gonadoblastoma of the existing testis after puberty.

### 10.2.5 Streak plus streak (pure gonadal dysgenesis)

Phenotypic females with bilateral gonadal streaks with three subgroups of karyotypes: 45XO (Turner's syndrome), 46XX and 46XY. The latter subgroup is particularly prone to malignant degeneration of the streak gonads.

## 10.3 DIAGNOSIS

### 10.3.1 The neonatal emergency

The first step is to explain the situation to the parents fully and kindly, and delay registering and naming the newborn as long as this is necessary. A careful family history must be taken and the baby carefully examined.

**Table 18: Diagnostic work up of neonates with ambiguous genitalia**

Good history (family, maternal, neonatal)
Parental consanguinity
Previous intersex disorders or genital anomalies
Previous neonatal deaths
Primary amenorrhoea or infertility in other family members
Maternal exposure to androgens
Failure to thrive, vomiting, diarrhoea of the neonate
Physical examination
Pigmentation of genital and areolar area
Hypospadias or sinus urogenitalis
Size of phallus
Palpable and/or symmetrical gonads
Blood pressure
Investigations
Buccal smear
Blood: 17-hydroxyprogesterone, electrolytes, LH, FSH, TST, Cortisol, ACTH
Urine: adrenal steroids
Karyotype
Ultrasound
Genitogram
HCG stimulation test
Androgen binding studies
Endoscopy

LH = luteinizing hormone; FSH = follicle stimulating hormone; TST = testosterone; HCG = human chorionic gonadotrophin  
ACTH = adrenocortico tropic hormone

It must be remembered that if one can feel a gonad it is almost certainly a testis, therefore this clinical finding virtually excludes female pseudohermaphrodites (i.e. CAH). The following laboratory investigations are mandatory:

- Buccal smear (if available with accuracy)
- Plasma 17-OH-progesteron assay
- Plasma electrolytes

These investigations will give evidence of CAH, which is the most frequent intersex disorder, and if this is the case no further investigation is needed. Otherwise the laboratory work up proceeds accordingly. The HCG stimulation test is particularly helpful in differentiating the main syndromes of male pseudohermaphrodites and in evaluating Leydig cell potential and phallic growth potential.

HCG stimulation test in male pseudohermaphrodites:

- Normal increase in both TST and DHTST = androgen insensitivity syndrome
- Subnormal increase in both TST and DHTST with increasing androgen precursors = TST biosynthetic block
- Normal increase in TST but subnormal increase in DHTST = 5 $\alpha$  reductase deficiency.

The following rules of thumb can be applied regarding a precise diagnosis:

- Positive buccal smear test and no palpable gonads is CAH or female pseudohermaphrodite due to maternal exposure to androgens. In the case of CAH, immediate medical therapy must be instituted (corticosteroid substitution, electrolyte and blood pressure monitoring).
- Negative buccal smear test and one or two gonads palpable (more often inguinal) – if there are Mullerian duct structures, then the anomaly concerns gonadal dysgenesis or true hermaphroditism; if there are no Mullerian duct structures, the anomaly concerns a male hermaphrodite due either to abnormal TST biosynthesis, inadequate conversion of TST to DHTST (5 $\alpha$ -reductase deficiency) or receptor anomaly (androgen insensitivity syndrome)

The decision for appropriate sex assignment is taken on account of a precise aetiological diagnosis and the functional potential of the genitalia. Schematically this practical outline can be applied:

- Female pseudohermaphrodites (i.e. CAH) should be reared as female since genitoplasty can correct virilization, and spontaneous puberty, sexual intercourse and fertility are to be expected.
- Male pseudohermaphrodites with an inadequate phallus should be given androgenotherapy, i.e. TST, and those with a poor clinical response should be reared as girls. The only exception is 5 $\alpha$ -reductase deficiency patients, if recognized, in whom a masculine puberty is expected and may be reared as male.
- True hermaphrodites are preferably reared as girls as they have adequate Mullerian structures, i.e. vagina.
- Mixed gonadal dysgenesis patients with inadequate phallus and intra-abdominal testis are preferably reared as girls. Male sex may, however, be chosen when the phallus has adequate size and cavernosum and the testis is palpable, inguinal or scrotal,
- Pure gonadal dysgenesis patients are reared as girls.

### 10.3.2 Late diagnosis and management

Problems arise when cases with disordered sexual differentiation are brought for urological consultation during late childhood or adolescence. These individuals fail to conform to their sex of rearing, cannot perform sexually or still have gonads with neoplastic potential.

Female patients with CAH may complain of difficulties during intercourse because of a narrow introitus and inadequate vaginal opening. The patient should be carefully examined, if needed under general anaesthesia, and a gynaecologist should be called in to assess the need for revision vaginoplasty.

Male patients with CAH may present with signs of excess androgen production such as rapid growth, hirsutism and precocious puberty. Steroid treatment will stall their precocious puberty and prevent premature closure of the epiphyses.

Male pseudohermaphrodites due to 5 $\alpha$ -reductase deficiency reared as girls develop at puberty the secondary characteristics dependent on TST. They become aggressively male in behaviour, their 'clitoris' grows, the voice breaks, the body habitus becomes obviously male, whereas there is no acne or facial hirsutism. Careful urological examination will reveal high lying testes. The question of gender re-assignment at this stage may become the centre of prolonged discussion, and re-evaluation by a team of specialists, including a psychiatrist, is mandatory.

## 10.4 TREATMENT

Problems of ambiguous genitalia should, in principle, be managed by a team of specialists in order to reach a prompt and correct diagnosis. Amongst this group, urologists should have an important role and work in close co-operation with neonatologists, endocrinologists and geneticists, in order to achieve the best possible management of these patients.

### 10.4.1 Genitoplasty

Masculinizing genitoplasty incorporates the following stages:

- a) Androgenotherapy i.e. administration of TST. Its goal is to restore, if possible, a normal penile size, hence it should be used in the first months of life. Systemic or local TST can be administered (the latter mode involves the mother in the treatment).
- b) Excision of Mullerian duct structures: firstly because subsequent urethroplasty may cause urine retention and infection within an existing pseudocolpos, and secondly because casual discovery of a retained Mullerian structure later in life may question the patient's gender.
- c) Urethroplasty with release of chordee and correction of scrotal deformities.  
Orchidopexy of testes that are to be retained.

Feminizing genitoplasty in CAH should be performed once the patient's general status, blood pressure and electrolyte balance have been stabilized by systemic steroid substitution. This is usually achieved around the second or third month of life. The family should be cautioned, however, that re-evaluation of the vaginal opening and possibly revision vaginoplasty may be needed at puberty.

### 10.4.2 Indications for the removal of gonads

The gonads of intersex patients should be removed in the following cases:

- a) Inappropriate gonadal type for the sex of rearing, as in male pseudohermaphrodites who are to be reared as girls or true hermaphrodites where discordant gonadal tissue is not needed. This type of surgery should be performed as early as possible in the neonate.
- b) High risk of malignancy (gonadoblastoma/dysgerminoma). Particularly for patients with mixed gonadal dysgenesis and those with true gonadal dysgenesis and 46XY karyotype. To a lesser extent, for male pseudohermaphrodites with androgen receptor insensitivity and true hermaphrodites with 46XY karyotype. The risk for gonadal tumour is real after puberty, hence this type of surgery can be postponed until that age.

## 10.5 REFERENCES

1. **Allen TD.**  
Disorders of sexual differentiation. *Urology* 1976; 7 (Suppl): 1-32.
2. **Androulakakis PA.**  
*Pediatric Urology*. Beta Publishing Co: Athens, 1993.
3. **Diamond M, Sigmudson HK.**  
Management of intersexuality. Guidelines for dealing with persons with ambiguous genitalia. *Arch Pediatr Adolesc Med* 1997; 151:1046-150.
4. **Fékété CN, Lortat-Jacob S.**  
Management of the intersex child at birth. *Proceedings of Pediatric Uroendocrinology, ESPU Annual Course, 1996, Paris.*
5. **Imperato-Mc Ginley J, Peterson RE, Gautier T, Sturla E.**  
Male pseudohermaphroditism secondary to 5 $\alpha$ -reductase deficiency - a model for the role of androgens in both the development of the male phenotype and the evolution of a male gender identity. *J Steroid Biochem* 1979; 11: 637-645.
6. **Manuel M, Katayama KP, Jones HW.**  
The age of occurrence of gonadal tumors in intersex patients with a Y chromosome. *Am J Obstet Gynecol* 1976; 124: 293-300.
7. **Reiner WG.**  
Sex assignment in the neonate with intersex or inadequate genitalia. *Arch Pediatr Adolesc Med* 1997; 151: 1051-1052.
8. **Rubin RT, Reinisch JM, Haskett RF.**  
Postnatal gonadal steroid effects on human behavior. *Science* 1981; 211: 1318-1324.

9. **Savage MO, Lowe DG.**  
Gonadal neoplasia and abnormal sexual differentiation. Clin Endocrinol 1990; 32: 519-533.
10. **Sohval AR.**  
"Mixed" gonadal dysgenesis: a variety of hermaphroditism. Am J Hum Genet 1963; 15: 155-158.
11. **Whitaker RH, Williams DM.**  
Diagnostic assessment of children with ambiguous genitalia. Eur Urol Update Series 1993; 2: 2-7.

# 11. URODYNAMICS

## 11.1 STANDARDIZATION OF INVESTIGATIONS

### 11.1.1 Residual urine

Except in infants, the normal bladder will empty completely. Unrepresentative results may be obtained after voiding in unfamiliar surroundings, after voiding on command with a partially filled or overfilled bladder, or in patients with a high-grade VUR. An isolated finding requires confirmation. Residual volumes can be considered clinically significant when they represent on repeated occasions volumes of more than 20 mL, or volumes of >10% of cystometric bladder capacity.

### 11.1.2 Uroflowmetry

This involves measurement, either sitting or standing, of voided volume, micturition time, average and maximum urine flow rate. The dependence of the urine flow rate on bladder capacity, which in itself is age-dependent, has to be taken into account. Assessment of the maximum urine flow rate is only valid if the bladder is filled to more than half of its total capacity.

### 11.1.3 Cystometry

Cystometry is the measurement of intravesical and intra-abdominal pressures during storage and voiding phases. The advantage of transurethral access in school children is based on minimal invasiveness and recording of valid measurements. In younger children, the undisturbed assessment of the voiding phase requires a suprapubic measurement catheter equipment (7 Charr, double lumen filling/measurement catheter or a micro-tip catheter).

With a measurement catheter, rectal pressure sensor and two perineal electrodes to obtain muscular action potential from the pelvic floor, the investigation is performed in the supine position. The neutral electrode is applied to the thigh. Before the investigation the measurement catheter, electronic instruments, measurement tubing, pressure transducer and bubble-free filled input are connected; the external pressure transducer is adjusted to the symphyseal level and set to zero against atmospheric pressure. The correct position and function of the measurement equipment are checked by adequate pressure responses on coughing at regular intervals. The examination should be performed at the earliest 4-6 hours after sedation under infusion of isotonic NaCl solution or contrast medicine or dye. Bladder sensations (first desire to void; normal desire to void; strong desire to void; urgency; pain) are recorded; provocation tests (coughing, abdominal pressure rises and voluntary contraction of the external sphincters) are carried out intermittently. If a neuropathic bladder is suspected, provocation with 20 mL of ice water with about 50 mL bladder filling may be carried out. Non-suppressible detrusor contractions are signs of neurogenic disinhibition.

The carbachol test (subcutaneous injection of 0.035 mg of carbachol per kg of body-weight for children) allows differentiation between neurogenic and myogenic detrusor contractility. In neurogenic bladder dysfunction, an intravesical pressure rise of more than 25 cmH<sub>2</sub>O as over-reaction of the bladder denervation to the cholinergic stimulation after 20-30 minutes is recorded. Intact central inhibition prevents the increase in tonus of the detrusor.

The following parameters are determined with filling cystometry: residual urine (mL), maximum bladder capacity (mL), effective bladder capacity (mL), compliance (mL/cmH<sub>2</sub>O), intravesical pressure (cmH<sub>2</sub>O), abdominal pressure (cmH<sub>2</sub>O), detrusor pressure (cmH<sub>2</sub>O) and first desire to void. With voiding cystometry, the following parameters are determined: opening time (sec), pre-micturition pressure (cmH<sub>2</sub>O), opening pressure (cmH<sub>2</sub>O), maximum voiding pressure (cmH<sub>2</sub>O), intravesical pressure at maximum urine flow (cmH<sub>2</sub>O) urine flow (mL/sec), duration of micturition (sec), flow time (sec), maximum urine flow rate (mL/sec), time of flow increase (sec), micturition volume (mL), coefficient of resistance (cmH<sub>2</sub>O /mL/sec), contraction pressure at maximum urine flow (cmH<sub>2</sub>O), after contraction.

### 11.1.4 Video-urodynamic evaluation

Using a contrast media, video-urodynamic evaluation combines fluoroscopic recording of the bladder filling and emptying with simultaneous urodynamic examination. The necessity of short transillumination periods, particularly during the filling phase of the urine bladder (e.g. to exclude a VRR during involuntary detrusor contraction), depends on the demands of the attending physician. Digital X-ray equipment allows a 75% reduction in radiation exposure compared with conventional techniques. The most important indication for video-urodynamics evaluation is abnormal voiding (i.e. differential diagnosis of bladder outlet obstruction versus neuropathic vesico-urethral dysfunction).

### 11.1.5 Urethral pressure profile (sphincterometry)

Resting or stress profile of the urethra is used to determine and quantify sphincter insufficiency; however, the method cannot verify subvesical obstruction. Urethral pressure profile measurement is indicated in the assessment of stress incontinence (e.g. post-traumatic, sinus urogenitalis, myelomeningocele). In children, only thin micro-tip catheters with urethral and vesical pressure transducer should be used. A continuous withdrawal is necessary to determine the functional length of the urethra (withdrawal speed of 2-10 cm/min; faster withdrawal produces higher pressure values). At rest, the urethral profile is determined by continuous withdrawal of the measuring sensor. In the urethral stress profile, the pressure in the urethra and the pressure transmission are determined during intermittent intra-abdominal pressure rises (e.g. coughing, Valsalva's manoeuvre). After voiding to completion, the bladder should be filled up to 50% of its maximum capacity with a maximum of 100 mL.

### 11.1.6 Electromyography (EMG) of the external sphincter

EMG is the study of electrical potentials generated by the depolarization of the external sphincter. For recording, skin surface electrodes are used in children, positioned left and right from the external anal sphincter. EMG should be interpreted in the light of the patient's symptoms, physical findings and urological and urodynamic investigations.

In normal subjects, there is a gradual increase in EMG activity from the pelvic floor during bladder filling; at the onset of micturition, there is complete absence of activity.

The finding of increased EMG activity during voiding, accompanied by simultaneous detrusor pressure and flow changes, is described by the term detrusor-sphincter dyssynergia (in neuropathic bladder/sphincter dysfunction) or detrusor-sphincter dysco-ordination (in neurologically normal children). Because of the many artefacts noted and the inability to distinguish electronic 'noise' from true EMG potentials on the recording, there is no consensus about using the EMG registration.

**Table 19: Urodynamics: normal values in children**

<b>Storage phase</b>	
Maximum cystometric bladder capacity:	Age dependent (approx. age x 30)
Residual urine:	< 10 % of the bladder capacity
First desire to void:	Bladder filling > 60 % of the maximum bladder capacity
Intravesical pressure:	14 cmH <sub>2</sub> O at the beginning, up to 24 cmH <sub>2</sub> O at the end of the filling
Involuntary detrusor contraction:	None
Compliance:	> 25 mL/cmH <sub>2</sub> O
EMG:	Stable
<b>Micturition phase (mictiometry)</b>	
Maximum urine flow:	Age dependent
Medium urine flow:	Age dependent
Micturition pressure:	< 75 cmH <sub>2</sub> O (age dependent)
EMG:	Fluctuations

EMG = Electromyography

## 11.2 REFERENCES

1. **Agarwal SK, McLorie GA, Grewal D, Joyner BD, Bagli DJ, Khoury AE.**  
Urodynamic correlates of resolution of reflux in meningomyelocele patients. *J Urol* 1997; 158: 580-582.
2. **Bomalaski MD, Bloom DA.**  
Urodynamics and massive vesicoureteral reflux. *J Urol* 1997; 158: 1236-1238.
3. **Chandra M.**  
Nocturnal enuresis in children. *Curr Opin Pediatr* 1998; 10: 167-173.
4. **Cisternino A, Passerini Glazel G.**  
Bladder dysfunction in children. *Scand J Urol Nephrol Suppl* 1995; 173: 25-28; discussion 29.
5. **Combs AJ, Horowitz M.**  
A new technique for assessing detrusor leak point pressure in patients with spina bifida. *J Urol* 1996; 156: 757-760.
6. **Dahms SE, Schulz-Lampel D, Thüroff JW.**  
Leitlinie zur Urodynamik in der Kinderurologie. *Urologe A* 1998; 37: 574-575.



7. **Ewalt DH, Bauer SB.**  
Pediatric neurourology. *Urol Clin North Am* 1996; 23: 501-509.
8. **Hoebeke P, Raes A, Vande Walle J, Van Laecke E.**  
Urodynamics in children: what and how to do it? *Acta Urol Belg* 1998; 66: 23-30.
9. **Hoebeke P, Vande Walle J, Everaert K, Van Laecke E, Van Gool JD.**  
Assessment of lower urinary tract dysfunction in children with non- neuropathic bladder sphincter dysfunction. *Eur Urol* 1999; 35: 57-69.
10. **Hoekx L, Wyndaele JJ, Vermandel A.**  
The role of bladder biofeedback in the treatment of children with refractory nocturnal enuresis associated with idiopathic detrusor instability and small bladder capacity. *J Urol* 1998; 160: 858-860.
11. **Holmdahl G, Sillen U, Bachelard M, Hansson E, Hermansson G, Hjalmas K.**  
The changing urodynamic pattern in valve bladders during infancy. *J Urol* 1995; 153: 463-467.
12. **Jorgensen JB, Jensen KM.**  
Uroflowmetry. *Urol Clin North Am* 1996; 23: 237-242.
13. **Kaefer M, Rosen A, Darbey M, Kelly M, Bauer SB.**  
Pressure at residual volume: a useful adjunct to standard fill cystometry. *J Urol* 1997; 158: 1268-1271.
14. **Kaplinsky R, Greenfield S, Wan J, Fera M.**  
Expanded followup of intravesical oxybutynin chloride use in children with neurogenic bladder. *J Urol* 1996; 156: 753-756.
15. **Kjolseth D, Madsen B, Knudsen LM, Norgaard JP, Djurhuus JC.**  
Biofeedback treatment of children and adults with idiopathic detrusor instability. *Scand J Urol Nephrol* 1994; 28: 243-247.
16. **Nijman RJ.**  
Pitfalls in urodynamic investigations in children. *Acta Urol Belg* 1995; 63: 99-103.
17. **Norgaard JP.**  
Technical aspects of assessing bladder function in children. *Scand J Urol Nephrol Suppl* 1995; 173: 43-46; discussion 46-47.
18. **Norgaard JP, Van Gool JD, Hjalmas K, Djurhuus JC, Hellstrom AL.**  
Standardization and definitions in lower urinary tract dysfunction in children. International Children's Continence Society. *Br J Urol* 1998; 81 Suppl 3: 1-16.
19. **Opsomer RJ, Clapuyt P, De Groote P, Van Cangh PJ, Wese FX.**  
Urodynamic and electrophysiological testing in pediatric neurourology. *Acta Urol Belg* 1998; 66: 31-34.
20. **Schultz Lampel D, Thüroff JW.**  
Enuresis. *Urologe A* 1997; 36: W265-274.
21. **Shoukry MS, El Salmy S, Aly GA, Mokhless I.**  
Urodynamic predictors of upper tract deterioration in children with myelodysplasia. *Scand J Urol Nephrol* 1998; 32: 94-97.
22. **Starr NT.**  
Pediatric gynecology urologic problems. *Clin Obstet Gynecol* 1997; 40: 181-199.
23. **Wan J, Greenfield S.**  
Enuresis and common voiding abnormalities. *Pediatr Clin North Am* 1997; 44: 1117-1131.
24. **Yannakoyorgos K, Ioannides E, Zahariou A, Anagnostopoulos D, Kesselas V, Kalinderis A.**  
Management of nocturnal enuresis in children with desmopressin and bladder physiotherapy. *Pediatr Surg Int* 1998; 13: 281-284.
25. **Yeung CK, Godley ML, Duffy PG, Ransley PG.**  
Natural filling cystometry in infants and children. *Br J Urol* 1995; 75: 531-537.
26. **Zermann DH, Lindner H, Huschke T, Schubert J.**  
Diagnostic value of natural fill cystometry in neurogenic bladder in children. *Eur Urol* 1997; 32: 223-228.

In view of the diversity and complexity of the addressed issues on the one hand and the necessity to limit the number of cited articles on the other hand an incorporation of the references into the text seemed inappropriate.

## 12 ABBREVIATIONS USED IN THE TEXT

AGS:	adrenogenital syndrome
AMH:	anti-Mullerian hormone
CAH:	congenital adrenal hyperplasia
CNS:	central nervous system
CRP:	C-reactive protein
CT:	computed tomography
DHTST:	dihydrotestosterone
DMSA:	di-mercaptosuccinic acid
EMG:	electromyography
ESR:	erythrocyte sedimentation rate
ESWL:	extracorporeal shock wave lithotripsy
FSH:	follicle stimulating hormone
HCG:	human chorionic gonadotrophin
IVU:	intravenous urogram
LH:	luteinizing hormone
LHRH:	luteinizing hormone releasing hormone
MRI:	magnetic resonance imaging
PNL:	percutaneous litholapaxy
TST:	testosterone
UPJ:	ureteropelvic junction
URS:	ureterorenoscopy
UTIs:	urinary tract infections
VCUG:	voiding cystourethrography
VRR:	vesicorenal reflux
VUR:	vesicoureteral reflux